



# ELECTROENCEPHALOGRAPHY

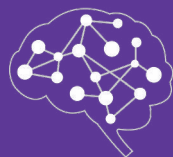An Introductory Text and Atlas of Normal and Abnormal Findings in Adults, Children, and Infants

Erik K. St. Louis, MD

*Mayo Clinic College of Medicine, Rochester, Minnesota*

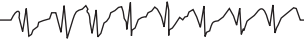Lauren C. Frey, MD

*University of Colorado, Denver, Colorado*



AMERICAN  
EPILEPSY  
SOCIETY

[www.AESNET.org](http://www.AESNET.org)



# Electroencephalography (EEG): An Introductory Text and Atlas of Normal and Abnormal Findings in Adults, Children, and Infants

## Editors

Erik K. St. Louis, MD  
*Mayo Clinic College of Medicine, Rochester, Minnesota*

Lauren C. Frey, MD  
*University of Colorado, Denver, Colorado*

## Contributors

Jeffrey W. Britton, MD  
*Mayo Clinic College of Medicine, Rochester, Minnesota*

Lauren C. Frey, MD  
*University of Colorado, Denver, Colorado*

Jennifer L. Hopp, MD  
*University of Maryland, Baltimore, Maryland*

Pearce Korb, MD  
*University of Colorado, Denver, Colorado*

Mohamad Z. Koubeissi, MD, FAAN, FANA  
*George Washington University, Washington, District of Columbia*

William E. Lievens, MD  
*University of Alabama, Birmingham, Alabama*

Elia M. Pestana-Knight, MD  
*Cleveland Clinic Foundation, Cleveland, Ohio*

Erik K. St. Louis, MD  
*Mayo Clinic College of Medicine, Rochester, Minnesota*

## Staff

Executive Director: Eileen M. Murray, MM, CAE  
Project Manager: Jessica A. Daniels, MNA  
Publishing Manager: David Burns, Allen Press, Inc, Lawrence, KS

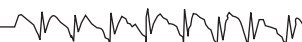ISBN: 978-0-9979756-0-4  
Copyright ©2016 by American Epilepsy Society  
135 S. LaSalle St., Suite 2850, Chicago, IL 60603

Care has been taken to confirm the accuracy of the information presented and to describe generally accepted practices. However, the authors, editors, and publisher are not responsible for errors or omissions or for any consequences from application of the information in this book and make no warranty, express or implied, with respect to the contents of the publication.

This text is designed to assist clinicians by providing a framework for evaluating and treating patients. It is not intended to establish a community standard of care, replace a clinician's medical judgment, or establish a protocol for all patients. The clinical conditions contemplated by the text will not fit or work with all patients. Approaches not covered here may be appropriate.

The authors, editors, and publisher have exerted every effort to ensure that drug selection and dosage set forth in this text are in accordance with current recommendations and practice at the time of publication. However, in view of ongoing research, changes in government regulations, and the constant flow of information relating to drug therapy and drug reactions, the reader is urged to check the package insert for each drug for any change in indications and dosage and for added warnings and precautions. This is particularly important when the recommended agent is a new or infrequently employed drug.

Some drugs and medical devices presented in this publication have Food and Drug Administration (FDA) clearance for limited use in restricted research settings. It is the responsibility of the health care provider to ascertain the FDA status of each drug or device planned for use in their clinical practice.



### **License**

Except where indicated, this publication is licensed under the Creative Commons Attribution-NonCommercial-ShareAlike 4.0 International Public License (BY-NC-SA: <http://creativecommons.org/licenses/by-nc-sa/4.0/legalcode>).

No permission is required from the editors, authors, or publisher to reuse or repurpose content, provided the original work is properly cited. Figures, tables, and images included in this work are also published under the CC BY-NC-SA license and should be properly cited when reused or repurposed.

For any reuse or redistribution of a work, you must also make clear the license terms under which the work was published. You may not apply legal or technological measures that legally restrict others from doing anything the license permits.

### **Using Content, Including Figures, Tables, and Images**

Notifications of re-use should be directed to [education@aesnet.org](mailto:education@aesnet.org).

Where indicated, image and figure re-use permission requests should be directed to the Mayo Foundation for Medical Education and Research.

### **Attribution**

This publication is provided by the American Epilepsy Society (AES) for use by educators and students. Additional resources from AES are available to the medical and scientific community. Visit [www.aesnet.org](http://www.aesnet.org) to find more.

The following is an example of proper attribution for this work:

St. Louis, EK, Frey, LC (Eds.). *Electroencephalography (EEG): An introductory text and atlas of normal and abnormal findings in adults, children and infants*. Chicago, IL: American Epilepsy Society; 2016. <http://dx.doi.org/10.5698/978-0-9979756-0-4>.

### **About the American Epilepsy Society**

The American Epilepsy Society is a medical and scientific society whose members are engaged in research and clinical care for people with epilepsy. For more than 75 years, AES has provided a dynamic global forum where professionals from academia, private practice, not-for-profit, government, and industry can learn, share, and grow. Find out more at [www.aesnet.org](http://www.aesnet.org).

The Society seeks to promote interdisciplinary communications, scientific investigation, and exchange of clinical information about epilepsy.

This publication was produced through the volunteer efforts of the AES Council on Education, Student & Resident Education & Curriculum Committee, and the EEG Work Group.

### **Correspondence**

American Epilepsy Society  
135 S. LaSalle St., Suite 2850, Chicago, IL 60603  
Phone: (312) 883-3800 | email: [info@aesnet.org](mailto:info@aesnet.org) | website: [www.aesnet.org](http://www.aesnet.org)

Erik K. St. Louis, MD - Ex Officio Work Group Chair, Primary Author & Editor  
Departments of Neurology and Medicine, Mayo Clinic  
200 First Street SW, Rochester, MN 55905  
Phone: (507) 266-7456 | email: [StLouis.Erik@mayo.edu](mailto:StLouis.Erik@mayo.edu)

Lauren Frey, MD - Workgroup Chair & Editor  
Department of Neurology, University of Colorado  
Phone: (720) 848-8583 | email: [Lauren.Frey@ucdenver.edu](mailto:Lauren.Frey@ucdenver.edu)



# Table of Contents

## Introduction

Brief History and Background

## **An Orderly Approach to EEG Analysis: Visual Inspection of the Background and Pattern Recognition** ..... 6

Calibration

Orientation and Nomenclature

Clinical Approach

## **The Normal EEG** ..... 8

The Background

Provocation Techniques

Drowsiness and Sleep

## **The Developmental EEG: Premature, Neonatal, Infant, and Children** ..... 20

Neonatal EEG

Infant and Pediatric Developmental Changes in the EEG

## **Benign Variants in the EEG** ..... 42

## **The Abnormal EEG** ..... 48

Focal and Generalized Slowing and Significance

Encephalopathies/Delirium

Dementias

Coma

Anesthetic Patterns

## **EEG in the Epilepsies** ..... 56

Routine Interictal EEG in Epilepsy and Spells

Ictal EEG Applications and Formats

Nonepileptic Spells

Epileptic Seizure Classification and Types

Long-term Video-EEG Monitoring With Intracranial Electrodes

## **Urgent and Emergent EEG for Evaluation and Treatment of Acute Seizures** ..... 73

## **References** ..... 80

## **Additional Texts and Recommended Readings** ..... 81

## **Appendix 1. The Scientific Basis of EEG: Neurophysiology of EEG Generation in the Brain** ..... 81

## **Appendix 2. Principles of Digital EEG** ..... 81

EEG Signal Collection and Display

Advantages of Digital EEG

## **Appendix 3. Principles of Electrical Safety** ..... 83

## **Appendix 4. Common Artifacts During EEG Recording** ..... 84

Eye Movements

Tongue Movements, Talking, and Chewing

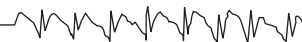Movement Artifacts

Electrode Artifacts

Sweat Artifact

## **Appendix 5. EEG Standards and Examples for the Determination of Brain Death** ..... 94

## **Appendix 6. A Brief History of EEG** ..... 95



## Introduction

### *Brief History and Background*

The first known neurophysiologic recordings of animals were performed by Richard Caton in 1875. The advent of recording the electrical activity of human beings took another half century to occur. Hans Berger, a German psychiatrist, pioneered the EEG in humans in 1924. The EEG is an electrophysiological technique for the recording of electrical activity arising from the human brain. Given its exquisite temporal sensitivity, the main utility of EEG is in the evaluation of dynamic cerebral functioning. EEG is particularly useful for evaluating patients with suspected seizures, epilepsy, and unusual spells. With certain exceptions, practically all patients with epilepsy will demonstrate characteristic EEG alterations during an epileptic seizure (ictal, or during-seizure, recordings). Most epilepsy patients also show characteristic interictal (or between-seizure) epileptiform discharges (IEDs) termed spike (<70  $\mu$ sec duration), spike and wave, or sharp-wave (70–200  $\mu$ sec duration) discharges.

EEG has also been adopted for several other clinical indications. For example, EEG may be used to monitor the depth of anesthesia during surgical procedures; given its great sensitivity in showing sudden changes in neural functioning even as they first occur, it has proven quite helpful in this setting in monitoring for potential complications such as ischemia or infarction. EEG waveforms may also be averaged, giving rise to evoked potentials (EPs) and event-related potentials (ERPs), potentials that represent neural activity of interest that is temporally related to a specific stimulus. EPs and ERPs are used in clinical practice and research for analysis of visual, auditory, somatosensory, and higher cognitive functioning.

The EEG is thought to be primarily generated by cortical pyramidal neurons in the cerebral cortex that are oriented perpendicularly to the brain's surface. The neural activity detectable by the EEG is the summation of the excitatory and inhibitory postsynaptic potentials of relatively large groups of neurons firing synchronously. Conventional scalp or cortical surface-recorded EEG is unable to register the momentary local field potential changes arising from neuronal action potentials. Please see Appendix 1 for further details on neurophysiologic principles underlying the EEG.

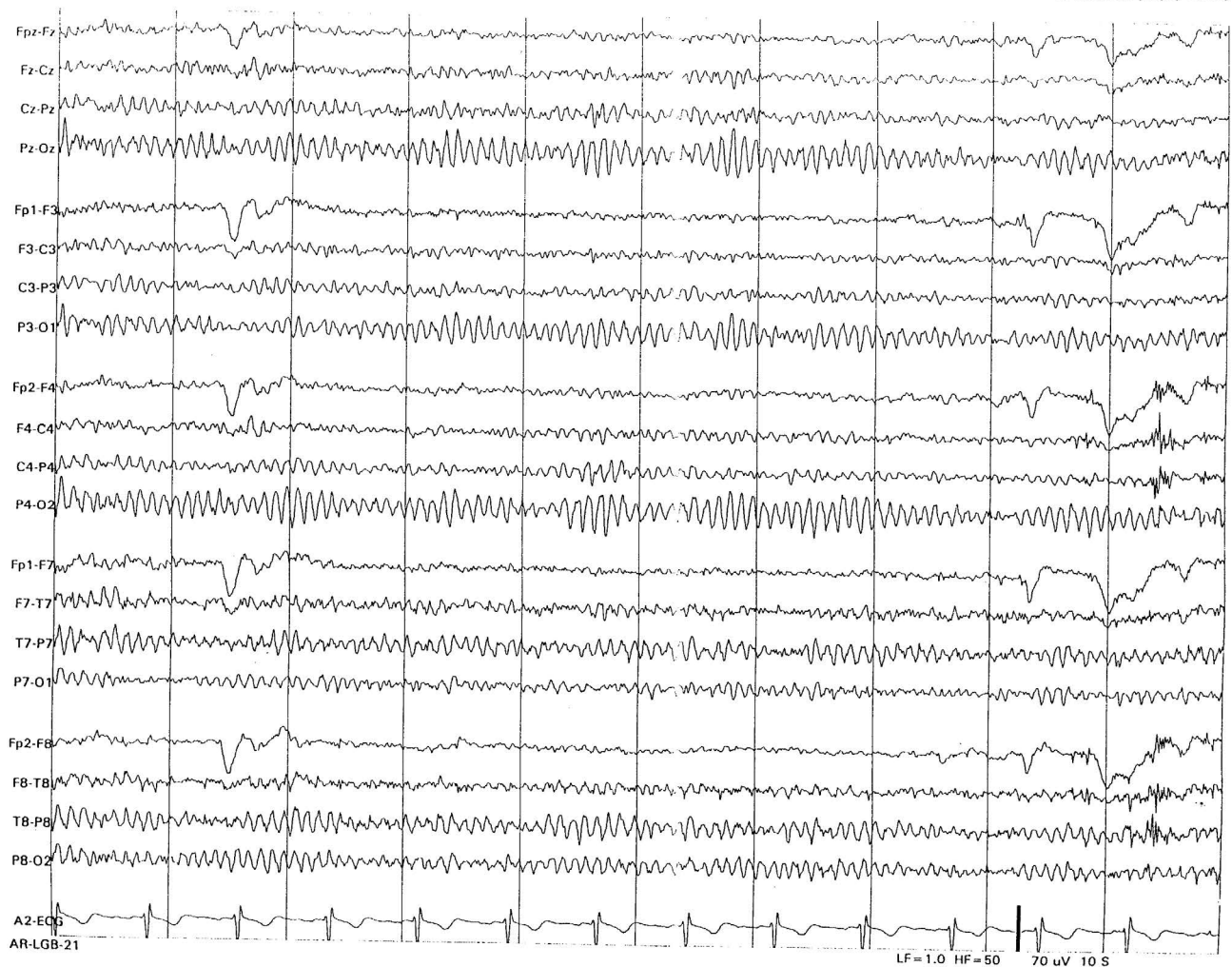
An unfortunate reality of EEG is that cerebral activity may be overwhelmed by other electrical activity generated by the body or in the environment. To be seen on the scalp surface, the miniscule, cerebrally generated EEG voltages must first pass through multiple biological filters that both reduce signal amplitude and spread the EEG activity out more widely than its original source vector. Cerebral voltages must traverse the brain, CSF, meninges, the skull, and skin prior to reaching the recording site where they can be detected. Additionally, other biologically generated electrical activity (by scalp muscles, the eyes, the tongue, and even the distant heart) creates massive voltage potentials that frequently overwhelm and obscure the cerebral activity. Temporary detachments of the recording electrodes (called "electrode pop" artifact) can further erode the EEG, or even imitate brain rhythms and seizures. The bottom line is that biological and environmental electrical artifacts frequently interfere with the interpreter's ability to accurately identify both normal rhythms and pathological patterns. Fortunately, artifacts possess many distinguishing characteristics that are readily identifiable by well-trained, careful observers. Please see Appendix 4 for several examples of artifacts commonly encountered during EEG recording.



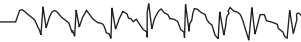A typical EEG display graphs voltages on the vertical domain and time on the horizontal domain, providing a near real-time display of ongoing cerebral activity (Figure 1). With digital recording and review, the interpreter can change several aspects of the EEG display for convenience and intelligibility of the data. The interpreter is able to adjust the sensitivity (also known as [aka] "gain") of the recording, in microvolts per millimeter, to either increase or reduce the display height of waveforms. One may also alter the amount of time displayed, which is sometimes referred to as an epoch and used to be known as "paper speed." Shorter intervals can be viewed with a few seconds on a computer screen, a distinct advantage for viewing very brief EEG events such as epileptiform spikes. Conversely, the time scale may be expanded to display longer segments of EEG over several minutes to look at slowly evolving rhythmic discharges. Digital filters may also be applied to reduce artifact in certain settings but must be used with great caution since they also filter EEG activity of interest and may distort EEG waveforms severely.

EEG uses the principle of differential amplification, or recording voltage differences between different points using a pair of electrodes that compares one active exploring electrode site with another neighboring or distant reference electrode. Only through measuring differences in electrical potential are discernible EEG waveforms generated. By convention, when the active exploring electrode (termed G1, for "Grid 1," a historical convention from analog amplification) is more negative than the reference

© American Epilepsy Society

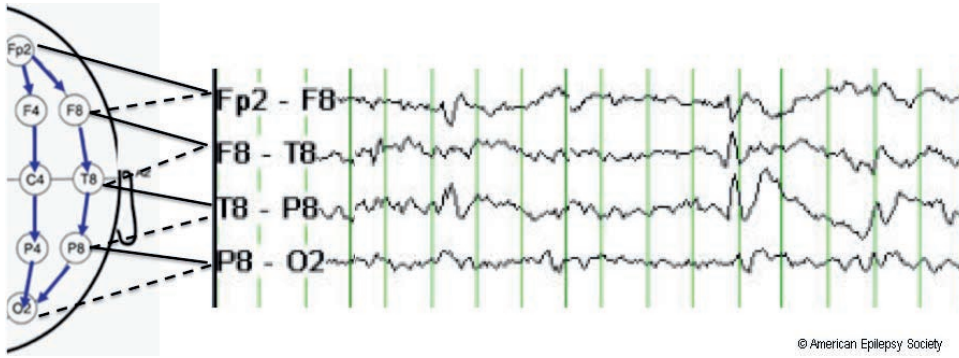


**Figure 1.** Normal EEG with typical montage. An example of the EEG recorded during wakefulness in a 24-year-old woman. This is a 10-second duration epoch. The first four channels, together referred to as a chain, show cerebral activity recorded from the midline head region and by convention are arranged front to back. The next four channels, the second chain, show activity over the left parasagittal head region. The middle four channels, the third chain, shows the corresponding right parasagittal region. The two bottom sets of four channels, or chains, each show the left and right temporal head regions, respectively. Each division shows 1 second of recording time. There is faster sinusoidal rhythmic activity that is most prominent in each set of four channels over the occipital regions or posterior channels and is approximately symmetric. This is the PDR, best seen when the eyes are closed during relaxed wakefulness. The broadly contoured, downward deflection in the 2nd second in each of the five frontal channels represents an eye-blink artifact, as does the similar wave in the 9th second. An ECG channel is displayed at the very bottom, which helps the interpreter to detect the cardiac cycle (a common source of artifacts contaminating the EEG channels) and possible cardiac dysrhythmias. Copyright 2013. Mayo Foundation for Medical Education and Research. All rights reserved. Figure courtesy of Erik K. St. Louis, MD.



electrode (G2), the EEG potential is directed above the horizontal meridian (i.e., an upward wave), whereas if the opposite is true, where the reference electrode is more negative, the EEG potential vector is directed below the horizontal meridian (downward potential). Other polarity possibilities are shown in Figure 2.

A related technique to the EEG is MEG, which does not record electrical activity but, rather, utilizes sensors to capture magnetic fields generated by the brain. MEG provides complementary information to the EEG by demonstrating the activity of magnetic cerebral dipoles. Since magnetic fields are less degraded by the head's biological filters than electrical activity, MEG dipoles may produce more accurate locations for cerebral epileptiform generators than EEG. A detailed review of MEG is beyond the scope of this review. The interested reader is referred to excellent recent literature on the subject (1–3). See Figure 3 for an example of MEG.



**Figure 2.** Polarity conventions and localization in EEG. An upward deflection is surface negative, and a downward deflection is surface positive. Each derivation or channel is made up of two electrode site pairs, in the manner shown below, which shows a longitudinal bipolar recording strategy (the voltage recorded at one electrode site is subtracted from its neighbor, front to back, in series in a linked chain, where Grid 1 represents the first electrode site and Grid 2, the second electrode site). In the example below, there are two sharp waves with slightly differing polarity characteristics shown.

In the first second, the sharp wave has maximal electronegativity at F8–T8, where equipotential is seen; channel 1 (FP2–F8) shows a surface positive deflection, because the sharp wave is oriented downward (this means that Grid 1 [FP2] is relatively more positive than Grid 2 [F8]), while in channel 2 (F8–T8), there is a fairly flat voltage, as Grid 1 (F8) and Grid 2 (T8) are nearly equal in voltage to one another, leading to a substantial amount of in-phase cancellation and an isoelectric/equipotential voltage (equal voltage at both sites). Channel 3 (T8–P8) shows a surface negative upward deflection of the sharp wave, meaning that Grid 1 (T8) is more negative than Grid 2 (P8) in voltage. Channel 4 (P8–O2) again shows a slightly upward, surface negative waveform, showing a falling off of voltage of the spike focus. Determining the voltages in this manner across channels helps the interpreter to localize the maximal negativity to channel 2 (F8–T8), suggesting that there is a sharp-wave focus held between the second and third electrode sites in the chain.

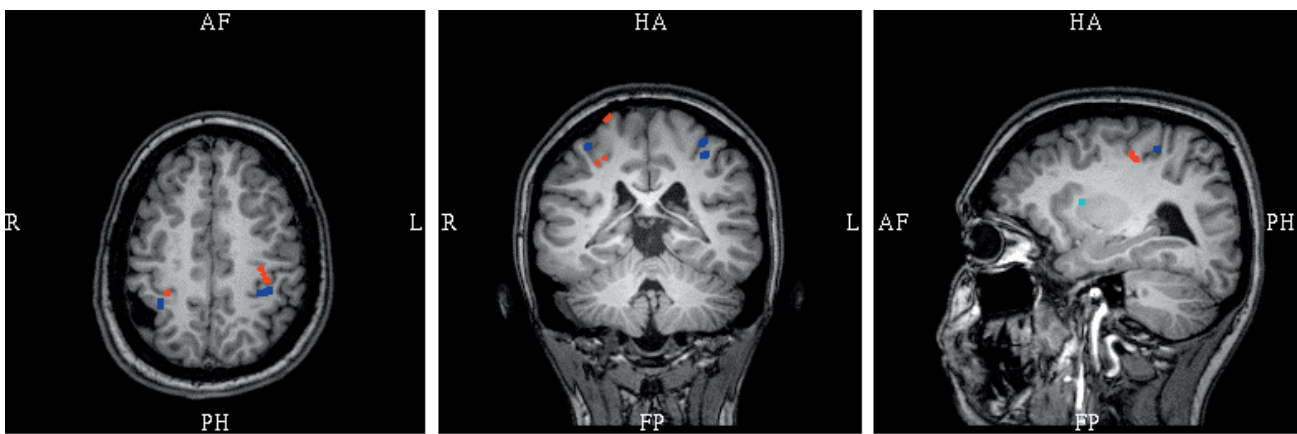
In the second sharp wave, occurring late within the 2nd second, the sharp wave shows maximal electronegativity instead at the F8 electrode. The logic for localization is similar to the example above. In channel 1 (FP2–F8), there is a downward, surface positive deflection, whereas in channel 2 (F8–T8), there is an upward, surface negative deflection, so one can conclude that the sharp wave is localized to F8.

Copyright 2013. Mayo Foundation for Medical Education and Research. All rights reserved. Figure courtesy of Erik K. St. Louis, MD.

cerebral dipoles. Since magnetic fields are less degraded by the head's biological filters than electrical activity, MEG dipoles may produce more accurate locations for cerebral epileptiform generators than EEG. A detailed review of MEG is beyond the scope of this review. The interested reader is referred to excellent recent literature on the subject (1–3). See Figure 3 for an example of MEG.

**An Orderly Approach to EEG Analysis: Visual Inspection of the Background and Pattern Recognition**

Novice EEG interpreters are often and understandably overwhelmed by the sheer amount of data before them and may balk at the whole enterprise as “information overload.” An orderly routine of inspecting the EEG facilitates accurate and thorough review.



**Figure 3.** Example of MEG. Equivalent current dipoles in a young girl with tuberous sclerosis. Color-coded regions of interest represent hand motor (red), somatosensory (blue), and epileptiform dipoles (aqua). The sagittal image demonstrates that epileptiform dipoles neighbor a structural tuber and are distant from motor and somatosensory functions. Figure courtesy of Deepak Madhavan, MD, University of Nebraska, Omaha, Nebraska.



### Calibration

Prior to beginning to interpret the EEG, one should first ensure that the study was appropriately calibrated. Before running an EEG recording, the technologist first passes a known voltage through the system to ensure that each amplifier for each channel handles this known signal identically; if there is a problem at this stage, there may be a problem with amplification that could affect interpretation of the EEG. Then, *biocalibration* is performed as an additional step to ensure the fidelity of the cerebral signal; this commonly involves having the patient open and close their eyes.

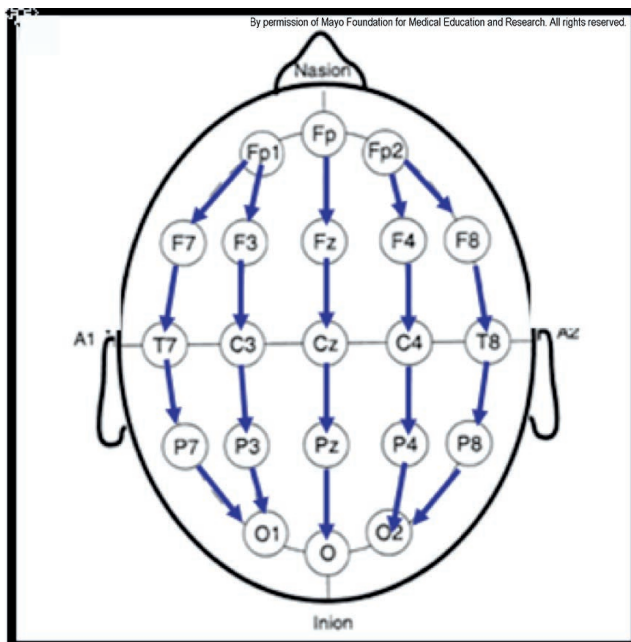
### Orientation and Nomenclature

#### Electrode Placement

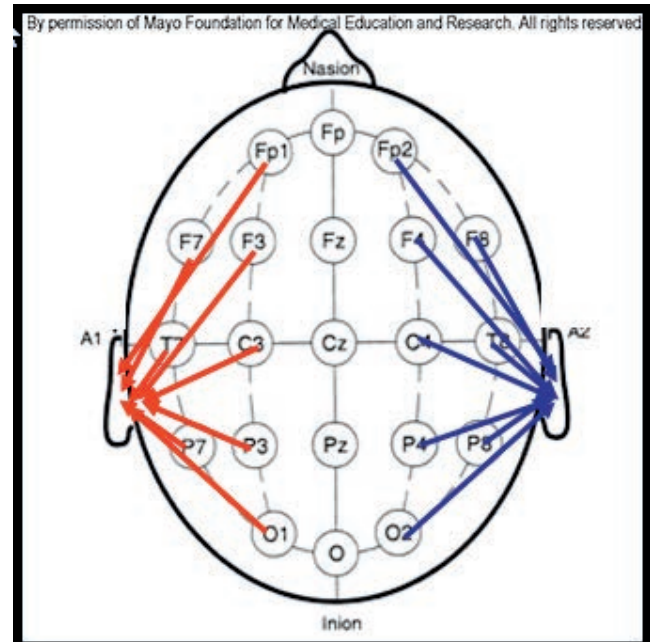
Familiarity with the nomenclature of EEG is important prior to commencing interpretation. Please see Figure 4, which demonstrates the standard International 10-20 electrode site placement strategy. The nomenclature "10-20" represents standard intervals of measurement of either 10 or 20 percent for positioning electrodes over the anterior-posterior dimension between the nasion (point at the bridge of the nose) and inion (prominent bump on the back of the head representing lowest point of the skull), and between the auricular (ear) positions. Each electrode site is represented with a letter and a given number. The letter represents which lobe of the brain the electrode site overlies (i.e., F is frontal, T is temporal, P is parietal, and O is occipital). Odd-numbered electrode sites are on the left side of head, even-numbered electrodes are on the right side, "z"-labeled sites are in the midline from anterior to posterior, and "A" or auricular sites are on the mastoid processes/ears.

#### Montages

Once the calibration has been reviewed and found to accurately display both known voltages and patient EEG data, one should note the EEG montage. A montage is a standardized arrangement and selection of channel pairs and chains for display and review. There are many different montages used for various purposes, but they are divided into two types: bipolar and referential. One common montage is the longitudinal bipolar montage (aka the "double banana" because the electrode configuration appears like two bananas laid front to back over each of the brain hemispheres; see Figure 4). In a bipolar montage, neighboring electrodes are paired to one another, either anterior to posterior (longitudinal bipolar) or side to side (transverse bipolar), which is a good way to try to localize EEG potentials. Alternatively, referential montages link each exploring active electrode to a distant reference. Common referential choices include the vertex (Cz electrode), the mastoid process (either individual ears, as shown in Figure 5, or a mathematical derivation of both sites), or a common average reference. Another commonly used montage in the evaluation of epilepsy is the Laplacian or source derivation montage, where each active recording electrode is compared with a mathematical weighted average of the surrounding electrodes.



**Figure 4.** The International 10-20 electrode placements. Showing a longitudinal bipolar montage. Copyright 2013. Mayo Foundation for Medical Education and Research. All rights reserved. Courtesy of Dr. Jeffrey W. Britton, MD.



**Figure 5.** Ipsilateral ear referential montage. EEG electrode placement using the International 10-20 electrode placement system. Copyright 2013. Mayo Foundation for Medical Education and Research. All rights reserved. Figure courtesy of Jeffrey W. Britton, MD.





*Frequency Bandwidths*

Another important convention of EEG is the notation for different waveform frequency bandwidths, or bands. Frequency of EEG waveforms is important because the predominant frequencies vary by which state (e.g., alert wakefulness, drowsiness, sleep) the patient is in and may confer developmental and pathologic significance. EEG waveform frequency bands are expressed as follows: 1 to 3 cycles per second (Hz) are delta, 4 to 7 Hz are theta, 8 to 12 Hz are alpha, and 13 Hz and higher are beta. Frequencies above 25 Hz are not commonly encountered in the scalp EEG but may be seen arising directly from the cortical surface during intracranial recordings; these frequencies are termed gamma and are divided into low gamma (25–70 Hz) and high gamma (>70 Hz). The term “ripples” (generally >100 Hz) are thought to reflect epileptiform discharges (see Figure 6).

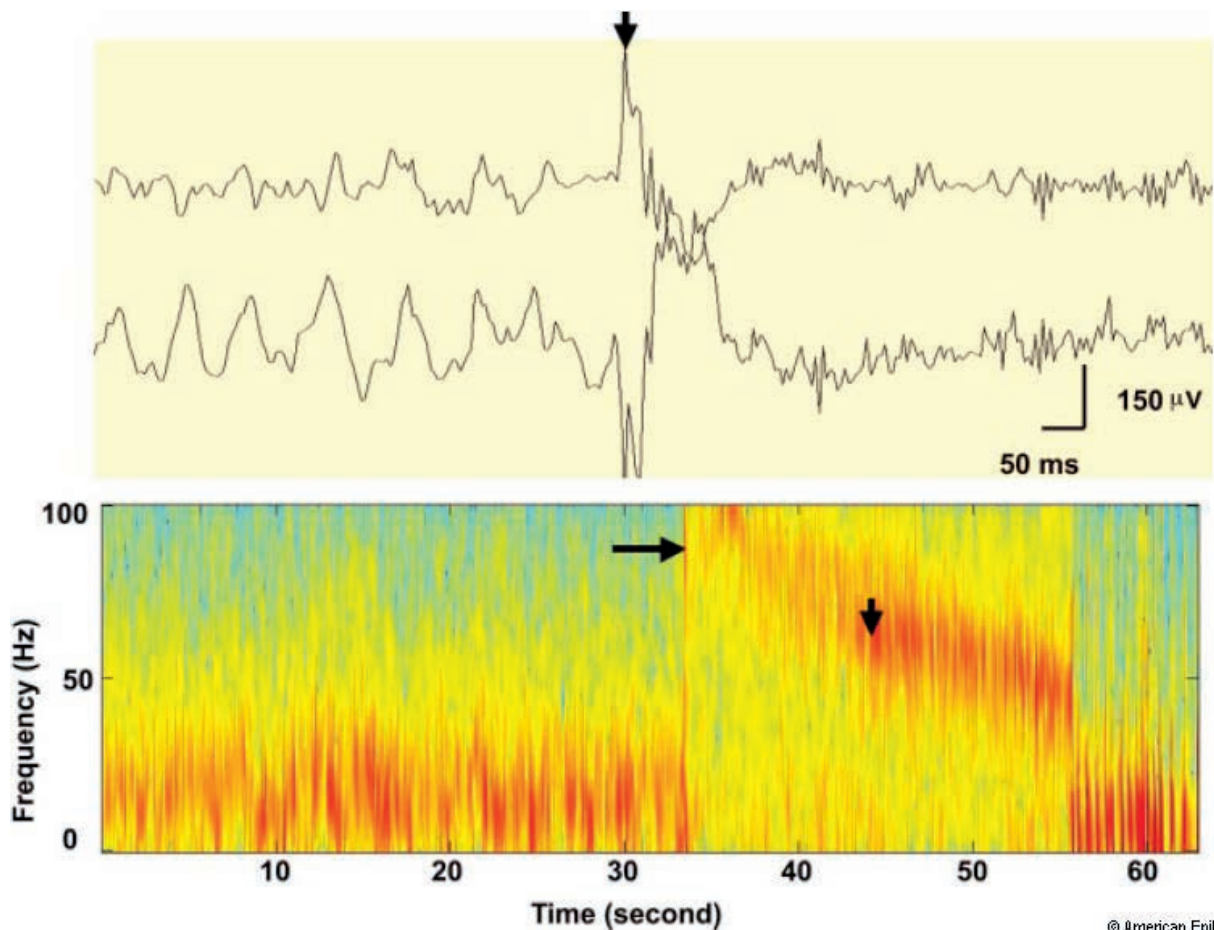
**Clinical Approach**

There are different opinions as to whether one should review the clinical history prior to EEG interpretation. Some experts prefer to know the patient history prior to interpreting the EEG, so that the likelihood of a potential abnormality can be interpreted within its appropriate clinical context. Others think that knowing the history biases the interpretation and may lead to “overcalling” or “undercalling” questionable findings. There is potential value in both approaches, and one solution is to first read through the tracing without the history of the patient, and then take a second pass after reviewing the history.

**The Normal EEG**

*The Background*

One of the initial goals for EEG interpretation is determination of the background. To gain a complete sense about the background EEG, one should employ a variety of different screening montages to enable several different perspectives of its chief frequencies, amplitude, and degree of synchrony.



© American Epilepsy Society

**Figure 6.** Ripples from intracranial EEG recordings. (Figure courtesy of Greg Worrell, MD, and Ben Brinkmann, PhD, Mayo Systems Electrophysiology Laboratory, Mayo Clinic Rochester).

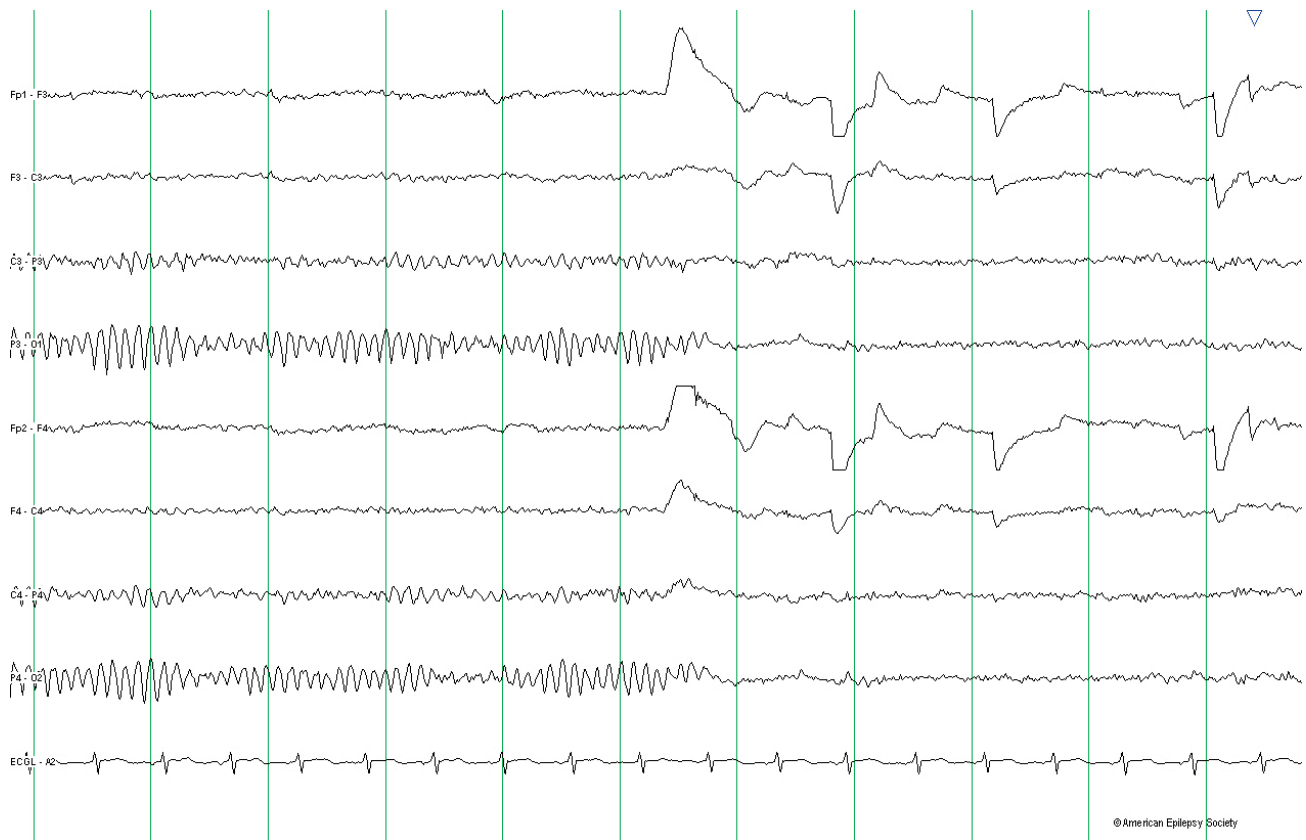


### Common Physiological Artifacts

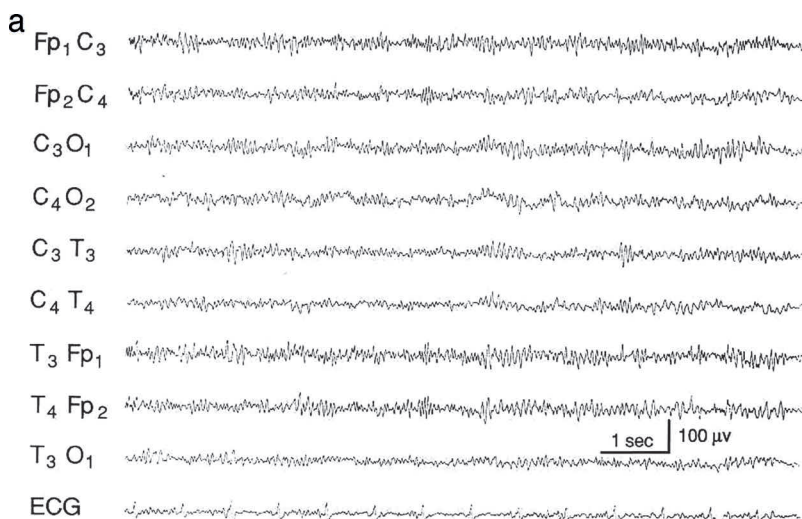
Artifacts are common during the wakeful EEG, and one of the first hurdles of EEG interpretation is distinguishing these from cerebral signal. Most notable is the presence of low-amplitude, high-frequency activity arising from scalp muscles, often frontally dominant but seen throughout the tracing. Rapid eye movements (REMs), resulting from saccades and spontaneous changes of gaze, may be seen as small, rapid deflections in frontal regions. Extremely large-voltage, diphasic potentials in frontal regions result from blinks. This occurs because the eye is a dipole, relatively positive at the corneal surface and negative at the retinal surface, and the eye moves characteristically upward during a blink according to Bell phenomenon, resulting in a moving charge and potential change. Since the positivity of the cornea rotates upward toward frontal electrode sites, a transient positivity, then negativity is recorded there. Another common artifact during the waking EEG is caused by swallowing and the related movement of the tongue, which similar to the eye is a dipole and causes a slow potential with superimposed muscle artifact. See Appendix 4 for representative common EEG artifacts seen during wakefulness.

### The Posterior Dominant Rhythm

Healthy adults typically manifest relatively low-amplitude, mixed-frequency background rhythms, also termed *desynchronized*. When the patient is relaxed with eyes closed, the background is usually characterized by the posteriorly dominant alpha rhythm, also known simply as the posterior dominant rhythm. (Figure 7). The alpha rhythm, or alpha, is attenuated in amplitude and frequency and often completely ablated by eye opening. Alpha amplitude is usually highly symmetrical, although it may be of somewhat higher amplitude over the right than left posterior head regions (greater than 50% amplitude asymmetry is considered abnormal, with the abnormality usually on the side of the lower amplitude). Alpha frequency normally remains symmetrical, so if one side is slower than the other, an abnormality of cerebral functioning exists on the slower side. The alpha generator is thought to be located within the occipital lobes. While some normal patients lack well-formed alpha activity, the frequency, symmetry, and reactivity of alpha merits special attention and comment in any EEG report. There are several variants of the alpha rhythm, and they include temporal alpha, characterized by independent alpha activity over the temporal regions seen in older patients, frontal alpha, consisting of alpha activity over the anterior head regions, which may



**Figure 7.** The posterior dominant alpha rhythm. The normal background EEG during wakefulness contains posteriorly dominant, symmetrical, and reactive alpha rhythm. Alpha activity is more prominent in amplitude during relaxed, eyes-closed wakefulness and demonstrates reactivity by decreasing in amplitude and presence during eye opening and mental alerting. Copyright 2013. Mayo Foundation for Medical Education and Research. All rights reserved. Figure courtesy of Erik K. St. Louis, MD.

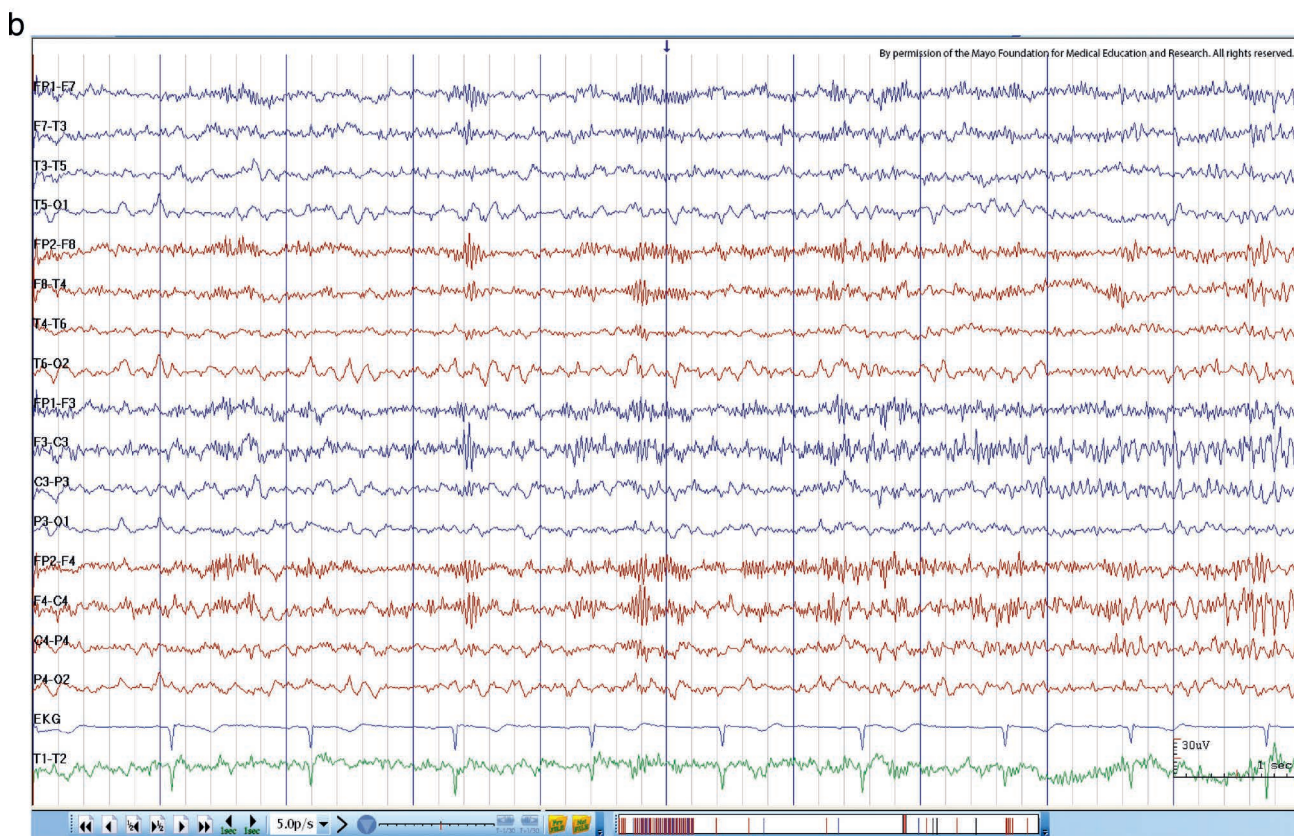


be related to drugs, anesthesia, or following arousal from sleep (Note: When invariant and unreactive to any stimuli in a comatose patient, this variant is pathological and represents an alpha coma pattern.) or paradoxical alpha, which is a return of alpha activity with an alerting stimulus or eye opening.

*Other Features of the Normal Waking Background*

The remainder of the normal waking EEG is usually composed of lower amplitude beta frequencies in the fronto-centro-temporal head regions (see Figure 8). Beta frequencies are generally over 13 Hz and of low

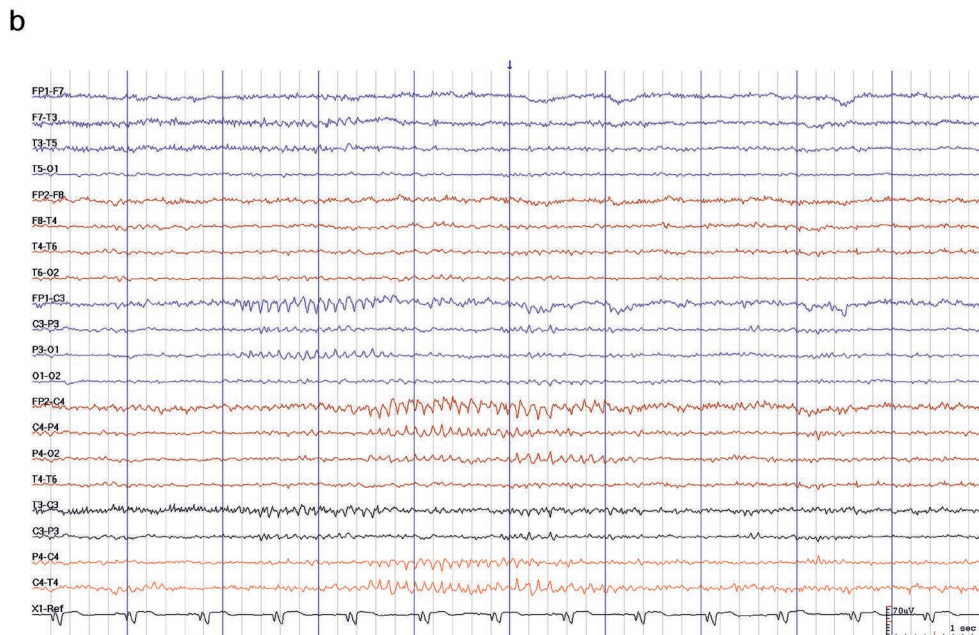
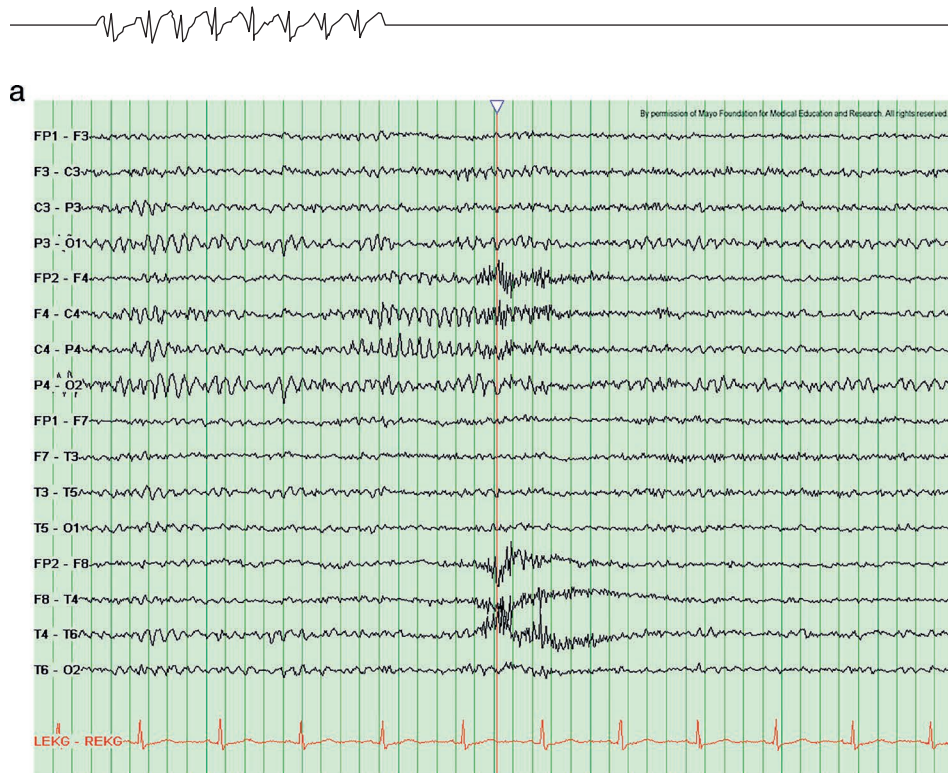By permission of Mayo Foundation for Medical Education and Research. All rights reserved.



**Figure 8.** Excess beta activity. In example (a), generalized excess beta activity is shown in a modified alternating bipolar montage. In example (b), a very prominent frontally maximal beta rhythm is noted in this slightly drowsy 32-year-old woman, very likely as a result of recent lorazepam ingestion for anxiety. Copyright 2013. Mayo Foundation for Medical Education and Research. All rights reserved.

(a) Generalized excess beta. Figure courtesy of Jeffrey W. Britton, MD.

(b) Frontally predominant excess beta activity. Figure courtesy of Jennifer L. Hopp, MD, University of Maryland.v



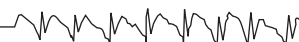**Figure 9.** Mu rhythms. (a) A prominent Mu rhythm is seen over the right central region. Note the arciform waves of approximate alpha-range frequency of 8 to 12 Hz. Mu is reactive to movement or the thought of movement, unlike alpha activity, which is reactive instead to eye opening. Longitudinal bipolar montage. (b) Trains of asynchronous mu are seen over either central region during drowsiness. Copyright 2013. Mayo Foundation for Medical Education and Research. All rights reserved.

(a) Right central mu activity. Figure courtesy of Jeffrey W. Britton, MD.

(b) Asynchronous mu, bilateral central regions. Courtesy Dr. Jennifer L. Hopp, MD, University of Maryland.

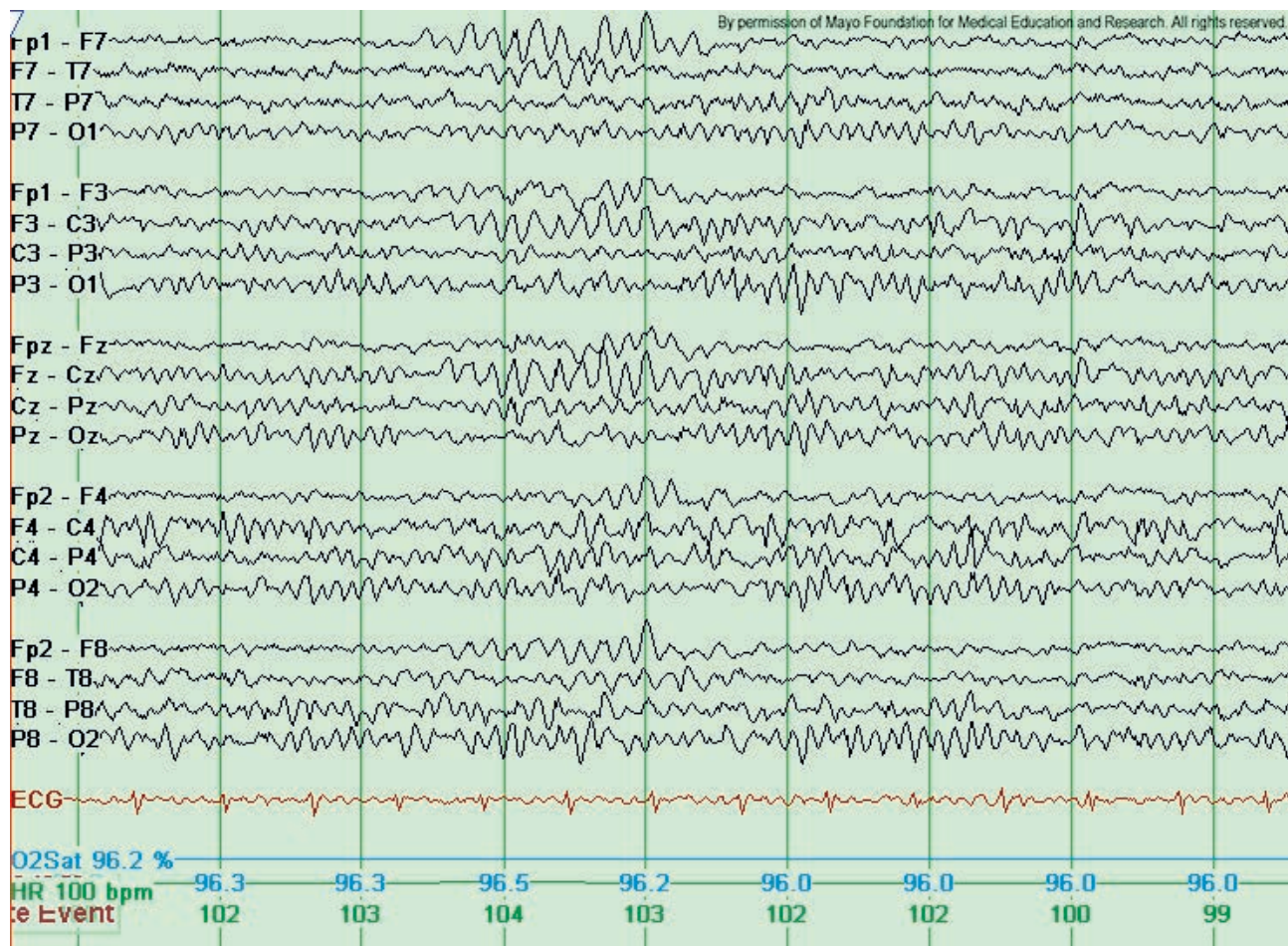
amplitude. Beta is often enhanced during drowsiness, seen in a precentral distribution, and felt to be related to the functions of the sensorimotor cortex. When beta is prominent in amplitude, either in the frontal or generalized distribution, it is likely a result of the use of sedating drugs such as benzodiazepines or barbiturates. In this sense, it is a mild abnormality of the background and often referred to as “excess beta” (Figure 8).

Sometimes, a prominent alpha-range frequency of 8 to 12 Hz is seen over the central head regions, termed the mu rhythm (Figure 9). Mu is seen in between 20 and 40 percent of normal adults, is characterized by arch-shaped (arciform) waves occurring either unilaterally or bilaterally over the central regions, and is prominent during drowsiness. Mu is unrelated to eye opening or closure and reacts to movement, somatosensory stimulus, or the thought of movement. It is thought to be generated in the rolandic region of the frontal and parietal lobes in relation to functions of the sensorimotor cortices. The technologist should instruct the patient to wiggle their thumb to distinguish mu from alpha; mu will attenuate, whereas alpha is unchanged, by movement or intention to move.



*Slower Background Rhythms*

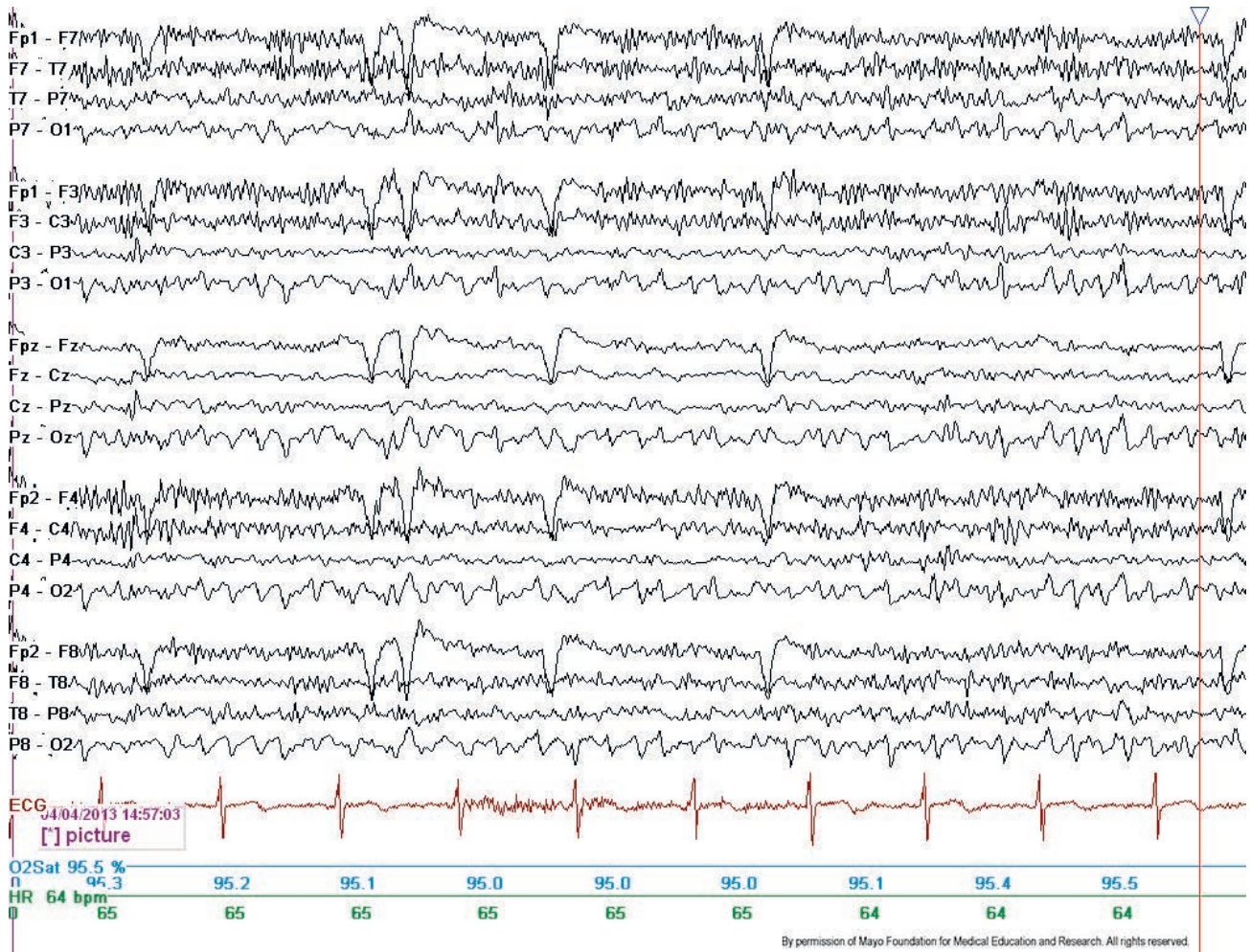
Occasional slower theta (4–7 Hz) or even delta (1–3 Hz) frequencies transiently may be seen during normal wakefulness, but usually these slower activities only become prominent during drowsiness (Figure 10). In children, adolescents, young adults, and some elderly individuals, it is frequent and entirely normal for there to be “drowsy bursts” of generalized theta–delta frequency activity on the EEG (Figure 10). Intermittent or pervasive, focal or generalized, theta or delta frequency, range slowing of the background in a vigilant adult is abnormal and indicates either focal, regional, or generalized cerebral dysfunction (see section on Abnormal Background for further discussion on the significance of background slowing and for example Figures).



**Figure 10.** Background in drowsiness. Normal EEG during drowsiness in an 8-year-old child, illustrating background theta and delta frequency slowing and a “drowsy burst” of frontally dominant theta activity in the third and fourth seconds. Such findings are normal in this age group and should not be overinterpreted as a sign of encephalopathy or seizure disorder. Longitudinal bipolar montage. Copyright 2013. Mayo Foundation for Medical Education and Research. All rights reserved. Figure courtesy of Jeffrey W. Britton, MD.



An additional normal background phenomenon is the occurrence of lambda waves (Figure 11). Lambda is elicited by pattern viewing, having the configuration of the Greek letter lambda ( $\Lambda$ ) and is a surface positive, occipitally predominant waveform.

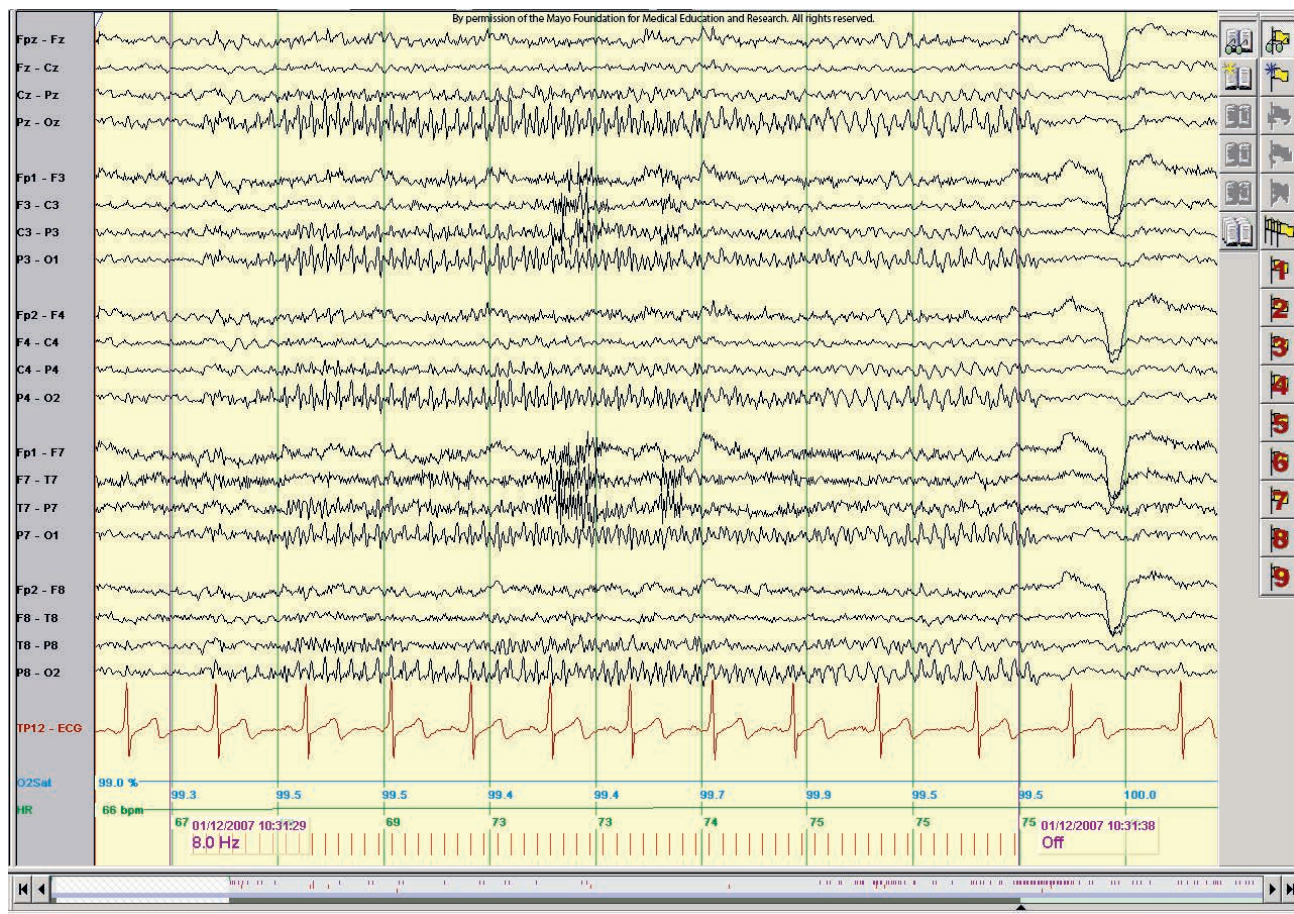


**Figure 11.** Lambda waves. Lambda waves over posterior head regions, elicited by complex pattern viewing. Note the surface positive waveforms over both occipital regions. Longitudinal bipolar montage. Copyright 2013. Mayo Foundation for Medical Education and Research. All rights reserved. Figure courtesy of Jeffrey W. Britton, MD.

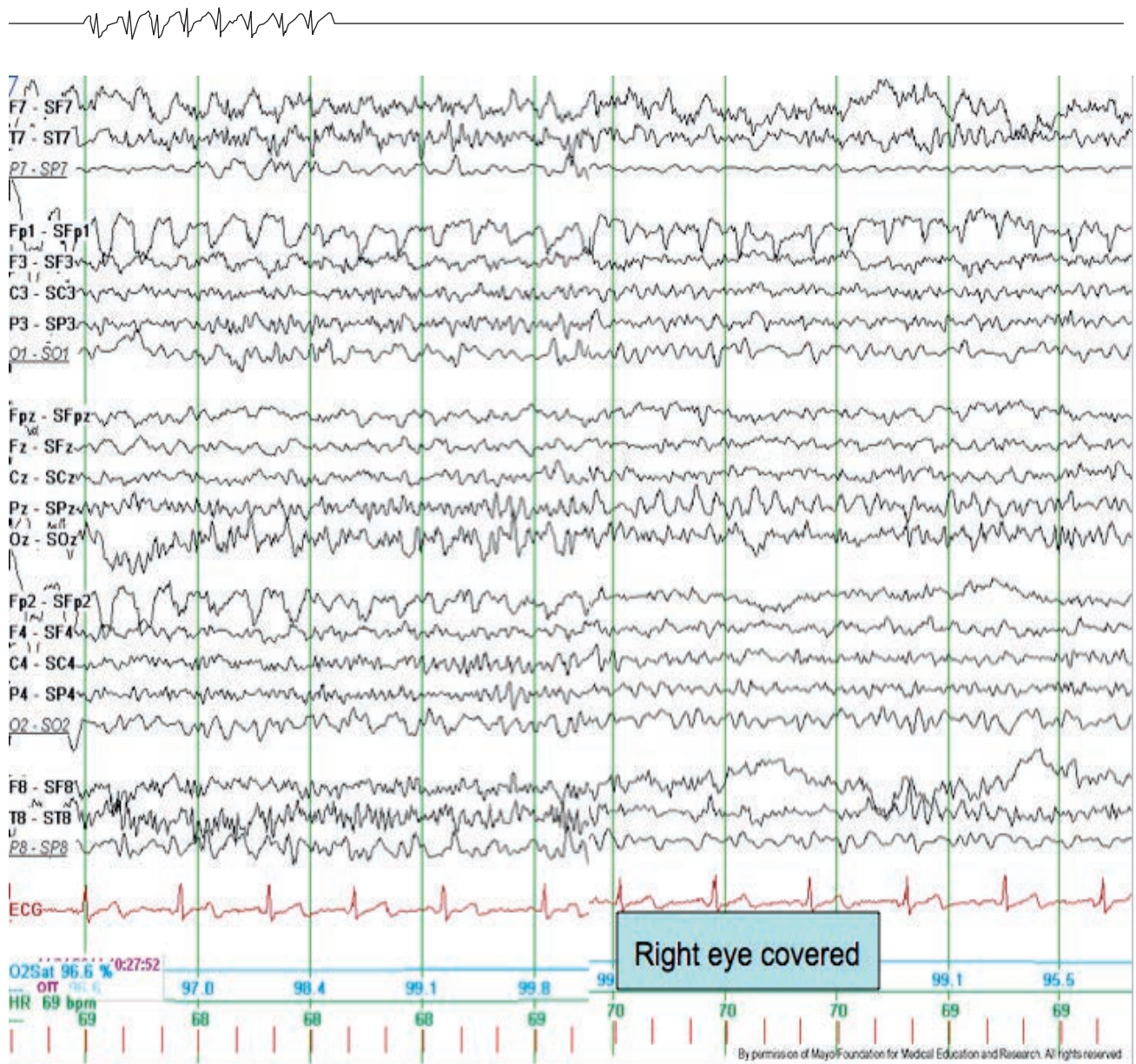


**Provocation Techniques**

During the wakeful EEG recording, provocative maneuvers are usually administered in an effort to produce possible background or epileptiform abnormalities, including hyperventilation and photic stimulation. In adults, hyperventilation often produces minimal change, but in children, adolescents, and young adults, a prominent high-amplitude or hypersynchronous background-slowning phenomena termed “buildup” is often seen and is considered a normal finding in these age groups. The expected normal findings during photic stimulation are either no change in the background, or a symmetrical “photic driving” response, consisting of entrainment of the background alpha rhythm to the same or a harmonic frequency variant of the administered flashing lights (see Figure 12, below). A similar finding is sometimes seen over the frontal head regions induced by photic stimulation, but this represents instead evoked responses from retinal neurons, the electroretinogram (ERG), which is distinguished by its purely anterior (rather than posteriorly predominant photic stimulation) response (see Figure 13, below). See the section on Abnormal Background for further discussion concerning typical abnormalities induced by activating procedures during EEG.



**Figure 12.** Photic stimulation. Photic stimulation responses include either no change in the background or, as shown below, symmetrical entrainment of the background posterior rhythms over the occipital region. Longitudinal bipolar montage. Photic stimulus marked by gray ticks at bottom of figure. Copyright 2013. Mayo Foundation for Medical Education and Research. All rights reserved. Figure courtesy of Jeffrey W. Britton, MD.



**Figure 13.** Photic stimulation may also induce an anteriorly dominant frequency in the EEG, but this emanates from evoked retinal neuronal responses, the ERG. The ERG artifact is caused by retinal depolarization induced by photic stimulus shown in FP1 and FP2 derivations on a longitudinal Laplacian montage. The ocular source of waveforms was established by covering the right eye, which blocked stimulation of the right retina eliminating ERG in the FP2 derivation. Copyright 2013. Mayo Foundation for Medical Education and Research. All rights reserved. Figure courtesy of Jeffrey W. Britton, MD.

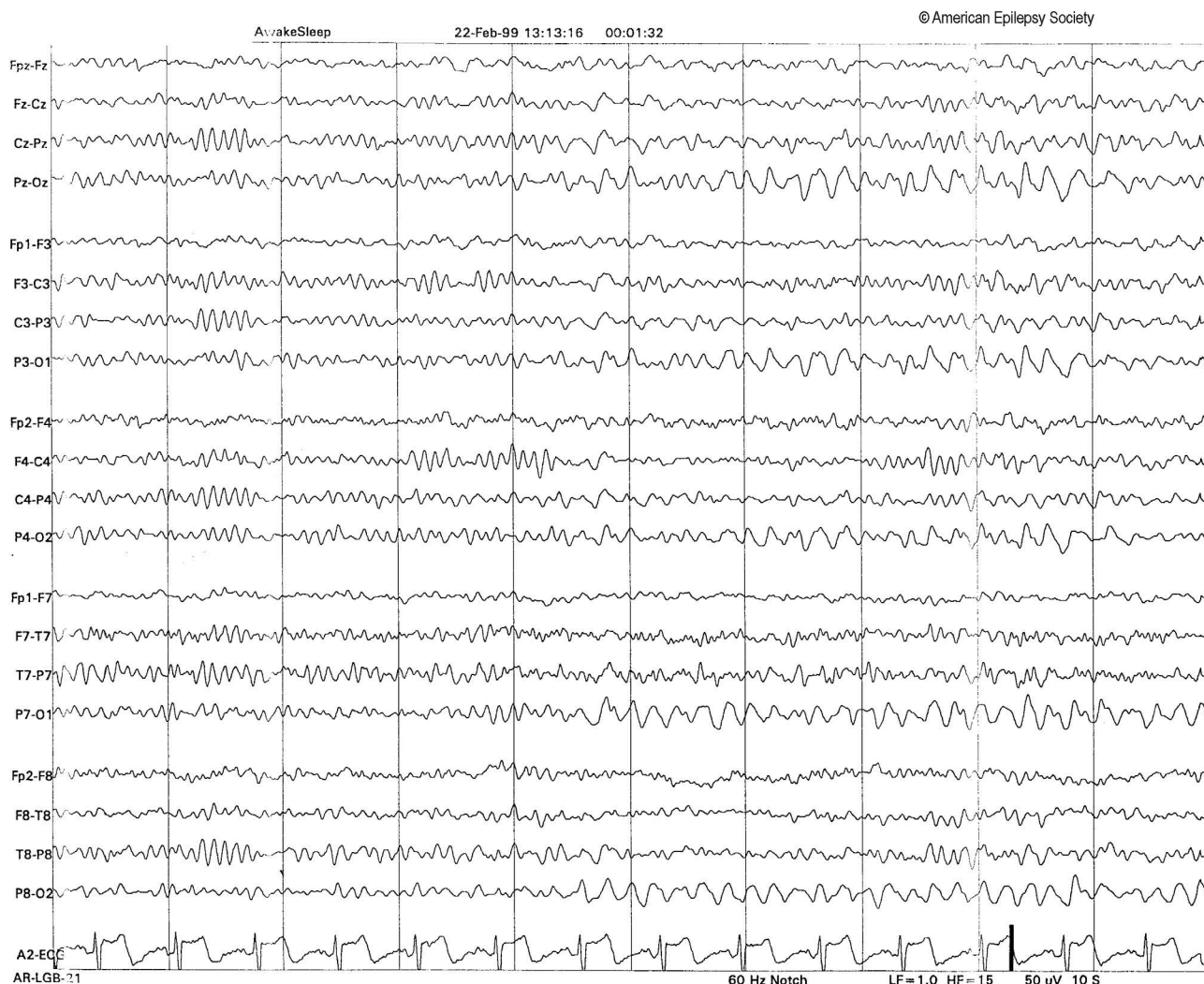




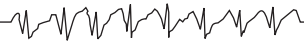
**Drowsiness and Sleep**

During drowsiness, the first discernible change is gradual loss of the frequent muscle and movement artifacts and reduction of blinks and rapid lateral eye movements. Instead, a very slow frequency of 0.25 to 1.0 Hz in the frontal and lateral frontal channels emerges. These are slow rolling eye movements, or SEMS (slow eye movements of sleep), which begin in drowsiness and persist through stage 1 sleep, until gradually being lost with deeper stages of non-rapid eye movement (NREM) sleep. The EEG during drowsiness contains slower, synchronous frequencies of theta and delta throughout the background (see Figure 14).

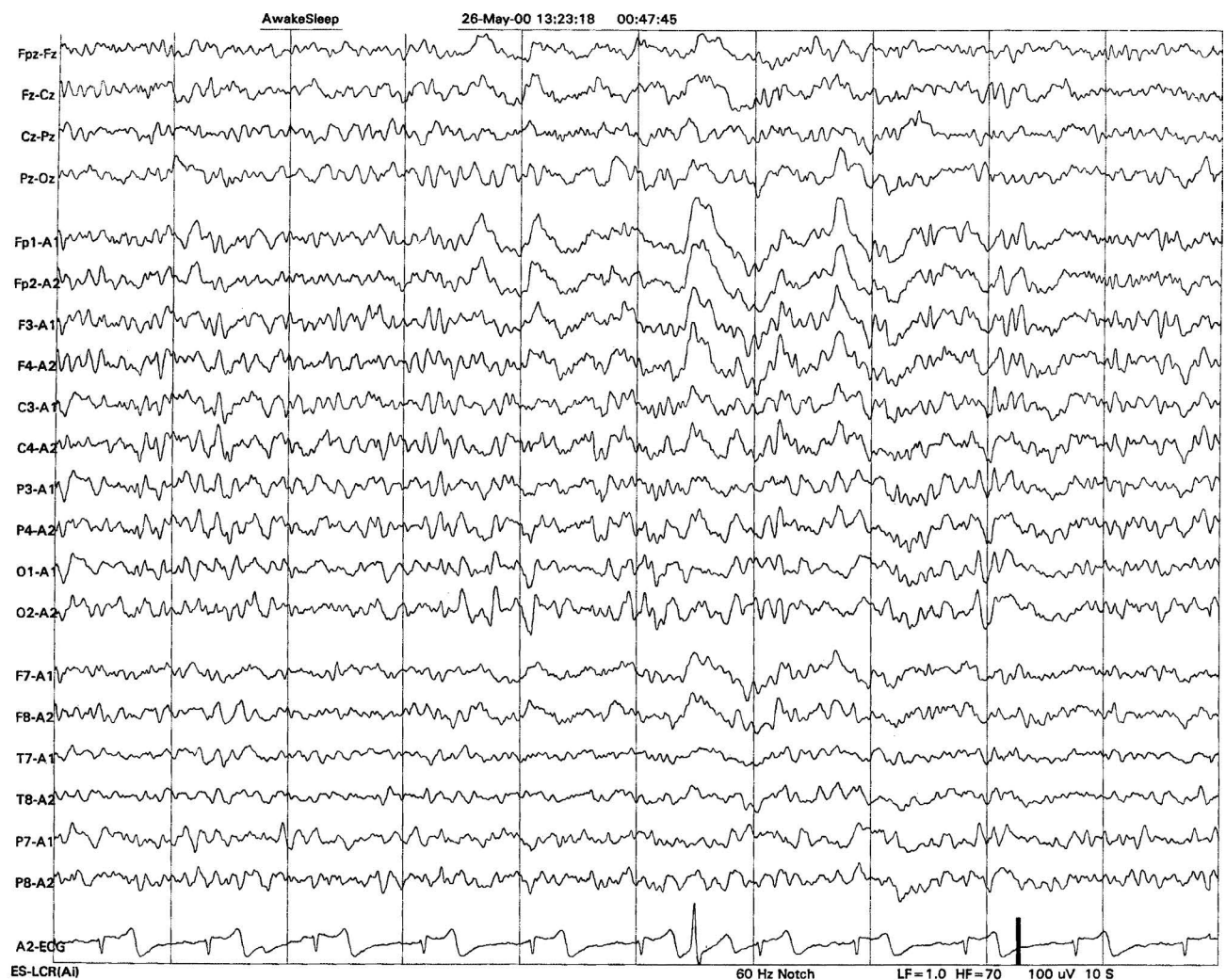
Defining features of sleep stages are listed in Table 1. NREM sleep is classified as light NREM (stages 1–2; now termed N1–2) and deeper slow wave sleep (SWS, formerly known as stages 3–4; N3–4), as well as REM sleep. Typically, approximately 75% of the night is spent in NREM sleep and up to 25% in REM sleep. Stage 1 (N1) sleep is contiguous with drowsiness and is characterized by SEMS and slower theta and delta EEG frequencies of 1 to 7 Hz, with less than 50% alpha frequency activity in a 30-second epoch. It is easily marked by the appearance of vertex waves (V-waves); sharply contoured, fronto-centrally predominant waves (Figure 15).



**Figure 14.** Example of drowsiness from a normal adult EEG recording. Note the prominent theta and delta activity, lack of eye movements or blinks, lack of muscle or movement artifact, and early suggestion of slow lateral rolling eye movements best seen in the F7 and F8 containing derivations. Copyright 2013. Mayo Foundation for Medical Education and Research. All rights reserved. Figure courtesy of Erik K. St. Louis, MD

**TABLE 1. Defining Features of Sleep Stages on the EEG**

State	Frequency, Hz	Amplitude	Feature(s)	Other
Awake	8–13	Low	Desynchronized	Blinks, swallowing, muscle
Drowsiness	3–7	Mixed	More synchronized, SEMS	Blinks, muscle drop out
Stage 1 (N1)	3–7	Mixed	V-waves, SEMS	Rare POSTS
Stage 2 (N2)	1–7	Moderate	Synchronized, K-complexes, spindles, POSTS	Delta power higher
SWS	1–5	High	Delta >20%	K-complexes, spindles, and POSTs recede
REM	4–8	Low	Desynchronized, REMs, sawtooth waves	

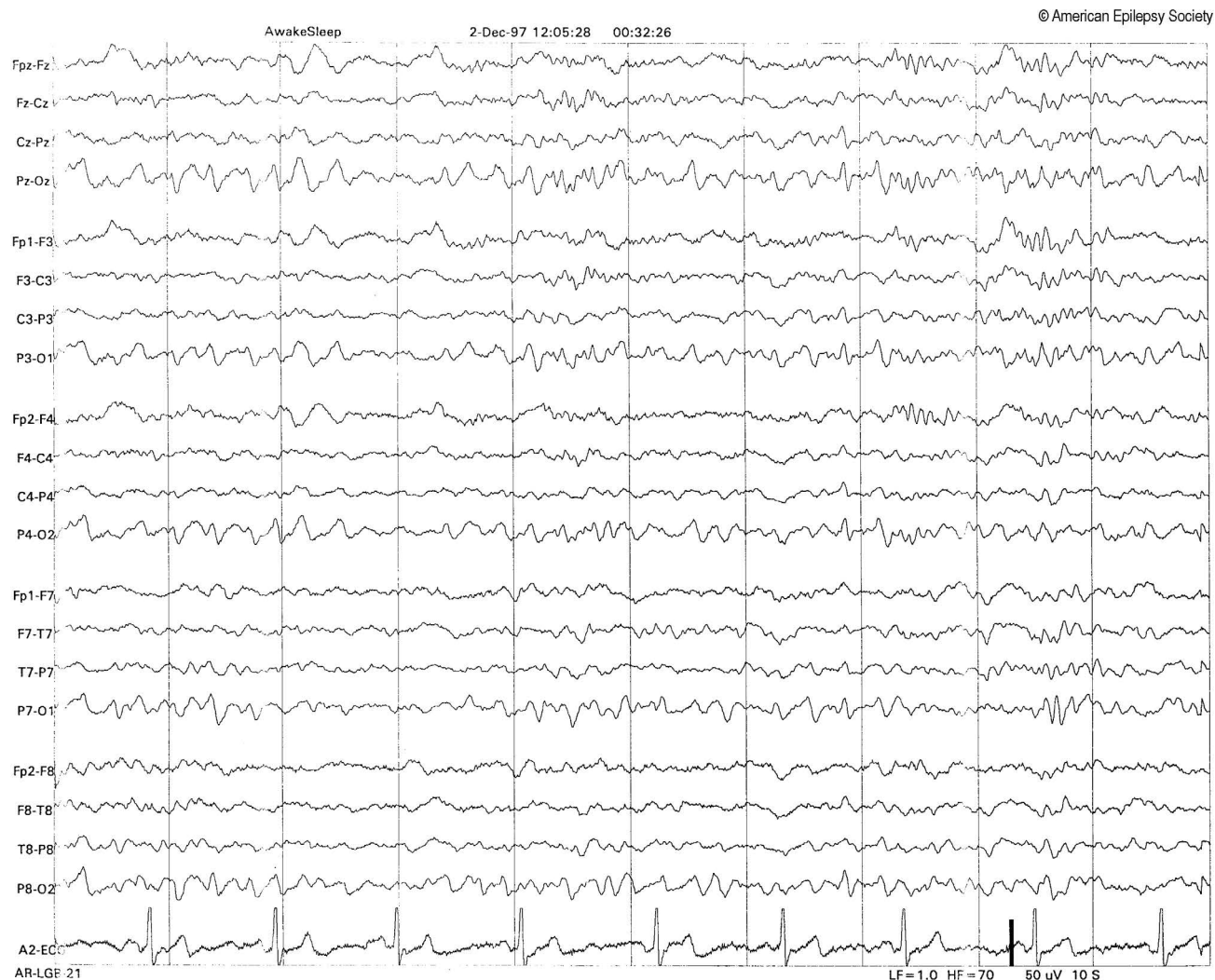

© American Epilepsy Society

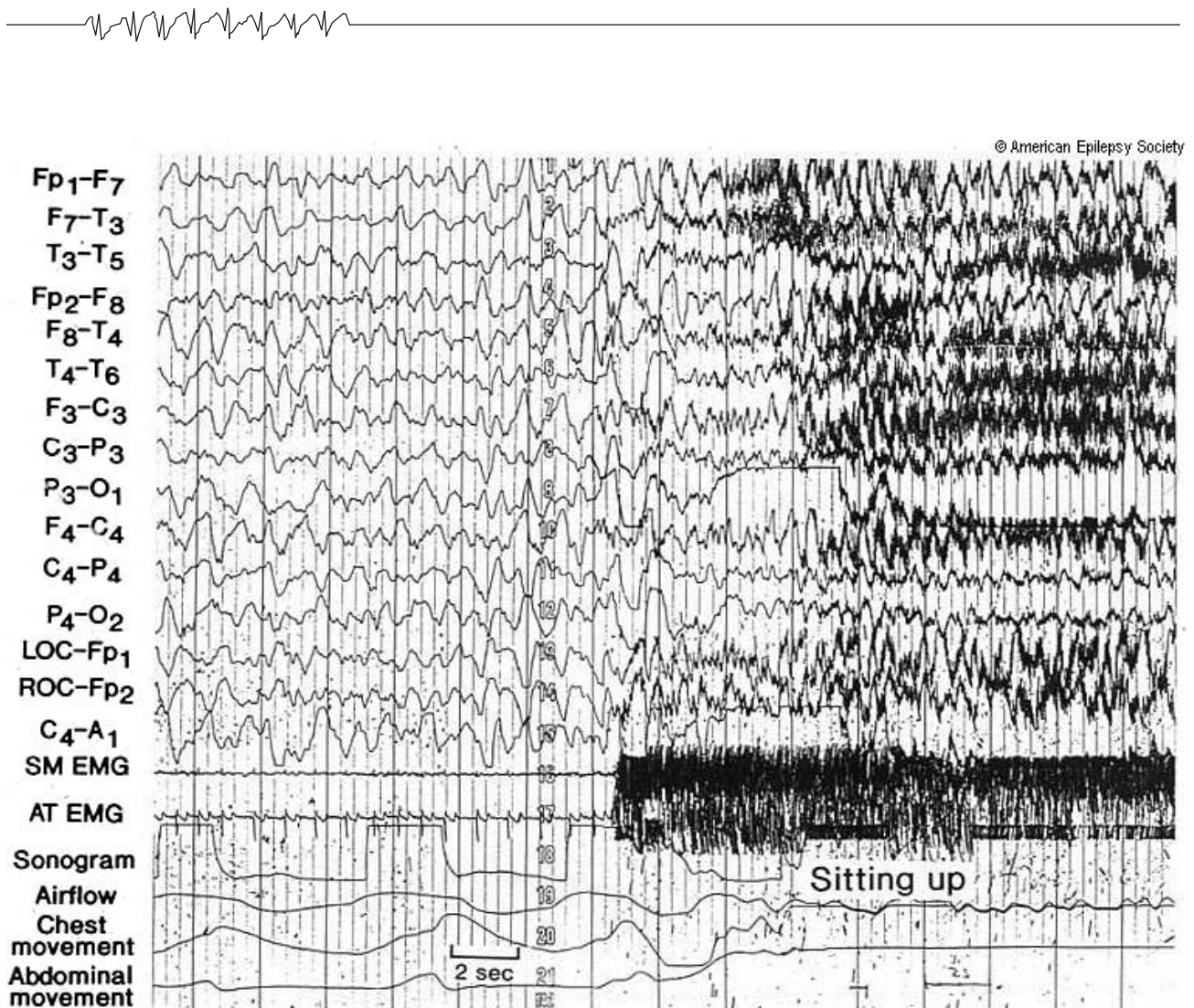
**Figure 15.** Stage 1 (N1) sleep. Characterized by slow rolling eye movement artifacts, and slower theta and some delta frequencies in the EEG background. V-waves (V) also typically occur. Copyright 2013. Mayo Foundation for Medical Education and Research. All rights reserved. Figure courtesy of Erik K. St. Louis, MD.



During stage 2 (N2) sleep, more delta frequency background begins to emerge, and the defining features of sleep spindles, K-complexes, and posterior occipital sharp transients of sleep (POSTS) are seen (Figures 16, 17). Sleep spindles are thought



**Figure 16.** Stage 2 (N2) sleep. Slower theta and some delta (by definition, less than 20% of background of delta range slowing) frequencies in the EEG background. K-complexes and sleep spindles are the hallmarks of N2 architecture. Copyright 2013. Mayo Foundation for Medical Education and Research. All rights reserved. Figure courtesy of Erik K. St. Louis, MD.



**Figure 17.** Slow wave sleep (N3) contains greater than 20% high-voltage ( $>75 \mu\text{V}$  crest to crest) delta frequencies and fewer K-complexes and spindles. The figure below was taken from a full EEG recording during a polysomnogram, since N3 sleep is typically not recorded during laboratory daytime recordings unless there has been substantial sleep deprivation preceding the study. Note the high-voltage delta activity in the first half of this 15-second epoch, followed by a spontaneous arousal. The event following is actually an NREM parasomnia (a confusional arousal) in which the patient sat up and stared around the room, appearing confused. The patient was later amnesic for the event. High-voltage delta activity can be seen persisting behind the muscle and movement artifact as the patient sits up, which is often seen in NREM arousal disorders. Copyright 2013. Mayo Foundation for Medical Education and Research. All rights reserved. Figure courtesy of Erik K. St. Louis, MD.



to reflect the synchronous activity mediated by thalamo-cortical neuronal networks. SWS (N3) has similar features, but less spindles, K-complexes, and POSTS are seen and even more delta frequency activity emerges (Figure 18).

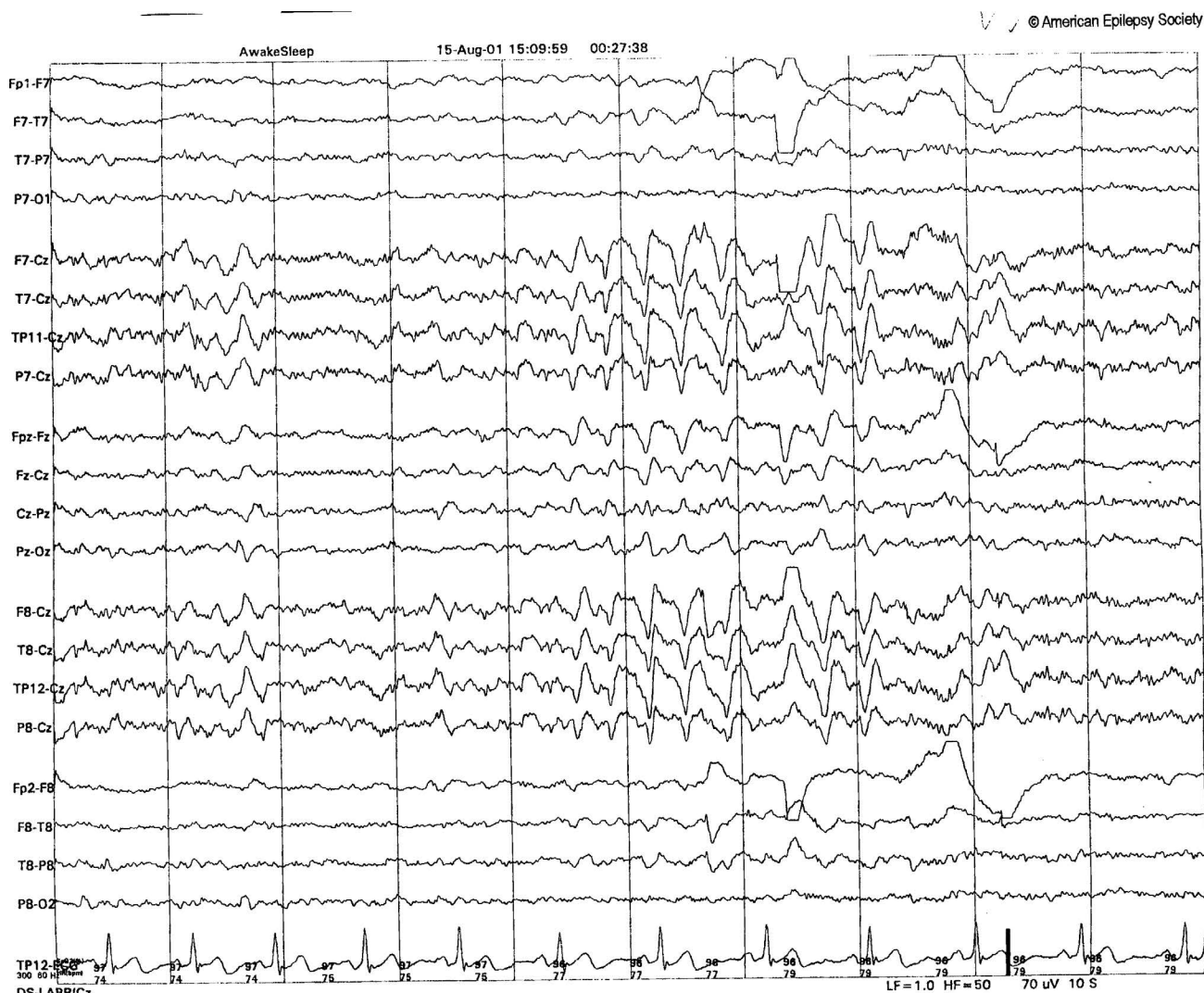
REM sleep was previously known as paradoxical sleep, because REM actually resembles the waking EEG more closely than NREM sleep, having a desynchronized, low-voltage background. There are also fronto-central, sharply contoured theta frequencies called sawtooth waves, as well as REM artifacts seen in lateral frontal sites (Figure 18). Proper sleep-staging criteria also require features of very low-voltage chin electromyography (EMG) and eye movements recorded by electrooculogram (EOG) channels, but these polysomnographic channels are not routinely recorded during outpatient EEGs.

**The Developmental EEG: Premature, Neonatal, Infant, and Children**

**Neonatal EEG**

The neonatal EEG has some very different clinical considerations for recording and interpretation. Understanding certain clinical details, such as the conceptional (aka conceptual) age (CA) and the clinical state of the recorded patient, is essential for interpretation of the neonatal EEG.

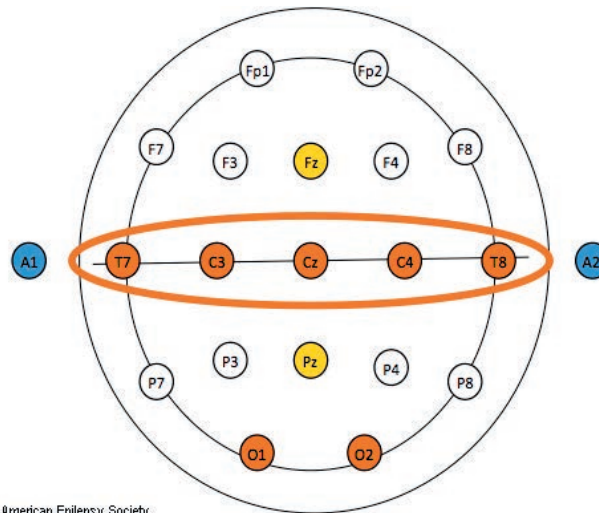
The indications for the conventional neonatal EEG include assessment of age and maturity; identification of neonatal seizures and neonatal status epilepticus; evaluation of neonatal encephalopathy and focal abnormalities; and assessment of response to treatment or to aid neurologic prognosis. The conventional neonatal EEG is the gold standard for the diagnosis and confirmation of neonatal seizures and neonatal encephalopathy.



**Figure 18.** REM sleep is characterized by a more typically wake-appearing, desynchronized, mixed-frequency background, which may contain alpha frequencies, characteristic centrally dominant sharply contoured sawtooth waves, and rapid eye movement artifacts in lateral frontal electrode sites. Copyright 2013. Mayo Foundation for Medical Education and Research. All rights reserved. Figure courtesy of Erik K. St. Louis, MD.



There are also several specific technical considerations for neonatal EEG, beginning with the montage and electrode placement. The neonatal montage is used from the time of birth until the baby reaches full-term age. In some centers, the neonatal montage is used until the baby is 46 to 48 weeks gestational age (GA) or until sleep spindles are seen in the recording (around 46–48 weeks) (see Figure 19).



© American Epilepsy Society

**Figure 19.** The 10-20 System electrode placements modified for neonates. Most of the neonatal EEG activity is found in the central regions of the brain, therefore the neonatal montage should have sufficient coverage of the centro-temporal regions. Figure courtesy of Elia M. Pestana-Knight, MD, Cleveland Clinic Foundation.

A study from Tekgul and colleagues compared the sensitivity and specificity of the reduced (neonatal) montage versus a full 10-20 montage in neonates (4). They found that the neonatal montage had a sensitivity of 96.8% and specificity of 100%. An electrode cap is used in some institutions in which there is no 24-hour EEG technologist coverage, since a cap can be placed by nurses, residents, or fellows. Electrocaps are color coded and can be adjusted to fit different head sizes. Other polygraphic parameters or extracerebral channels that are included in the conventional neonatal EEG are the electrooculogram (EOC), electromyogram (EMG), electrocardiogram (ECG), pneumograph, and video. For the EOC, two EOC electrodes are placed near the outer canthus of the eyes, one above the eye and the other below the eye. EOC allows for identification of different behavioral stages, in particular awake and active sleep stages, where eye movements are seen. For EMG recordings, the EMG electrode is placed under the chin. EMG allows for the identification of different behavioral stages (awake and active sleep), since active sleep is often associated with relative muscle atonia.

ECG leads are located on the chest to record variations of the heart rate and allow distinction of ECG artifact on the EEG. A pneumograph or respiratory belt also allows for the identification of behavioral stages. Synchronized video recording should also be used when possible, although a well-trained EEG technician or nurse annotating the EEG record can help substitute for tracking behaviors of the patient or environmental issues that may generate EEG artifacts, such as patting or nurse manipulation; this is crucial since sometimes movements such as these may generate artifacts that almost precisely mimic seizure patterns on the neonatal EEG.

Newborns, in particular preterm babies, have very thin and sensitive skin. Even when the recommendation is to keep the skin impedance (a measure of the quality of the connection between the skin and the recording electrode) at around 5 k $\Omega$ , an impedance of approximately 10 k $\Omega$  also may produce a technically adequate recording, while avoiding severe skin abrasions. The low-frequency filter is set lower in neonatal recordings than for EEG recordings in older children and adults to allow for the recording of slower frequencies at 0.005 to 0.01 Hz or 0.5 Hz, and the high-frequency filter setting is similar to adult recordings at 35 to 70 Hz.

Neonatal EEG recording should last at least 2 to 3 hours to capture awake and all sleep stages. Neonatal EEG is typically displayed with a longer time interval on the screen (a faster “paper speed” of 15 mm/s) producing a more compressed-appearing recording. This compressed screen allows for better display of very slow activity, asymmetries, and asynchronies that are crucial to evaluate in neonatal recordings.

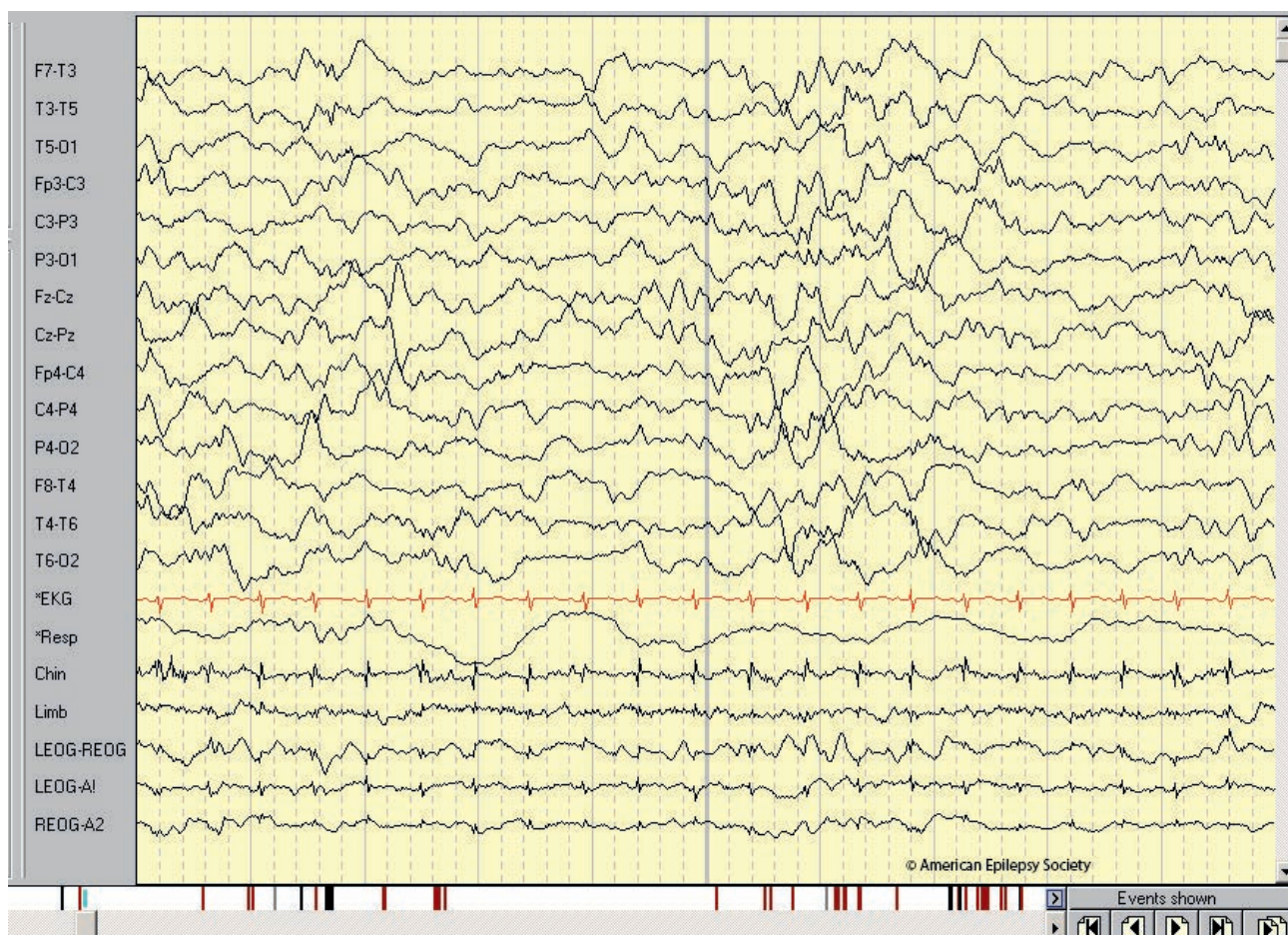


Neonatal montages have some variations between institutions. The main variations are where the different channels are located on recording montages and how they are displayed on the screen or page (see Figure 20 for a typical neonatal montage display).

To provide an accurate interpretation of the neonatal EEG, it is important to know the conceptional age (aka conceptual age) (CA) of the baby, the medications the baby is taking at the time of the recording, the different behavioral states of the baby, and any pertinent environmental changes. The CA is calculated by adding the estimated GA and the legal or chronologic age of the patient following birth. An example is a 4-week-old baby born at 30 weeks GA would have a CA of 34 weeks. Taking into account the CA, a neonate is a newborn infant with age <4 weeks. The definitions of preterm, near-term, and term are also important to become familiar with for neonatal EEG interpretation. A neonate is a newborn baby less than 4 weeks of age. A preterm baby has a CA between 24 and 34 weeks. Near-term babies have a CA between 34 and 36 weeks, while a term baby has a CA of 37 weeks and above.

Some medications and cooling therapy decrease the voltage of the neonatal EEG, so it is very important to know what medications and therapies are being given to the baby at the time of the EEG recording. Morphine, barbiturates, benzodiazepines, and other antiepileptic drugs decrease the voltage of the neonatal EEG. Head cooling and total body cooling also reduce the voltage of the neonatal EEG.

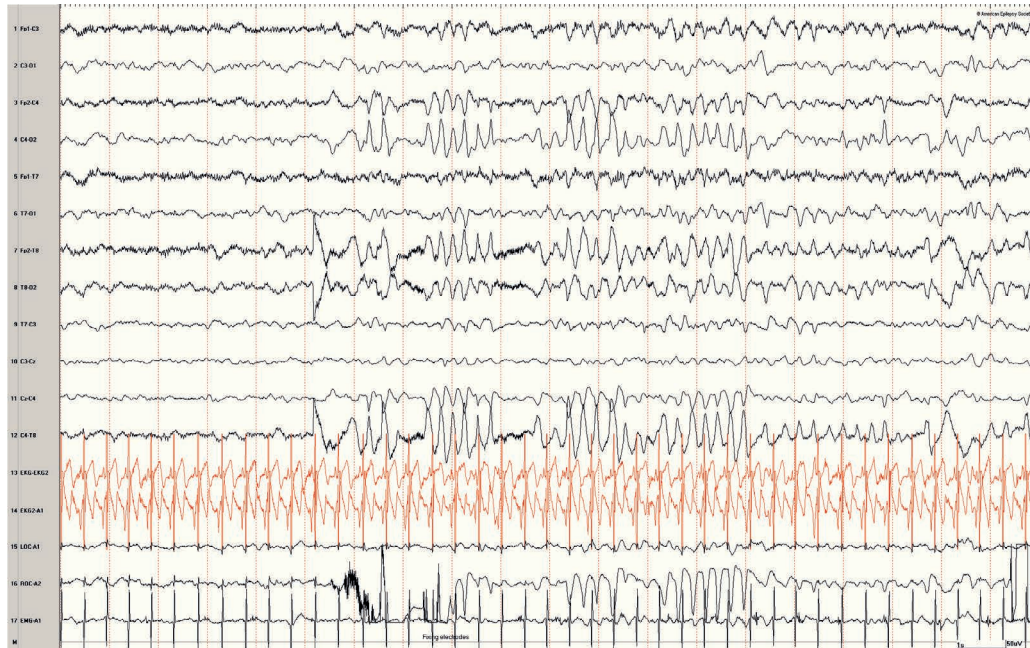
Technician annotations regarding the different behavioral states assist significantly in the interpretation of the neonatal EEG. Neonatal EEG recordings have clear differences during awake and sleep states, and within sleep stages. In general, neonates when awake have eyes open, whereas when they sleep, they have eyes closed. Regularity of respirations and eye movements help to differentiate between active sleep (REMs and irregular respirations) and quiet sleep (no REMs and regular respirations).



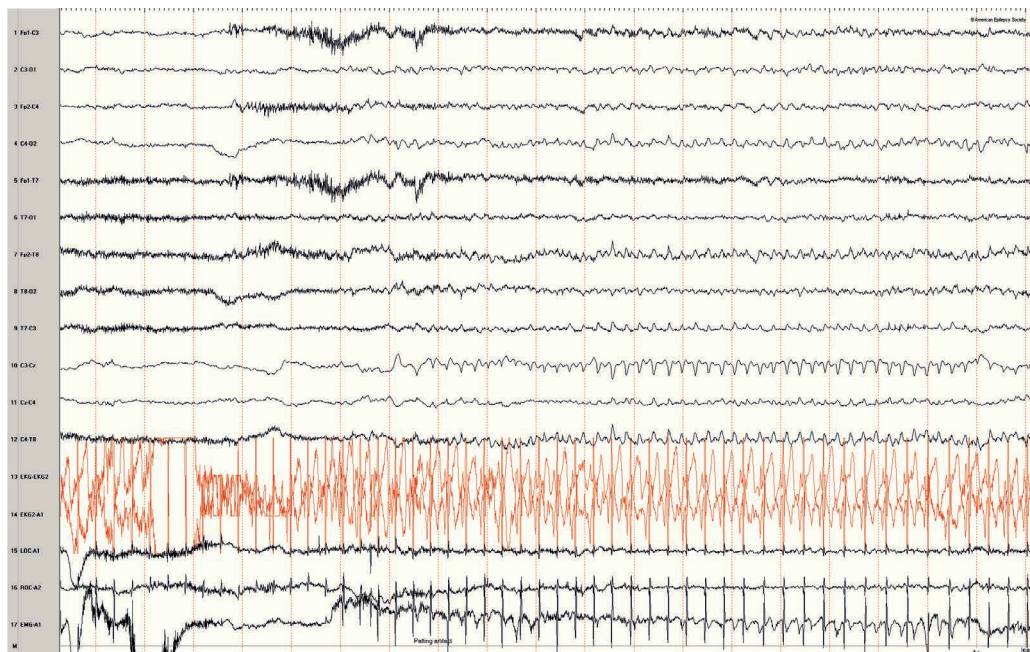
**Figure 20.** Typical neonatal montage. Neonatal montages have some variations from institution to institution. The main variations are where the different channels are located. In this sample, the vertex electrodes are in the middle of the EEG trace, and the additional electrodes (EKG, respiratory belt, EMG, EOG) are placed at the bottom. Also this recording has EMG electrodes at the chin and limb. Displayed 10 seconds per screen or 30 mm/s. Figure courtesy of Elia M. Pestana-Knight, MD, Cleveland Clinic Foundation.



Sources of artifacts should also be noted by the technologist. Sources of artifacts in the neonatal EEG are ventilators, incubators, lines and drips, and feeding. Loud noises, flashes of light, and nursing or parental care can also be sources of artifacts and should be noted. These factors all produce transient attenuation of the neonatal EEG background as seen with arousals. Some artifacts can be produced in the EEG trace when EEG technicians are fixing the electrodes (Figure 21). These artifacts can be mistaken as sharp waves or even seizures. The same is true for patting artifact, that typically has a variable frequency from beginning to end and can resemble an ictal pattern (Figure 22).



**Figure 21.** Neonatal EEG artifacts from technician fixing electrodes. This sample shows some artifacts (channels 3, 4, 7, 8, 11, and 12) produced by fixing the electrodes. Figure courtesy of Elia M. Pestana-Knight, MD, Cleveland Clinic Foundation.



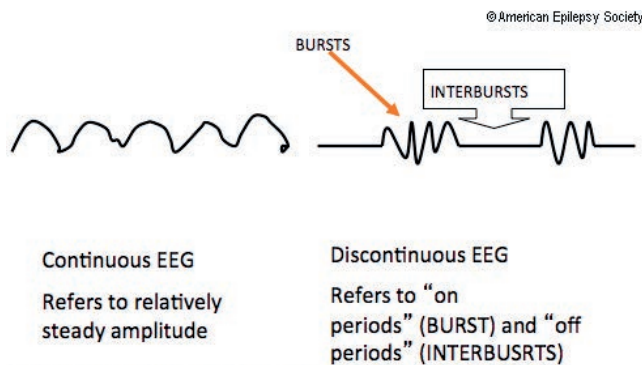
**Figure 22.** Patting artifact. This sample shows a widespread rhythmic artifact produced by patting the baby. Figure courtesy of Elia M. Pestana-Knight, MD, Cleveland Clinic Foundation.





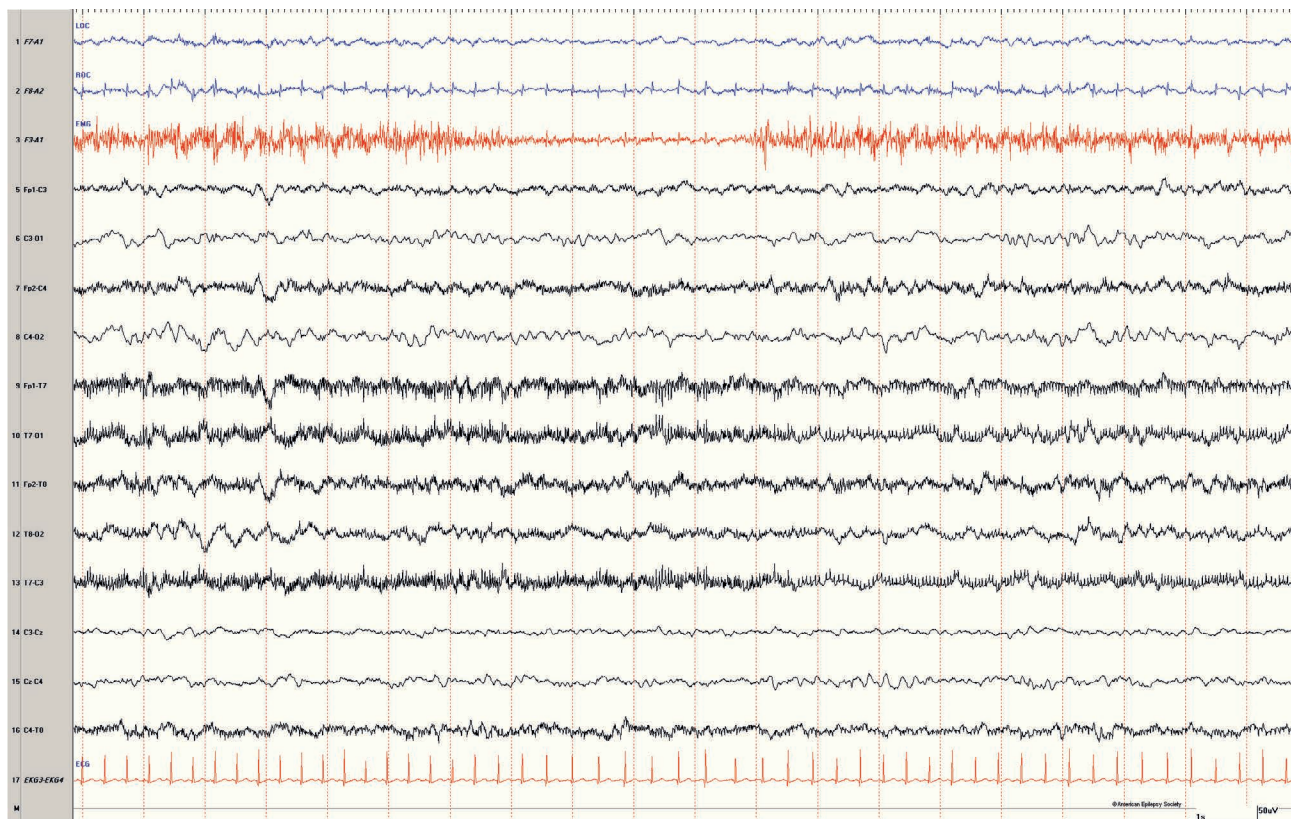
Similar to adult EEG, an orderly approach to visual analysis is necessary to effectively interpret neonatal EEG. The basic organization of the background rhythm should include an inspection of the EEG continuity and discontinuity, symmetry, synchrony, amplitude, reactivity, and morphology and composition of graphoelements.

Continuity in neonatal EEG refers to an EEG tracing with relatively constant and consistent amplitude (Figures 23, 24). Discontinuity in neonatal EEG refers to periods of relatively higher amplitude bursts that alternate with periods of lower amplitude,



**Interburst interval (IBI):** discontinuous portion of the EEG

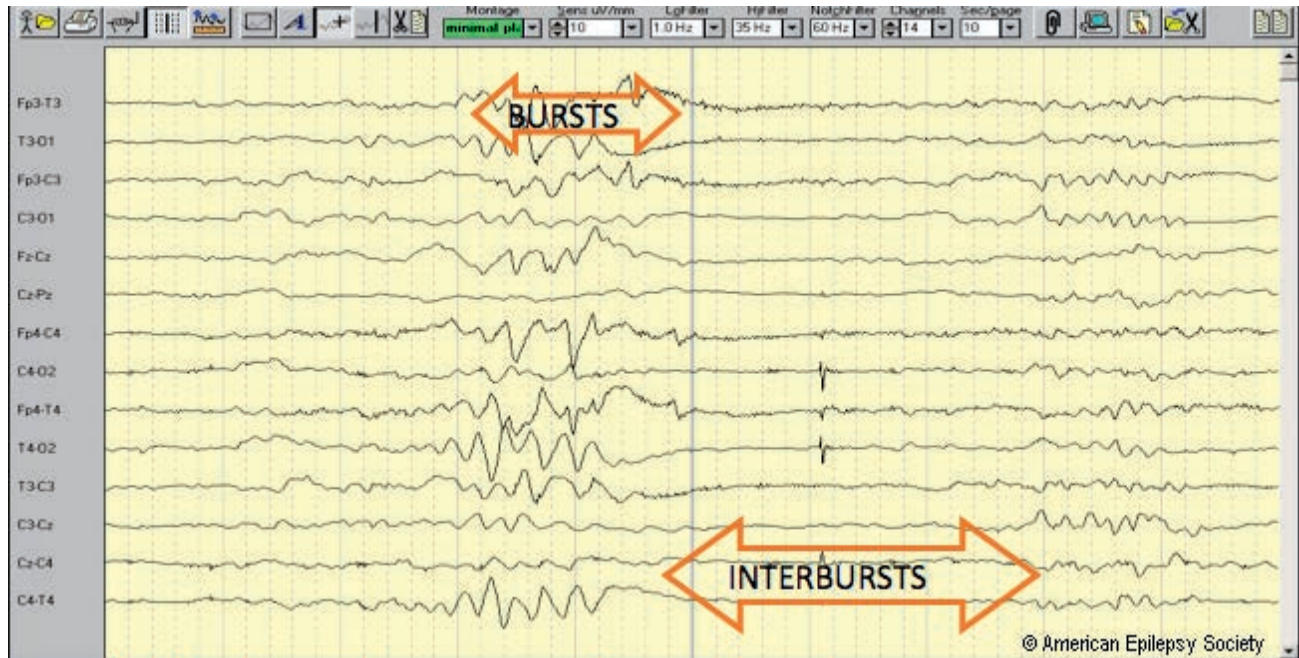
**Figure 23.** Continuity of the neonatal EEG. Continuity in neonatal EEG refers to a trace with relatively steady amplitude. Discontinuity in neonatal EEG refers to periods of relatively higher amplitude or bursts that alternate with periods of lower amplitude or interbursts. Figure courtesy of Elia M. Pestana-Knight, MD, Cleveland Clinic Foundation.



**Figure 24.** Continuous neonatal EEG. Continuity in neonatal EEG refers to a trace with a steady amplitude. This sample shows a continuous EEG. Figure courtesy of Elia M. Pestana-Knight, MD, Cleveland Clinic Foundation.



or interbursts (Figures 23, 25). The background evolves through different states in neonates with CA between 24 and 46 weeks, as shown in Table 2. Between CA 24 and 29 weeks, the EEG appears very similar in different states, and there is no reactivity to stimulation. The EEG is discontinuous but synchronous, and interburst intervals (IBI) are between 6 and 12 seconds with ampli-



**Figure 25.** Discontinuous neonatal EEG. Discontinuity in neonatal EEG refers to periods of relatively higher amplitude or bursts that alternate with periods of lower amplitude or interbursts. This sample shows a normal 27-week CA infant with a discontinuous EEG, with interbursts seen in the first 3 seconds and in seconds 6 to 8 and 10. Bursts are seen in seconds 2 and 3 and second 9. Figure courtesy of Elia M. Pestana-Knight, MD, Cleveland Clinic Foundation.

**Table 2. Neonatal EEG Background Evolution in Different Behavioral States\***

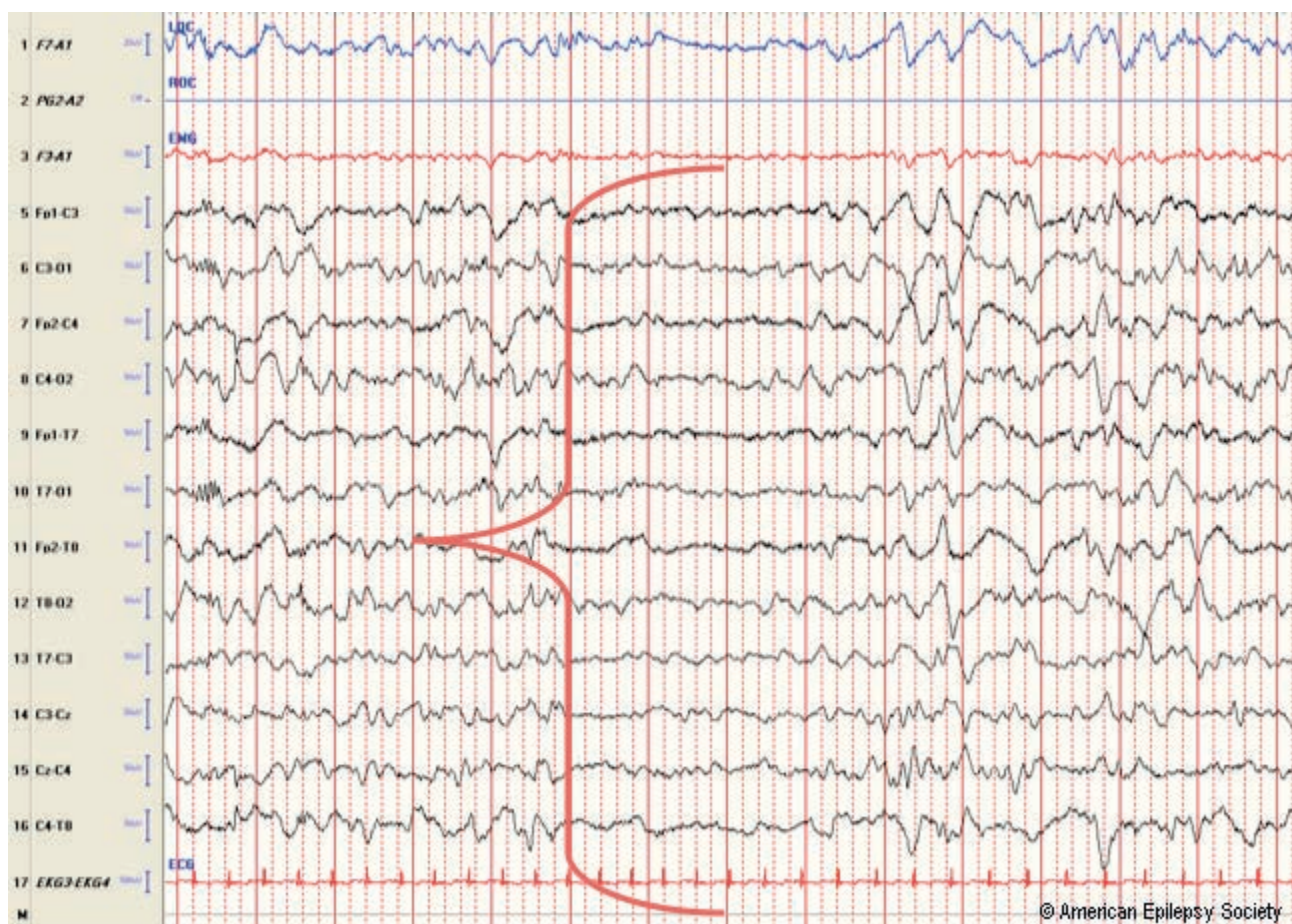
\*This table shows the background evolution of different states in neonates with CA 24 to 46 weeks. Between CA 24 and 29 weeks, the EEG looks very similar in the different states, and there is no reactivity on stimulation, the EEG is discontinuous but synchronous and in the IBI are between 6 and 12 seconds with amplitude <2  $\mu$ V. Between CA 30 and 34 weeks, the EEG has longer periods of continuity but is still discontinuous and becomes somewhat reactive with stimulation. The EEG looks similar during awake and active sleep. Quiet sleep is characterized by periods of discontinuity that are known as tracé discontinu. EEG is synchronous in around 70 to 80 percent of the recording. From this age onward, the IBI intervals will become progressively shorter, and the amplitude of the IBI will progressively increase until the EEG becomes completely continuous around 44 weeks CA. Between CA 35 and 36 weeks, there is clear distinction between awake and active sleep states. The EEG is more continuous in both states (activité moyenne) but remains discontinuous during quiet sleep (tracé alternant owing to alternating periods of high-voltage burst intervals and low-amplitude IBI). EEG is clearly reactive with voltage flattening and increases continuity with stimulation during quiet sleep. EEG is more synchronous (~85%). Between 37 and 40 weeks CA, the EEG is continuous and similar during awake and active sleep states. During quiet sleep, there is tracé alternant with some periods of continuous slow wave sleep. EEG is completely synchronous and reactive to internal or external stimuli. Between CA 40 and 44 weeks, the EEG is continuous during the awake, active sleep and continuous slow wave sleep portion of quiet sleep. EEG is reactive in all states and synchronous. Between CA 44 and 46 weeks, the EEG is continuous in all states. There is continuous slow wave sleep that replaces tracé alternant. Spindles appear in the central regions with a frequency of 12 to 14 Hz. Stimulation during continuous slow wave sleep produces relative attenuation of the EEG. (Adapted with permission from Ebersole and Pedley's *Current Practice of Clinical Electroencephalography*, Figure 6.23).<sup>37</sup>

Conceptional age	Awake (eyes open)	Active Sleep (eyes closed)	Quiet Sleep (eyes closed)
24-29 weeks			
30-34 weeks			
35-36 weeks			
37-40 weeks			
40-44 weeks			
44-46 weeks			



tude less than 2  $\mu$ V. Between CA 30 and 34 weeks, the EEG has longer periods of continuity but is still relatively discontinuous and becomes somewhat reactive to stimulation. The EEG has a similar appearance during the awake and active sleep states. Quiet sleep is characterized by periods of discontinuity that are known as *tracé discontinu*. The EEG is synchronous in approximately 70 to 80 percent of the recording. From this age onward, the IBI intervals become progressively shorter, and the amplitude of the IBI progressively increases until the EEG becomes completely continuous around CA 44 weeks. Between CA 35 and 36 weeks, there is a clear distinction between the awake and active sleep states. The EEG is more continuous in both states (*activité moyenne*) but remains discontinuous during quiet sleep (known as *tracé alternant*, because of alternating periods of high-voltage burst intervals and low-amplitude IBI). The EEG is clearly reactive with voltage flattening, and increased continuity occurs during stimulation in quiet sleep. The EEG is more synchronous, during about 85% of the recording.

Between 37 and 40 weeks CA, the EEG becomes continuous and appears similar during wake and active sleep states. During quiet sleep, there is *tracé alternant* (Figure 26) with some periods of continuous SWS. EEG is completely synchronous and reactive to internal or external stimuli. Between 40 and 44 weeks CA, the EEG is continuous during wake, active sleep, and continuous SWS portion of quiet sleep. EEG is reactive in all states and synchronous. Between 44 and 46 weeks CA, the EEG is continuous in all states. There is continuous SWS that replaces *tracé alternant*. Spindles appear in the central regions with a frequency of 12 to 14 Hz. Stimulation during continuous SWS produces relative attenuation of the EEG.

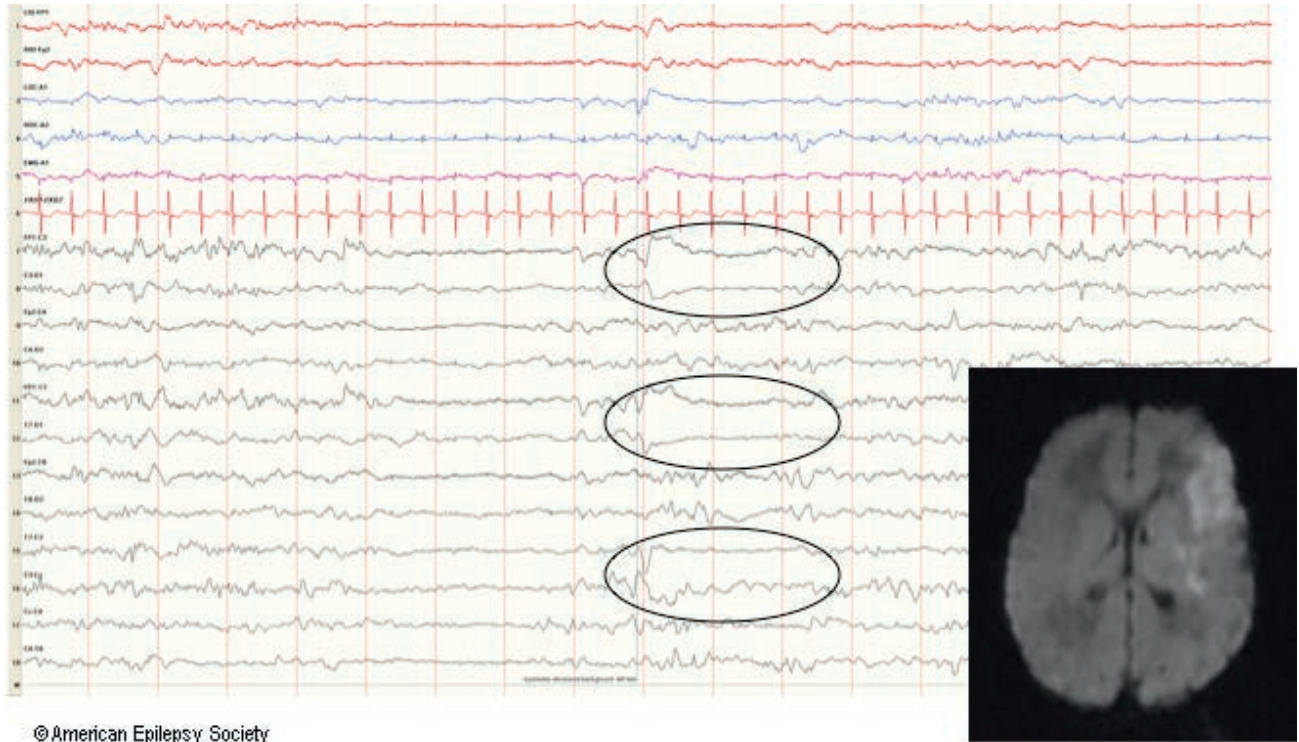


**Figure 26.** *Tracé alternant*. This is a neonatal EEG sample of a 25-day-old girl born at 39 weeks GA. The sample shows a segment of quiet sleep with *tracé alternant*. Figure courtesy of Elia M. Pestana-Knight, MD, Cleveland Clinic Foundation.



These patterns of continuity and discontinuity are clinical-electrographically defined as *tracé discontinu*, around 30 to 34 or 35 weeks, with quiet periods of voltage  $<25 \mu\text{V}$  (often  $<10 \mu\text{V}$ ); *tracé alternant*, occurring between 34 and 35 weeks until term during quiet sleep, with quiet periods of voltage  $>25 \mu\text{V}$ , alternating with bursts of 100 to 200  $\mu\text{V}$ ; and *tracé continu*, at 40 weeks CA and above, with continuous, irregular delta and theta of 50 to 100  $\mu\text{V}$  during awake and active sleep.

Symmetry in neonatal EEG refers to symmetry of activity arising from both hemispheres or homologous brain regions. Elements to consider for evaluation of symmetry are amplitude, frequency, and waveform elements. Asymmetry is suspected when the amplitude of two homologous brain regions exceeds a ratio of 2:1 (Figure 27). When analyzing an asymmetric pattern, if asymmetry is only in amplitude, one should consider incorrect EEG placement, scalp edema, and subdural collections. If asymmetry is of frequency, amplitude, and graphoelements, then one should consider stroke or structural lesions.

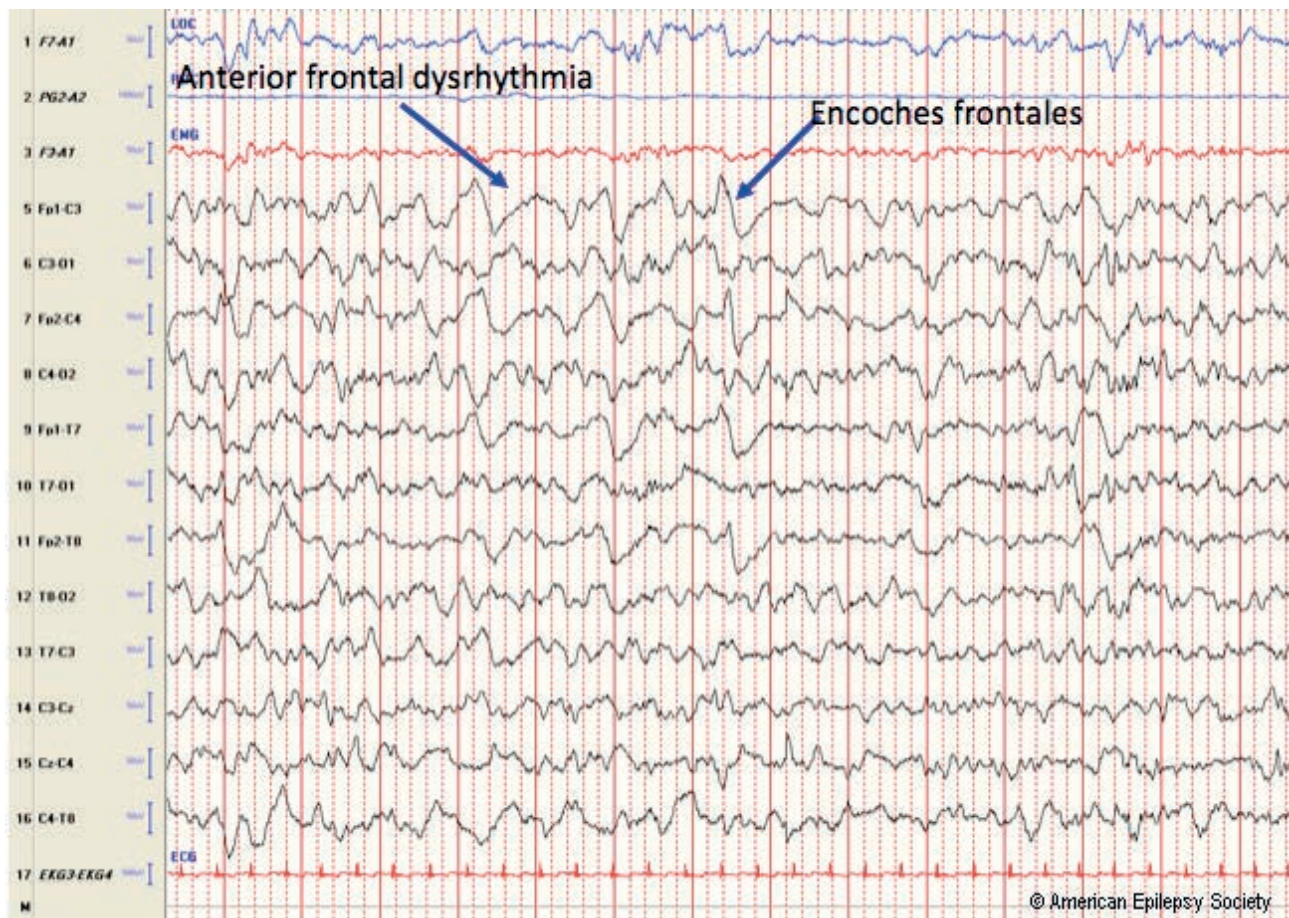


© American Epilepsy Society

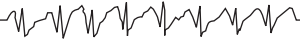**Figure 27.** Asymmetric background. This neonatal EEG sample was recorded in a 2-day-old full-term baby boy who had a left stroke. Notice the asymmetry in amplitude and frequency seen in the electrodes covering the left hemisphere (oval). This was an intermittent but consistent finding during the entire EEG record. Figure courtesy of Elia M. Pestana-Knight, MD, Cleveland Clinic Foundation.



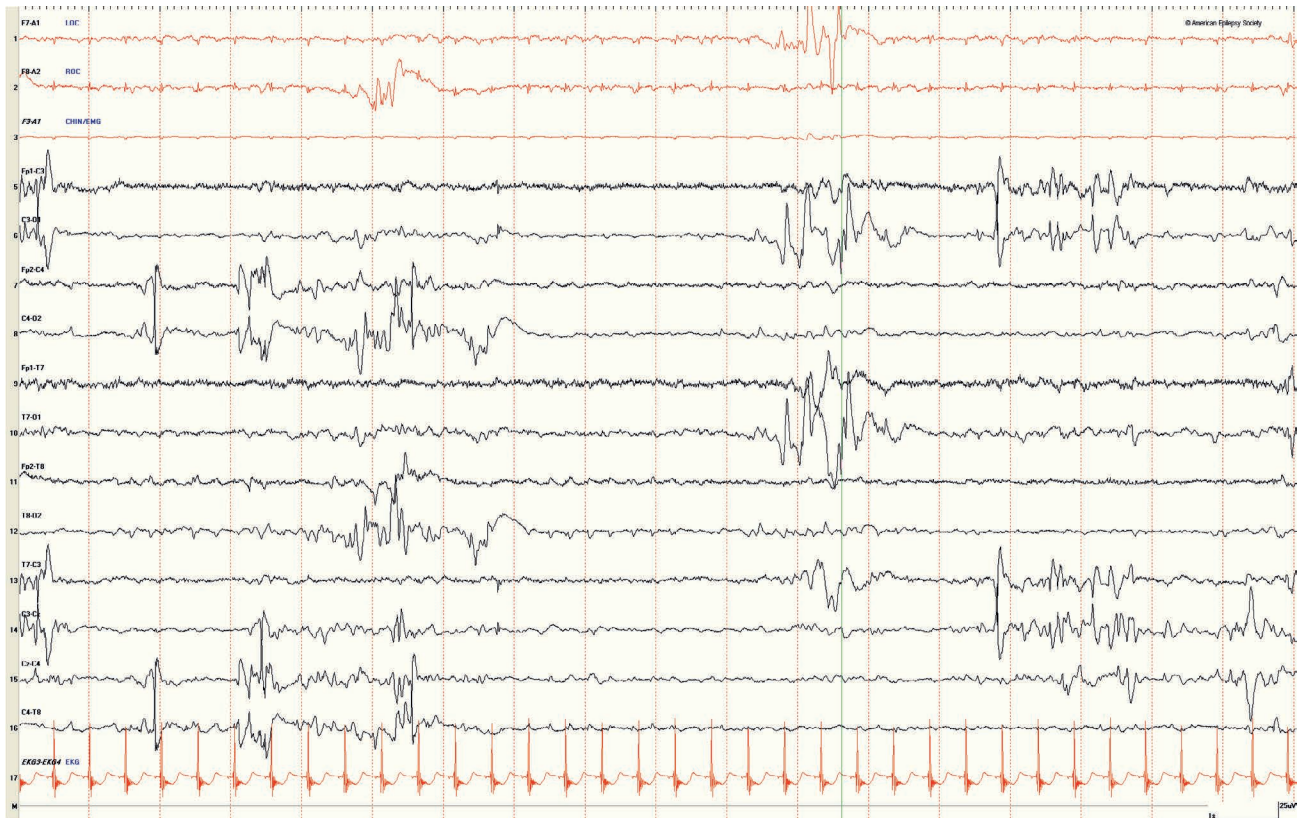
Synchrony has several meanings in EEG interpretation but in this case refers to the interhemispheric timing of graphoelements, mainly during the discontinuous portions of the neonatal EEG. EEG bursts are considered synchronized when there is less than 1.5 seconds separating the onset of the burst between the two hemispheres. Graphoelements that are always synchronous are *encoches frontales* and *anterior frontal dysrhythmia*, which are seen in all behavioral states but especially during quiet sleep in the transition from active to quiet sleep (Figure 28), and monorhythmic occipital delta. The amount of synchronization varies during neonatal EEG maturation. Before 29 to 30 weeks CA, bursts are 100% synchronous. Synchrony decreases to approximately



**Figure 28.** Neonatal EEG synchrony: example of encoches frontales and anterior frontal dysrhythmia. This is a sample of quiet sleep in a 25-day-old baby girl born at 39 weeks GA. There are two synchronous graphoelements in this sample: anterior frontal dysrhythmia, bifrontal semi-rhythmic delta activity lasting a few seconds and encoches frontales, bifrontal, sharply contoured symmetrical and synchronous transients. Both are seen in all behavioral states but more prominently in the transition from active to quiet sleep. Figure courtesy of Elia M. Pestana-Knight, MD, Cleveland Clinic Foundation.



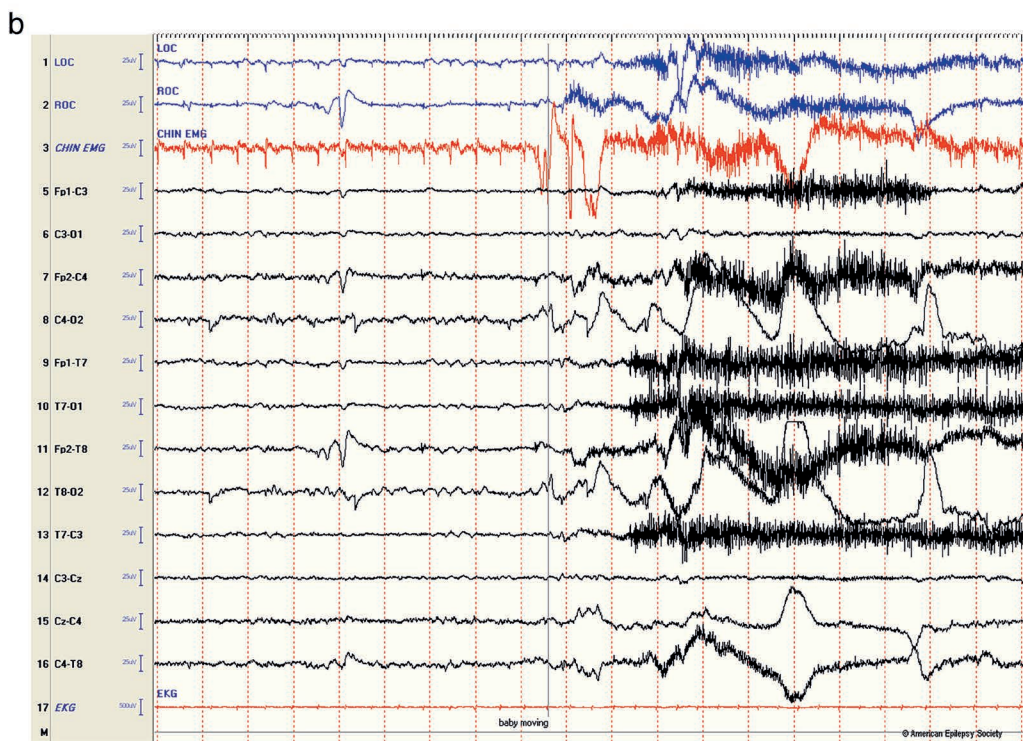
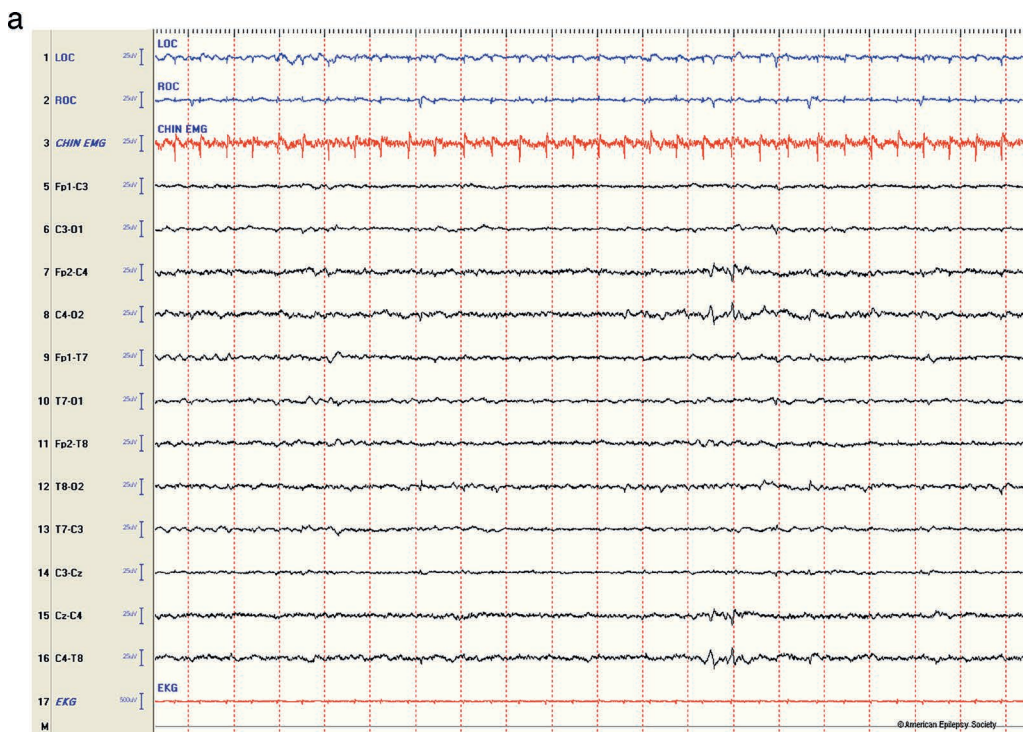70% between 31 and 36 weeks CA and increases progressively thereafter until again reaching 100% at age 37 weeks CA. Bursts are asynchronous if more than 1.5 seconds separate the onset of the bursts between the right and left hemispheres (Figure 29). Asynchrony can be seen in any condition that causes diffuse encephalopathy, and in cerebral dysgenesis with callosal agenesis.



**Figure 29.** Neonatal EEG: asynchrony. This is a sample of an abnormal neonatal EEG from a 2-week-old baby born at 37 weeks having neonatal seizures as a result of hypoxic-ischemic encephalopathy and sepsis. Notice the asynchrony of the bursts. The EEG is also significant for very low amplitude of the interburst periods. Figure courtesy of Elia M. Pestana-Knight, MD, Cleveland Clinic Foundation.



The amplitude of the EEG is measured in voltage. The voltage value is measured from peak to peak of the waveform. In neonatal EEG, the amplitude of the graphoelements decreases from 24 weeks CA to term. Amplitude abnormalities include an isoelectric EEG, a depressed or undifferentiated EEG with voltage less than 10  $\mu\text{V}$ , or an EEG with persistent low voltage under 5 to 10  $\mu\text{V}$  when awake, under 10 to 25  $\mu\text{V}$  during quiet sleep, or low voltage persistent beyond 43 weeks CA (Figure 30a and b).



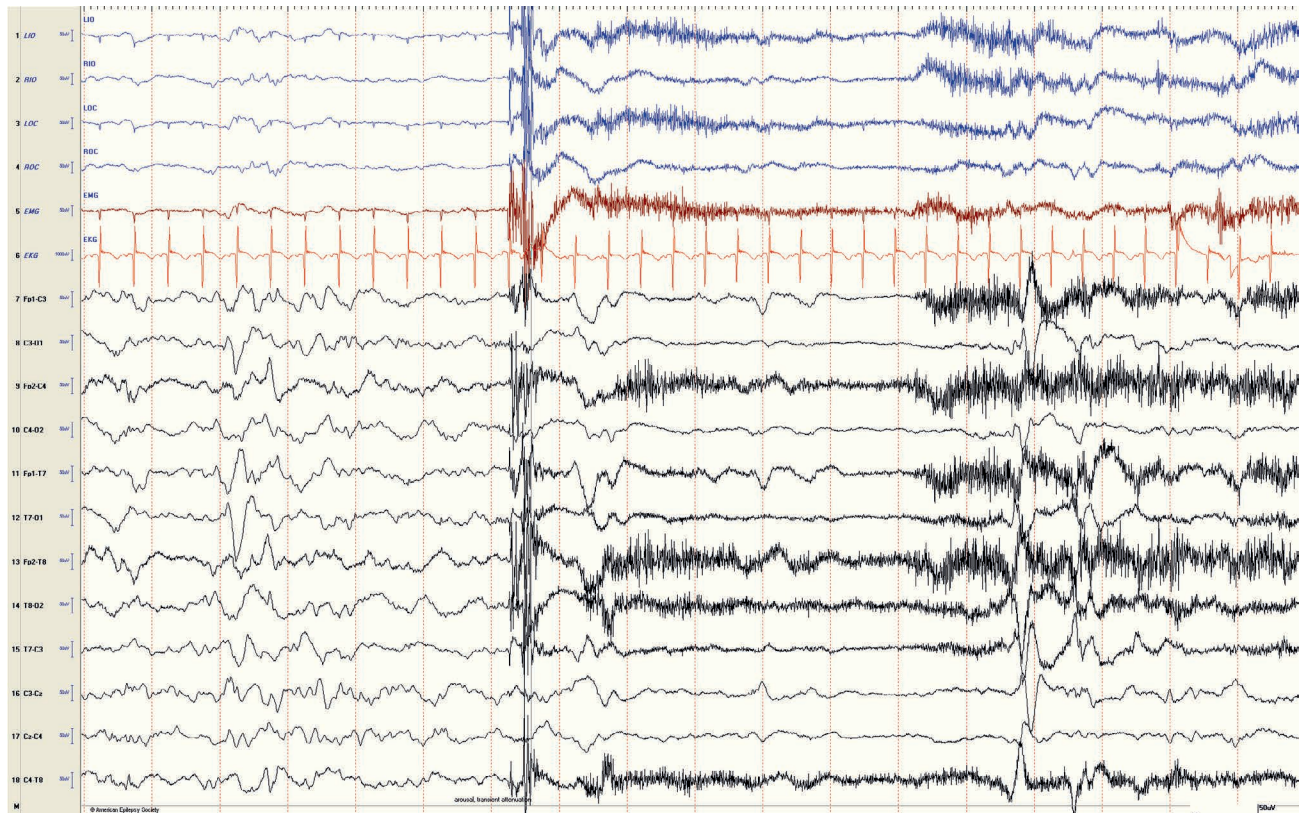
**Figure 30.** Low-amplitude neonatal EEG in hypoxic-ischemic encephalopathy. (a) Low-amplitude, sleep, newborn with hypoxia; (b) low-amplitude neonatal EEG: arousal, no change in stage. (a) and (b) correspond to an EEG sample of a full-term baby boy with severe hypoxic-ischemic encephalopathy. This sample is recorded during the sleep state and shows a very depressed and undifferentiated EEG with very limited mixture of frequencies. Figure courtesy of Elia M. Pestana-Knight, MD, Cleveland Clinic Foundation.

(a) Low-amplitude, sleep, newborn with hypoxia.  
 (b) Low amplitude neonatal EEG: arousal, no change in stage.



Reactivity is the clinical or EEG response to external stimulation or internal arousal. There are clinical changes and EEG changes that indicate reactivity. Clinical response includes active movements and respiratory pattern changes. EEG response includes frequency changes, increased continuity, decreased amplitude, and change from sleep to a wakeful pattern (Figure 31). Photic stimulation does not produce photic driving in the term neonate. Absence of reactivity is normal in premature babies under 30 weeks CA. Otherwise, absence of reactivity indicates pathological thalamo-cortical disruption.

Table 3 shows the development of the different graphoelements at different CAs. When interpreting neonatal EEGs, it is important to learn to differentiate normal sharp-wave transients from sharp waves that can be indicative of neonatal CNS dysfunction.



**Figure 31.** Reactivity during arousal. This sample corresponds to a neonatal EEG of a full-term baby. Notice the reactivity of the EEG to arousal with a relative voltage attenuation (seconds 9–14) followed by continuous activity (second 15 until end of page). Figure courtesy of Elia M. Pestana-Knight, MD, Cleveland Clinic Foundation.

## Graphoelements

- Monomorphic occipital delta • 24-34 weeks
- Delta brushes • 24-36 weeks, peak 34 weeks, sometimes seen at term during quiet sleep
- Rhythmic temporal theta • 24-34 weeks
- Anterior dysrhythmia • 35-44 weeks
- Encoches frontales • 34-44 weeks

© American Epilepsy Society

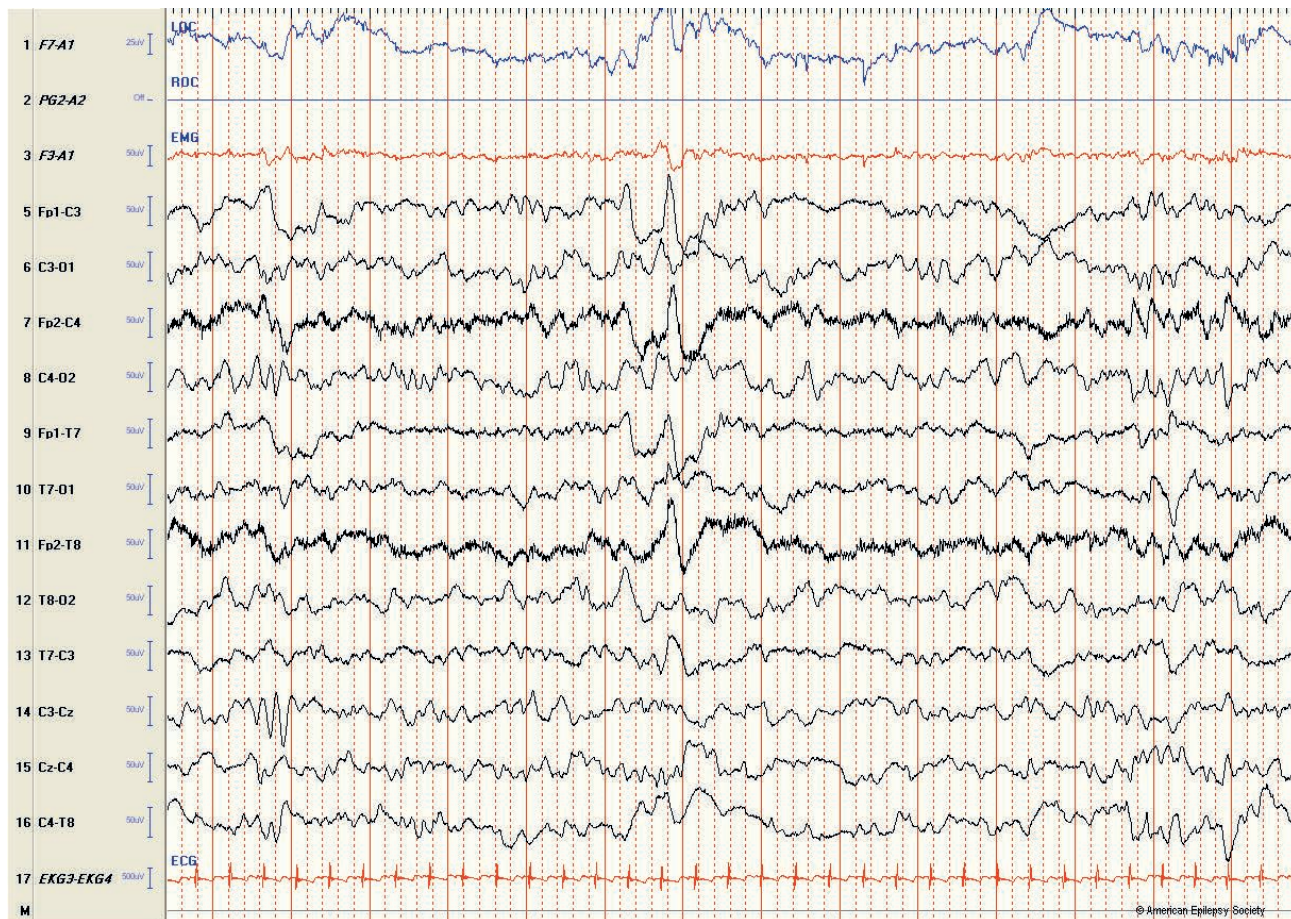
**Table 3. Development of Graphoelements\***

\*Table reproduced with permission from Elia M. Pestana-Knight, MD, Cleveland Clinic Foundation, Cleveland, Ohio.

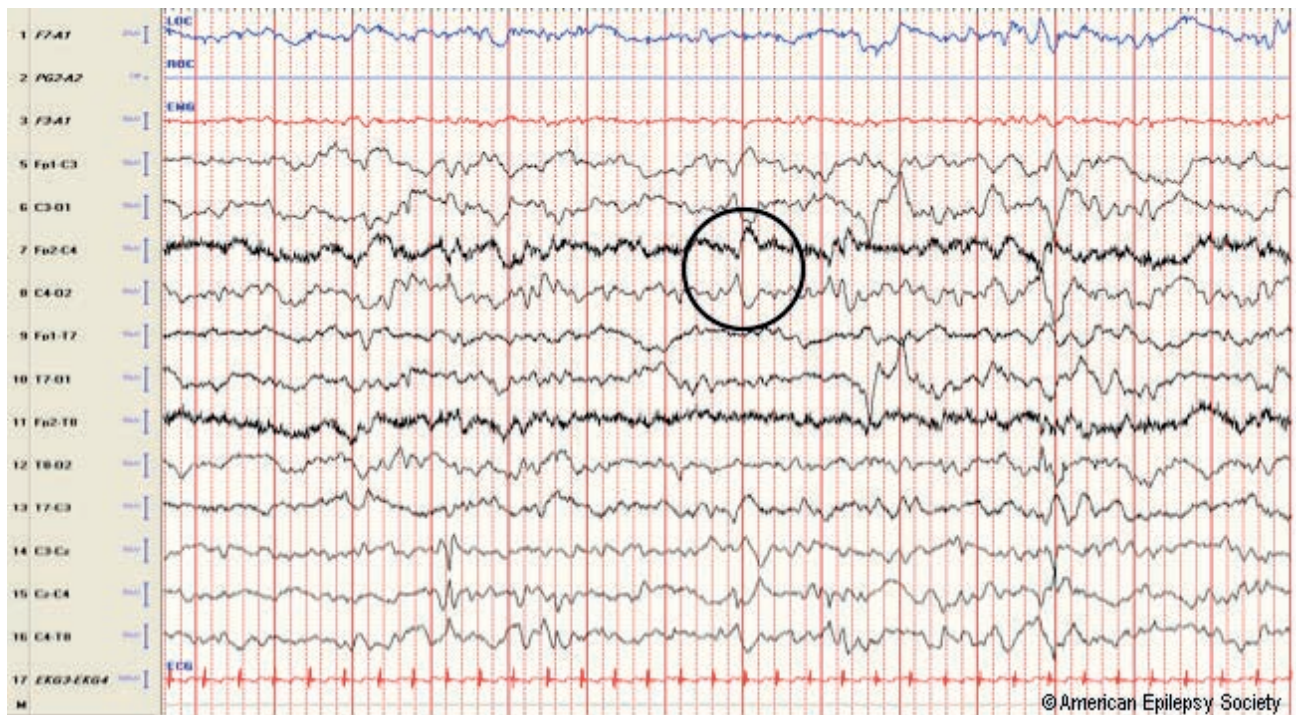



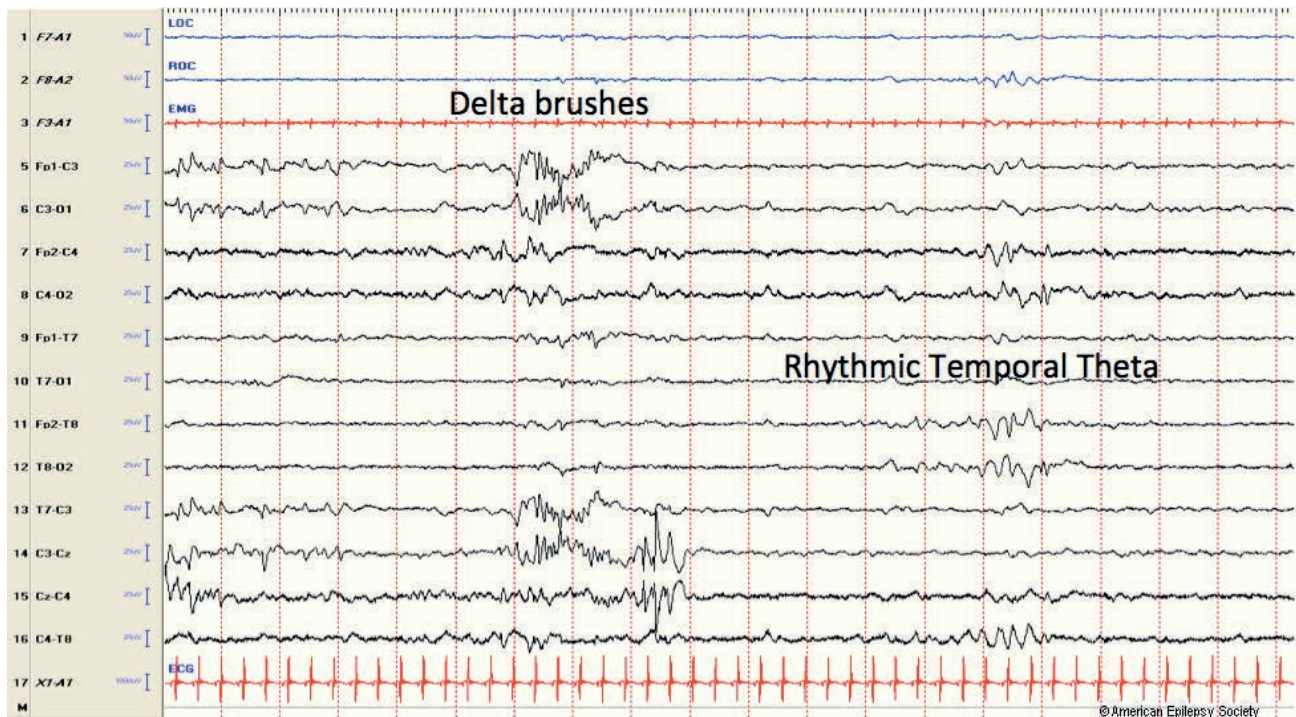
Sporadic sharp waves are present during all preterm and term recordings. Examples include encoches frontales (Figures 28, 32) and sharp transients located in the centro-temporal regions (Figures 33 and 34). Many sharp transients in neonatal EEGs can be



**Figure 32.** Encoches frontales. This EEG sample shows a normal sharp transient, encoches frontales. Figure courtesy of Elia M. Pestana-Knight, MD, Cleveland Clinic Foundation.



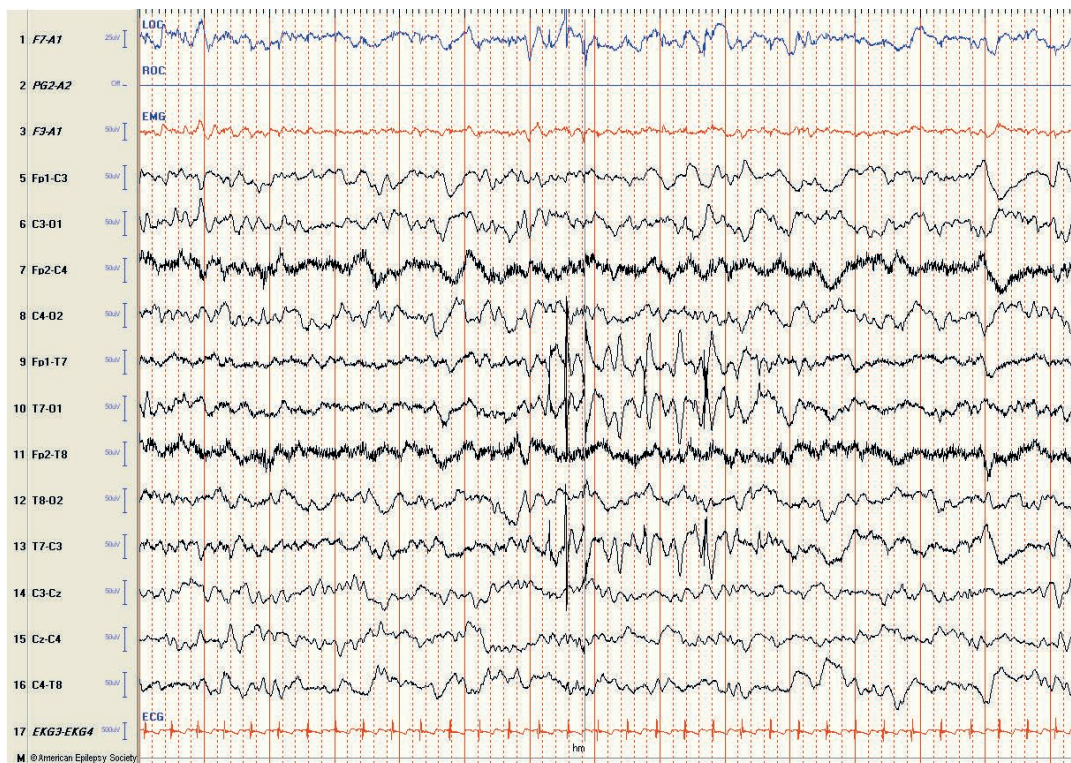**Figure 33.** Normal sharp transients, central region. This EEG sample shows normal sharp transients in the central region. Figure courtesy of Elia M. Pestana-Knight, MD, Cleveland Clinic Foundation.



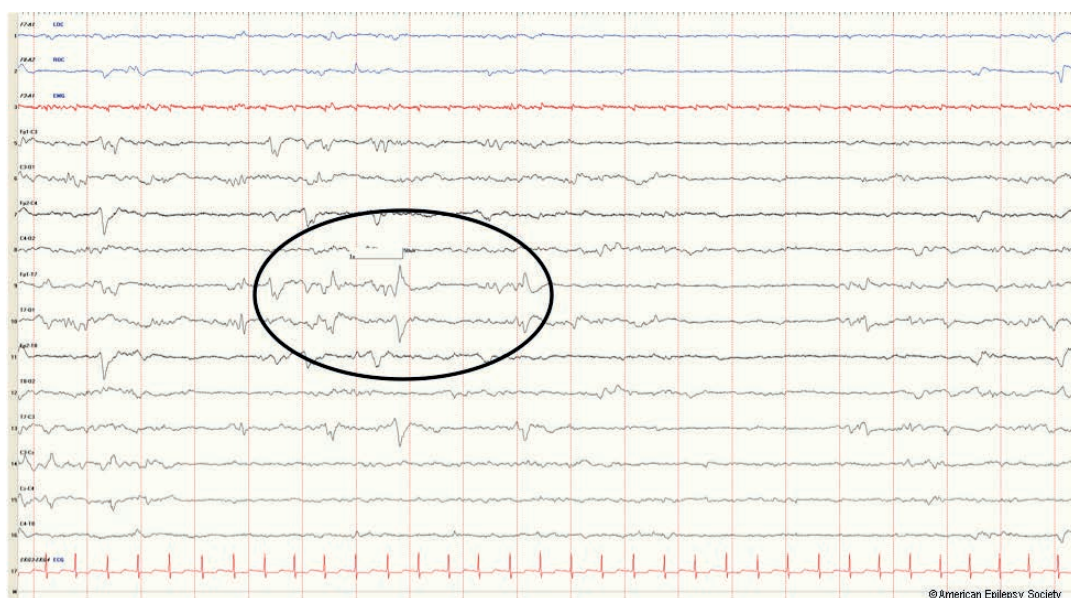
**Figure 34.** Central delta brushes, right rhythmic temporal theta. This is an EEG sample of a 32-week CA baby during sleep. Notice the centrally located delta brushes (delta wave with superimposed alpha beta activity 8 to 20 Hz) and the right temporal theta (brief paroxysmal or independent theta activity in the temporal region that can be sharply contoured but lacks evolution or after-going slow wave). Figure courtesy of Elia M. Pestana-Knight, MD, Cleveland Clinic Foundation.



considered artifacts until proven otherwise (Figure 35). As in adult EEGs, abnormal sharp waves are most often negative polarity sharp waves with a classic morphology, including a cerebral electrical field and an after-going slow wave that disrupts the background. The relation of neonatal sharp waves with neonatal seizures and subsequent risk for epilepsy is often unclear. Sharp waves seen in the occipital region and midline are usually abnormal. Positive sharp waves generally have no relation to seizures but are instead related to structural brain abnormalities; however, though rare, positive sharp waves may be epileptogenic (Figure 36). When positive sharp waves are located in the rolandic areas, they are most often associated with white matter lesions.



**Figure 35.** Neonatal EEG: artifact. Sharp wave–like transients owing to artifact in T7. Figure courtesy of Elia M. Pestana-Knight, MD, Cleveland Clinic Foundation.



**Figure 36.** Positive temporal sharp wave. This EEG sample is from a 2-week-old baby, born at 37 weeks, who had neonatal seizures. The sample shows positive temporal sharp waves. Figure courtesy of Elia M. Pestana-Knight, MD, Cleveland Clinic Foundation.



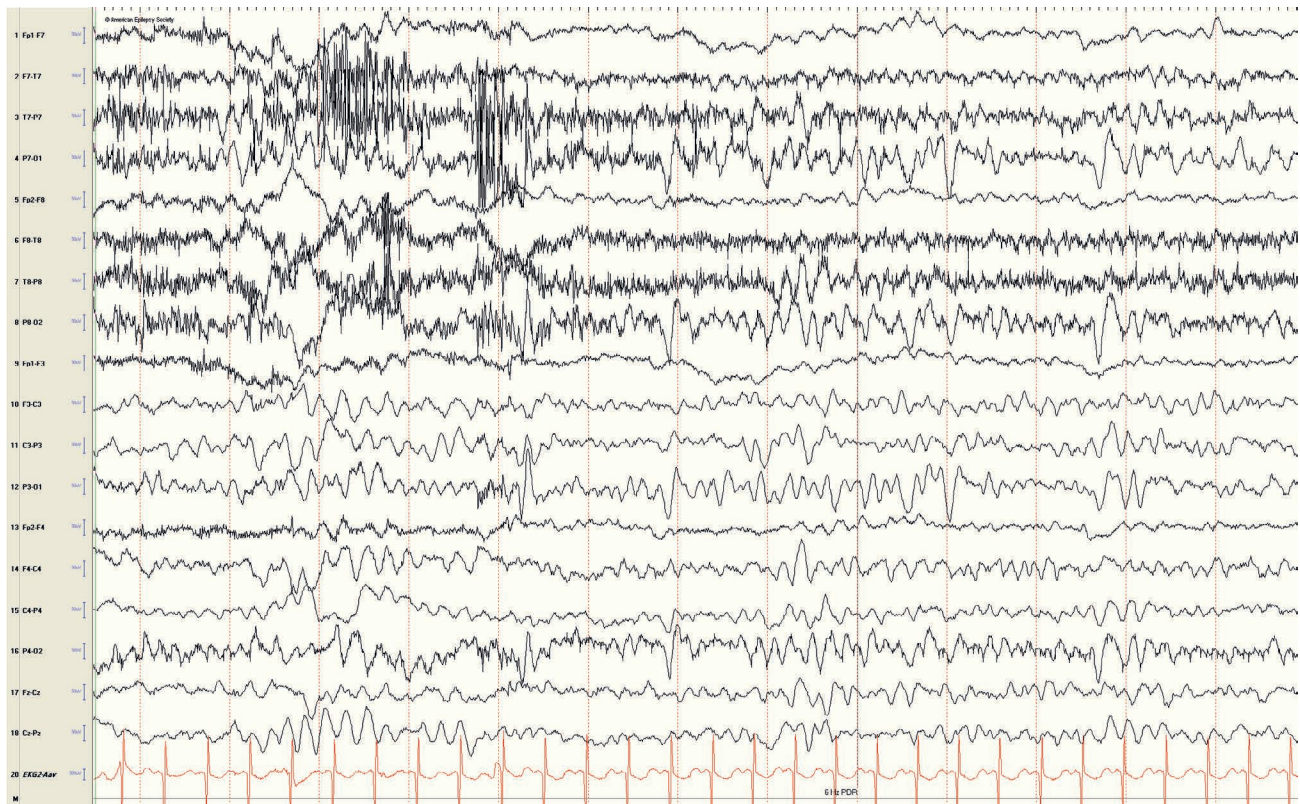
Sleep/wake cycles can only be differentiated by EEG after 31 weeks CA. Awake and active sleep have some clinical and EEG similarities, including irregular respirations and mixed frequencies in the EEG background. In contrast to older infants and adults, active sleep follows wakefulness in neonates. Active sleep accounts for up to half of the sleep time in neonates. Clinically, quiet sleep is characterized by absence of eye movements in the EOG, regular respiration, and absence of movement artifacts. On the EEG, *trace alternant* is characterized by quiet periods of voltage over 25  $\mu$ V, alternating with bursts of 100- to 200- $\mu$ V amplitude. Slow quiet sleep shows continuous high-amplitude delta activity over all brain regions. Encoches frontales is seen during quiet sleep. Transitional sleep or undetermined sleep cannot be classified into active or quiet sleep and is mainly seen between 37 and 40 weeks CA, during transitions between the different behavioral states.

In conclusion, analysis of the neonatal EEG background begins with knowledge of the conceptional (conceptual) age and clinical state of the recorded neonate. Subsequent interpretation should include an assessment of the EEG background continuity, symmetry, synchrony, normal and abnormal patterns, sleep/wake cycle, and seizures.

### ***Infant and Pediatric Developmental Changes in the EEG***

Thus far, we have considered the EEG in preterm and term neonates below 38 weeks GA. Infants may be defined as being in the age period between 1 and 12 months; toddlers, in the 1- to 3-year span; and preschool children, in the 3- to 6-year age range. School-age children are then in the 6- to 18-year span, with further changes in the EEG occurring in the subdivision of children aged 6 to 12 years and in teenagers aged 13 to 19 years.

During infancy (1–12 months), there are specific changes in the EEG background. By age 2 months, a posterior dominant rhythm (PDR), a forerunner of the alpha rhythm, is established. It usually begins as a 3- to 4-Hz frequency, increasing to 4 to 5 Hz by age 6 months, reaching approximately 5 to 7 Hz by 12 months (Figures 37–40), and finally becoming an alpha frequency range of 8 Hz by 3 years. Transition between wakefulness and drowsiness is apparent when the background slows by 1 to 2 Hz and fronto-central activity may predominate and reach relatively high amplitudes of approximately 200  $\mu$ V. Sleep spindles typically



**Figure 37.** Pediatric EEG: 5- to 6-Hz PDR in an 11-month-old child. Figure courtesy of Elia M. Pestana-Knight, MD, Cleveland Clinic Foundation.

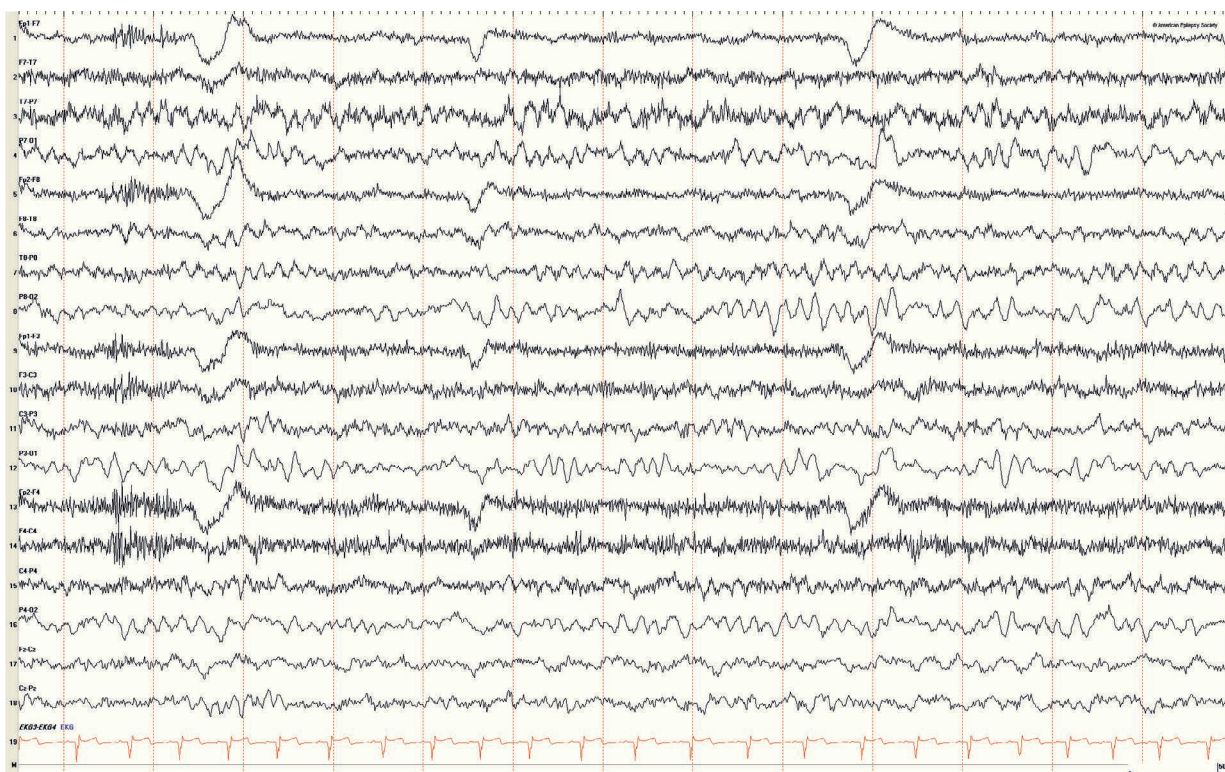


Figure 38. Pediatric EEG: 6- to 7-Hz PDR in a 12-month-old child. Figure courtesy of Elia M. Pestana-Knight, MD, Cleveland Clinic Foundation.

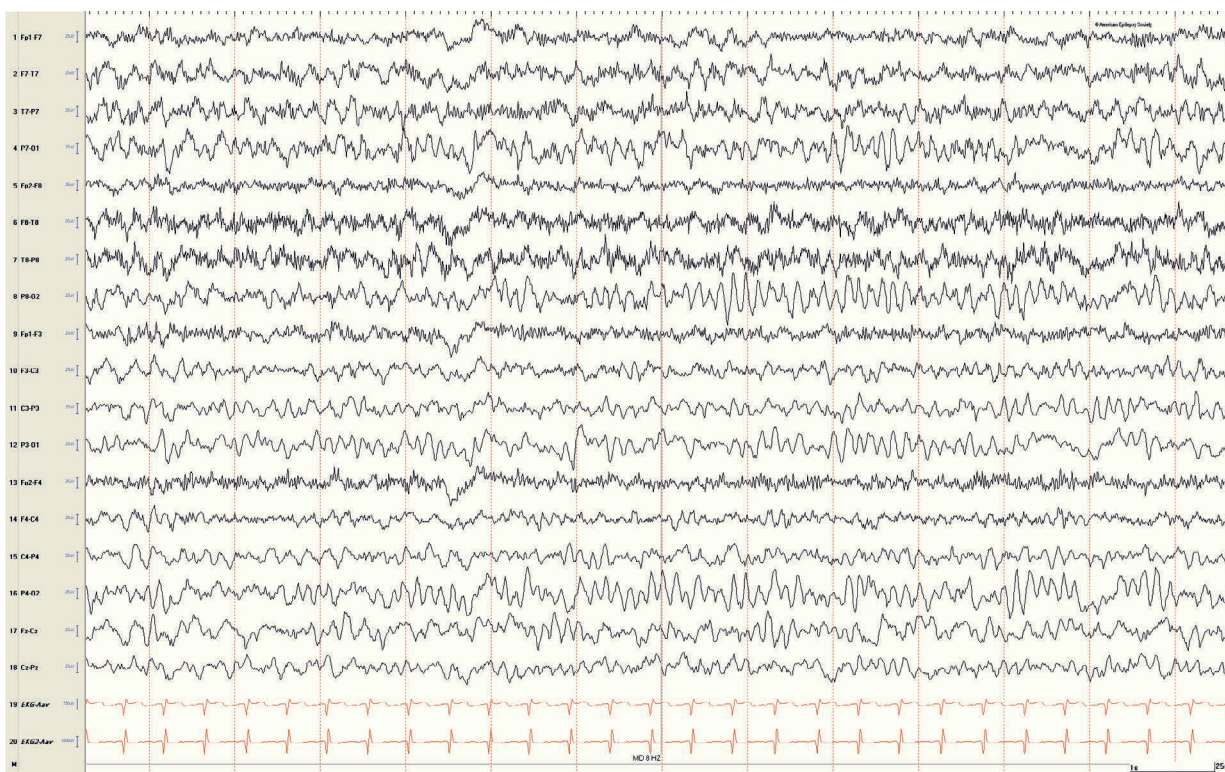
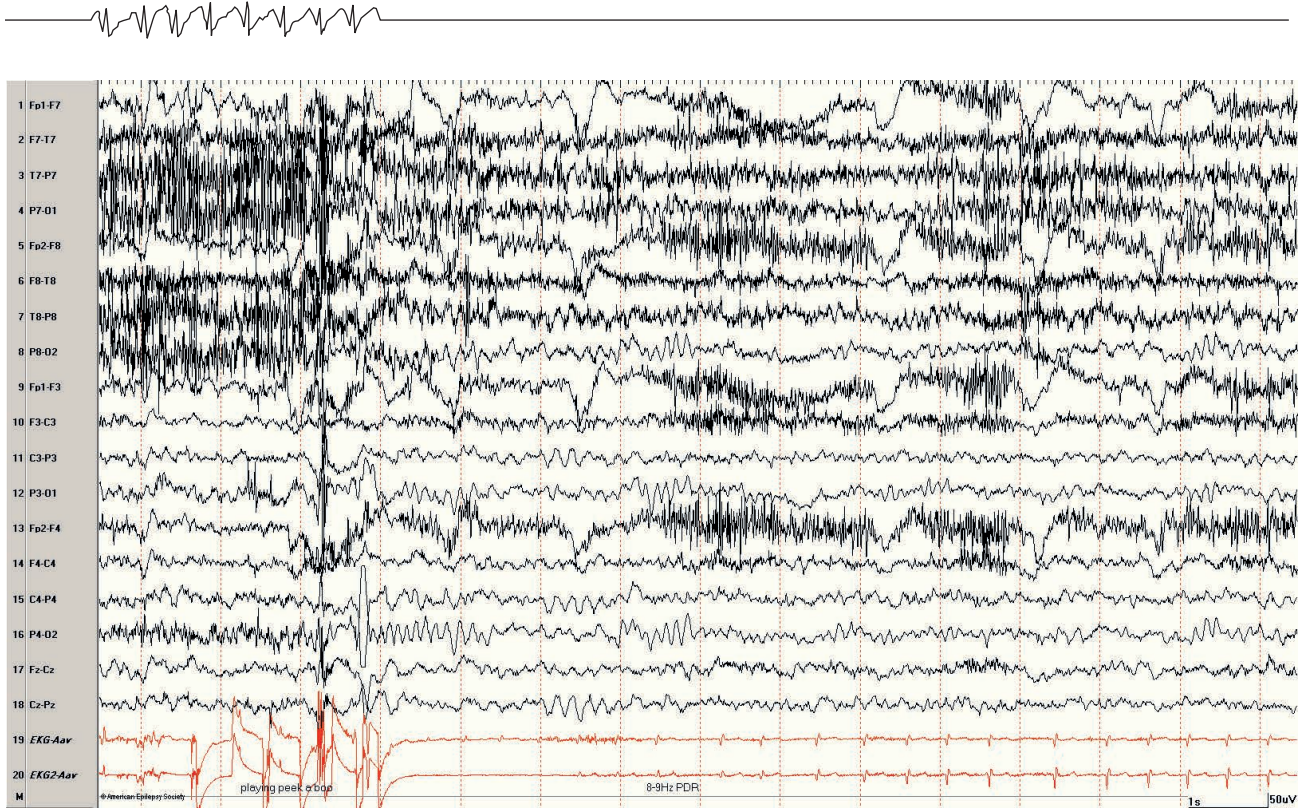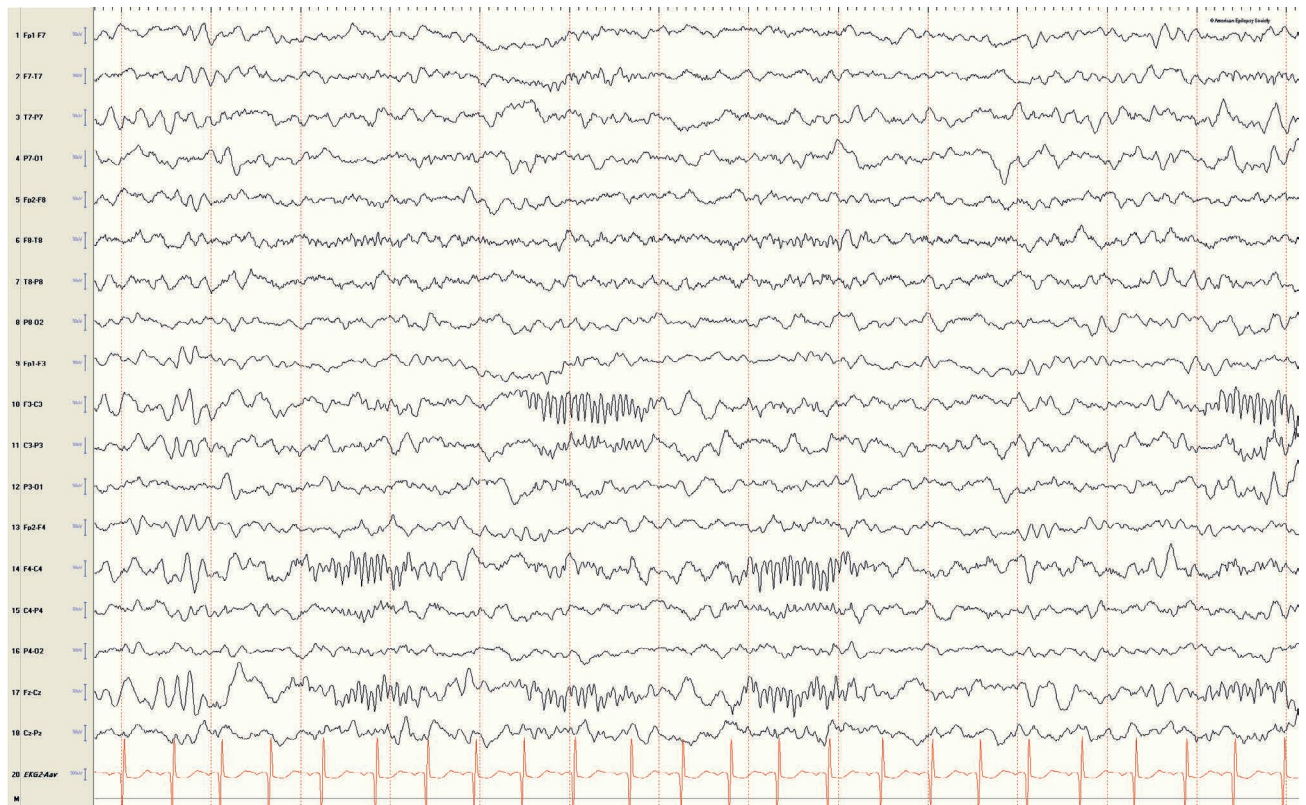


Figure 39. Pediatric EEG: normal 16-month-old waking EEG record, reaching 7- to 8-Hz PDR. Figure courtesy of Elia M. Pestana-Knight, MD, Cleveland Clinic Foundation.



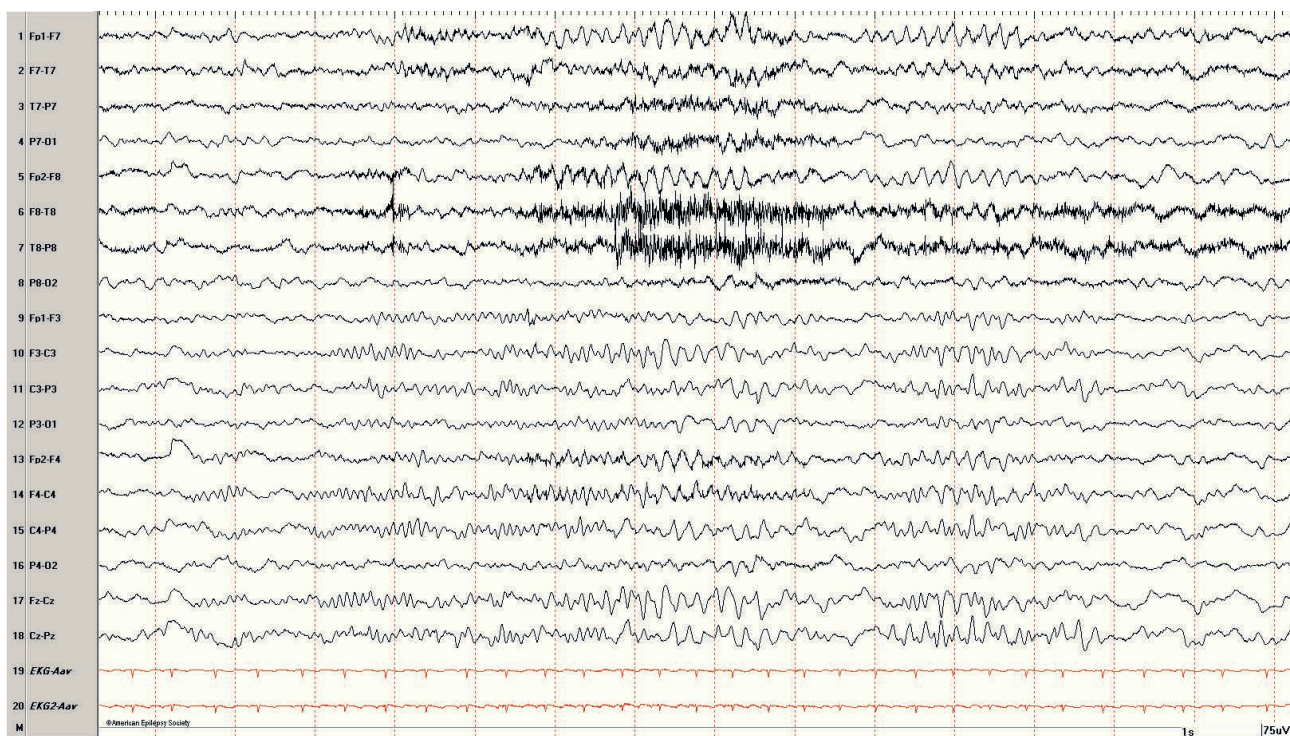
**Figure 40.** Pediatric EEG: eye closing in a 23-month-old boy playing “peek-a-boo,” demonstrating 7-Hz PDR. Figure courtesy of Elia M. Pestana-Knight, MD, Cleveland Clinic Foundation.



**Figure 41.** Pediatric EEG: asynchronous spindles in a 16-month-old boy. Figure courtesy of Elia M. Pestana-Knight, MD, Cleveland Clinic Foundation.



develop by 2 to 3 months, are often asynchronous, and may remain so until about 6 to 12 months of age. During the age period of 6 to 12 months, sleep spindles can have very long durations, lasting for 10 to 15 seconds, and may be quite asynchronous by durations as long as 1 to 5 seconds (Figure 41). V-waves and K-complexes develop between 2 and 5 months, and a slower frequency background of 1 to 3 Hz predominates during sleep. At this age, V-waves are characteristically sharp and spiky, often occur in repetitive trains, and appear lateralized with a fronto-central or even central distribution, requiring caution to carefully distinguish them from epileptiform discharges. REM sleep begins to diminish from approximately 50% levels of active (REM) sleep seen in newborns, to about 40% of sleep time by age 3 to 5 months, reaching 30% by 12 to 24 months of age. Activating procedures, such as hyperventilation, are not practical until about 3 years when children will cooperate with instructions. However, during spontaneous crying, state transitions between sleep and arousal to wakefulness, or during periods of drowsiness, a prominent buildup of slower high-voltage theta and delta EEG frequencies may be seen, similar to the effect of hyperventilation seen in children and adolescents (Figure 42). Photic stimulation may begin to produce a slow-frequency driving response of 1 to 3 Hz during infancy by about 6 months, and photic responses may be exaggerated in certain encephalopathies including neuronal ceroid lipofuscinosis and Gaucher disease.

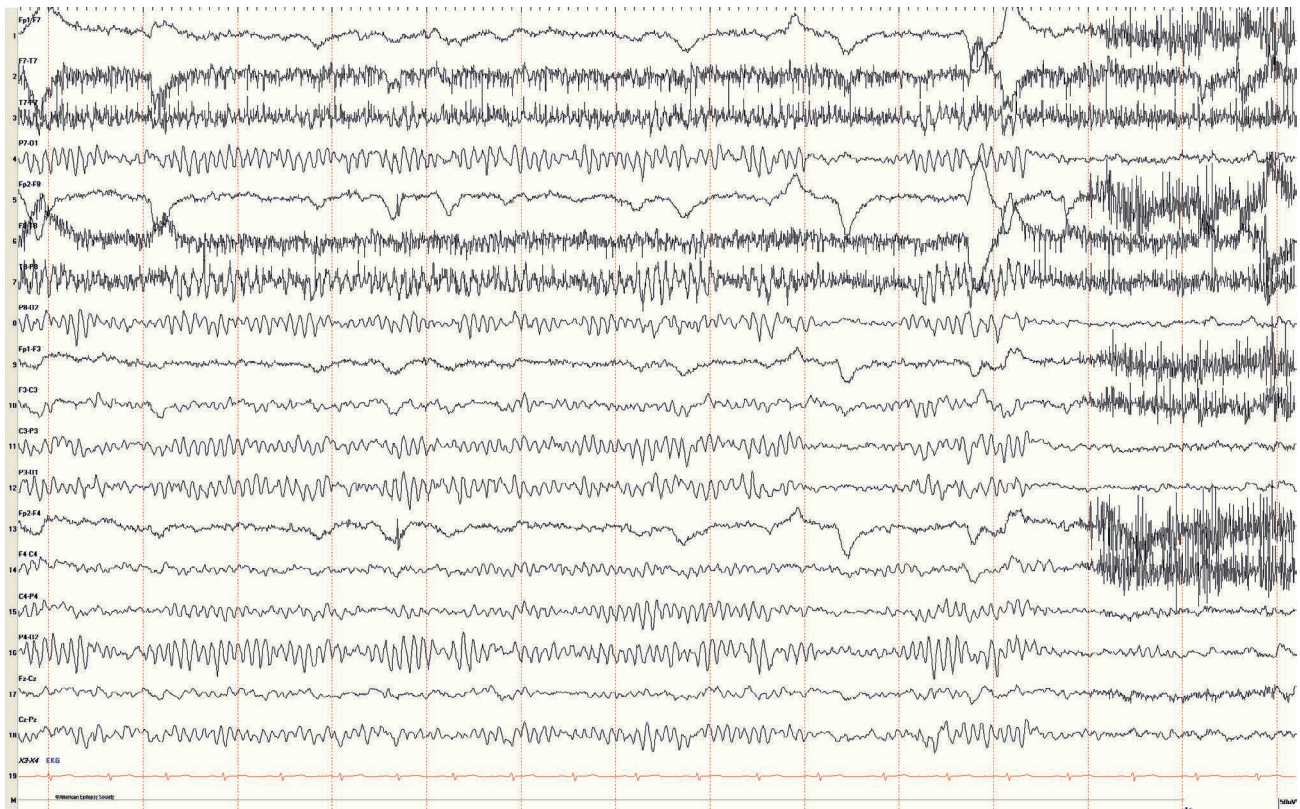


**Figure 42.** Frontal arousal in a 16-month-old boy. Figure courtesy of Elia M. Pestana-Knight, MD, Cleveland Clinic Foundation.



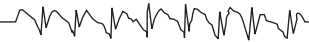Many further maturational changes unfold during the first 3 years of life. The PDR reaches about 8 Hz by 3 years in most toddlers, but the predominant EEG background frequencies remain slower in the delta and theta frequency ranges of 2 to 6 Hz. A prominent  $\mu$  rhythm over the central regions usually develops by 1 to 2 years, typically before the alpha rhythm fully reaches 8 Hz, and beta frequency activity also emerges. During drowsiness, *hypnagogic hypersynchrony*, a buildup of high-voltage delta activity, which can have sharp or spiky components often in the fronto-centro-parietal regions, is common following the first year of life and especially around 2 to 4 years. This should not be mistaken for epileptiform activity. By 1 to 3 years of age, sleep spindles should be synchronous and symmetric, and reach a frequency of 12 to 14 Hz.

In preschool children aged 3 to 6 years, theta frequencies remain in the background, but the alpha PDR background frequency increases further until reaching 8 to 9 Hz by 5 to 8 years of age. This is often intermixed with delta activity known as *posterior slow waves of youth*, which may persist into teenage years and even into young adulthood. Further maturation of the alpha rhythm frequency may still occur, with alpha activity reaching 8 to 9 Hz by 8 years of age, 9 to 10 Hz by 10 years, and adult range frequencies of 8 to 12 Hz by age 12 to 13 years (Figure 43). By 16 years of age, the minimal background alpha frequency should be 8.5 Hz, although posterior slow waves of youth may persist into the late 20s. Common NREM sleep features including V-waves,

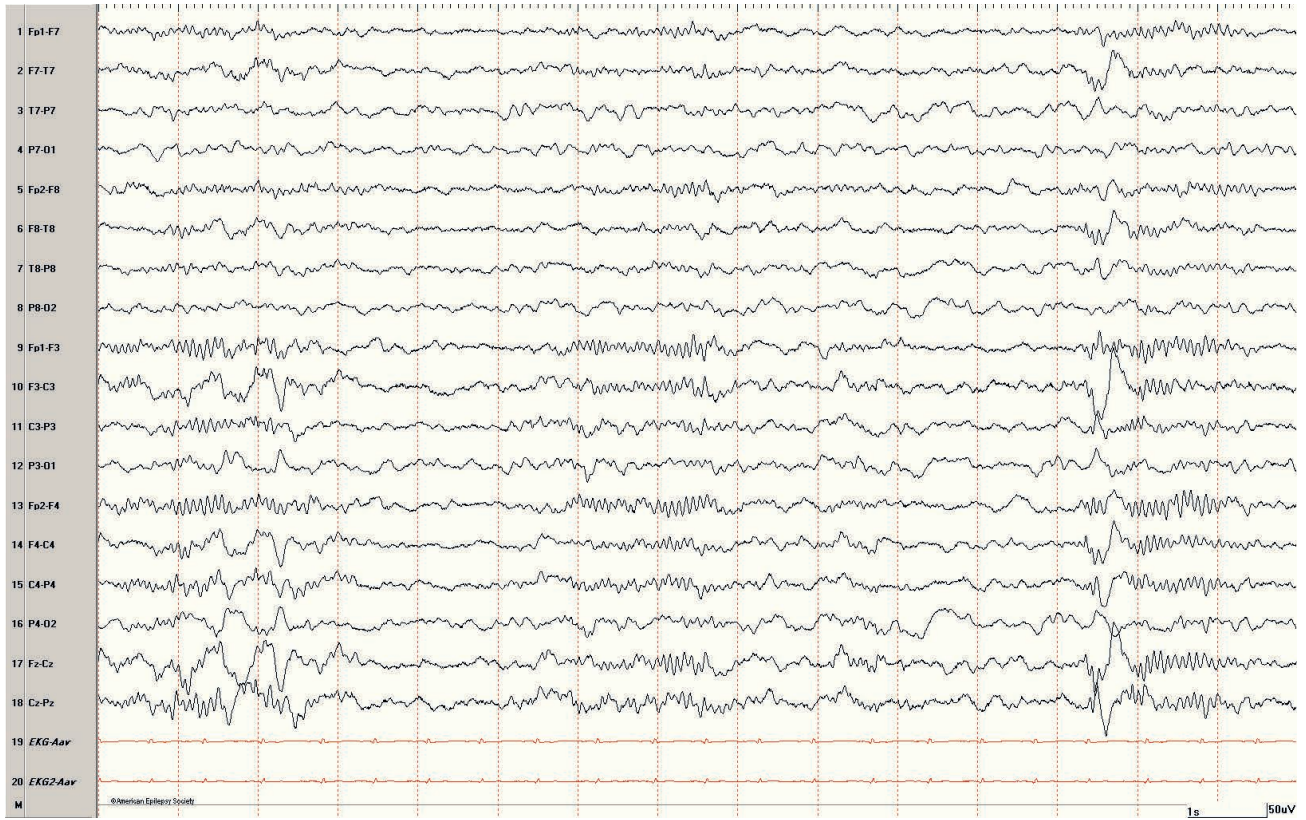


**Figure 43.** Pediatric EEG: normal waking background in a 10-year-old girl, showing a 10-Hz alpha PDR. Figure courtesy of Elia M. Pestana-Knight, MD, Cleveland Clinic Foundation.

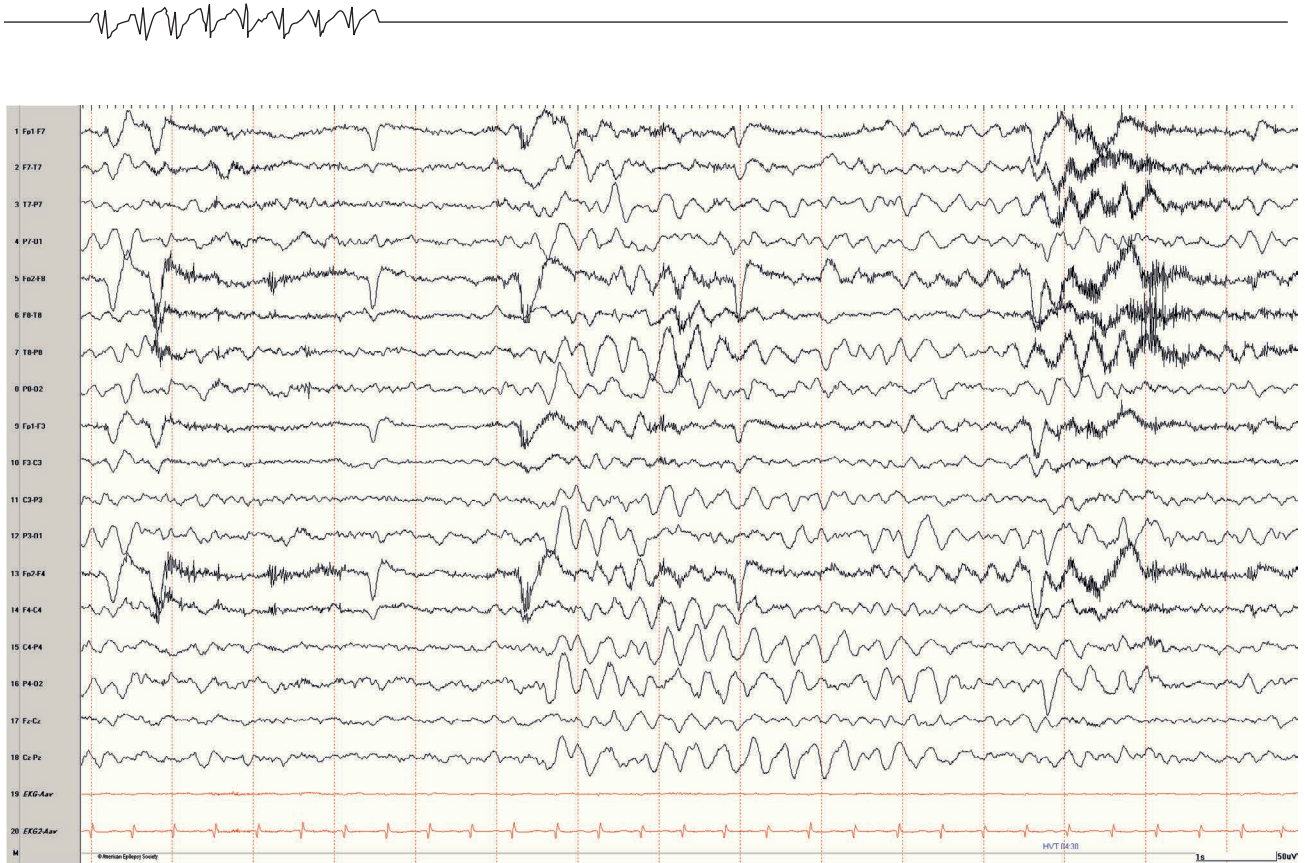



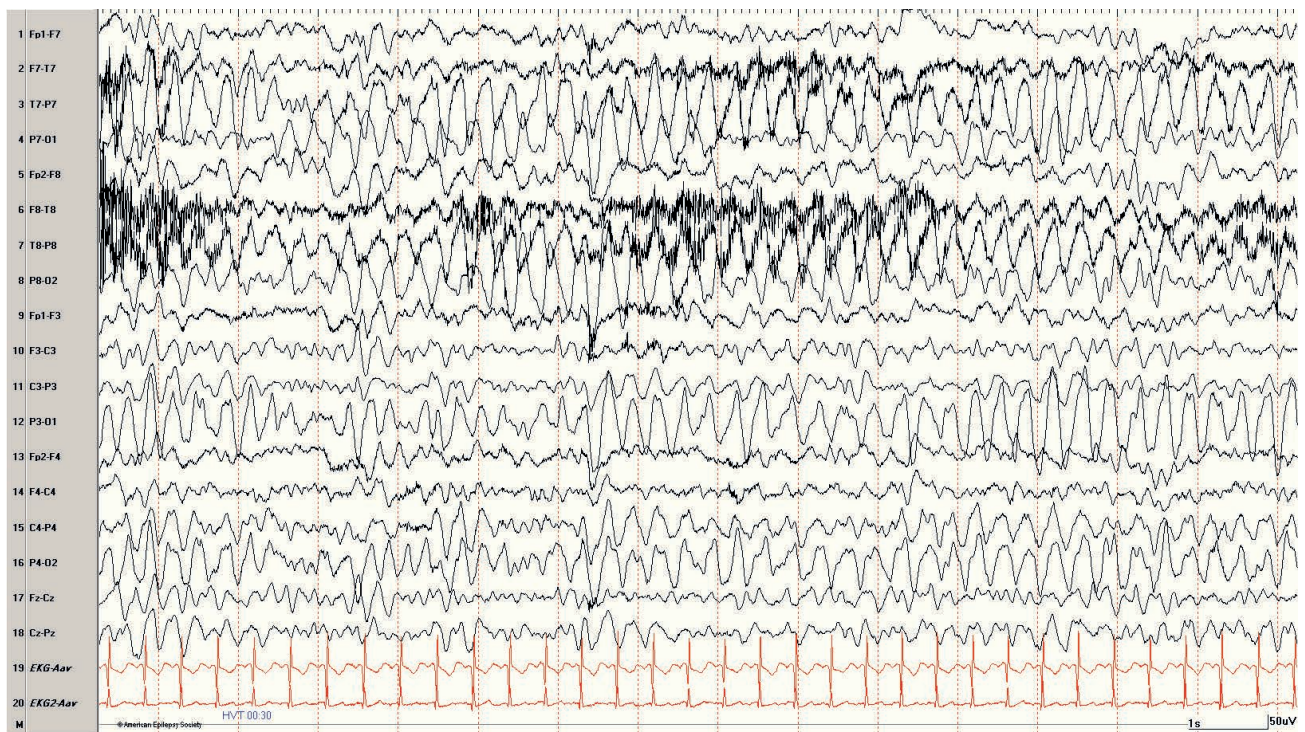
K-complexes, and sleep spindles become fully developed in school-aged children (Figure 44). Hyperventilation may now be routinely performed to attempt to activate epileptiform activity and absence seizures, and frequently elicits a prominent slow wave build-up response (Figures 45, 46). Photic stimulation may routinely elicit a posteriorly predominant driving response (Figure 47),



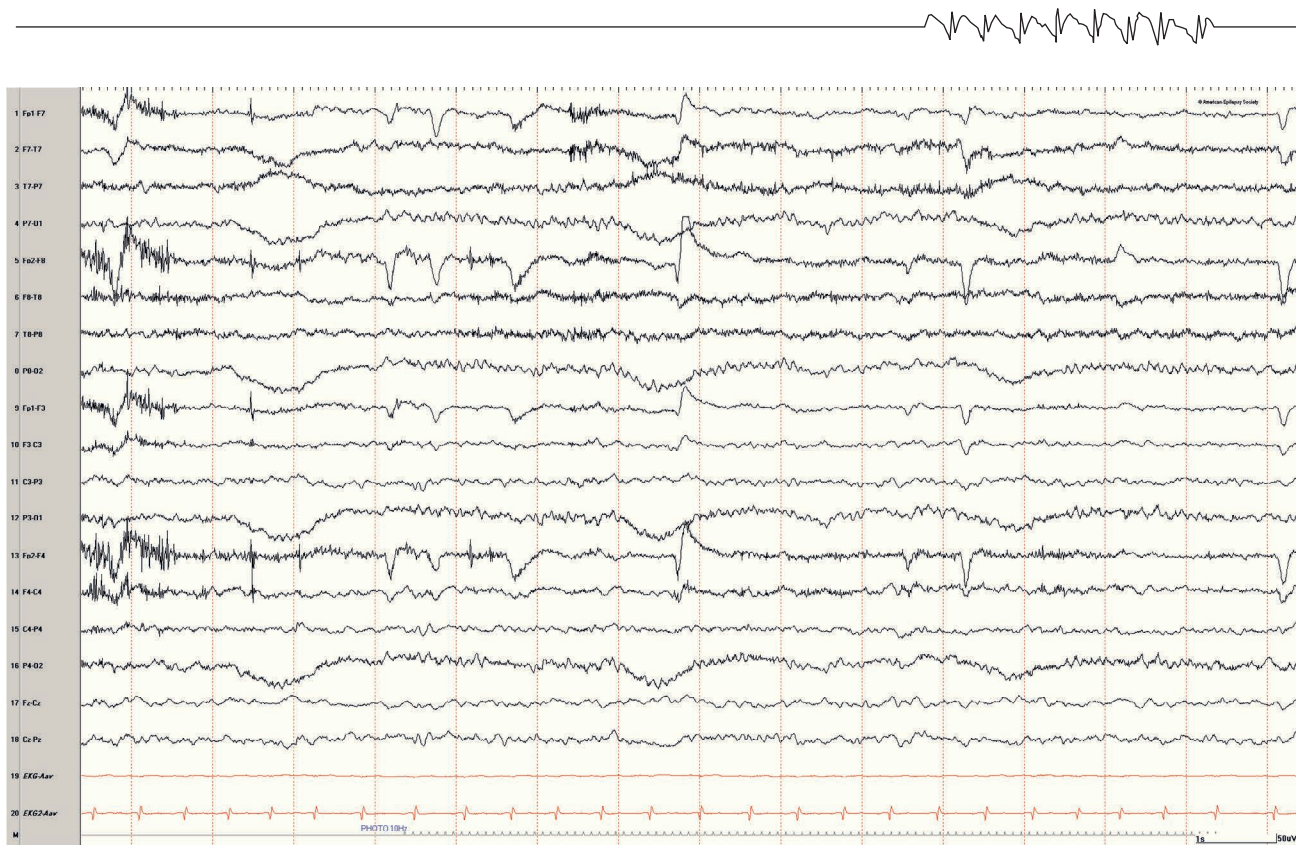
**Figure 44.** Pediatric EEG: N2 (stage 2 NREM) sleep in an 8-year-old boy. Figure courtesy of Elia M. Pestana-Knight, MD, Cleveland Clinic Foundation.



**Figure 45.** Pediatric EEG: buildup of slow wave frequencies during hyperventilation in a 7-year-old girl. Figure courtesy of Elia M. Pestana-Knight, MD, Cleveland Clinic Foundation.



**Figure 46.** Pediatric EEG: build-up response becomes more prominent later during hyperventilation in the same 7-year-old girl as shown in Figure 43. Figure courtesy of Elia M. Pestana-Knight, MD, Cleveland Clinic Foundation.



**Figure 47.** Pediatric EEG: photic driving response at 10-Hz flash frequency in a 7-year-old girl. Figure courtesy of Elia M. Pestana-Knight, MD, Cleveland Clinic Foundation.

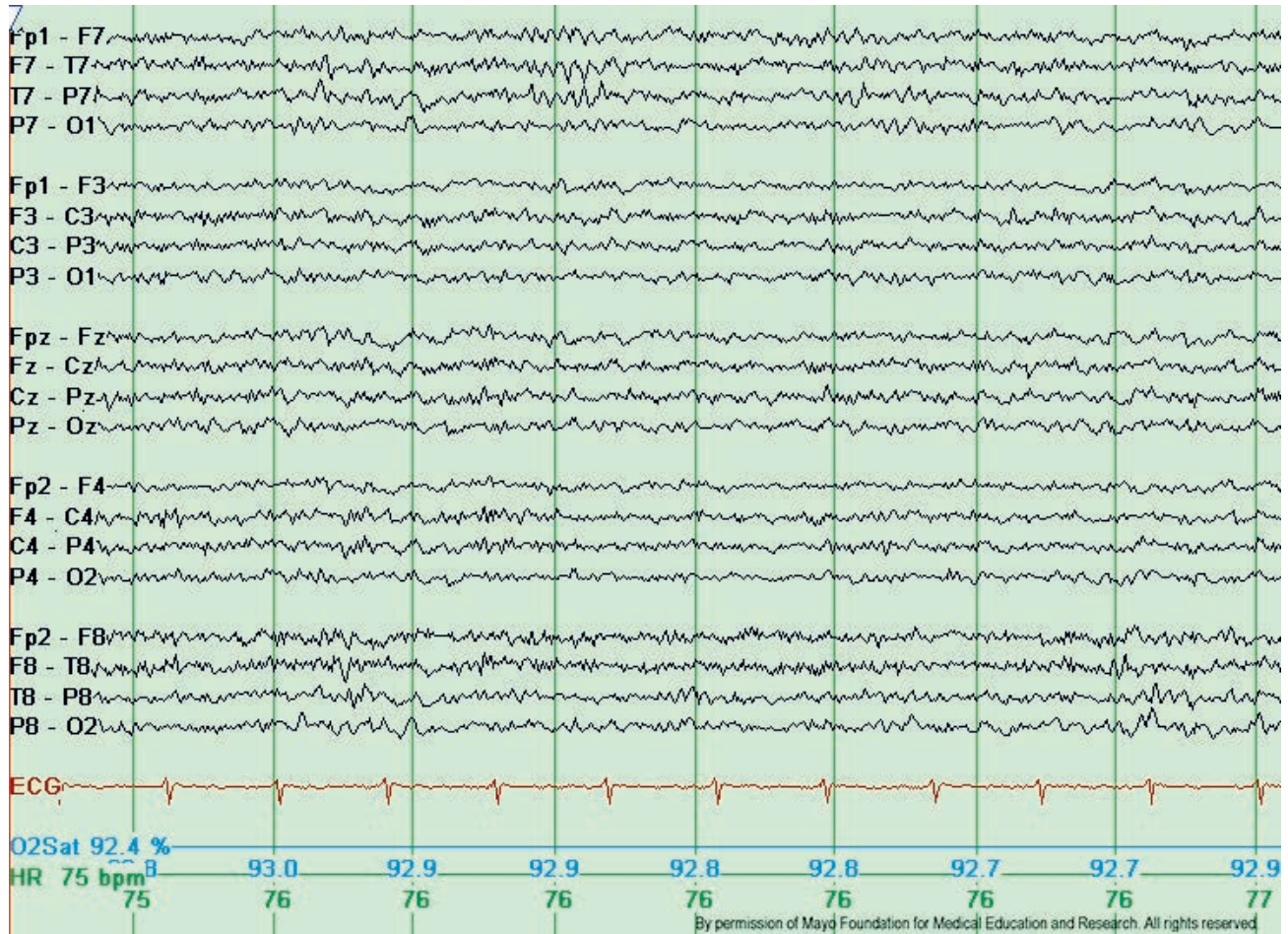
although absence of driving is not abnormal at any age. Lambda waveforms elicited by complex pattern viewing also appear in preschool-aged children between 3 and 5 years of age and become more frequent from 6 to 12 years of age. At the same time, POSTS appear during sleep, and more prominent photic driving responses at faster flash frequencies emerge. Anterior rhythmic theta bursts of 6- to 7-Hz frequency are often seen, especially during drowsiness in the mid-teenage years between 13 and 16, as prominent hypnagogic hypersynchrony begins to diminish.

### Benign Variants in the EEG

Accurate recognition and distinction of benign variants in the EEG are essential to avoid over interpretation of such findings as epileptiform, and subsequent errant diagnosis of epilepsy. The range of benign variants includes wicket waves, rhythmic mid-temporal theta of drowsiness (RMTD or RTTD), benign small sharp spikes (BSSS, sometimes denoted BSST for benign small sleep transients), 14 and 6 positive spikes, 6-Hz “phantom” spike and wave, subclinical rhythmic EEG discharge of adults (SREDA), and the midline theta rhythm of Ciganek.



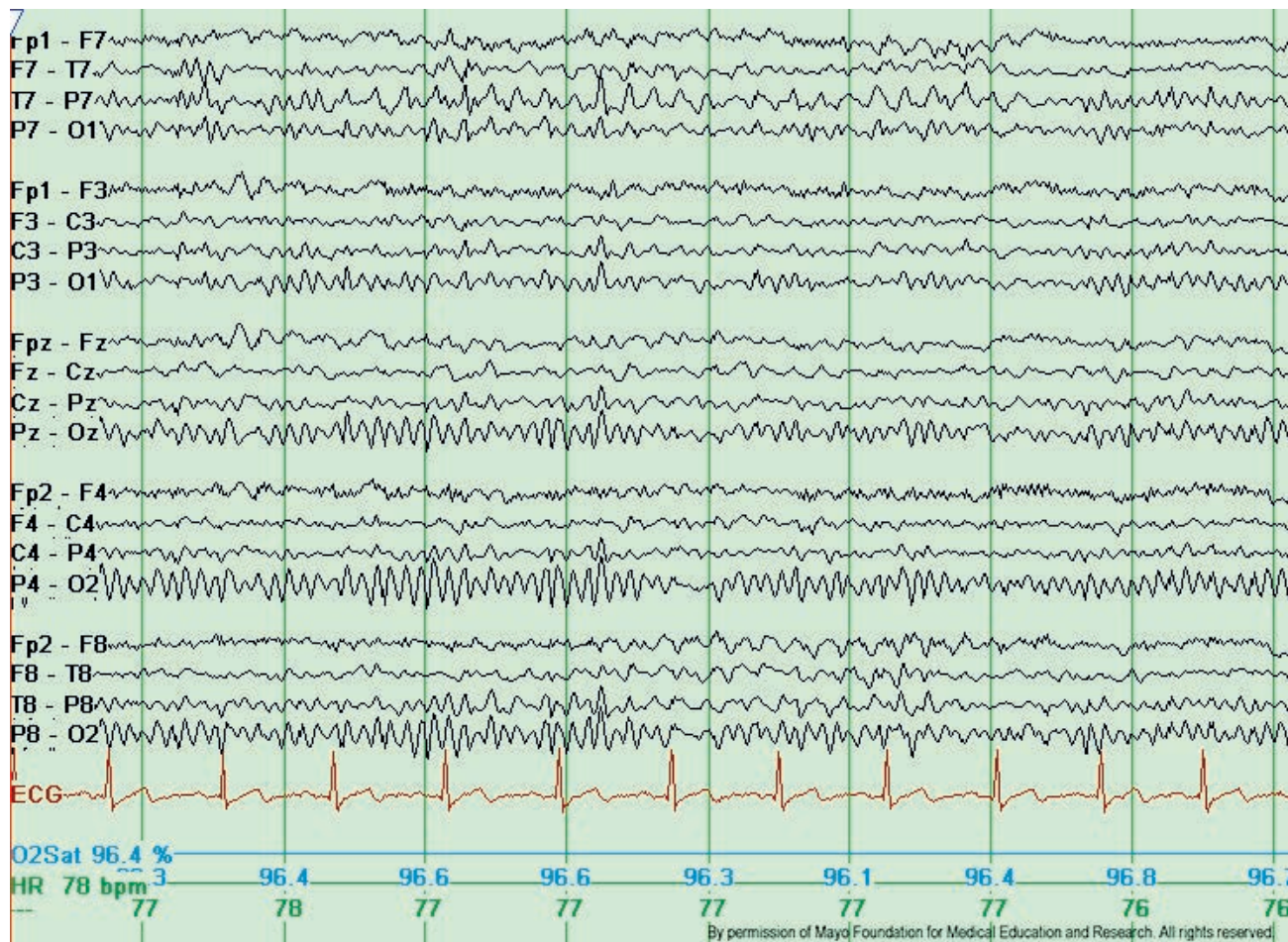
Wicket waves are by far the most commonly encountered benign variant and a frequent source of overinterpretation and mistaken diagnosis of epilepsy on EEG. Wicket waves are single waveforms that occur in brief trains or clusters. In distinction to true epileptiform spikes, however, wicket waves have a more arciform appearance and earn their name therefore by looking like "wicket" (see Figure 48). Wickets are most frequent in the temporal regions, occurring bilaterally or unilaterally, have a frequency of 6 to 11 Hz and amplitude ranging from 60 to 200  $\mu$ V. Wickets are not accompanied by after-going slow waves and are mainly seen in older adults during drowsiness and light sleep, becoming apparent when the alpha and other wakeful patterns drop out.



**Figure 48.** Typical wicket waves. Note the arciform appearance, lack of after-going slow wave, and lack of background disruption or disturbance. The wicket waves are seen in the left temporal region with phase-reversal at T7 in seconds 3 and 4 of the tracing, longitudinal bipolar montage. Copyright 2013. Mayo Foundation for Medical Education and Research. All rights reserved. Figure courtesy of Jeffrey W. Britton, MD.



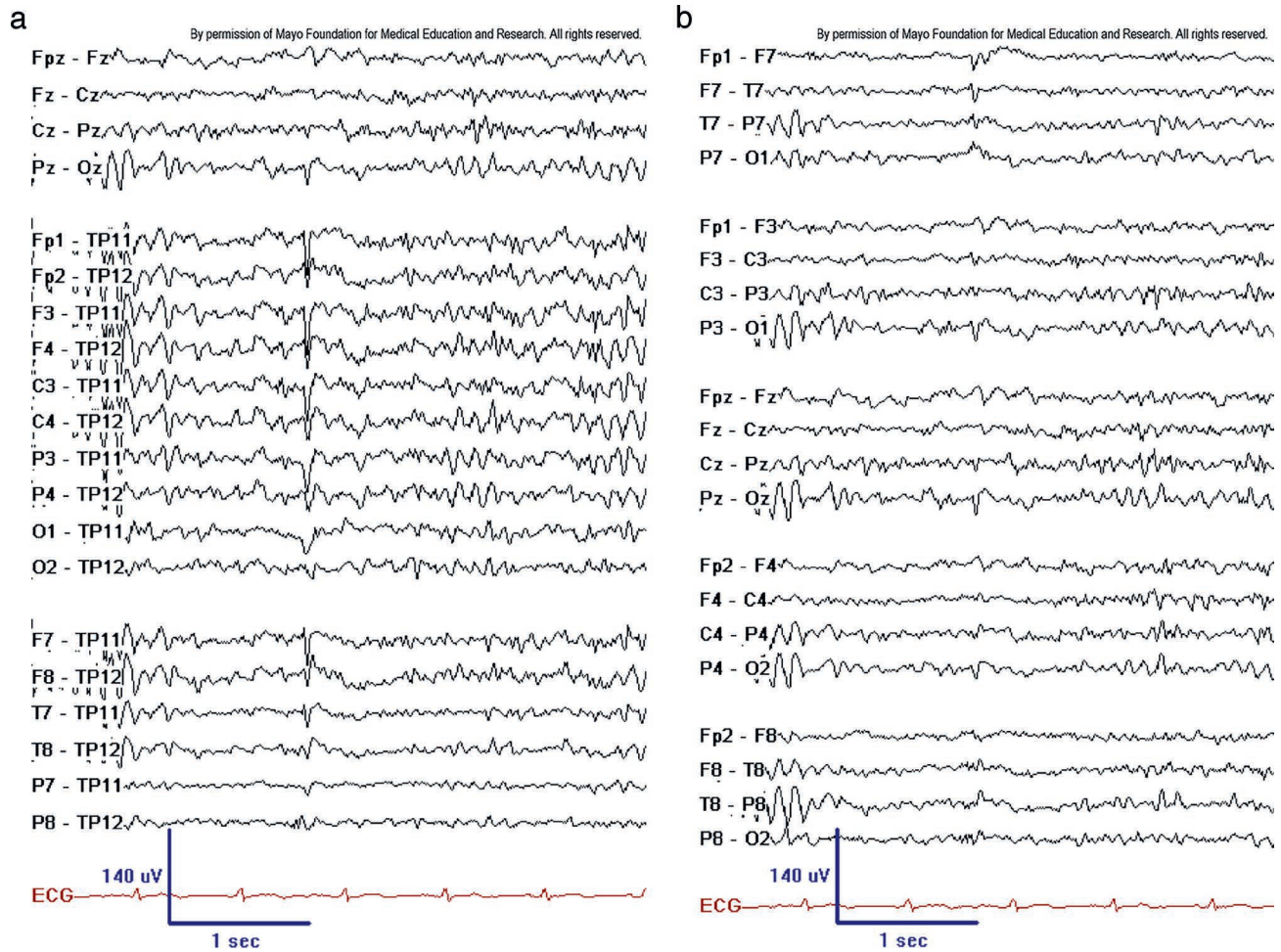
A common normal variant finding, often mistaken for pathological activity during drowsiness, is RMTD. This activity was previously known as “psychomotor variant” because of the similarity of this phenomenon to the focal rhythmic activity of a seizure discharge (Figure 49). In contrast to focal epileptiform activity, RMTD rhythms usually have a flat-topped or notched morphologic appearance, thought to result from a combination of two more different frequencies in the alpha and theta range. Also distinct from epileptiform activity, RMTD rhythms do not evolve or spread to other electrode sites over time and are typically very short-lived, lasting on the order of 5 to 15 seconds in duration. In addition, RMTD tends to become less prominent during increasing levels of drowsiness and disappears during light NREM sleep, which is the opposite for epileptiform activity. RMTD may be either unilateral or bilateral and independent.



**Figure 49.** Rhythmic temporal theta of drowsiness. Bipolar left greater than right, longitudinal bipolar montage. Noted are notched rhythmic waveforms localized to the temporal regions, some of which are sharply contoured. This rhythm was formerly referred to as the “psychomotor variant,” which can be differentiated from an epileptiform discharge by its relatively monomorphic appearance, lack of clinical accompaniment, and lack of spatiotemporal evolution. Copyright 2013. Mayo Foundation for Medical Education and Research. All rights reserved. Figure courtesy of Jeffrey W. Britton, MD.



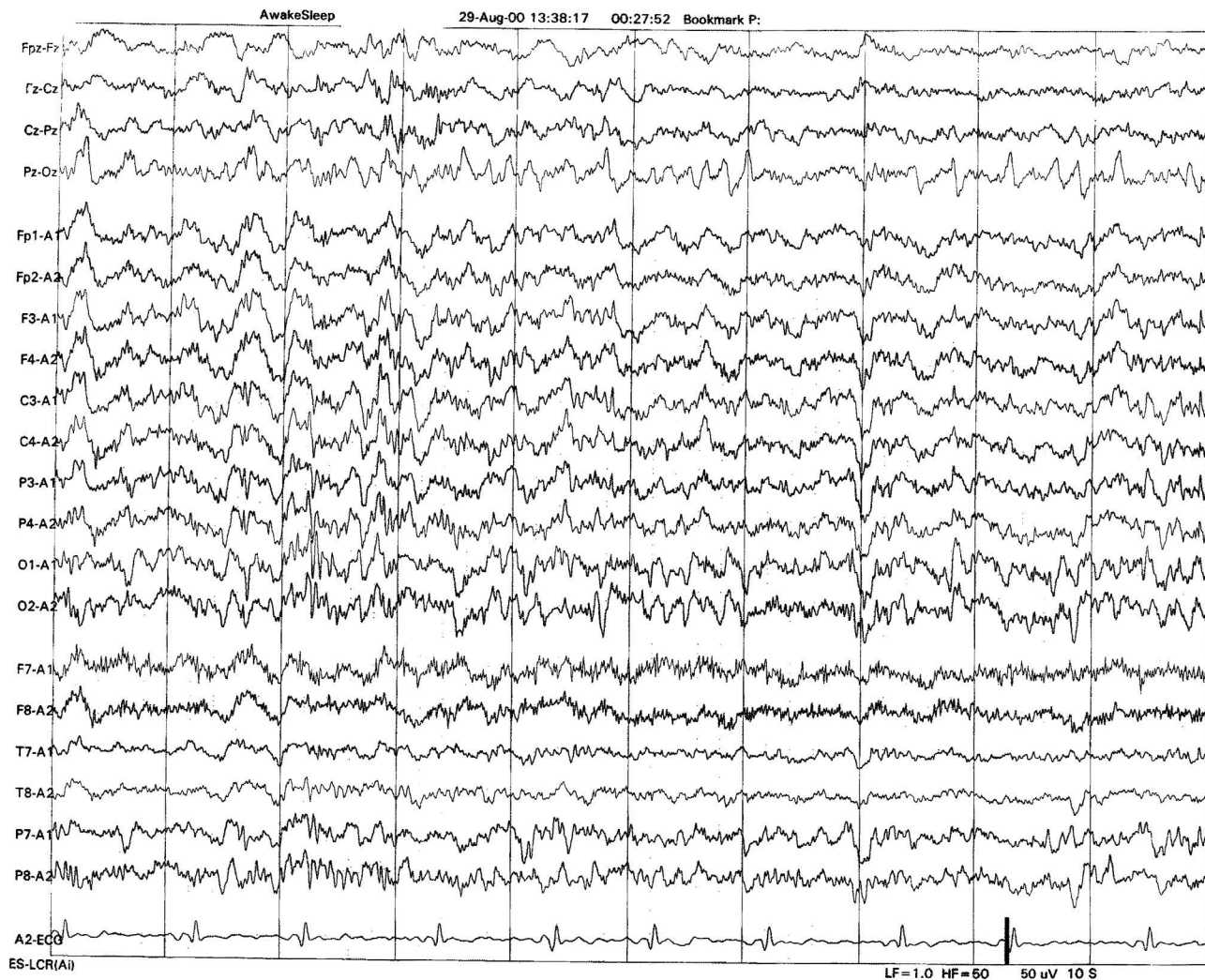
BSSS are monophasic or biphasic spikes with steep ascending and descending limbs (see Figure 50). BSSS occur mainly during drowsiness and light sleep in the adult age group and may have a wide electrographic field of distribution but are best seen in temporal and ear leads. Distinguishing small sharp spikes from more pathologic temporal spike or sharp-wave discharges is usually not difficult; BSSS have a characteristic sharp ascending and descending limb morphology of the waveform, an exquisitely brief duration and low amplitude, often bilateral distribution, and lack of a disturbance of the background or associated focal abnormality in the EEG. Another distinction between BSSS and epileptiform spikes is the tendency of BSSS to disappear during deeper levels of sleep, while interictal spikes are often further activated during deeper sleep and often occur during wakefulness as well (while BSSS may occur in drowsy wakefulness, they do not occur during periods of normal vigilance).



**Figure 50.** BSSS (aka BETS) on ipsilateral ear reference (left) and longitudinal bipolar montage (right). Note steep descending slope of low-amplitude spike and small after-coming slow wave, particularly at T7 to TP11. BSSS are a common feature in adult EEGs during drowsiness and sleep. Note the typical step descending waveform limb and lack of background disturbance. Copyright 2013. Mayo Foundation for Medical Education and Research. All rights reserved. Figure courtesy of Jeffrey W. Britton, MD.



The benign variants, 14 and 6 positive spikes, occur in 20 to 60 percent of the normal population, predominantly in adolescents and younger adults aged 12 to 20 years, especially during drowsiness and light NREM sleep. The 14 and 6 positive spikes are so named because of their tendency to occur in bursts at a rate of 14 Hz or 6 to 7 Hz (range, 0.5–1 second; see Figure 51). The 6-Hz positive spikes predominate in very young infants (under 1 year old) and in some adults. The 14-Hz positive spikes occur more frequently in adolescents. These bursts typically consist of “negative” arciform waveforms located over the posterior temporal head



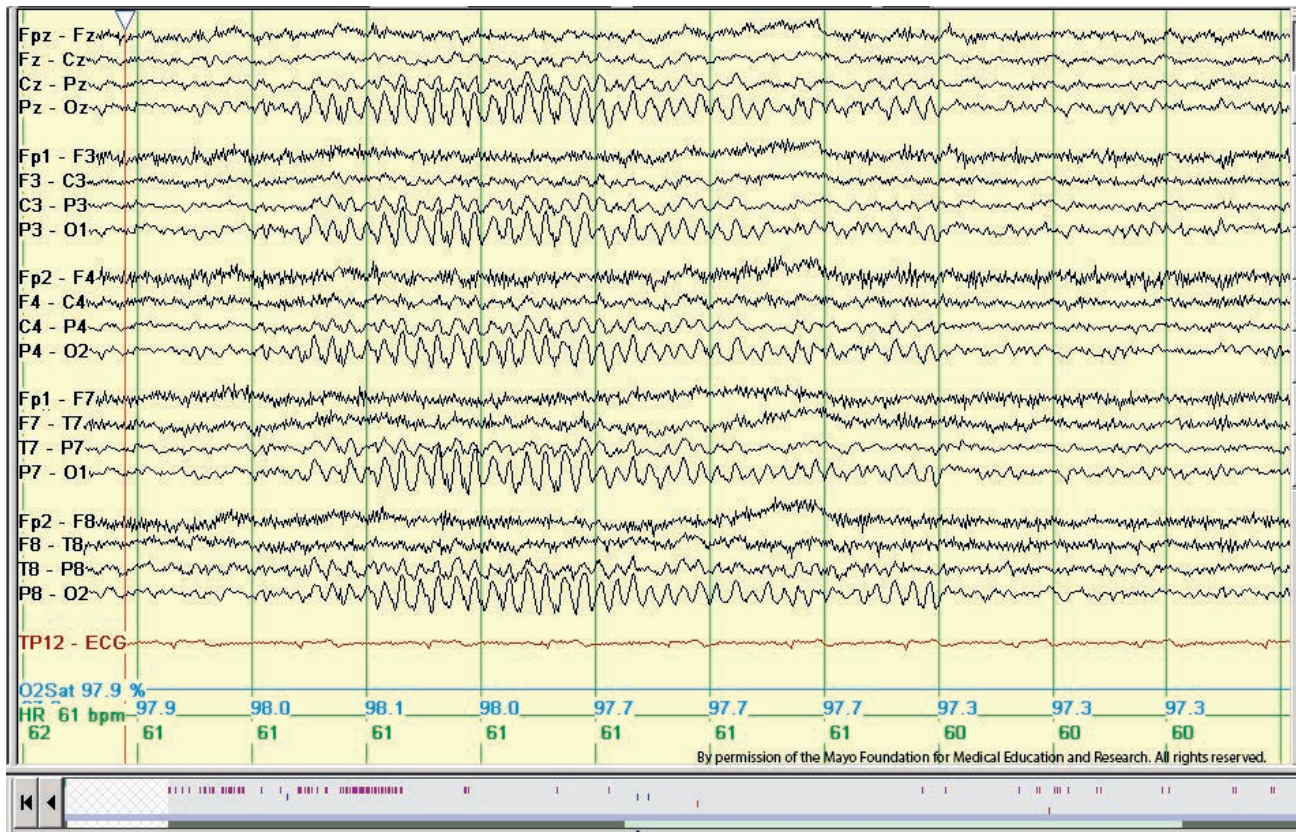
© American Epilepsy Society

**Figure 51.** Example of 14- and 6-Hz positive spikes in a 13-year-old girl. Note the 14-Hz positive spiky waveforms best appreciated over the posterior temporal and biposterior head regions, best seen in the third second.



regions, with alternating “positive” spiky components, and may be independent over the two hemispheres. The 14 and 6 positive spikes are best appreciated by using long interelectrode distances and referential montages.

The 6-Hz phantom spike and wave (see Figure 52) usually have a mitten-like morphology, with a very small or absent spike component, and a more apparent slow wave. The 6-Hz phantom spike and wave pattern may be observed in both adolescents and adults and is another pattern seen predominantly during drowsiness and light NREM sleep, vanishing in N3 and REM. The 6-Hz phantom spike and wave are diffuse or, alternatively, anteriorly or posteriorly predominant bursts.



**Figure 52.** Example of 6-Hz “phantom” spike and wave in an adolescent patient. There are bilaterally symmetrical diffuse tiny spikes with prominent wave components (“mitten-like” morphology) in seconds 3 through 6 below. Longitudinal bipolar montage. This is the posterior variant sometimes referred to as the FOLD (female occipital low-amplitude drowsiness) subtype. An anterior variant known as WHAM (wake high-amplitude male) subtype has also been described (not shown). Copyright 2013. Mayo Foundation for Medical Education and Research. All rights reserved. Figure courtesy of Jeffrey W. Britton, MD.





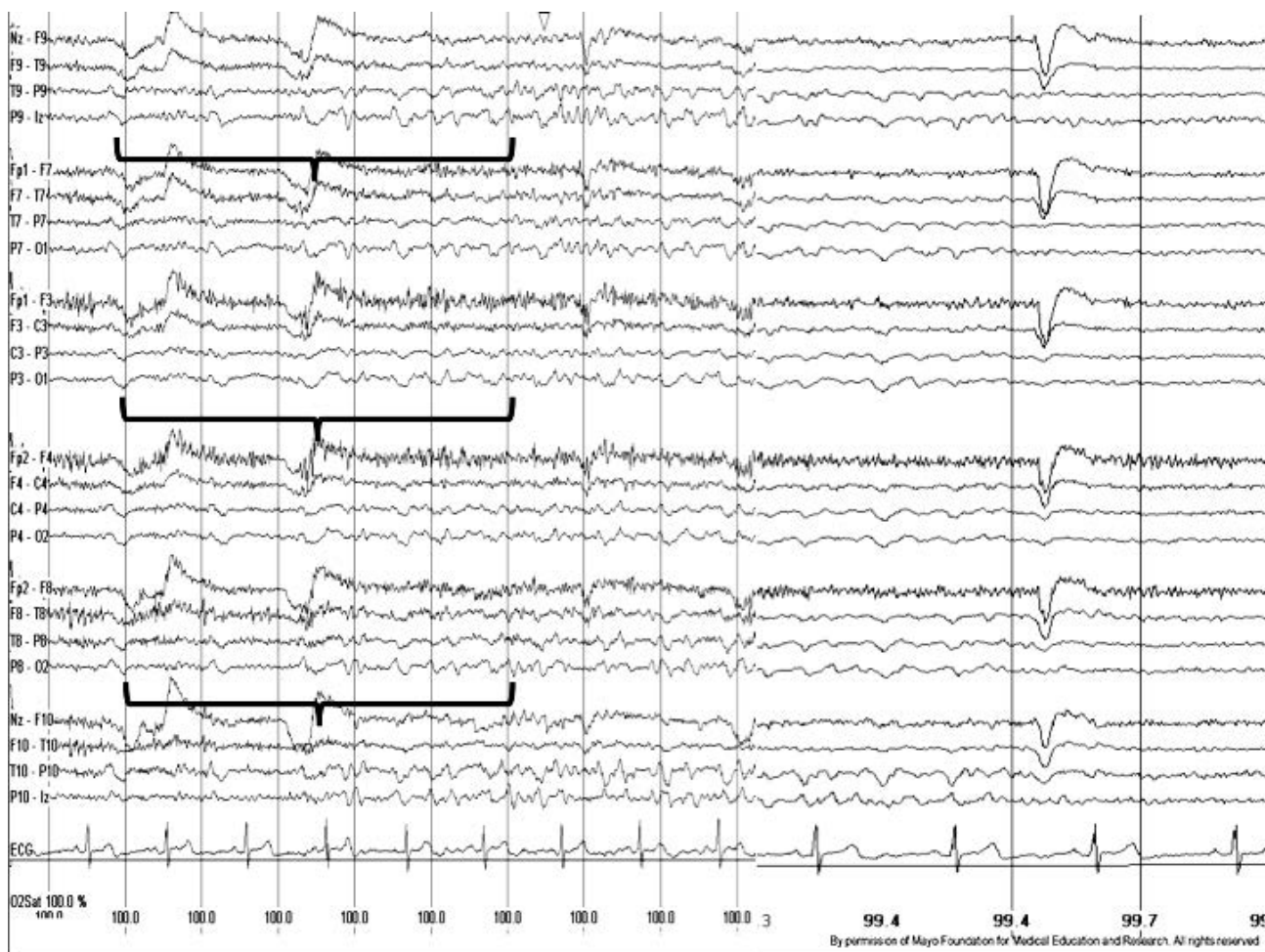
SREDA (aka SCREDA) is another benign variant pattern often mistaken for a subclinical electrographic seizure. SREDA typically occurs in normal older and elderly adults, especially over the age of 50 and is characterized by a sharply contoured theta frequency (between 5 and 6 Hz) discharge most often seen diffusely but maximally over the parietal and posterior head regions, and it may last a few seconds to approximately 1 or 2 minutes in duration. Again, SREDA is seen more during drowsiness. Typically, there may be mild frequency evolution but no spatial or topographic evolution to this EEG discharge (i.e., no spread to other brain regions), and unlike most partial seizures, there is no clinical accompaniment if response or interaction testing is performed. Sometimes SREDA has an abrupt offset, which may help distinguish this activity from partial seizures (see Figure 53).

A relatively rare benign variant again often confused with seizure activity is the midline theta rhythm (midline theta of Ciganek). Previously thought to potentially correlate with underlying epilepsy, the rhythm appears to be another nonspecific benign rhythm of drowsiness. Prominent theta frequency activity is seen confined to the vertex and midline derivations during drowsiness.

**The Abnormal EEG**

*Focal and Generalized Slowing and Significance*

EEG can provide evidence for underlying diffuse or focal cerebral dysfunction through demonstration of background slowing. The two main types of slowing are focal and generalized slowing. As previously discussed, generalized background slowing in the theta and delta frequency ranges is a normal finding on EEG when it represents developmental slowing in children, adolescents, and some young adults or the evolution of drowsiness and sleep activity. However, when there is intermittent or persistent focal slowing seen consistently over one head region, or persistent, unvarying, and unreactive focal or generalized slow wave activity in



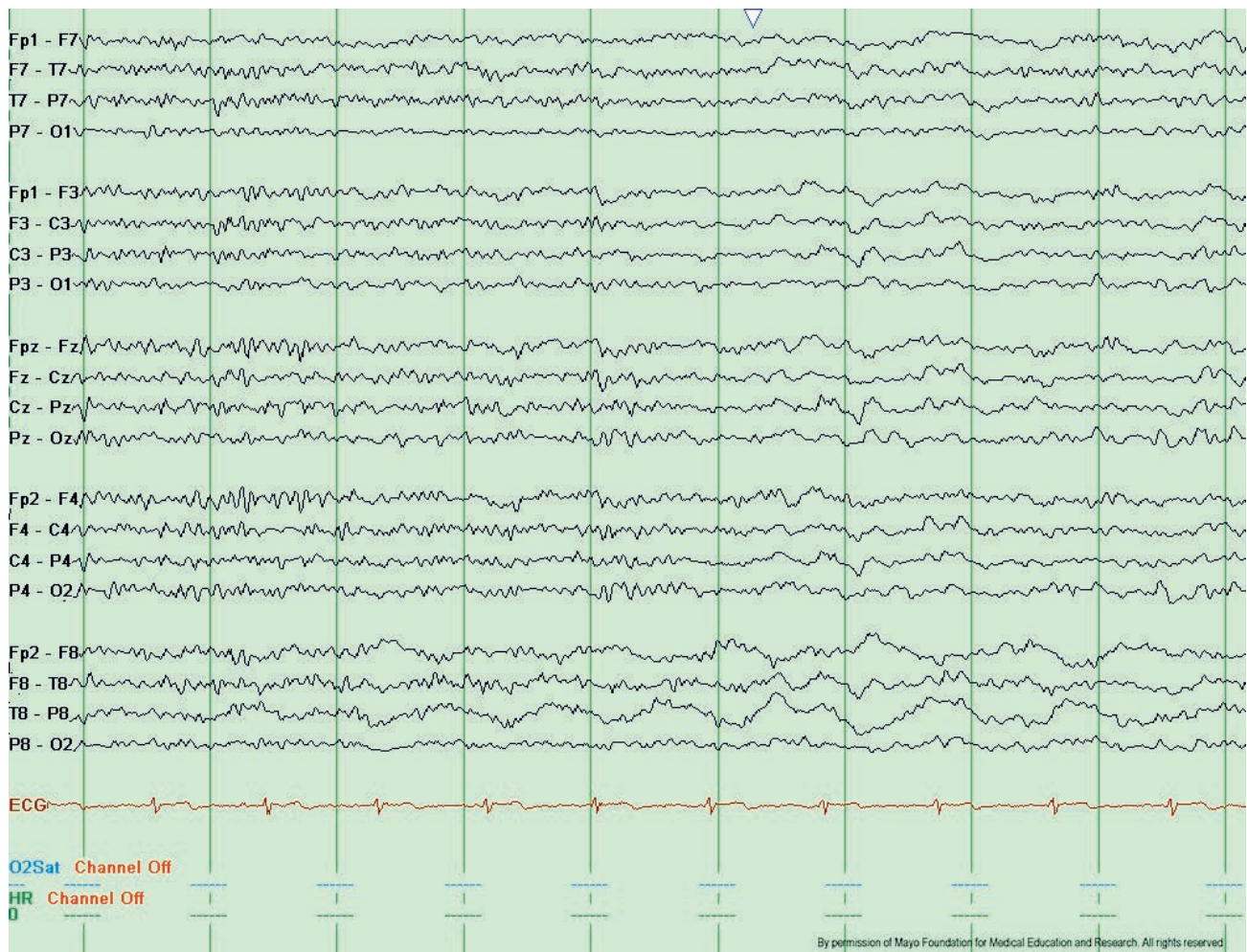
**Figure 53.** SREDA pattern, longitudinal bipolar montage. Black brackets show onset of periodic posterior-predominant sharply contoured waveforms, becoming rhythmic, then resolving at latter portion of figure. This normal elderly adult was asymptomatic during the discharge and showed no sign of behavioral or response alteration. Copyright 2013. Mayo Foundation for Medical Education and Research. All rights reserved. Figure courtesy of Jeffrey W. Britton, MD.



a vigilant adult patient, this slow wave activity should be considered pathologic and indicates corresponding focal or generalized cerebral dysfunction or both.

### Focal Slowing

Focal slow wave activity on the EEG is indicative of focal cerebral pathology of the underlying brain region. Slowing may be intermittent or persistent, with more persistent or consistently slower activity generally indicating more severe underlying focal cerebral dysfunction. A variety of etiologies for focal cerebral dysfunction may be seen. When intermittent, focal slowing may indicate unveiling of subtle focal cerebral dysfunction owing to the effects of a sedating or hypnotic medication, although usually medication-induced slowing is generalized in nature. Focal brain lesions of a variety of causes to cortex, underlying white matter, or both may induce focal slowing. The various causes are too numerous to be comprehensive, but common examples include transient or permanent ischemia resulting from stroke, brain hemorrhage, tumors, traumatic injury, malformations of cortical development, nonstructural focal cerebral dysfunction corresponding to a focal epileptic focus, focal involvement of the cortex by neurodegeneration, arteriovenous malformations, and focal brain infection caused by bacterial cerebritis or viral encephalitis. See Figure 54 for an example of focal temporal regional slowing, which also shows a “breach rhythm,” with focally elevated background amplitude as a result of a skull defect and previous surgery in this area.

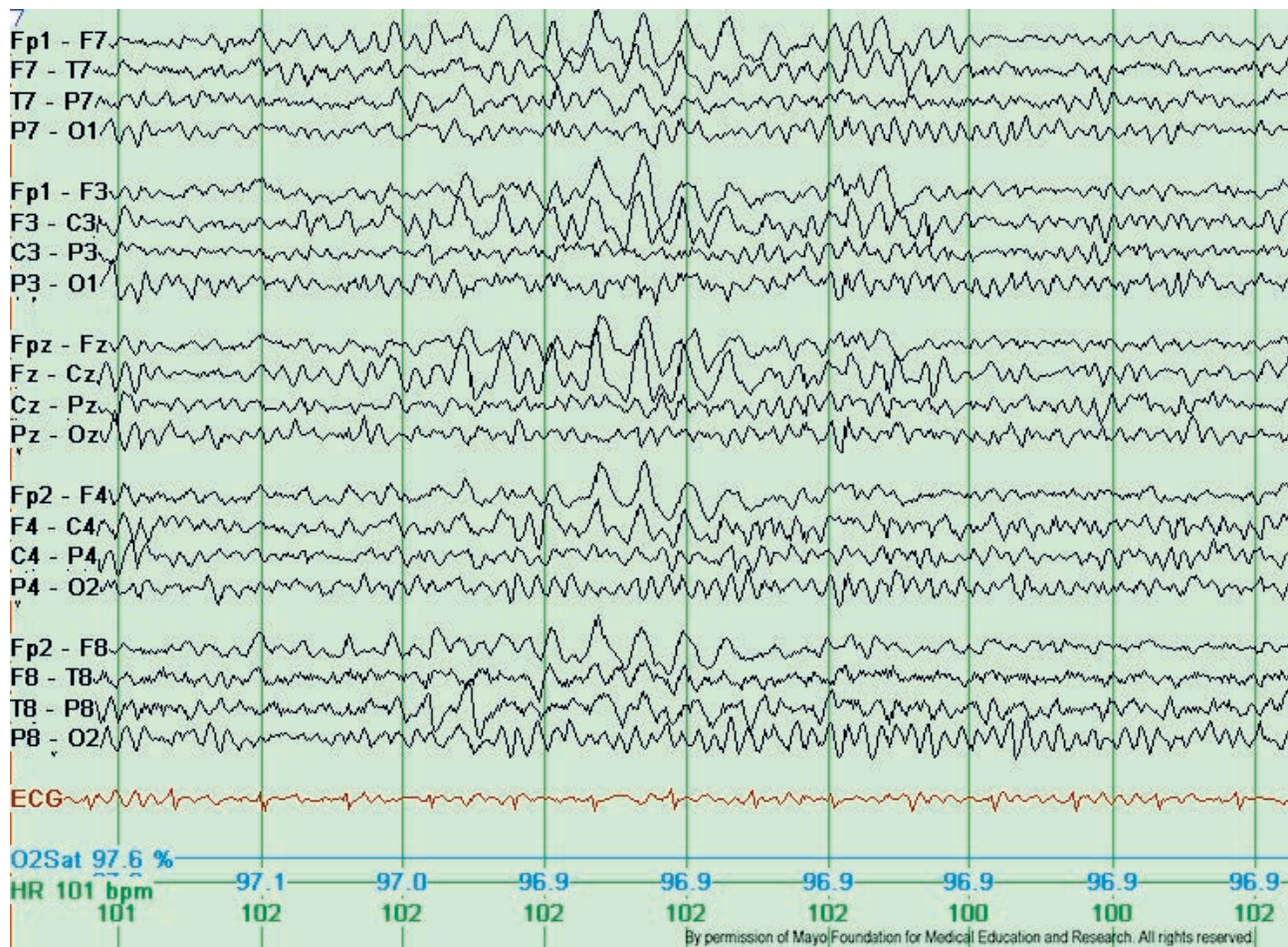


**Figure 54.** Focal slowing over the right temporal region as the result of a right temporal brain tumor in a 35-year-old man. Note the focal delta frequency slowing in the right temporal region as compared with the homologous normal right temporal region. Longitudinal bipolar montage. Copyright 2013. Mayo Foundation for Medical Education and Research. All rights reserved. Figure courtesy of Jeffrey W. Britton, MD.

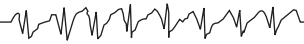

*Generalized Slowing*

Generalized background slowing indicates diffuse cerebral dysfunction, which, similar to focal slowing, is also not specific as to cause. Several different etiologies may provoke generalized background slowing, including the effects of sedative centrally acting medications, neurodegenerative disorders, a widespread neurodevelopmental process, hydrocephalus, metabolic or toxic encephalopathy, CNS infectious disorders such as meningoencephalitis, or even a focal midline structural lesion involving deep midline brainstem, diencephalic structures, or both (producing a phenomenon known in older EEG literature as a “distance or projected rhythm,” which often selectively involves the anterior or bifrontal areas and produces a pattern known as frontal intermittent rhythmic delta activity, or FIRDA). See Figure 55 for an example of generalized EEG slowing resulting from a metabolic encephalopathy. Specific examples of clinical phenomena associated with generalized slowing on the EEG are discussed below.

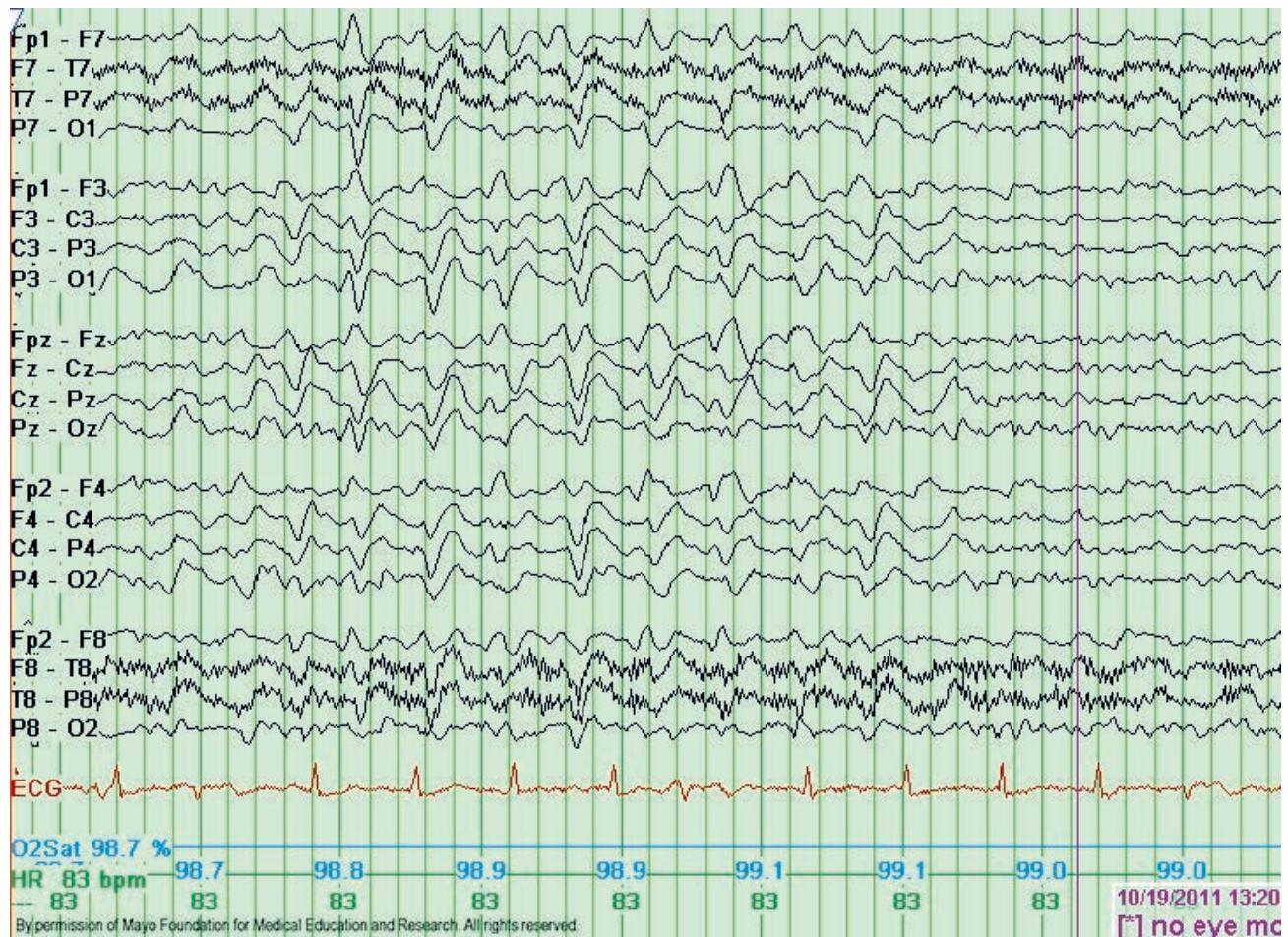


**Figure 55.** FIRDA pattern with a slightly slower theta EEG background in an elderly man with a metabolic encephalopathy. Periods of well-formed posteriorly dominant alpha activity are still also seen. Longitudinal bipolar montage. Copyright 2013. Mayo Foundation for Medical Education and Research. All rights reserved. Figure courtesy of Jeffrey W. Britton, MD.

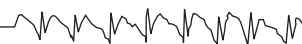

### Encephalopathy/Delirium

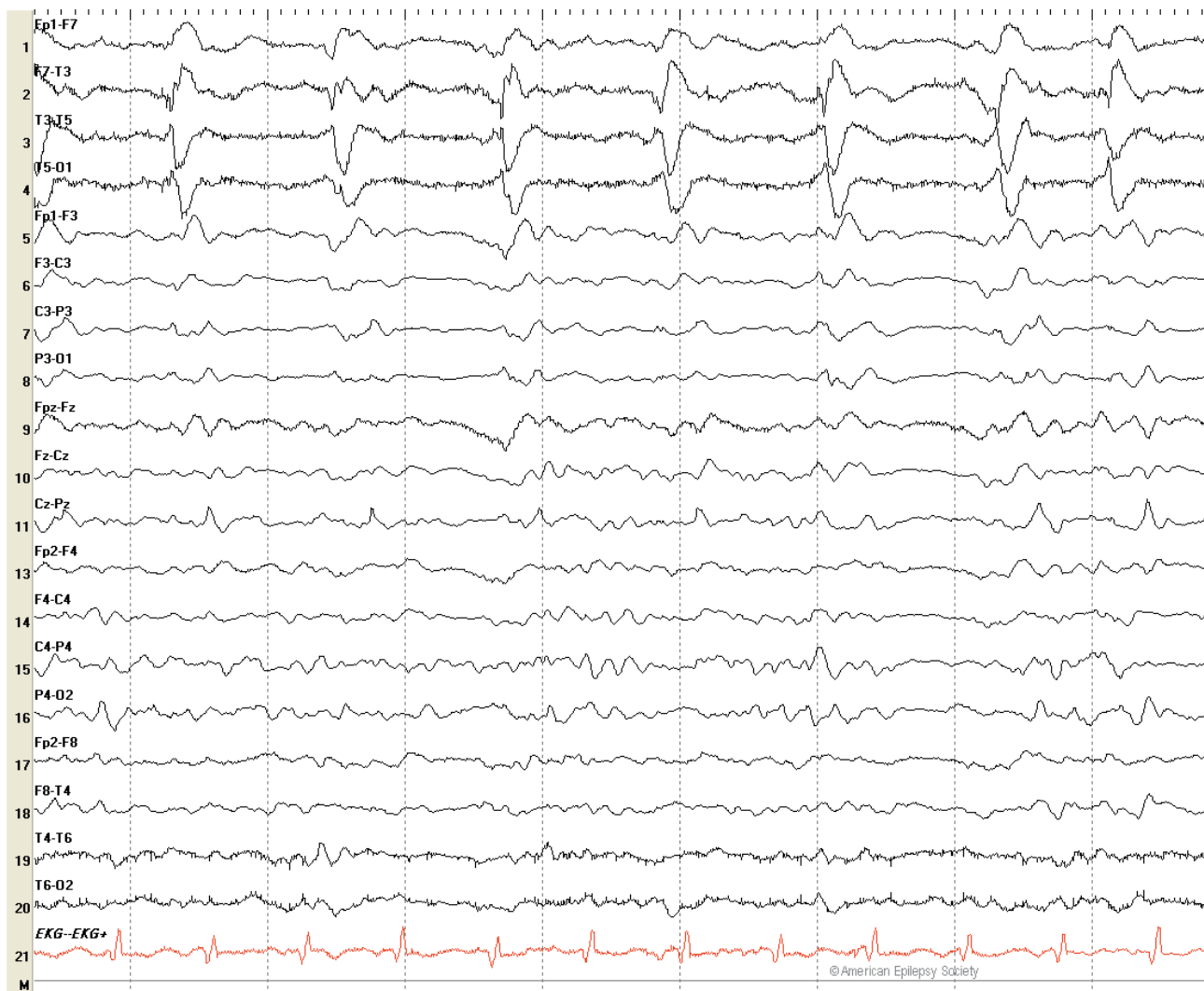
Delirium, also known as encephalopathy, is a reversible generalized confusional state induced by a systemic disorder. The clinical phenomena of confusion in a delirious state may closely resemble a complex partial or atypical absence seizure, involving blank staring with disorientation, inattention, and variable responsiveness, stupor with reduced vigilance, and unusual movements including myoclonic jerks. Encephalopathic patients may have acute symptomatic seizures, resulting in diagnostic confusion. EEG in a delirious patient may show either diffuse nonspecific nonepileptiform background slowing, or even epileptiform-appearing patterns such as triphasic waveforms (see Figure 56 for triphasic wave pattern), which are most common in patients with underlying associated hepatic or renal impairment or both, and resultant encephalopathy, although similar patterns may be induced by drug intoxication or adverse effects or other nonlesional causes of severe generalized cerebral dysfunction.



**Figure 56.** Generalized triphasic wave pattern and slowing in a 72-year-old man with hepatic encephalopathy. Longitudinal bipolar montage. Waveforms show characteristic anterior to posterior lag (see waveform marked by black arrow). Copyright 2013. Mayo Foundation for Medical Education and Research. All rights reserved. Figure courtesy of Jeffrey W. Britton, MD.



A distinctive pattern, which may be seen in some encephalopathic or even comatose patients, is lateralized periodic discharges (LPDs, formerly known as PLEDS), which may be focal, unilateral hemispheric, or even bilateral and independent. While LPDs are consistent with a heightened epileptogenic potential and may accompany patients having seizures (or even occur as a postictal and, somewhat controversially, on occasion as an ictal seizure pattern itself in prolonged status epilepticus), they may occur in a patient who is not having seizures when there is an acute destructive process involving the gray-white matter junction, especially in the context of herpes simplex virus (HSV) encephalitis, or following massive hemispheric ischemic infarction. See Figure 57 for an example of LPDs in HSV encephalitis.



**Figure 57.** LPDs over the left temporal region in a 75-year-old encephalopathic man with acute HSV encephalitis. Similar findings can be seen following acute ischemic infarction. Copyright 2013. Mayo Foundation for Medical Education and Research. All rights reserved. Figure courtesy of Jeffrey W. Britton, MD.



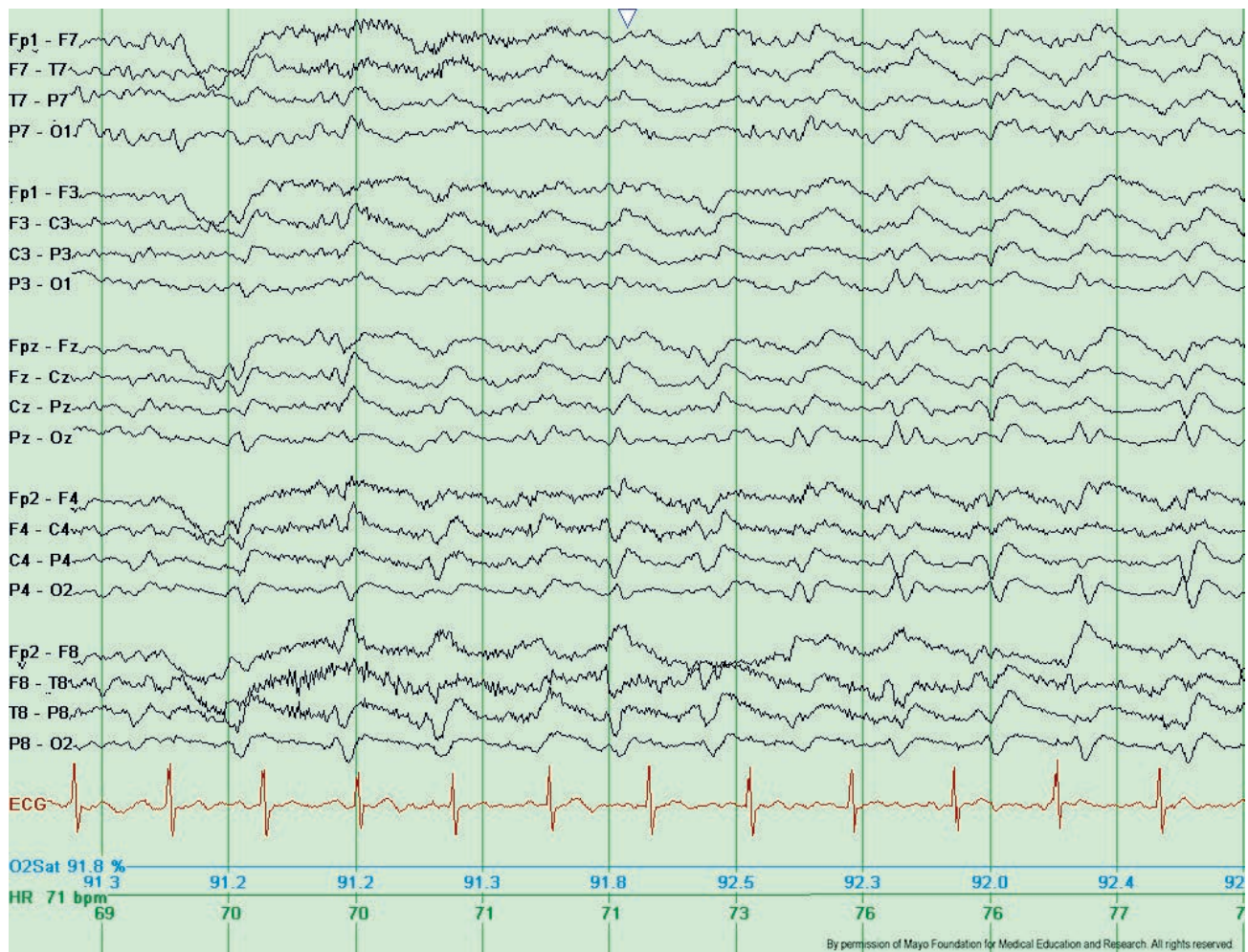
### Dementias

Early in the course of a slowly progressive neurodegenerative dementia, such as Alzheimer disease, the EEG may be normal during wakefulness and sleep. Later, as the disease progresses, there is frequently mild generalized background slowing. Focal slowing may also be seen.

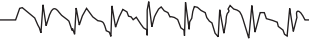A distinctive finding in a subacute, progressive dementia caused by prion disease (Creutzfeldt-Jakob disease, CJD) is the presence of periodic sharp-wave activity. While the EEG may be normal early in the course of CJD, by approximately the second to third month of symptoms, especially at the point of evolution of clinically overt myoclonus, periodic sharps appear, at times subtle or confined to a focal region (especially posteriorly); but with full-blown dementia and myoclonus, periodic sharp waves of 1- to 2-Hz frequency appear in a generalized distribution (see Figure 58 below).

### Coma

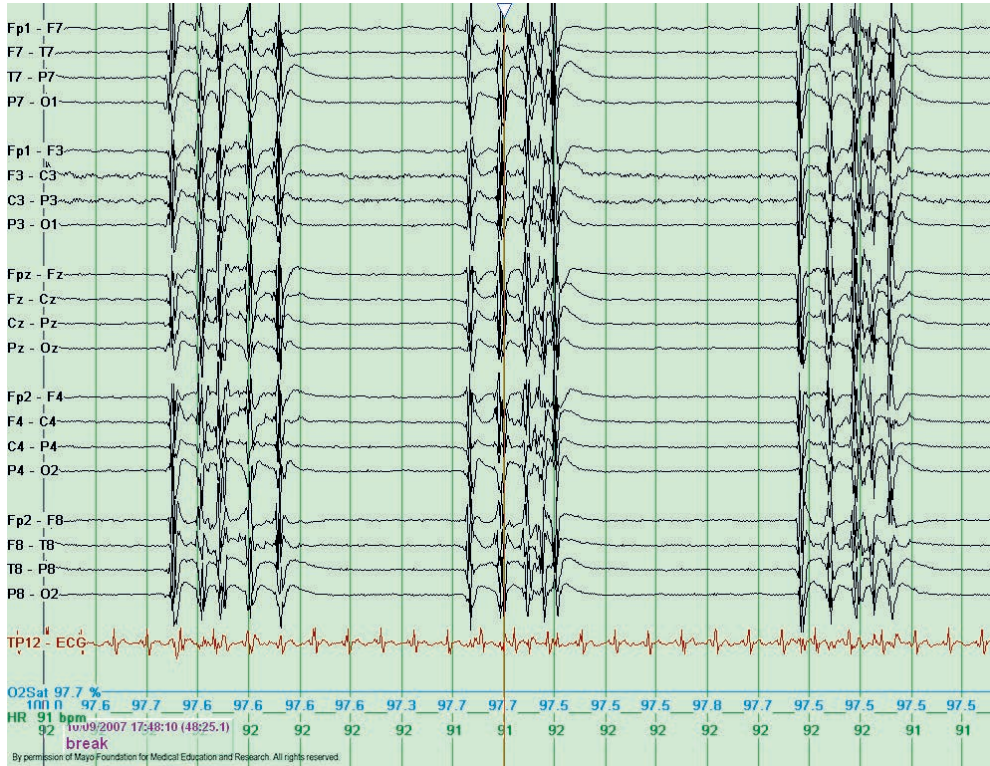
Coma is a clinical state of eyes closed, irreversible unresponsiveness (at least temporarily), as opposed to sleep in which the unresponsive state is readily reversible to wakefulness. The hallmark of coma patterns is their lack of variability and relative (or absolute) lack of reactivity. Reactivity of the background (background frequency speeding up, or changing in reaction to physical or auditory stimuli) is a sign of relative integrity and considered relatively more favorable.




**Figure 58.** Periodic sharp wave complexes in Creutzfeldt-Jakob disease. Generalized periodic sharp waves are seen in a 65-year-old man with rapidly evolving dementia and myoclonus later proven to have CJD. Longitudinal bipolar montage. This recording was obtained 3 weeks after symptom onset. The waveforms in this patient are most prominent over the right hemispheric region, which correlated with the patient's MRI findings and are triphasic in morphology. Copyright 2013. Mayo Foundation for Medical Education and Research. All rights reserved. Figure courtesy of Jeffrey W. Britton, MD.



Several common EEG coma patterns have been described. The two patterns that are considered to have the worst prognosis for recovery following anoxic-ischemic encephalopathy are burst suppression (see Figure 59) and alpha coma, with other patterns considered intermediate (theta coma, Figure 60) or even favorable (spindle coma). However, prognostication should certainly not rely upon EEG alone, as the findings must be integrated into the clinical context and other ancillary tests such as neuroimaging.



**Figure 59.** Burst-suppression coma pattern following anoxic-ischemic brain injury as a result of cardiopulmonary arrest in a 58-year-old man with status myoclonus. Note the intervals of spike, polyspike, and slow wave discharges with intervening suppressed background of varying duration. Longitudinal bipolar montage. Copyright 2013. Mayo Foundation for Medical Education and Research. All rights reserved. Figure courtesy of Jeffrey W. Britton, MD.



**Figure 60.** Theta coma pattern following heroin overdose in a 44-year-old comatose man post cardiac arrest. Note the relatively invariant theta and delta frequency slowing (predominantly theta) in a generalized distribution and lack of spontaneous variability in the background. To establish the diagnosis of theta coma or any of the coma patterns (e.g., alpha, spindle, and beta coma), one must demonstrate through stimulation of the patient that the pattern is invariant and does not alter in response to external stimuli. Longitudinal bipolar montage. Copyright 2013. Mayo Foundation for Medical Education and Research. All rights reserved. Figure courtesy of Jeffrey W. Britton, MD.

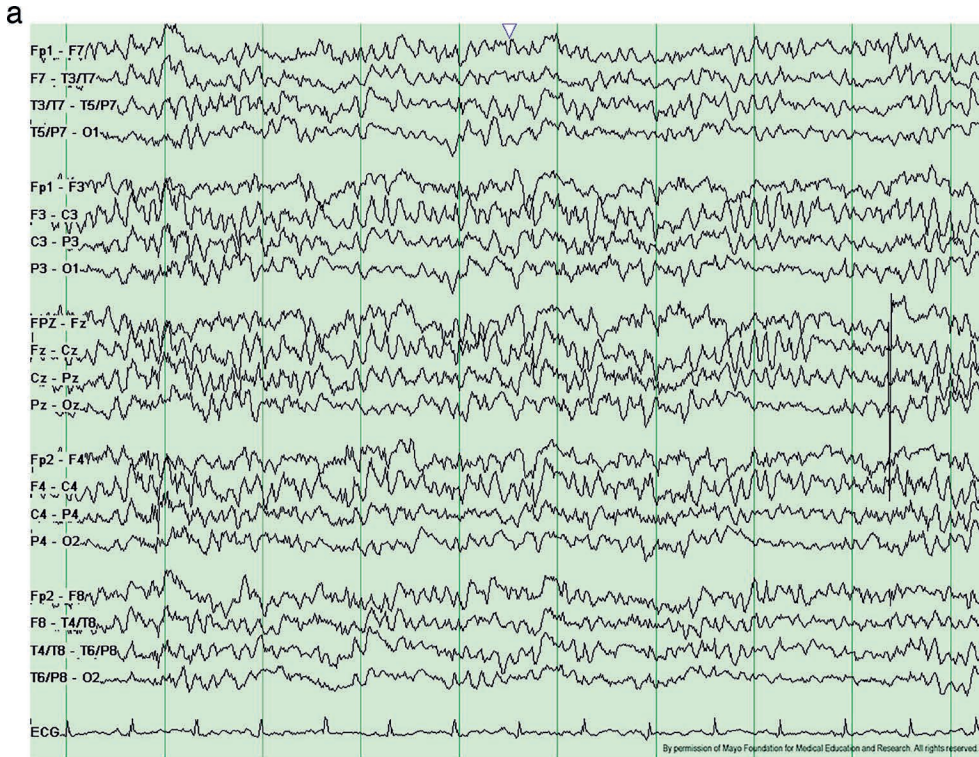


By permission of Mayo Foundation for Medical Education and Research. All rights reserved.

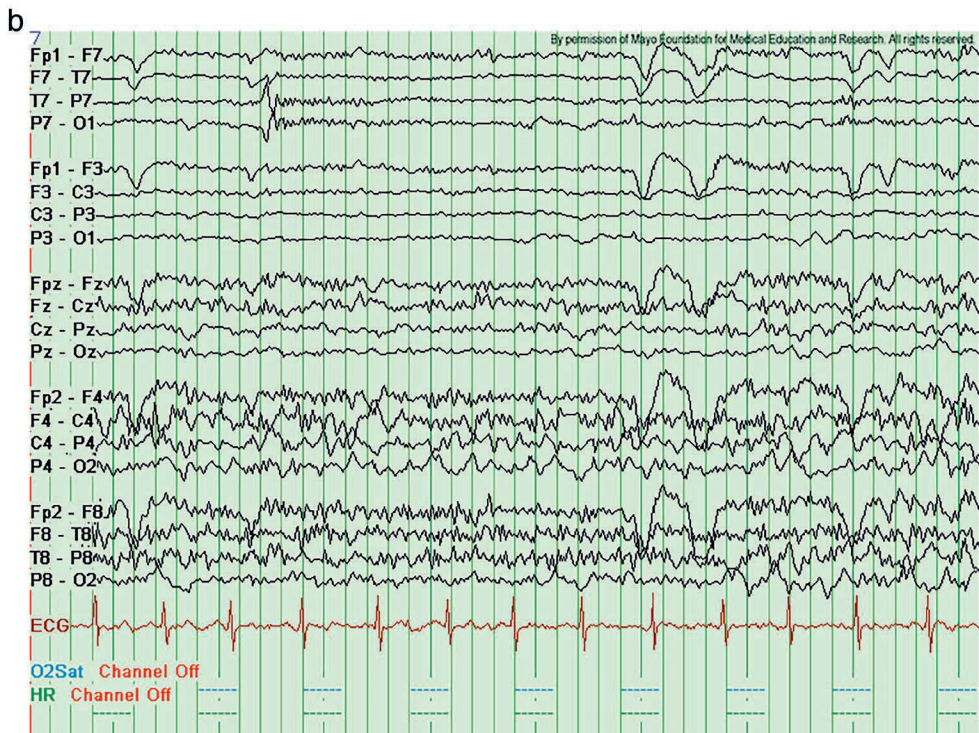


**Anesthetic Patterns**

The EEG is often useful during surgical procedures to follow the depth of anesthesia and is particularly useful during neurovascular surgeries in which there is risk for thromboembolism and otherwise covert occurrence of cerebrovascular ischemia, such as carotid endarterectomy surgeries. Figure 61 below demonstrates a typical anesthetic pattern, characterized by predominantly slower and some intermixed anteriorly dominant fast activity. If unilateral increased background slowing, reduction of voltage, or suppression occur, this may be helpful to prompt adjusting the duration of clamping or placing a shunt.



**Figure 61.** Generalized anesthetic pattern in patient undergoing routine carotid endarterectomy. Note diffuse anteriorly predominant alpha frequencies and triangular waveforms, superimposed on a generalized 0.5- to 1.0-Hz slow-frequency baseline. The findings in the first example (a) are relatively symmetrical and do not suggest unilateral cerebral ischemia, but in example (b), a marked asymmetry is shown, noted by suppression of EEG amplitude over left hemispheric derivations in post-hemispherectomy patient, longitudinal bipolar montage. Copyright 2013. Mayo Foundation for Medical Education and Research. All rights reserved. Figure courtesy of Jeffrey W. Britton, MD.







## EEG in the Epilepsies

### *Routine Interictal EEG in Epilepsy and Spells*

The main purpose in obtaining EEG (other than evaluation of focal or generalized cerebral function) is to evaluate patients with known seizures to permit an accurate diagnosis of the seizure type and epilepsy syndrome so that therapy may be appropriately directed or to diagnose unknown paroxysmal spells that may represent seizures.

While the background EEG is usually normal in patients with epilepsy (5), abnormal interictal EEG manifestations may include nonepileptiform abnormalities and interictal epileptiform discharges. Patients with epilepsy may show generalized or focal slowing of the background, but the most useful diagnostic finding supportive of a diagnosis of epilepsy is the activation of IEDs, which may be either focal or generalized in distribution. IEDs must be carefully distinguished from benign variants or normal brain waves to avoid overinterpretation of benign variants and artifacts (as discussed above) that may be mistaken for epileptiform activity. In addition, on rare occasions, some patients without clinical seizures or epilepsy demonstrate epileptiform activity on interictal recordings, potentially leading the clinician to commence antiepileptic drug (AED) therapy that may expose patients without actual clinical epileptic seizures to unwarranted and dangerous adverse effects.

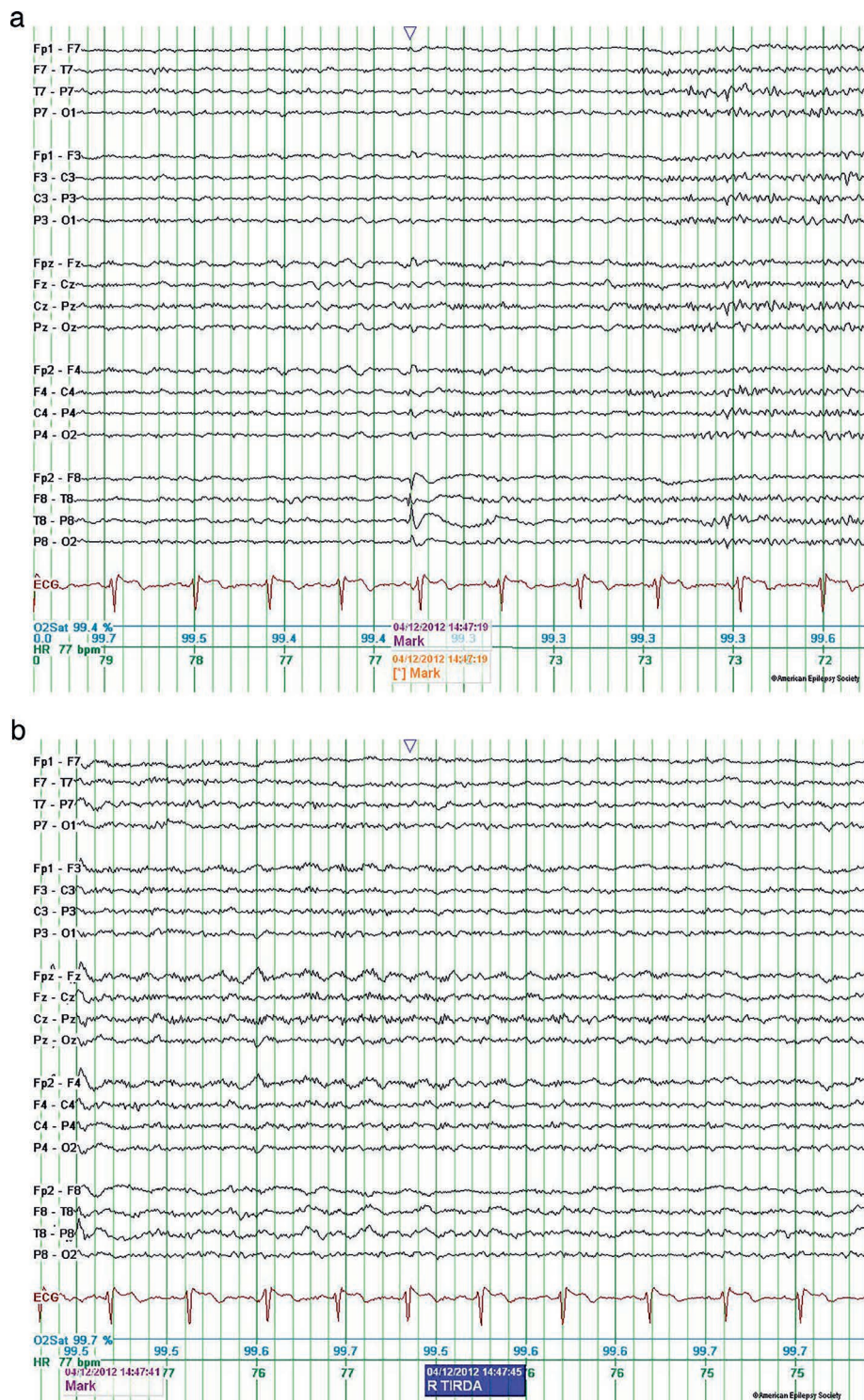
The type, localization, and frequency of IEDs are of significant diagnostic and prognostic value in diagnosis of the patient's specific epilepsy syndrome. For example, patients with mesial temporal lobe epilepsy who are being considered for possible epilepsy surgery and who have IEDs that are concordant to the surgical focus (i.e., unilateral anterior or midtemporal IEDs ipsilateral to the side of a surgical resection) have superior operative outcome compared with those who have other discordant bilateral temporal or extratemporal IEDs (6). Another example of the value of EEG in electroclinical epilepsy syndrome diagnosis is juvenile myoclonic epilepsy of Janz (JME). Of adolescent or adult patients having generalized IEDs on EEG who also meet clinical diagnostic criteria for JME, there is an approximate 80 to 90 percent chance of recurrent seizure activity following attempted AED withdrawal, so most clinicians favor lifelong treatment in such patients (7).

Artifacts or benign variants in the EEG require careful distinction from genuine interictal abnormalities when interpreting video-EEG studies. An advantage of epilepsy monitoring practice is the availability of continuous time-linked video so that patient movement and electrostatic artifacts can often be more readily distinguished and assigned a particular cause. The reader is referred to the previous sections on Benign Variants and Artifacts, which review appropriate recognition and interpretation of normal findings and commonly encountered benign EEG variants.

IEDs should be distinguishable from and disruptive of the background, and epileptiform ictal activity (discussed further below) should represent a distinct discharge that changes the EEG background and evolves over time in waveform frequency, amplitude, and morphology.

### *Focal IEDs*

Focal IEDs may occur over any lobe on either side but are most commonly seen in either temporal or frontal lobe epilepsy, as parietal and occipital epilepsies generally have rarer activation of IEDs. IEDs are almost invariably surface negative and are localized by principles of electrophysiologic polarity. In a referential montage, in the setting of a distant, inactive reference electrode, IEDs have maximal negativity in the channel having maximal amplitude, whereas in a bipolar montage, maximal negativity is at the site of "phase-reversal" (i.e., where maximal electronegativity is held between two neighboring derivations sharing a common electrode site, causing a surface positive downward deflection in one electrode pair and a surface negative upward deflection in the second electrode pair, such that the two negative-going waveforms point toward one another, resulting in a phase-reversal of polarity (see Figure 62). The characteristic morphology of a focal IED is a very sharp rise time, a complex waveform often with several phases or baseline crossings, and an after-going slow wave discharge that disturbs or disrupts the continuity of the background rhythm at least momentarily. See Figure 62 for an example of a left temporal IED.

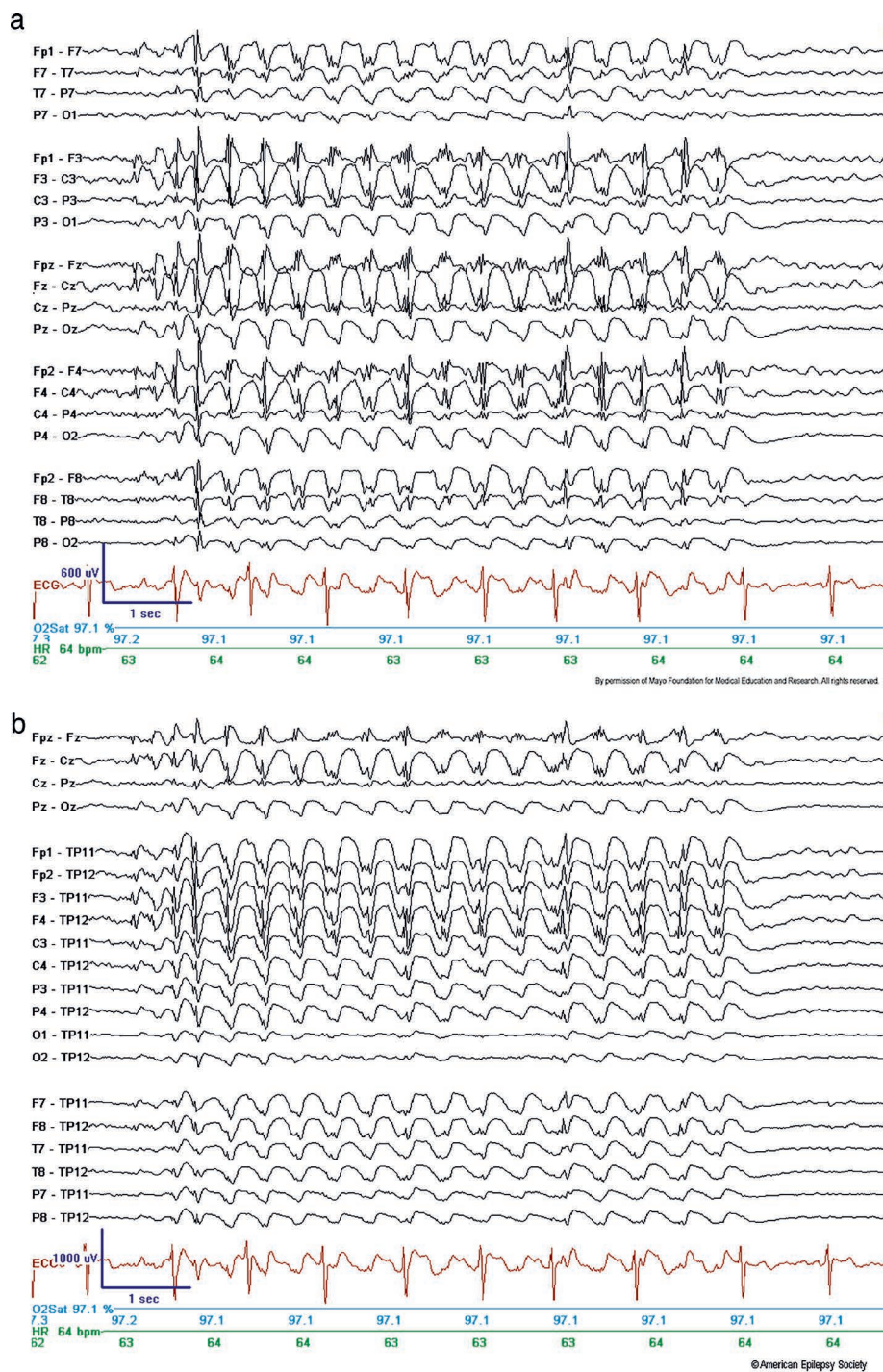


**Figure 62.** Right temporal IED in a 32-year-old man with right mesial temporal lobe epilepsy. (a) Channels 17 (FP2-F8) and 18 (F8-T8) show a “phase-reversal” of negativity, allowing localization of the spike discharge as maximally negative at the F8 electrode site (i.e., given maximal negativity at F8 and the conventions of EEG polarity, which state that when the Grid 1 electrode site, FP2 in channel 17, is more positive than the Grid 2 site, F8, the result is a surface positive downward deflection; whereas in channel 18, F8 is more negative than the T8 Grid 2 electrode site, resulting in an upward deflection). Thus, the phase-reversal demonstrates that the F8 electrode site holds maximal negativity and allows localization of the spike focus to that site. (b) Focal/regional slowing appears over the right temporal region, which has a rhythmic character consistent with the pattern known as temporal intermittent rhythmic delta activity (TIRDA), a frequent finding of epileptiform significance in those with temporal lobe epilepsy. Copyright 2013. Mayo Foundation for Medical Education and Research. All rights reserved. Figure courtesy of Erik K. St. Louis, MD.

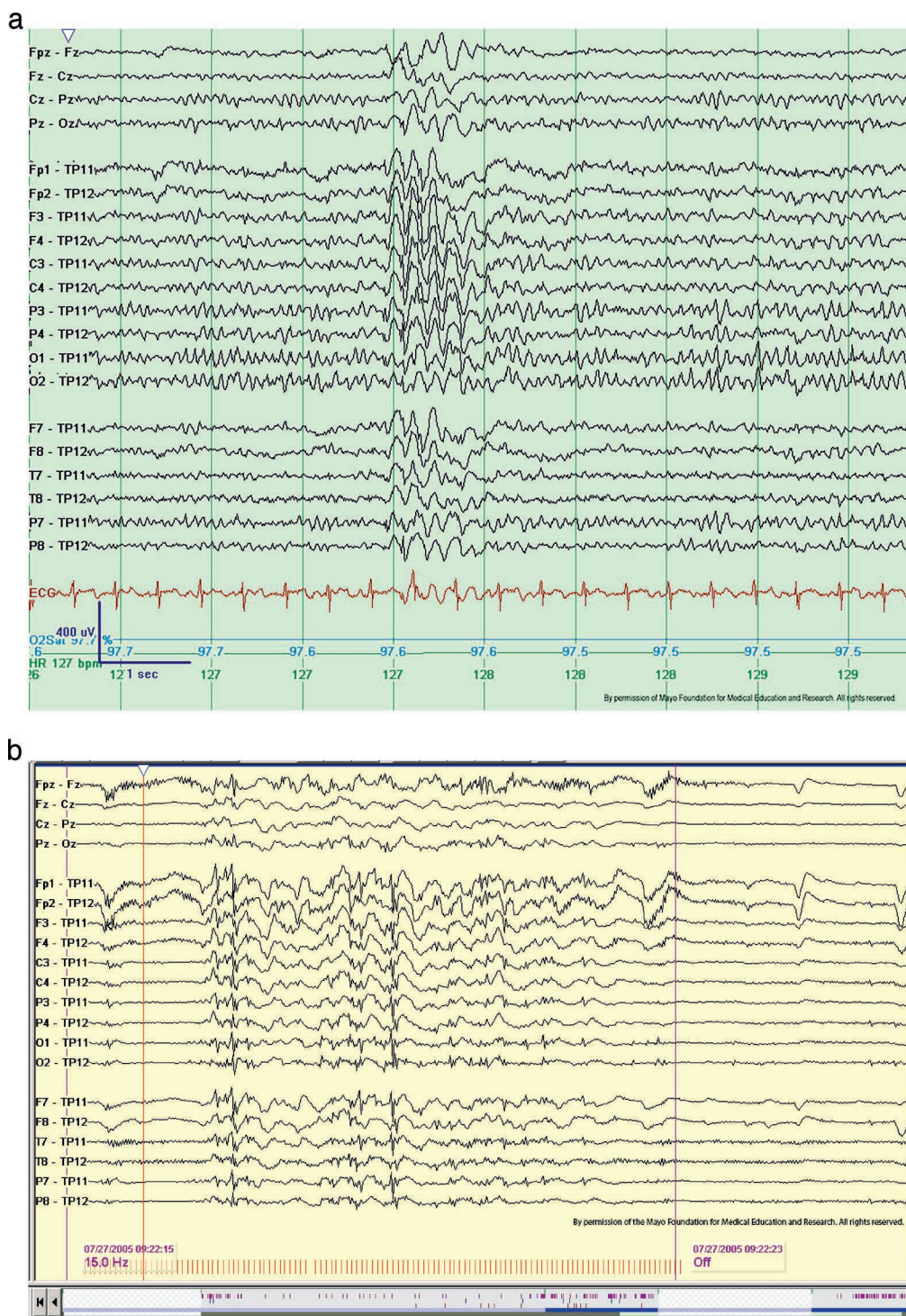
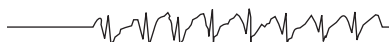

**Generalized IEDs**

Generalized IEDs are usually either typical or atypical generalized spike-wave complexes or polyspike discharges, polyspike-wave discharges, or both (see Figure 63 for a “typical” 3-Hz generalized spike-wave discharge, and Figure 64 for an atypical generalized IED). IEDs are seen in roughly 50% of patients with generalized tonic-clonic seizures (GTCs) overall but have been reported in between 1 and 13 percent of normal individuals and are seen with increased prevalence in nonepileptic patients having a first-



**Figure 63.** The 3-Hz (typical) generalized spike-wave IED. This IED is most commonly seen in children with CAE. (a) Longitudinal bipolar montage. (b) Ipsilateral ear reference montage. Copyright 2013. Mayo Foundation for Medical Education and Research. All rights reserved. Figure courtesy of Jeffrey W. Britton, MD.



**Figure 64.** Atypical generalized spike-wave IED. This IED is most commonly seen in children with juvenile absence or myoclonic epilepsy syndromes. Example (a) shows the discharges are spontaneous. In (b), the discharges are induced by the activating procedure of photic stimulation, representative of a so-called photoparoxysmal response, which often occurs in those with primary idiopathic generalized epilepsy syndromes. Copyright 2013. Mayo Foundation for Medical Education and Research. All rights reserved. Figure courtesy of Jeffrey W. Britton, MD.



degree relative with generalized epilepsy. Focal spike-wave discharges may also be seen in those with primary GTCs and epilepsies and should not be mistaken as definitive evidence for an underlying epileptogenic focus unless consistent and persistently focal discharges are seen.

In patients with symptomatic generalized epilepsy, especially the Lennox-Gastaut syndrome, spike-wave discharge frequency is characteristically slower, and there is often underlying associated background slowing, indicative of generalized cerebral dysfunction and an epileptic encephalopathy. See Figure 65 for an example of the slow spike and wave typical of patients with Lennox-Gastaut syndrome.

### Ictal EEG Applications and Formats

#### Ambulatory EEG and Continuous Bedside EEG

Ambulatory EEG may be quite useful when inpatient video-EEG is not available, or to permit real-world monitoring of spell or seizure capture in the patient's natural environment. In patients having frequent seizures on medication, ambulatory EEG can often helpfully clinch the diagnosis of the epilepsy type as either partial or generalized. However, without concomitant behavioral recording by video, nonepileptic events cannot be fully evaluated or confidently diagnosed by this technique.

Even when the diagnosis of epilepsy and the patient's seizure type is well known, many patients underestimate the true frequency of their seizures. Another role for ambulatory or prolonged bedside EEG recording (with or without video) is determining the frequency of seizures, a central aspect of tailoring therapy for an individual patient. When patients or their caregivers are unable to provide an accurate estimation of seizure frequency, objective seizure quantification of a patient's current baseline seizure frequency with video-EEG monitoring may be an important step prior to instituting new medications or considering withdrawal of current treatments. Of importance, however, because of the risk of status epilepticus, medication withdrawal should not be attempted outside of the supervised setting of a hospital, where emergency treatment and rescue medications can be promptly administered.

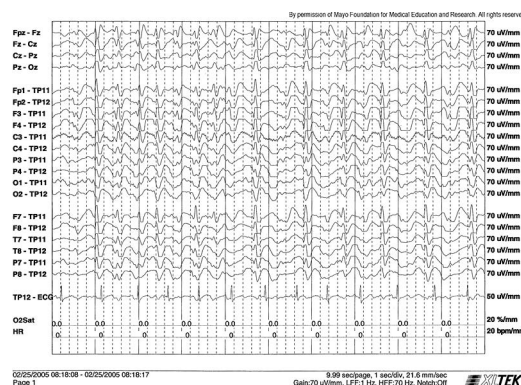
#### Long-term Video-EEG Monitoring

Prolonged EEG recordings, especially those employing simultaneous video for evaluation of corresponding behaviors, is often necessary when routine EEG recordings do not demonstrate diagnostic findings. Prolonged EEG monitoring provides a rich opportunity to analyze prolonged samples of interictal EEG data, adding significantly to the diagnostic yield of shorter interictal tracings. When prolonged EEG recordings are done as an inpatient in an epilepsy monitoring setting, the inpatient ward may provide a safe environment for recording the patient's habitual clinical spells or seizure types under conditions of medication withdrawal or sleep deprivation.

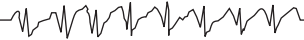Video-EEG monitoring is most appropriately reserved for patients needing event characterization or seizure localization in preparation for epilepsy surgery. When the diagnosis of epilepsy or the cause of paroxysmal spells is in doubt, ictal video-EEG recording of a patient's spell is the gold standard for establishing an accurate diagnosis. In certain patient groups, such as the elderly, diagnosis of epilepsy can be difficult owing to atypical seizure semiology and infrequent clinical episodes; in such patients, video-EEG might be particularly useful in clarifying a diagnosis of epilepsy. Objective evidence, through ictal video-EEG seizure recording, can clarify the nature of a patient's spell from beginning to end and permit intimate correlation of behavioral changes on video recording with underlying EEG activity, leading to an accurate seizure type diagnosis. However, if a patient's diagnosis is clear on clinical grounds, and empiric medications are successful in controlling seizures, video-EEG monitoring may not be necessary.

Generally, spells or seizures should recur at least once or twice per month to enable capturing a spell during a planned 1-week admission, which has an approximate 75% diagnostic yield. Other recent studies have confirmed that video-EEG leads to altered diagnosis in 45 to 58 percent of patients and changes in management in nearly 75% of monitored patients (8). However, video-EEG may still have a reasonable yield with less-frequent spell occurrence. In patients with seizure episodes occurring rarely on drug therapy, seizures may still be successfully recorded during hospital admission for inpatient monitoring, where AEDs can be safely lowered to permit seizure capture in a more abbreviated time frame.

However, no specific seizure count should alone determine the utility of monitoring in patients with refractory epilepsy (9). The practice of video-EEG monitoring has evolved in parallel with the clinical practice of epilepsy care, the tenet of which is to assist a patient in becoming seizure-free, without adverse side effects of treatment, and when that may not be realistic or feasible, to reduce the frequency of medically and socially disabling seizure episodes to limit patient morbidity and improve quality of life. One reason for suboptimal seizure control is inaccurate diagnosis of epilepsy, or misdiagnosis of the patient's seizure type. Seizure recording enables an accurate diagnosis of the patient's seizure type to facilitate optimal drug therapy and provides an estimation of whether future epilepsy surgery or vagal nerve stimulator (VNS) therapy is feasible. Not infrequently, an alternative diagnosis is established by video-EEG recording, such as psychogenic spells, for which AED therapy is ineffective.



**Figure 65.** Slow spike-wave IED typical of the Lennox-Gastaut syndrome. Also note the associated underlying background slowing, indicative of generalized cerebral dysfunction and an epileptic encephalopathy. Ipsilateral ear referential montage. Copyright 2013. Mayo Foundation for Medical Education and Research. All rights reserved. Figure courtesy of Jeffrey W. Britton, MD.



### *Seizure and Spike Detection Software*

Currently marketed video-EEG vendors offer alternatives for efficient data review of video-EEG studies through computerized seizure and spike detection algorithms. However, careful review of all interictal and ictal EEG-recorded data is always necessary by epilepsy monitoring personnel, although computerized detection software techniques are useful for data reduction for interpreting physician review.

### *Seizure Provocation: Sleep Deprivation, AED Withdrawal, and Photic Stimulation*

Whether or not AEDs are withdrawn during video-EEG monitoring is a highly individualized decision, depending on the clinical indication for monitoring and the patient's own seizure frequency, history, and current AED regimen. When withdrawing AEDs, one must ensure appropriate safety measures are in place, including seizure precautions and a specific rescue plan to re-administer drugs rapidly and efficiently. All patients having AEDs withdrawn should have an intravenous (IV) line in place for rapid administration of IV rescue medications.

Sleep deprivation is a reasonable provocative technique to attempt to increase the likelihood and efficiency of capturing seizure events. However, little evidence exists to support or guide the practice of sleep deprivation in epilepsy monitoring practice (10).

As in the outpatient EEG laboratory, photic stimulation and hyperventilation may also occasionally be employed to increase the yield of seizure and interictal epileptiform discharge recording, particularly when primary idiopathic generalized epilepsy is suspected. Patients with reflex epilepsies should also be tested with whatever specific visual, somatosensory, or cognitive stimulus that by history have most regularly and reliably precipitated their seizures (11).

### *Integrating the Clinical Picture and Other Appropriate Investigations*

While the gold standard for seizure classification is seizure capture and analysis by video-EEG monitoring, other clinical and ancillary data are considered in the overall epilepsy syndrome diagnosis for an individual patient, particularly when the video-EEG data are unclear concerning whether the seizures are primary generalized or partial in onset. Clinical characteristics such as the patient's age of seizure onset, the range of different seizure types involved (both as determined historically and objectively from video-EEG monitoring), the natural history of seizures and their response to AED therapies, the presence of a known etiology, a family history of epilepsy, and the neurologic examination are important factors to consider (12–15). Increasingly, application of structural or functional imaging tests often helps clarify the lobe of onset in partial epilepsy syndromes, and to help differentiate primary generalized from extratemporal frontal lobe epilepsies with rapid secondary bilateral synchrony.

### *Pitfalls in Video-EEG Monitoring*

Video-EEG monitoring is a highly reliable means of differentiating spells and seizures and appropriately diagnosing a patient's epilepsy syndrome. However, like any clinical test, video-EEG is subject to limitations. First, the technique is dependent upon capturing the patient's habitual clinical spell. If this spell does not occur during the monitoring session, "all bets are off" with regard to diagnosis. Second, the test has limited specificity just as interictal EEG. Qualitative interictal abnormalities and conclusions regarding monitored spells are subject to considerable variation in interpretation even among experienced clinicians. Considerable training and experience are necessary to accurately employ the technique. Third, technical frustrations are frequently encountered, including electrode disconnection or artifact, and the patient must be kept on camera at all times as much as is feasible, since important clinical data can be lost when spells/seizures occur off camera such as during bathroom breaks. If possible, providing a day room with video capabilities, where patients can still be observed but in a different environment, or mounting cameras in bathrooms also, can limit such losses. Last, it must be realized that just like laboratory EEG, the diagnosis of epilepsy cannot be made or excluded solely on the basis of interictal data. That is, one cannot accurately conclude that a diagnosis of epilepsy is excluded by several days of normal interictal EEG data, even under optimal recording and interpreting circumstances, since a substantial minority of patients with true epilepsy lack interictal epileptiform discharges between seizure events (16).

### *Long-term Video-EEG Monitoring in a Preoperative Evaluation*

One-third of those with epilepsy, approximately 750,000 individuals in the United States alone, suffer from refractory epilepsy. Epilepsy may be considered refractory to medication when two or more AEDs have failed to produce seizure freedom for a patient. Refractory epilepsy poses several risks to the patient, including impaired quality of life, morbidity from lost school or work attendance, injury, and even sudden death. Epilepsy surgery is the single most effective nonpharmacologic therapy available for the treatment of refractory epilepsy, but patients must be very carefully selected for surgical treatment. Seizures must be partial in onset and begin exclusively from a single cortical region that is not critical for normal neurologic functioning. Video-EEG monitoring and neuroimaging with a brain MRI are the crux of preoperative testing for surgical treatment for epilepsy.

In summary, video-EEG monitoring is a valuable diagnostic tool in clinical epilepsy practice. It readily allows distinction of a variety of paroxysmal spells, including common nonepileptic mimickers of epilepsy, such as psychogenic nonepileptic spells and syncope. For refractory epilepsy patients, it also enables appropriate classification of primary generalized or partial onset seizure types, yielding crucial information for patients and their treating physicians concerning prognosis, and informing treatment options. When seizures are difficult to quantify, video-EEG also allows an objective measure of seizure frequency that can help tailor treatment intensity. The main limitations of video-EEG include its dependency on spell capture and limitations in the yield



of even prolonged interictal recording. In conclusion, video-EEG remains the gold standard for seizure classification and localization in epilepsy care. When considered in the context of the patient's unique clinical history and accompanying interictal EEG and imaging data, video-EEG monitoring may yield crucial information informing patient prognosis, counseling, and treatment (17, 18). Specific clinical situations in which long-term video-EEG monitoring may be used and the range of specific EEG findings that might be encountered in these situations are discussed below.

### **Nonepileptic Spells**

Nonepileptic spells are further subclassified into psychogenic or physiologic categories.

#### *Psychogenic*

Psychogenic nonepileptic spells (PNES) are common in epilepsy monitoring unit practices, accounting for approximately 30% of admissions to epilepsy monitoring units (19, 20). PNES are behavioral events that closely resemble epileptic seizures but lack the typical clinical and electrophysiologic features of true epileptic seizures (21). For this reason, it is appropriate to distinguish these events from actual seizure events by using the term psychogenic nonepileptic spells.

Typical features of PNES may be nearly identical to features of actual epileptic seizures, including behavioral unresponsiveness, abnormal movements, and post-event behavioral alteration (postictal behavior). However, PNES are often distinguished by prominent, persistent eye closure throughout the spell (rarely seen in true epileptic seizures), usually have bizarre voluntary-appearing movements including "yes-yes" type (head-nodding) or "no-no" type (head-shaking) movements, prominent pelvic thrusting, or atypical progression of movements (e.g., clonic-type movements that start in a leg, spread to the head, and then back to an arm). Moreover, one PNES event is usually different from another; that is, individual PNES lack stereotypy between different events. PNES are usually accurately diagnosed within 2 days of admission to an appropriately experienced epilepsy monitoring unit (9).

The usual cause for PNES is a psychologic conversion disorder, where subconscious stress is being expressed in a physical way by the patient. A compassionate, thorough explanation of the diagnosis and its distinction from true epilepsy is necessary to allow the patient's insight into the diagnosis and eventually, possibly, a full recovery (22). AEDs should be withdrawn, unless they are being used for treatment of comorbid mood or highly suspected true epileptic disorders in addition to their diagnosis of PNES. Counseling and cognitive behavioral therapy are the most effective treatments, along with psychiatric care for associated underlying mood or anxiety disorders.

#### *Physiologic*

Physiologic nonepileptic spells may include neurologic or nonneurologic categories.

*Paroxysmal Neurologic Conditions.* Numerous paroxysmal neurologic disorders may be confused with epileptic seizures. These include nonepileptic behavior in cognitively impaired individuals, transient ischemic attacks (TIAs) from cerebrovascular disease, delirium, migrainous events, movement and sleep disorders. Cognitively impaired individuals are particularly likely to be misdiagnosed with epilepsy, or to have a mixture of nonepileptic behavior and true epilepsy. Examples of nonepileptic behavior ascribed to epilepsy in this patient population include staring with unresponsiveness and movements mistaken for epileptic automatisms (i.e., stereotypies, voluntary mannerisms, or even tardive dyskinesia).

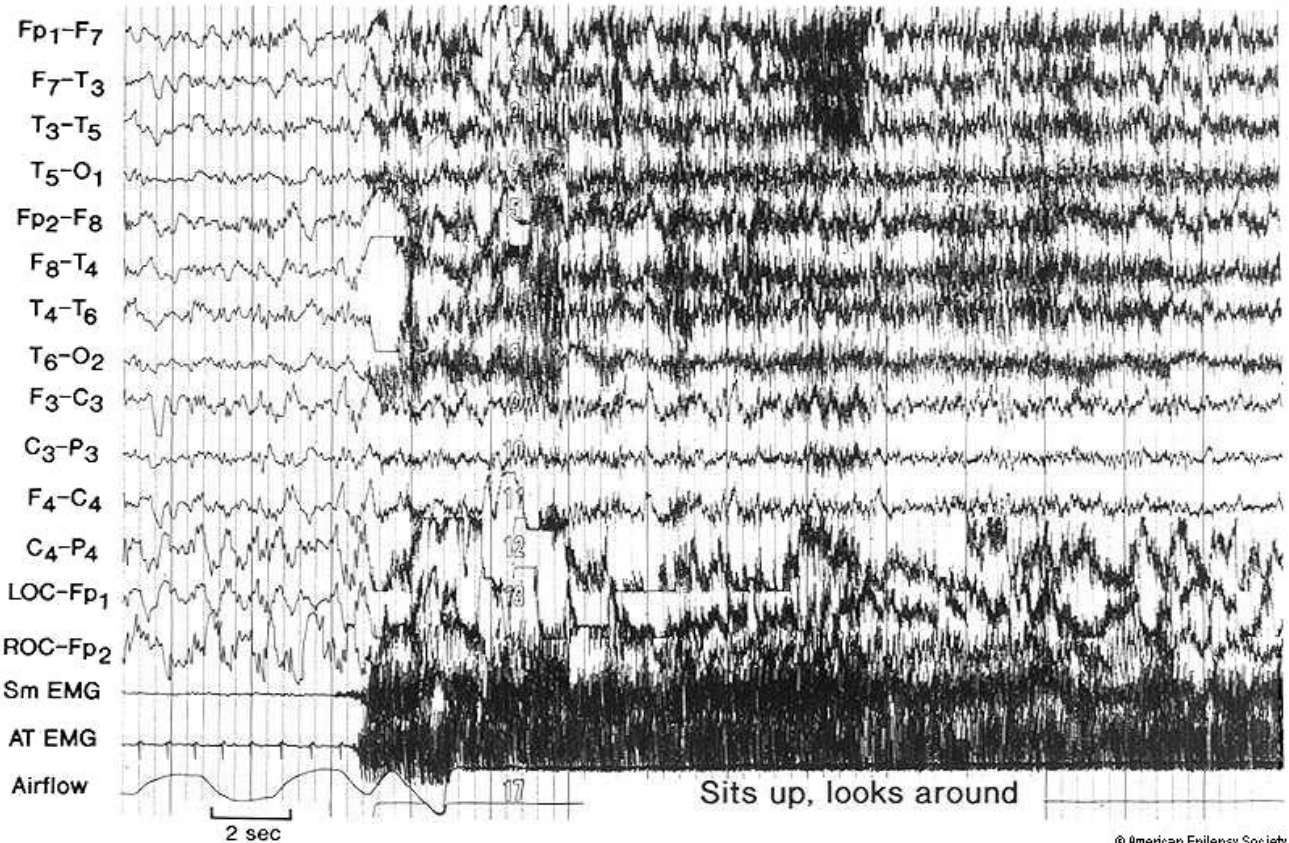
Cerebrovascular disorders may present with paroxysmal disturbances of cerebral function, leading to diagnostic confusion with seizures. Cerebrovascular disorders result from cerebral ischemia (deprivation of blood flow and reduction of tissue oxygenation), or hemorrhage from rupture of a brain arterial structure. Most commonly, cerebrovascular disorders cause loss of function (i.e., "negative" symptoms), such as numbness, weakness, visual loss, or aphasia in distinction to epileptic seizures, which almost always involve "positive" symptoms and signs during the ictal event (although postictal negative signs such as aphasia and weakness are common accompaniments of seizures, and loss of function with ictal weakness may very rarely occur). However, a gain of function including limb shaking movements or symptomatic seizures from irritation of neighboring cerebral cortical tissue may occur, leading to diagnostic uncertainty in some cases. EEG is sometimes helpful in differentiating TIAs from seizures, since focal cerebral slowing or normal findings are seen on EEG during ischemic TIAs or stroke (typically polymorphic delta activity), distinguished from focal evolving rhythmic activity accompanying most partial seizures.

The clinical phenomena of migraine and epilepsy are often similar, involving visual, sensory, and cognitive symptoms. The EEG during a migraine attack demonstrates focal slowing, as opposed to partial seizures, which may show focal evolving rhythmic activity.

Some neurologic movement disorders including paroxysmal dystonias and dyskinesias, and some tremor disorders, may resemble epileptic seizures. EEG is invariably normal during subcortically triggered movement disorders. Careful observation of the video clinical phenomenology by epilepsy or movement disorder specialists or both is necessary to distinguish these episodes, since simple partial motor seizures may also demonstrate stereotyped movements lacking EEG change.



The two most common nocturnal events to be confused with sleep epilepsies are NREM parasomnias or REM sleep behavior disorder. Nonstereotyped behavior or arousal, with or without vocalization or sleep walking behavior, is typical for NREM parasomnias. EEG may show no change other than arousal but occasionally shows generalized or frontally dominant rhythmic delta or theta patterns lasting a few seconds following the arousal (see Figure 66). REM sleep behavior disorder is characterized by complex motor behavior suggestive of dream enactment, with prominent vocalization and rapid phasic muscle jerks and heightened



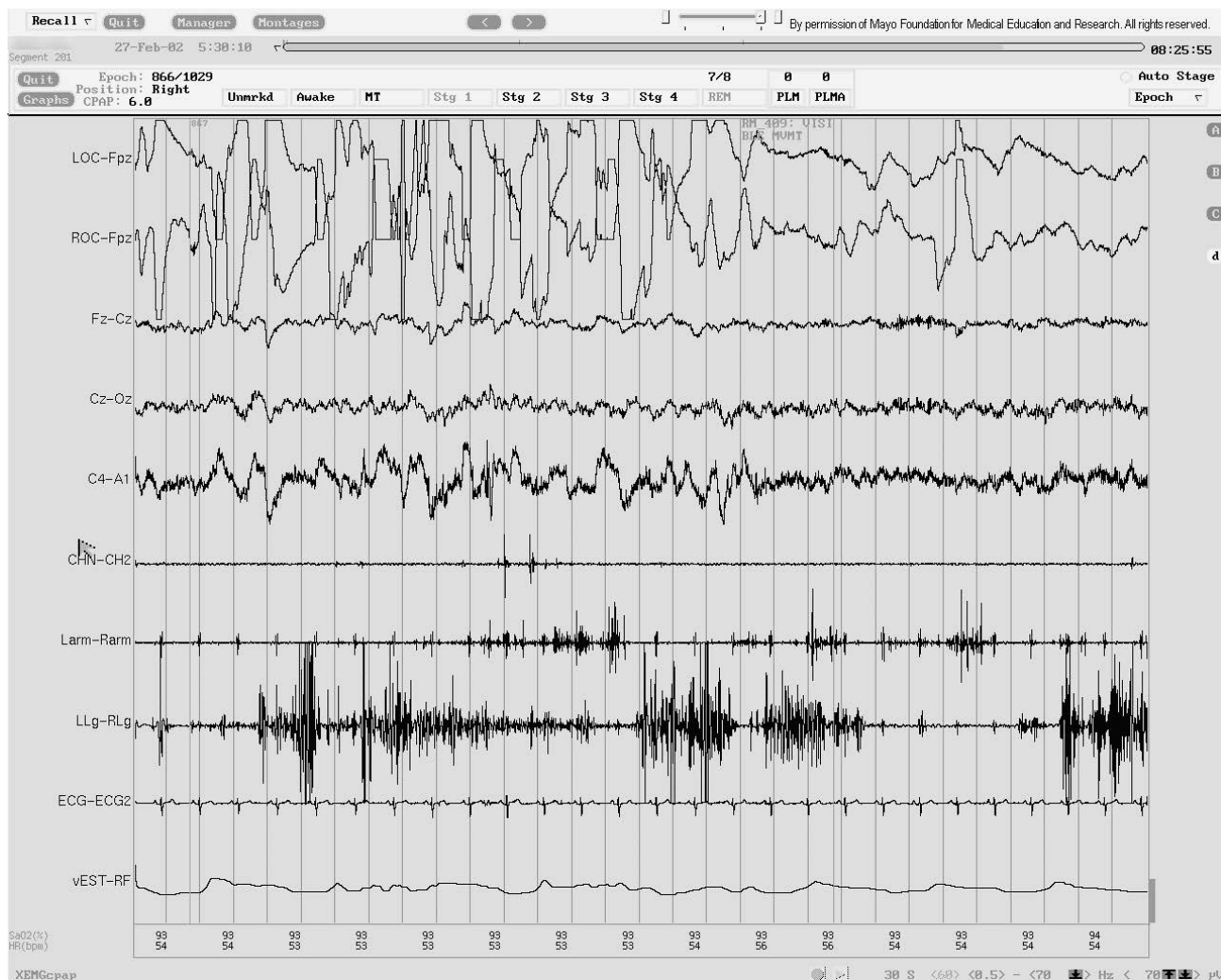
© American Epilepsy Society

**Figure 66.** NREM parasomnia. Note the delta frequency slowing persists following arousal for several seconds (although much of this is difficult to appreciate given the prominent high-frequency muscle and movement artifact following the arousal). Such patterns can be seen in confusional arousal or sleep walking episodes arising from N3 (slow wave) NREM sleep. Copyright 2013. Mayo Foundation for Medical Education and Research. All rights reserved. Figure courtesy of Erik K. St. Louis, MD.

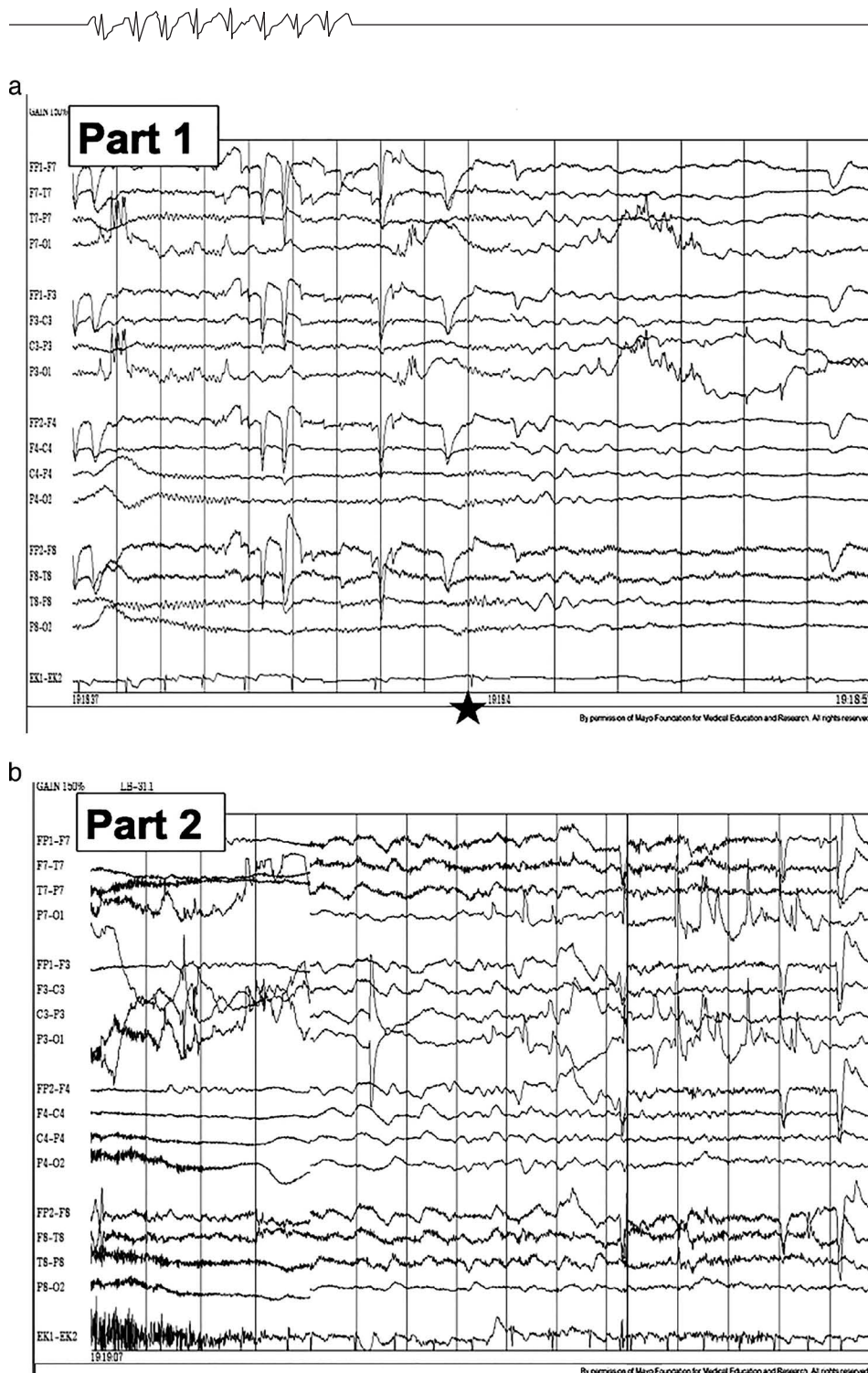




chin and limb muscle tone during REM sleep (see Figure 67). In distinction, nocturnal seizures demonstrate highly stereotyped complex motor behavior, frequently with oral or limb automatisms or both, or trunk automatisms. Seizures of temporal lobe origin show prominent focal evolving rhythmic activity, while frontal lobe seizures often show little if any ictal EEG change other than muscle and movement artifact, and diagnosis relies upon the interpreter’s experience and observation of stereotypy in such instances.



**Figure 67.** REM sleep behavior disorder (RBD). RBD is shown during a 30-second polysomnogram epoch. The first two channels are EOG, demonstrating rapid eye movements; the third through fifth channels show relatively desynchronized background EEG; while the sixth through ninth channels, from the chin, arm, and leg EMG leads, demonstrate abnormally increased muscle tone. To accurately diagnose RBD, sleep polygraphy with EOG and EMG recording, including surface EMG of all four limbs, must be recorded to document the hallmark neurophysiologic finding of REM sleep without atonia (abnormally elevated muscle tone during REM, enabling dream enactment behaviors). Copyright 2013. Mayo Foundation for Medical Education and Research. All rights reserved. Figure courtesy of Erik K. St. Louis, MD.



*Paroxysmal Nonneurologic Physiological Condition: Syncope.* Syncopal disorders may result from either cardiogenic, vasovagal (so-called “simple faints”), or hypotensive causes (23). EEG during each of these events shows generalized slowing or even suppression if blood flow is interrupted for a period of 20 to 30 seconds, such as during asystole following a particularly severe vasovagal attack. See Figure 68 for an example of EEG alterations during a syncopal event.

#### **Epileptic Seizure Classification and Types**

Seizure classification is important in clinical practice, not only for a common nomenclature for describing information but to determine appropriate therapy for an individual patient. Seizures are categorized according to defining clinical and electrophysiologic criteria set forth by the International League Against Epilepsy (24–28). See the Clinical Epilepsy section for a full discussion of clinical seizure types and principles of epilepsy syndrome diagnosis, and the appropriate other diagnostic imaging and treatment considerations for these patients. Below follows a brief discussion of the major features of each of the common generalized and partial seizure types and examples of their ictal EEG features.

#### *Primary Generalized Seizures*

Primary generalized seizures result from bisyn-

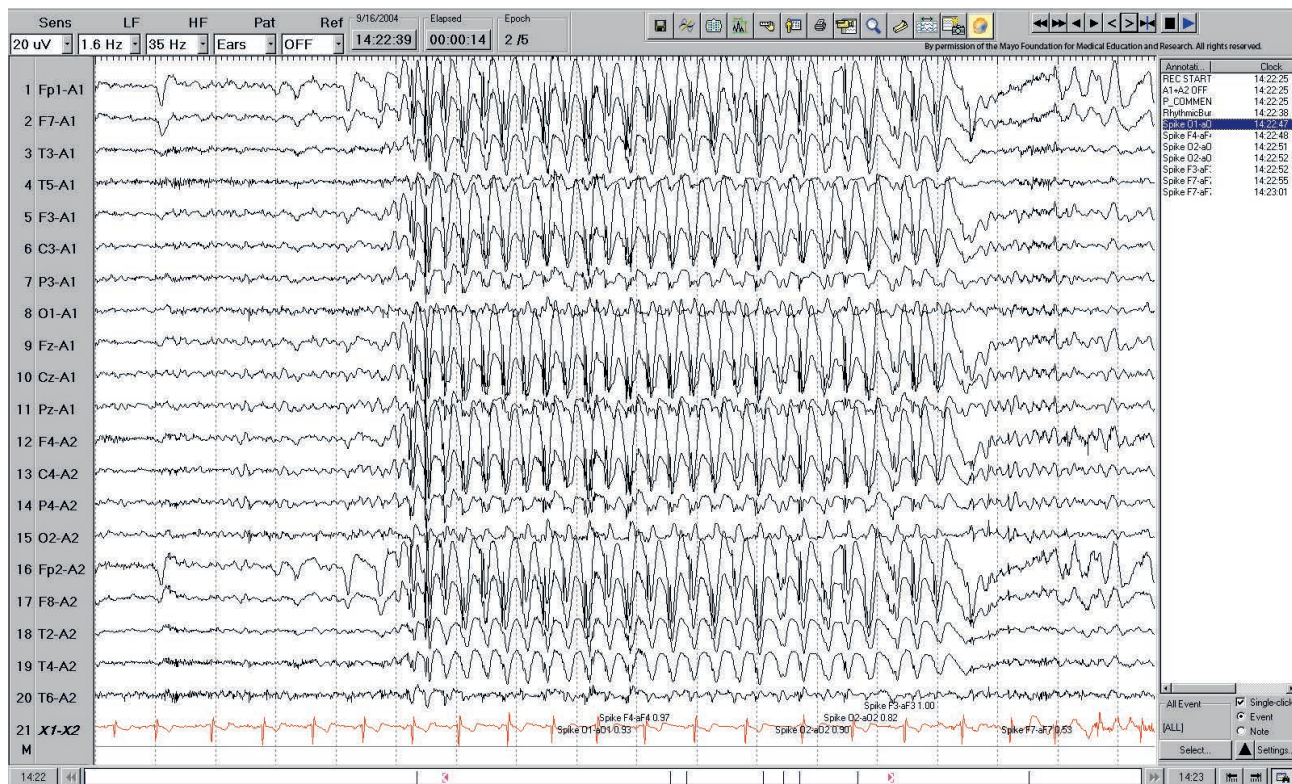
**Figure 68.** Syncope. Recorded syncope during venipuncture on compressed time base. (a) Part 1 shows a normal awake EEG tracing followed by onset of asystole (marked by star). The EEG begins to show diffuse delta activity, then becomes suppressed at the end of the epoch shown. (b) Part 2 shows diffuse suppression in the initial portion of the epoch. Sinus rhythm has returned, correlating with an initial resumption of diffuse delta and then theta EEG activity, then a return of normal background in the latter portion of the figure. Copyright 2013. Mayo Foundation for Medical Education and Research. All rights reserved. Figure courtesy of Jeffrey W. Britton, MD.

- (a) Syncope, Part 1.  
(b) Syncope, Part 2.



chronous cortical seizure onset and are reflected by a narrow and well-defined group of possible seizure behaviors and electroencephalographic patterns.

*Absence.* Absence seizures involve consciousness disturbance for 5 to 10 seconds, with or without accompanying automatisms and lack a prodromal aura or postictal state. The behavior may closely resemble that of a complex partial seizure or the daydreaming behavior in a school-age child. Attacks may be readily precipitated by hyperventilation, or occasionally by photic stimulation or viewing of high-contrast visual patterns (see Figure 69). Absence seizures are most common, and often the exclusive seizure type seen in childhood absence epilepsy (CAE), the chief primary idiopathic generalized epilepsy syndrome of childhood, with onset in the first decade of life. CAE most often remits by the mid-teenage years. Ictal EEG shows the generalized 3-Hz spike and wave activity (Figure 69).



**Figure 69.** Absence seizure. During an absence seizure, the typical ictal EEG pattern is an extension of the interictal pattern (i.e., 3-Hz generalized spike-wave of a prolonged duration, with usual clinical accompaniments of staring with behavioral arrest, or with variable accompaniment by oral and manual automatisms such as blinking, lip smacking, or hand-fumbling movements. Copyright 2013. Mayo Foundation for Medical Education and Research. All rights reserved. Figure courtesy of Erik K. St. Louis, MD.

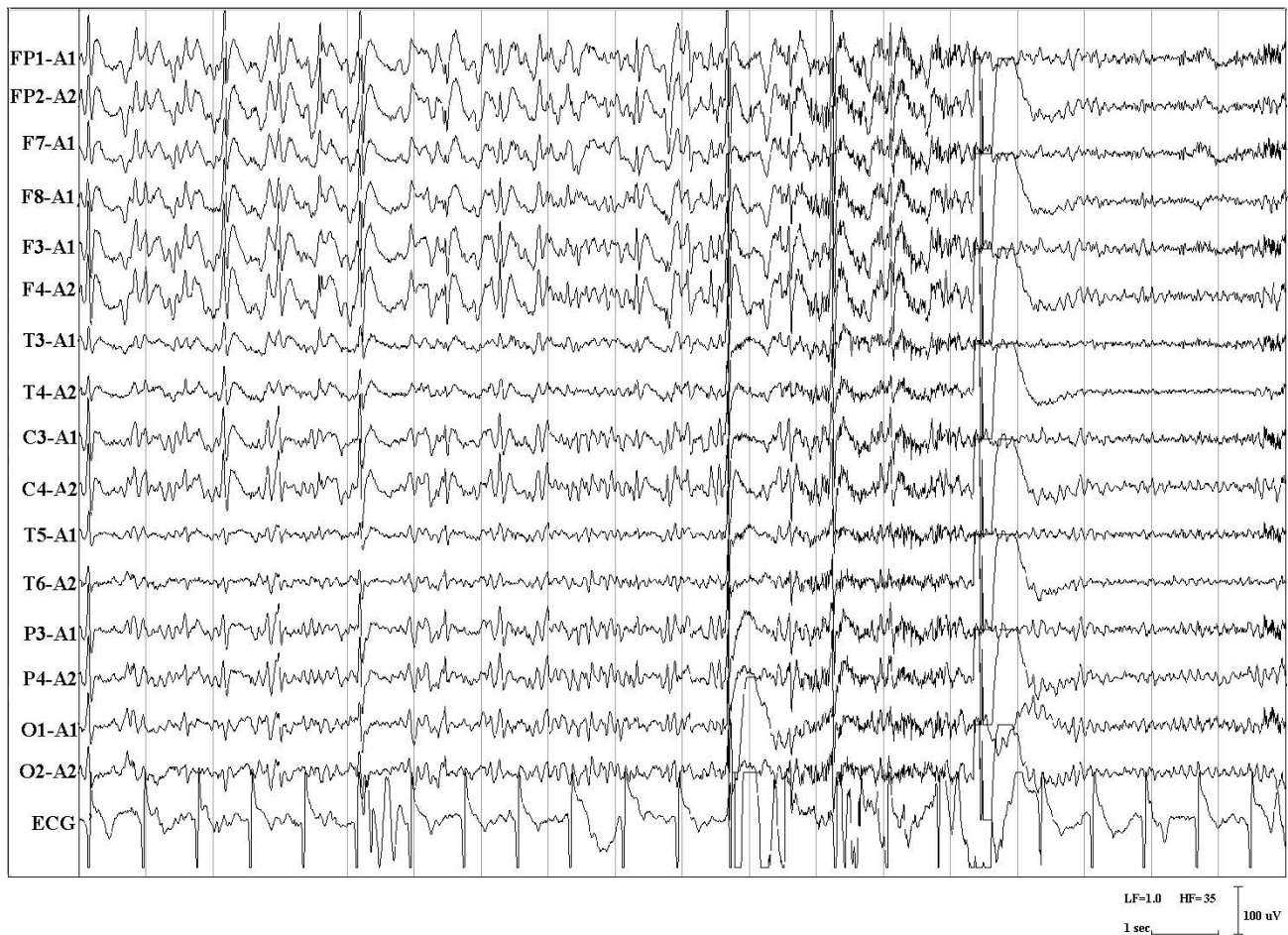


*Atonic/Astatic.* Atonic/astatic seizures are characterized by a sudden loss of postural tone, with variable severity from head nods/drops to complete loss of axial posture with falling and injury. Atonic/astatic seizures frequently occur in children with Lennox–Gastaut syndrome or another form of symptomatic generalized epilepsy, but they can have their onset in later life following generalized cerebral hypoxia. Attacks are often refractory to medical therapy, so ambulatory patients may require a prescription for a protective “crash” helmet. EEG shows slow spike-wave or an electrodecremental pattern with generalized fast activity. (See Figure 70 below for a myoclonic seizure with an example of an accompanying electrodecremental type pattern).

*Myoclonic and Clonic.* Myoclonic seizures involve sudden brief jerks or twitching of any limb or axial musculature, usually with preserved consciousness. Repetitive myoclonic seizures may merge and escalate into sustained generalized clonic seizures (essentially, a bisynchronous bodily convulsion without any preceding tonic phase). Massive myoclonus involving the trunk may lead to falls and injury. Myoclonic seizures are especially frequent in patients with adolescent-onset primary idiopathic generalized epilepsy syndromes such as JME. Ictal EEG patterns include generalized spike and wave or polyspikes (see Figure 70).

*Tonic.* Tonic seizures feature generalized tonic stiffening caused by cocontraction of agonist and antagonist musculature. Typical seizure semiology involves abduction of the upper extremities with extension of the legs, with the patient holding this “cross-like” posture for several seconds. Sleep is an activating influence. Although most tonic seizures are brief, less than 15 seconds in duration, escalation into tonic status epilepticus with prominent autonomic instability may occur. Vocalization, apnea, and falling

© American Epilepsy Society

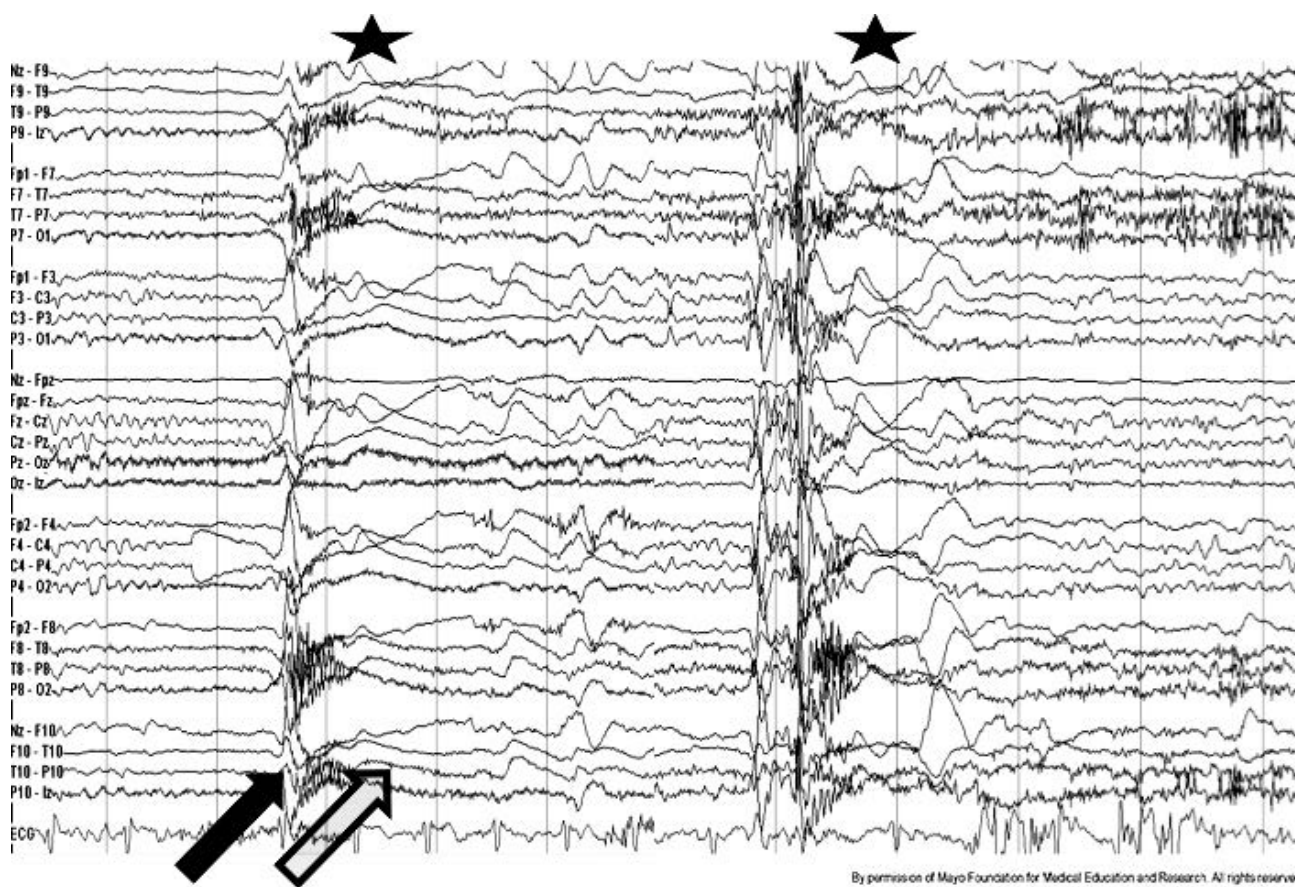


**Figure 70.** Myoclonic seizure in a patient with JME. The patient had a generalized axial myoclonic jerk during second 14, which coincided with the generalized spike-wave discharge and electrodecremental pattern seen on EEG. Copyright 2013. Mayo Foundation for Medical Education and Research. All rights reserved. Figure courtesy of Erik K. St. Louis, MD.



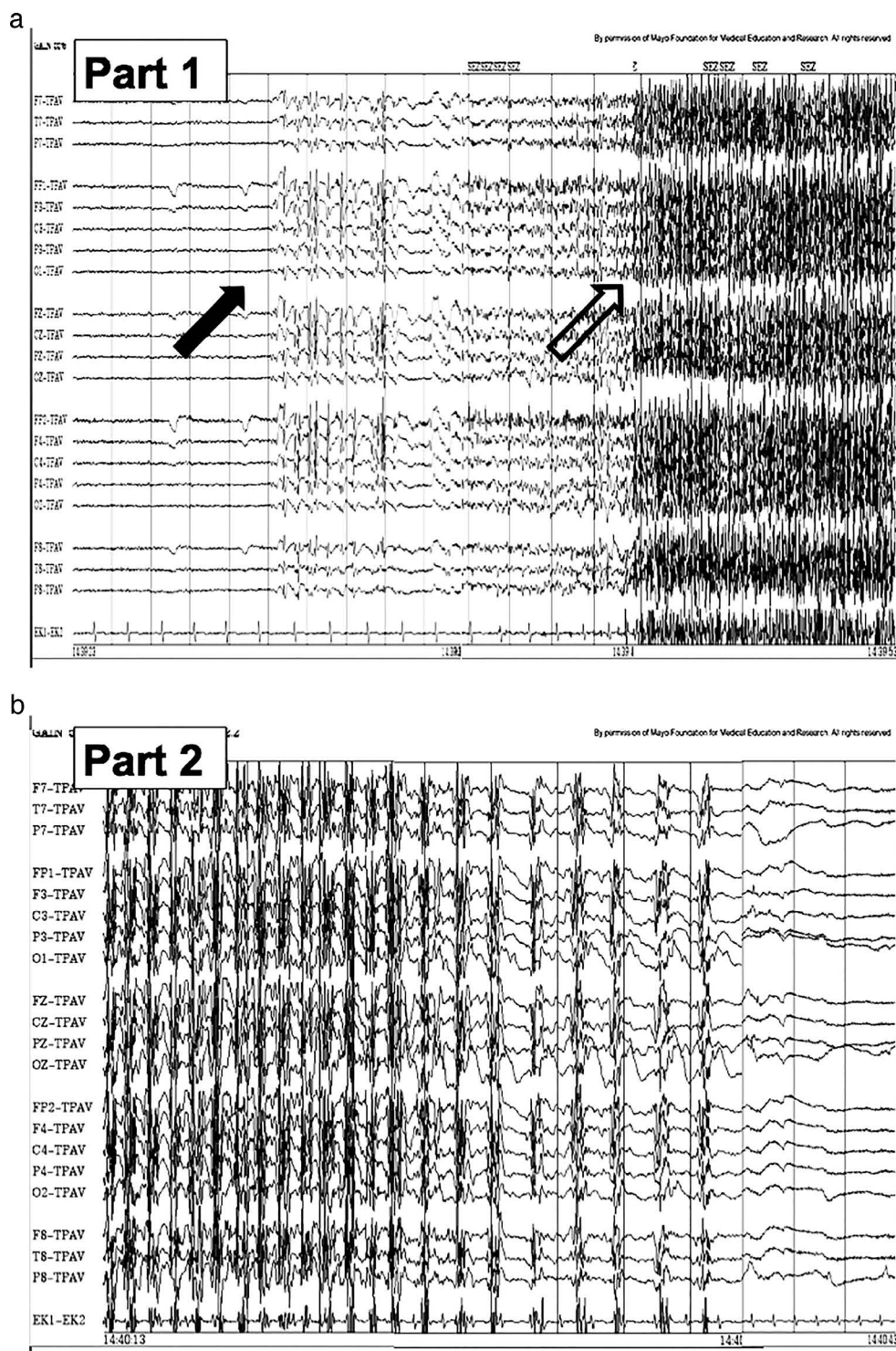
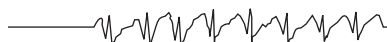may occur. Tonic seizures occur as part of the rubric of seizures in symptomatic generalized epilepsies such as the Lennox–Gastaut syndrome. Ictal EEG demonstrates generalized polyspikes often obscured by muscle and movement artifact, or alternatively, an electrodecremental pattern (Figure 71).

*Tonic-Clonic.* GTC is more frequently of partial onset, with the GTC as the final common pathway of seizure propagation. Nonetheless, primary GTCs may also occur as part of the seizure repertoire in primary idiopathic generalized epilepsy syndromes including CAE and JME. The seizure has two distinct phases, first a tonic phase with generalized agonist–antagonist muscle coactivation, followed by a progressively slowing generalized clonic phase of muscle movements involving repetitive clonic contraction, directly followed by gradually longer relaxation phases, until a state of deep postictal sleep and unresponsiveness ensues, frequently with loss of bladder or bowel continence or both. Tongue laceration from biting is frequent. While most GTCs last 90 seconds or less in duration, persistence beyond 5 minutes should be considered a medical emergency with treatment initiation for status epilepticus. Ictal EEG shows initial generalized polyspikes building up to a frequency of approximately 10 Hz (the so-called “epileptic recruiting rhythm”) during the tonic seizure phase, followed by a generalized spike-wave pattern that gradually slows to a frequency of 1 Hz coinciding with the clonic seizure phase, and ultimately postictal suppression following seizure termination (Figure 72).



By permission of Mayo Foundation for Medical Education and Research. All rights reserved

**Figure 71.** Tonic seizure. Recorded generalized tonic seizures leading to drop attacks (each recorded event marked by star). Patient stood up in a harness system in order to safely record typical events. Onset of each event in this patient is correlated with occurrence of a high-amplitude generalized slow complex (marked by filled arrow), followed by an electrodecremental response (marked by open arrow). Copyright 2013. Mayo Foundation for Medical Education and Research. All rights reserved. Figure courtesy of Jeffrey W. Britton, MD.



**Figure 72.** GTCs. (a) Part 1 shows the onset of generalized tonic-clonic seizure in the longitudinal average ear referential montage. Generalized spike and wave and polyspikes are noted at seizure onset (filled arrow), evolving to continuous activation of spike-wave discharges largely obscured by muscle and movement artifact during the tonic phase (open arrow). (b) Part 2 shows the seizure progressing to the clonic phase, with intermittent bursts of diffuse high-frequency activity and progressively longer intervals of suppression between bursts, which parallel the slowing of the clonic clinical jerking movements. The postictal phase follows seizure termination and is marked by diffuse suppression as noted in the latter portion of the epoch shown. Copyright 2013. Mayo Foundation for Medical Education and Research. All rights reserved. Figure courtesy of Jeffrey W. Britton, MD.

- (a) Part 1, GTC.  
 (b) Part 2, GTC.

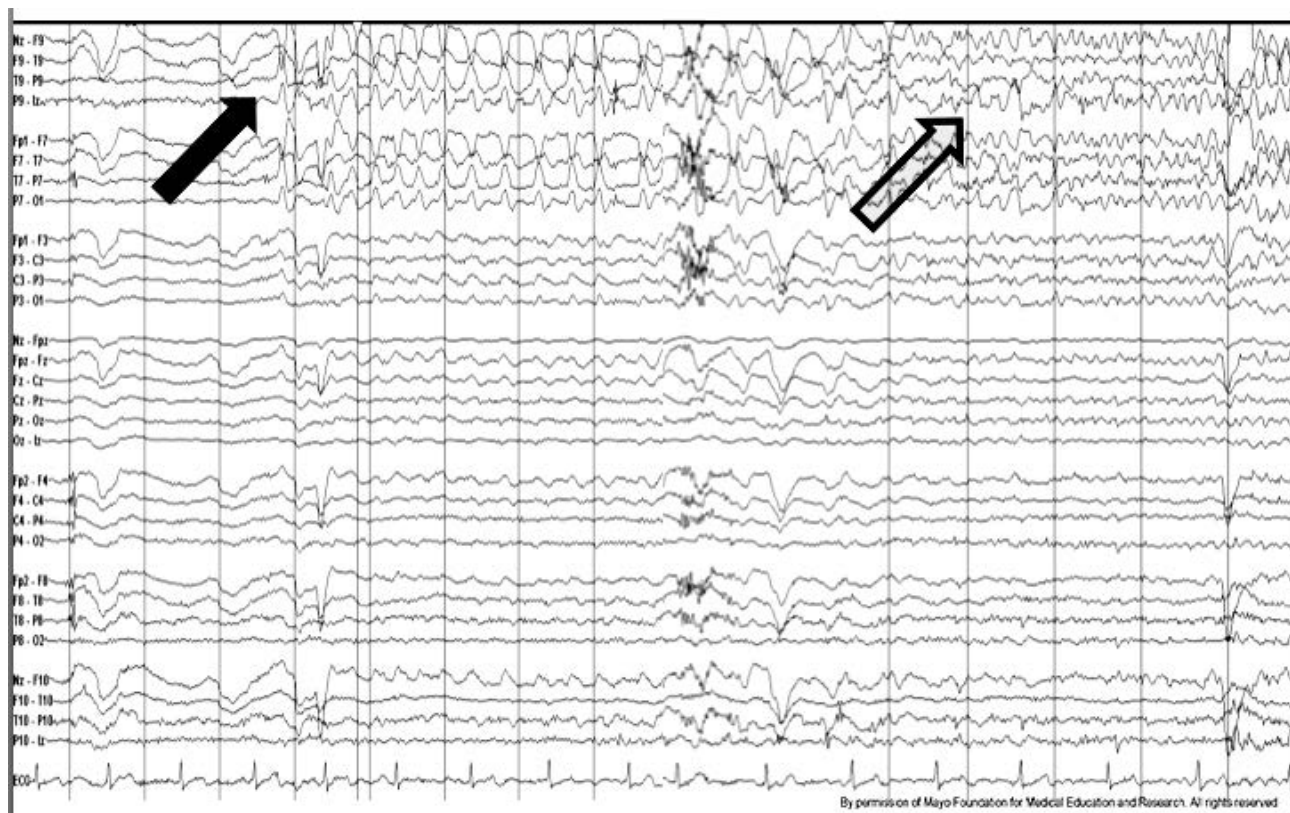


### Focal Seizures

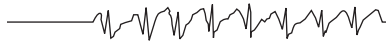Focal seizures are subclassified further as without or with impairment of consciousness (formerly known as simple or complex partial seizures, respectively). The ictal EEG demonstrates characteristic spatiotemporal evolution of initially focal rhythms that progressively increase in amplitude, while slowing in frequency, and spread to neighboring electrode derivations and beyond (see Figure 73). Seizures may be considered as subclinical if they have no subjective or objective clinical accompaniment, or clinical in expression if they do have an overt accompaniment. Subclinical seizures are of interest predominantly in epilepsy syndrome classification and may also have prognostic importance when surgery is being considered, since subclinical seizures that colocalize to the surgical epileptic focus have better prognosis for outcome than those that are not colocalized (29). However, clinical seizures that can be verified as representing that patient's habitual clinical seizure type out of the hospital have the most importance in determining the epilepsy syndrome diagnosis, as well as in presurgical planning.

*Focal Seizures Without Impairment of Consciousness.* In focal seizures without impairment of consciousness (simple partial seizures), consciousness is by definition entirely preserved. Clinical expression is heterogeneous and depends upon lobe/region of cerebral onset. The term *aura* is still also used frequently, especially by patients, to describe focal seizures without impairment of consciousness beginning in the occipital, temporal, or parietal cortex, since the symptoms involved are subjective visual, cognitive/emotional, or sensory and may serve as a warning to the patient prior to progression of the seizure into lost or altered consciousness as the seizure discharge propagates beyond the region of initial onset. Focal seizures without impairment of consciousness of frontal lobe origin most often have an objective expression of focal posturing and clonic motor movements. While focal atonia with weakness are common postictal signs, they may rarely be seen during an EEG ictus as well. EEG during focal seizures without impairment of consciousness may demonstrate focal evolving rhythmic discharges, but of importance, they may be normal on scalp EEG. The seizure may be so limited in spatial distribution that the resulting electro potential may not be picked up by scalp EEG. This is an important limitation and consideration when interpreting EEG, as not understanding this could lead to misdiagnosis.

*Focal Seizures With Impairment of Consciousness.* A focal seizure with impairment of consciousness (complex partial seizures) by definition features loss or alteration of consciousness. Clinical behavior depends upon region or lobe of onset.



**Figure 73.** Left temporal onset seizure. The left temporal lobe onset seizure discharge with onset shows rhythmic delta localized to the left anterior temporal region, with phase-reversal noted over the F7-T7 and F9-T9 derivations (filled arrow). Discharge evolves into rhythmic left temporal theta toward the end of the epoch shown (open arrow) toward the end of the epoch shown. Longitudinal bipolar montage with left hemispheric derivations in the upper half and right hemispheric derivations in the lower half. Copyright 2013. Mayo Foundation for Medical Education and Research. All rights reserved. Figure courtesy of Jeffrey W. Britton, MD.

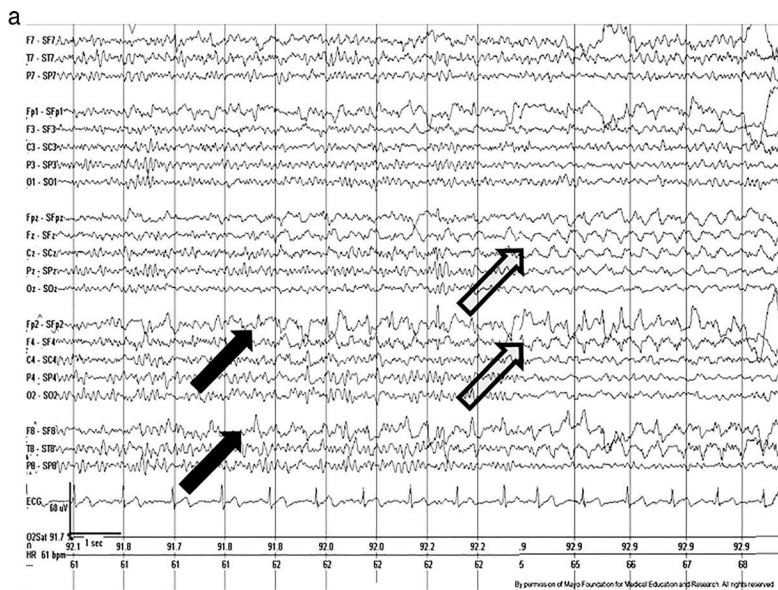


### Classification by Localization of Onset

**Temporal Lobe Seizures.** Temporal lobe–onset seizures most frequently show staring, behavioral arrest, and automatisms of the mouth, face, and limbs such as lip smacking, repetitive swallowing, tongue thrusting, vocalization, or aimless fumbling hand/finger movements. Aimless walking and falls are possible. As the seizure propagates, head turning and limb posturing are frequent. Head turning is most often toward the seizure focus initially (ipsiversive), followed by head or body/trunk deviation, or both, away from the seizure focus late in the course (versive turning). Limb posturing may be asymmetric, involving a still and dystonic hand posture contralateral to the seizure focus and a hand/arm with mobile automatisms ipsilateral to the focus (see Figure 73).

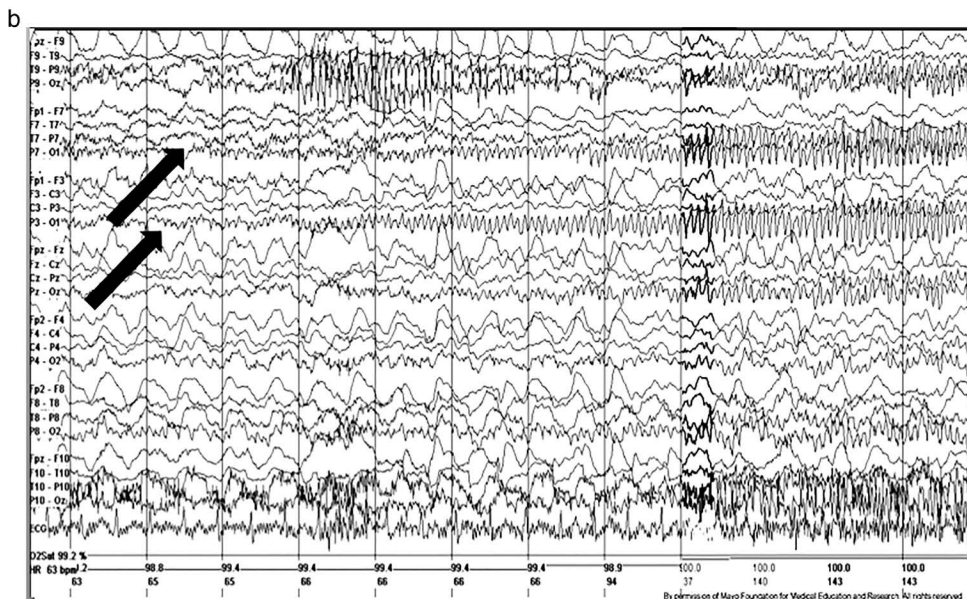
**Extratemporal Seizures.** Seizures of extratemporal origin (frontal, parietal, or occipital lobes) may have features similar to temporal lobe seizures. However, extratemporal seizures more often will have prominent axial and proximal limb movements that lead to mobilization of the patient and falls from bed, bizarre and sometimes violent limb flailing movements that may be misdiagnosed as psychogenic (so-called “hyperkinetic” or “hypermotor” seizures), and more frequently arising from the sleep state. Ictal EEG during extratemporal seizures may show localization to a lobe or region but more commonly shows only minimal rhythmic background change or is obscured by muscle and movement artifact. Ictal discharges may either be minimal or poorly lateralized and localized, or on occasion, may show focal rhythmic activity over the lobe of onset. Figure 74 shows focal frontal and occipital lobe partial seizure activity.

**Focal Seizure Evolving to a Bilateral Convulsion (Formerly Secondary GTCs).** Focal seizures that propagate to both cerebral hemispheres may become secondary generalized convulsions. Immediately prior to evolution to a bilateral convulsion, the contralat-



**Figure 74.** Extratemporal seizures of (a) frontal lobe and (b) occipital lobe origin. (a) Recorded seizure of right frontal lobe onset is shown in the longitudinal Laplacian referential montage. Seizure onset is manifested as rhythmic sharp activity involving FP2 and F8 (filled arrows). The seizure discharge then evolves into a rhythmic delta discharge involving the midline and right frontal derivations (open arrows). (b) Left occipital onset seizure is shown in the longitudinal bipolar montage, with left hemispheric derivations in the upper half and right hemispheric derivations in the lower half. The seizure onset is at P3-O1 and P7-O1 (filled arrows). Copyright 2013. Mayo Foundation for Medical Education and Research. All rights reserved. Figure courtesy of Jeffrey W. Britton, MD.

(a) Frontal lobe seizure  
(b) Occipital lobe seizure





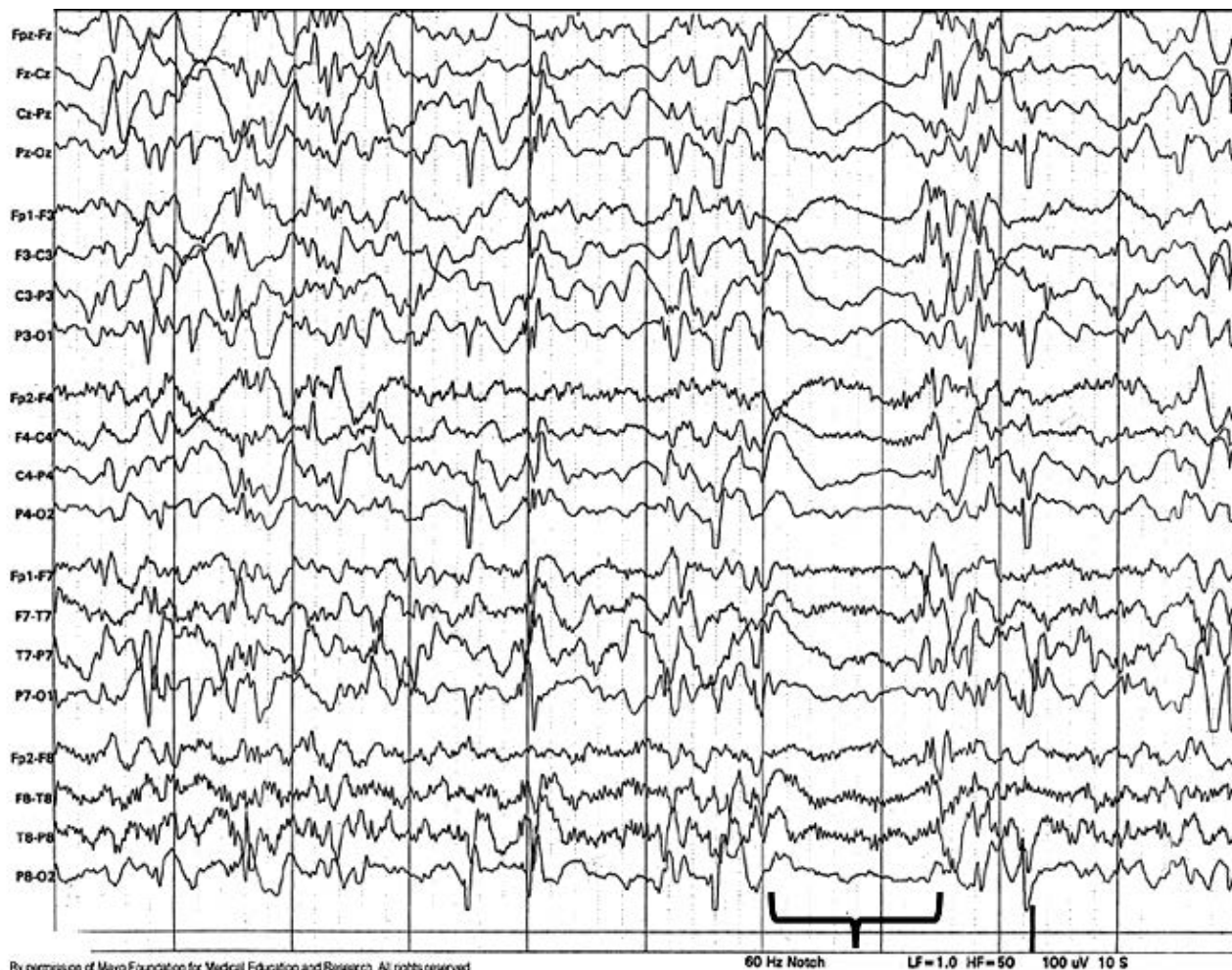

eral arm may become fully extended, while the ipsilateral arm is flexed at the elbow, making the so-called “figure-4” sign. The most reliable point of assessing the lateralizing significance of head turning and body posturing movements relative to the side of seizure onset (i.e., lateralization) is immediately prior to the onset of the clonic seizure phase (30). Clinical phenomena are otherwise similar to that described for primary GTCs, and the two types can be quite difficult to differentiate even during detailed video-EEG monitoring, so the distinction may instead necessarily depend upon other variables such as structural or functional imaging tests, interictal EEG abnormalities, and neuropsychologic data.

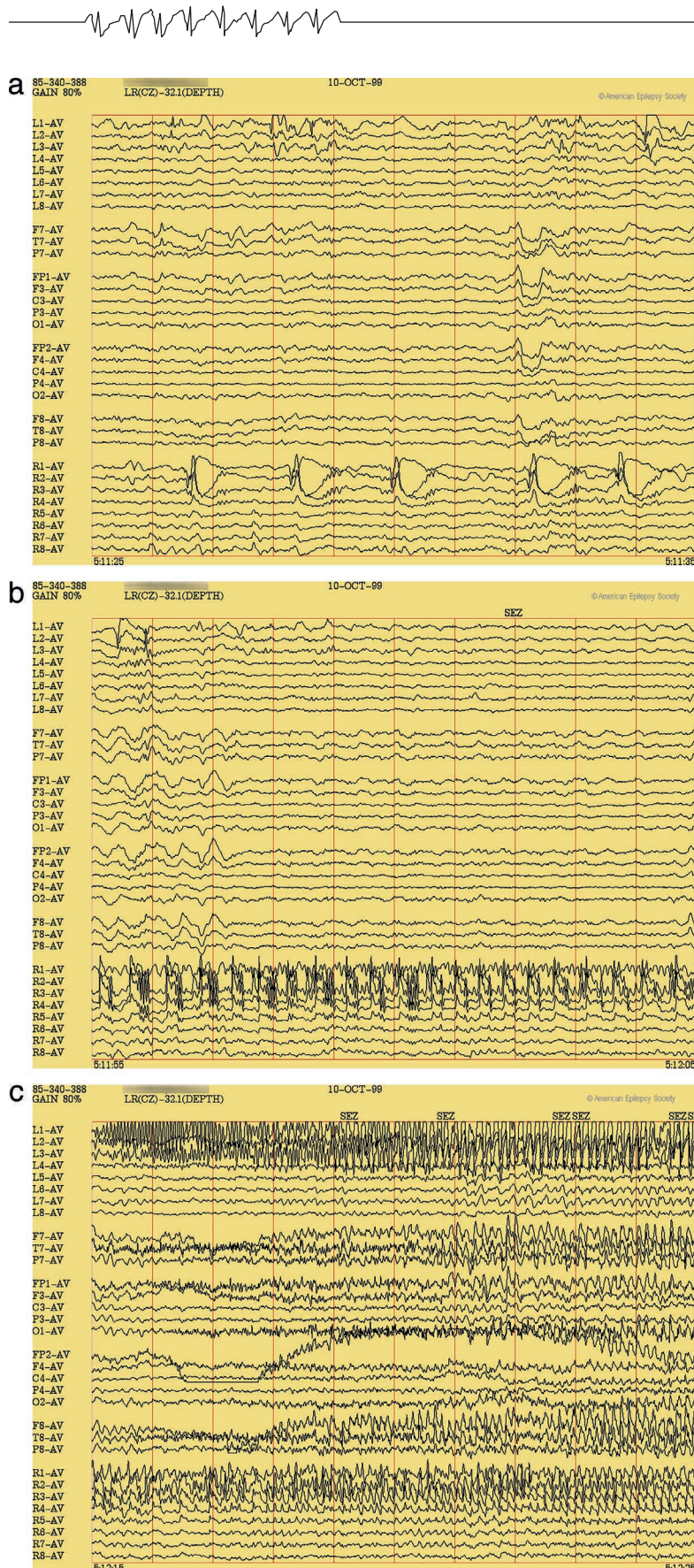
*Seizures in Infant and Pediatric Video-EEG Monitoring.* Infants display a range of potential ictal semiologies with partial or generalized onset seizures. A detailed review of the full range of neonatal, infantile, and pediatric seizure types and their accompanying EEG patterns is beyond the scope of this work, and the interested reader is referred to other recent sources describing epilepsies and seizure types with both benign, presumably genetic mechanisms, as well as refractory and enduring courses. However, infantile spasms are of sufficiently common occurrence and a clinically vital entity to be distinguished from other neonatal spells and seizure types, so as to merit inclusion herein.

#### *Infantile Spasms and the West Syndrome*

Infantile spasms, generalized atonic/astatic seizures involving loss of postural tone and sudden head nodding or collapse, often with forward arm extension (leading to the formerly used term “Salaam attacks”) occur as part of the West Syndrome (infantile spasms, developmental delay, and hypsarrhythmic EEG background). Ictal EEG shows an electrodecremental pattern with generalized background attenuation. Interictal EEG typically shows hypsarrhythmia with frequent generalized and multifocal interictal epileptiform discharges superimposed upon a high-voltage, chaotic, and disorganized background (likened to “scrambled eggs” by many) (see Figure 75). Prognosis is poor for return to a normal development, but prompt treatment with ACTH, other steroids,



**Figure 75.** Hypsarrhythmic EEG pattern in an infant with West syndrome. EEG of an 8-month-old infant with infantile spasms and developmental regression. An ictal electrodecremental response (black brackets) is seen during an epileptic spasm. Copyright 2013. Mayo Foundation for Medical Education and Research. All rights reserved. Figure courtesy of Jeffrey W. Britton, MD.



or vigabatrin in a subset of patients may effect an excellent outcome. Future evolution into a symptomatic generalized epilepsy syndrome such as Lennox–Gastaut syndrome is frequent (31).

#### **Long-term Video-EEG Monitoring With Intracranial Electrodes**

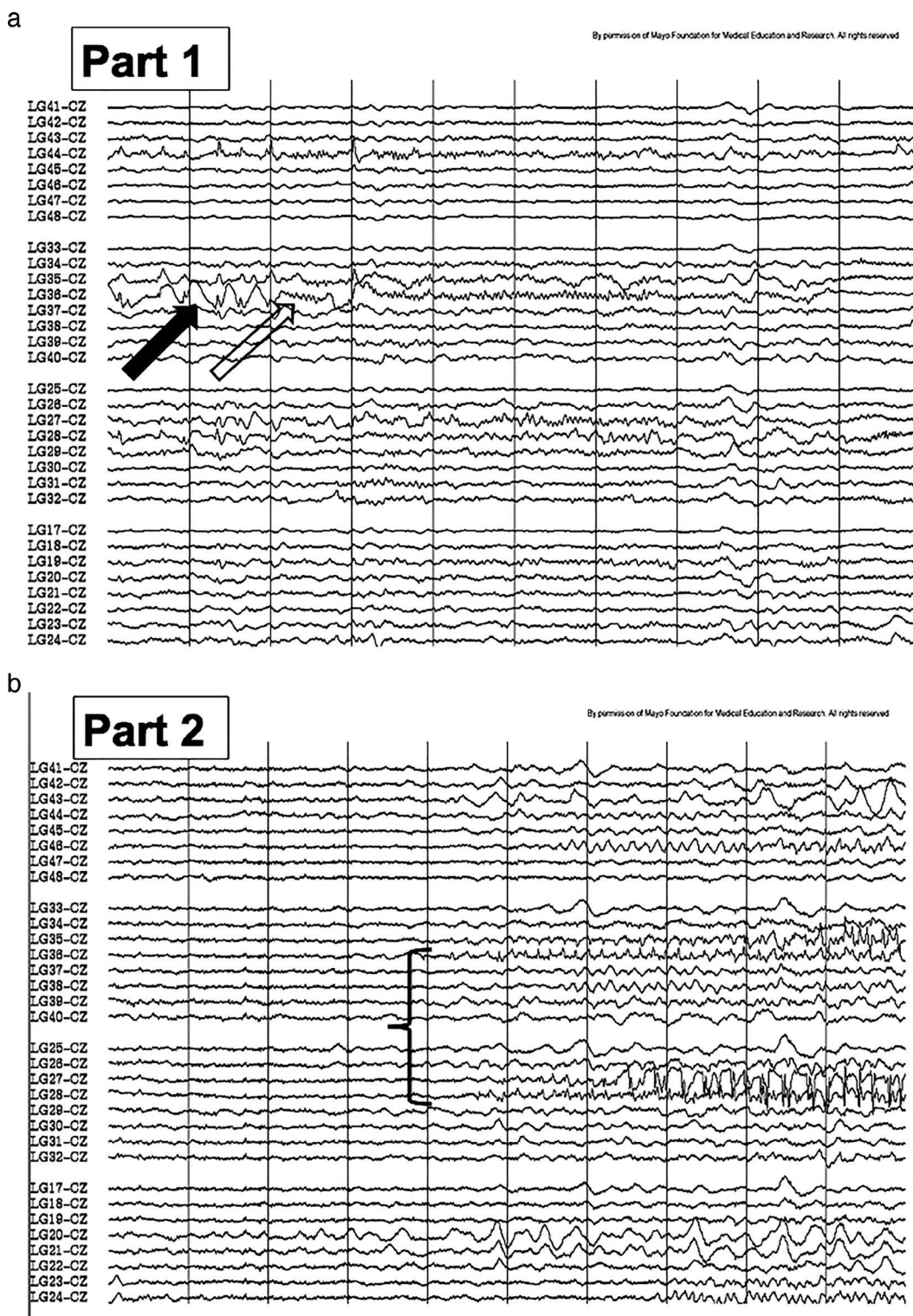
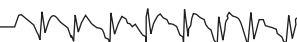Invasive monitoring, involving placement of subdural strips or grids, intraparenchymal depth electrodes, or both, are sometimes necessary for more precise localization of the epileptic focus prior to surgical removal. An advantage of intracranial electrodes is much cleaner recording fidelity since muscle and movement artifact are not present, and the ability to perform electrical stimulation mapping of eloquent functional cortex to avoid incurring neurologic deficits following resection. Figure 76 shows examples of intracranial monitoring of a temporal lobe seizure recorded from subdural temporal strip electrodes and a frontal lobe extratemporal lobe seizure recorded from an electrode grid.

An extensive review of preoperative evaluation for epilepsy surgery is beyond the scope of this work, and the reader is referred to the Clinical Epilepsy text for further details.

#### **Urgent and Emergent EEG for Evaluation and Treatment of Acute Seizures**

A frequent difficulty in the interpretation of urgent and emergent EEGs is that these studies are conducted in patients who are already systemically or neurologically critically ill, resulting in an often highly abnormal background, sometimes with either sharply contoured waveforms that highly resemble epileptiform activity, or at other times representing actual epileptiform waveforms that result from brain damage and may not be accompanied by clinical seizures. An overarching theme in the interpretation of urgent and emergent EEGs is that caution is necessary

**Figure 76.** Recorded seizure in patient with bitemporal depth electrodes (right, labeled R1 through R8-AV; left, labeled L1 through L8-AV) and scalp electrodes showing longitudinal average referential montage. (a) Seizure onset is shown in right anterior medial temporal depth contacts (R1–R3). (b) Seizure discharge is seen to be evolving as rhythmic high-frequency activity, maximal in right anterior medial temporal depth contacts (R1–R3). (c) There is further progression of the seizure, showing rhythmic 8-Hz activity involving both medial temporal depths and bitemporal temporal scalp electrodes. Copyright 2013. Mayo Foundation for Medical Education and Research. All rights reserved. Figure courtesy of Jeffrey W. Britton, MD.



**Figure 77.** Two recorded seizures in nonlesional patient with left lateral frontal seizure focus. Recordings acquired via left lateral frontal subdural grid electrodes. (a) Seizure onset is shown. Part 1 of the seizure consists of rhythmic spike and wave activity at LG36-CZ and LG44-CZ (black arrow) evolving into a rhythmic high-frequency discharge in same distribution (open arrow). In the latter portion of the epoch, low-amplitude diffuse high-frequency activity is present. (b) In Part 2 of the seizure, a new seizure arises in the same patient as depicted in Part 1 as focal rhythmic spike discharge involving LG36-CZ, LG27-CZ, and LG28- CZ (black brackets). Copyright 2013. Mayo Foundation for Medical Education and Research. All rights reserved. Figure courtesy of Jeffrey W. Britton, MD.



in the interpretation of such findings, taking care to avoid overinterpretation or subsequent overtreatment. General principles of EEG interpretation still apply, in that epileptiform activity should be distinguishable from and disruptive of the background, and ictal activity should represent a distinct discharge that changes the EEG background and evolves over time in waveform frequency, amplitude, and morphology.

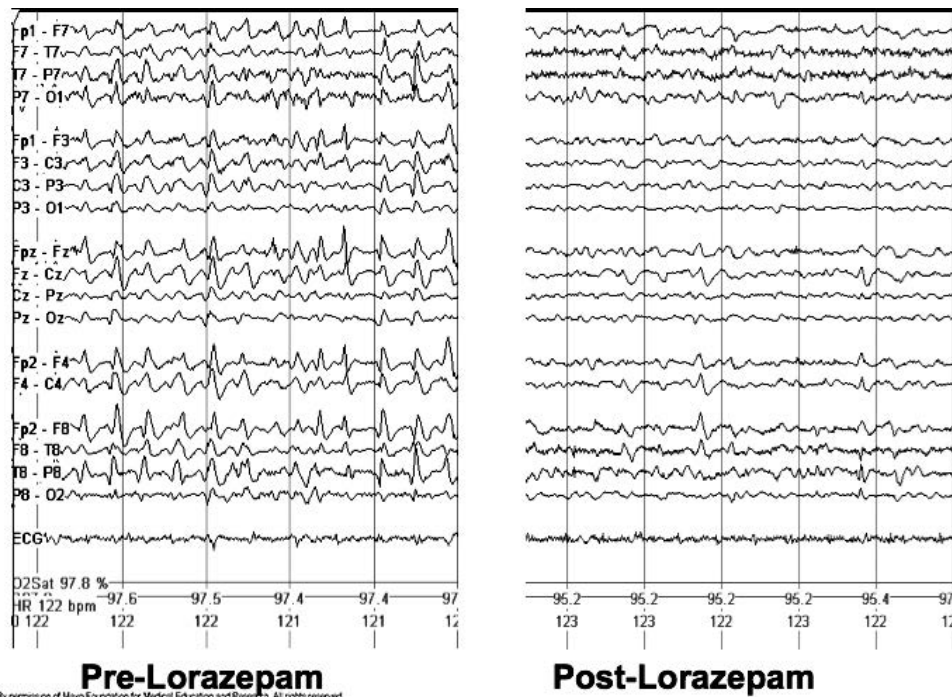
The primary types of EEG available in an emergent setting are (1) a routine 20- to 30-minute study, or (2) continuous video-EEG (CEEG) monitoring, which can range in duration from hours to days. Either type of EEG will only be able to record and assess brain activity in real time. Because of this limitation, a 20- to 30-minute EEG will only offer definitive information if it is recorded when a patient is actively clinically seizing. If available, longer-term video-EEG monitoring has the advantage over routine EEG in the acute setting because there is a higher potential yield for real-time abnormal electrical activity with a longer sampling time. Longer-term video-EEG monitoring also offers the potential for monitoring treatment effectiveness in an actively seizing patient.

Status epilepticus in adults and older children (>5 years old) can be defined as the occurrence of 5 minutes of continuous seizure activity or the occurrence of two or more discrete seizures between which there is incomplete recovery of consciousness (32). Status epilepticus can be divided into convulsive or nonconvulsive subtypes. Convulsive status epilepticus, with its clear behavioral manifestations, is usually diagnosed clinically. However, nonconvulsive status epilepticus (NCSE) is less clinically obvious than the convulsive subtype and may require EEG for detection and establishment of treatment efficacy. When the diagnosis of NCSE is made solely on EEG criteria, the diagnosis of “electrographic status epilepticus” can be used.

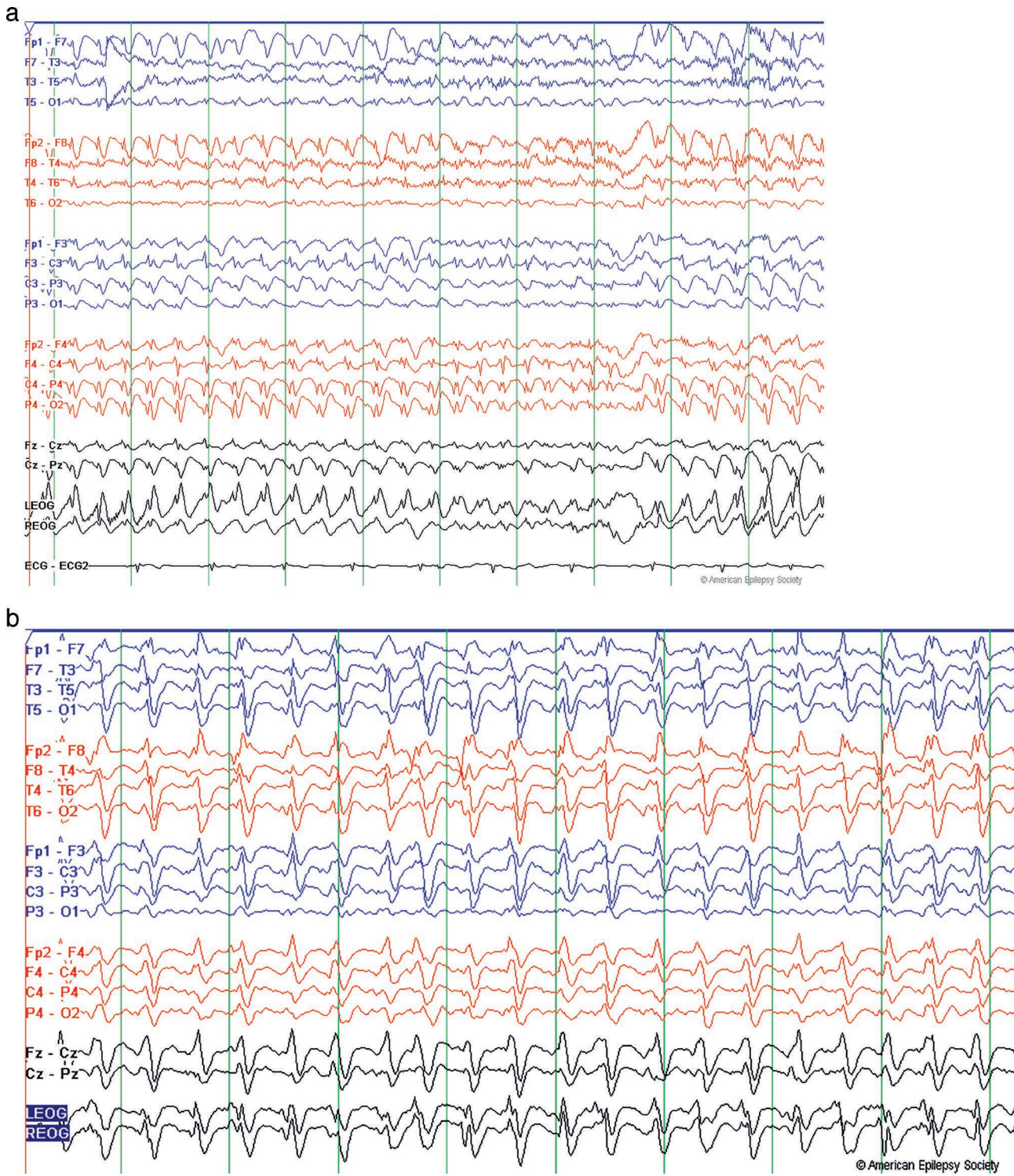
The detection of NCSE has important clinical implications. For example, the presence of nonconvulsive seizures (NCSz) or NCSE on CEEG was associated with worse clinical outcome, regardless of the etiology of the seizures (33). NCSz and NCSE on CEEG are also associated with increased morbidity and mortality after convulsive status epilepticus (34).

There are some data regarding how long patients should be monitored when NCSz are suspected. In one study, 95% of noncomatose patients who had NCSz did so within the first 24 hours of long-term video-EEG monitoring. However, only 80% of comatose patients who had NCSz did so within the first 24 hours (35).

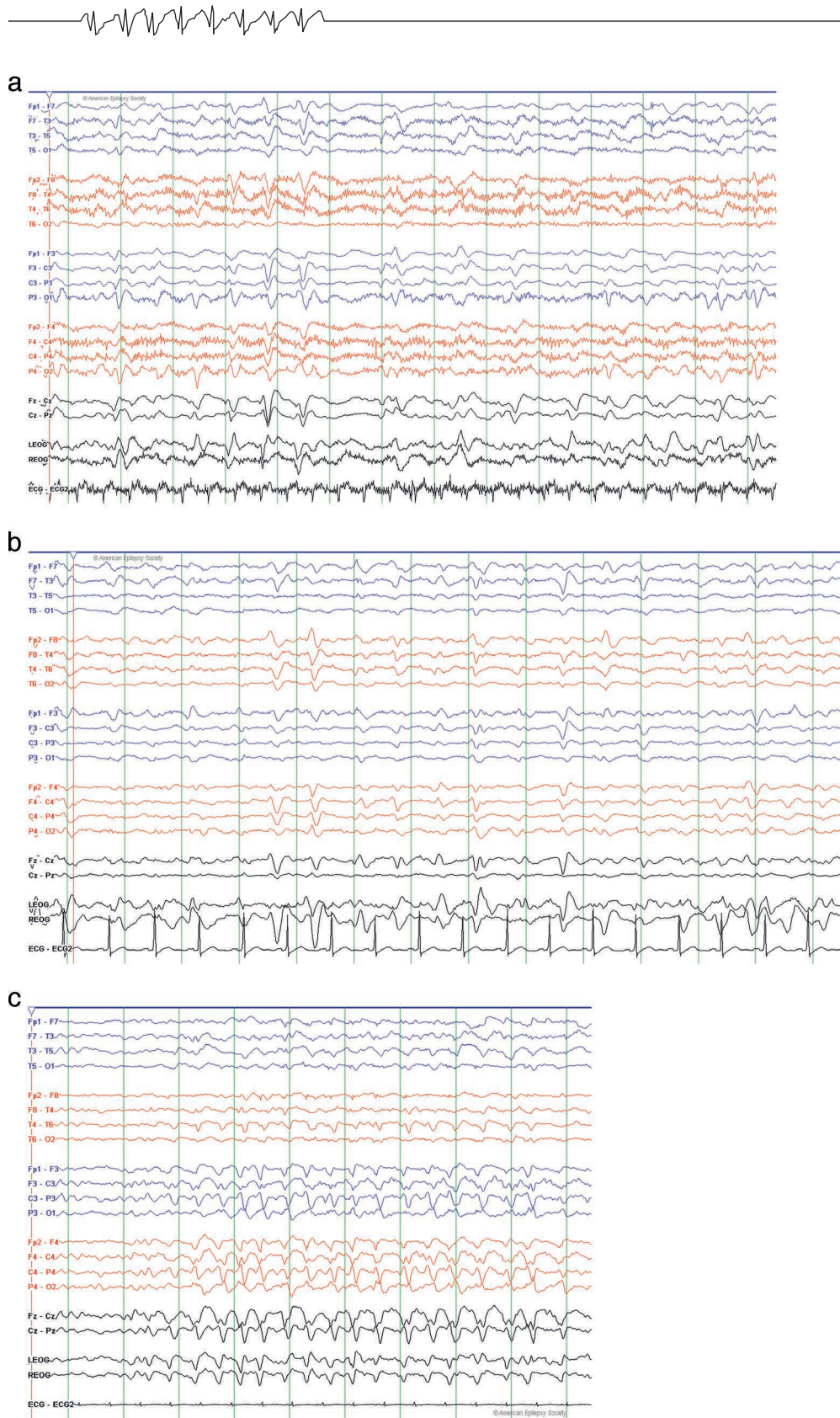
On EEG, NCSE can have a wide range of appearances, ranging from recurrent, discrete ictal discharges to more continuous repetitive epileptiform discharges or rhythmic slowing. An example of continuous epileptiform discharges can be seen in absence status, where the EEG contains repetitive, synchronous, and symmetric generalized spike and wave epileptiform discharges. There are no formal agreed-upon criteria for when continuous, frequent, epileptiform discharges represent electrographic status epilepticus (as opposed to frequent interictal epileptiform discharges, a known “gray area” in the field of EEG). However, work from Drislane can be used to help distinguish between an interictal state of frequent epileptiform discharges and electrographic status epilepticus (36). According to his criteria, electrographic status epilepticus can be diagnosed in the presence of epileptiform abnormalities that are rhythmic and rapid (2–3.5 Hz) on the EEG (see Figures 78, 79).



**Figure 78.** Generalized nonconvulsive status epilepticus. The EEG examples shown were recorded in a confused patient showing continuous generalized anterior predominant sharp activity (labeled “Pre-Lorazepam”). Resolution of generalized sharp activity is then shown post lorazepam infusion (labeled “Post-Lorazepam”). Longitudinal bipolar montage. Copyright 2013. Mayo Foundation for Medical Education and Research. All rights reserved. Figure courtesy of Jeffrey W. Britton, MD.



**Figure 79.** EEG examples of NCSE. The EEG in both (a) and (b) are displayed in a longitudinal bipolar display montage with a sensitivity of 7 mm/mV. (a) EEG contains spike and slow wave epileptiform discharges that are rhythmic and rapid (3 Hz). (b) EEG also contains sharp and slow wave epileptiform discharges that are rhythmic but are repeating at a slower frequency than those shown in (a). Figure courtesy of Lauren C. Frey, MD, University of Colorado.

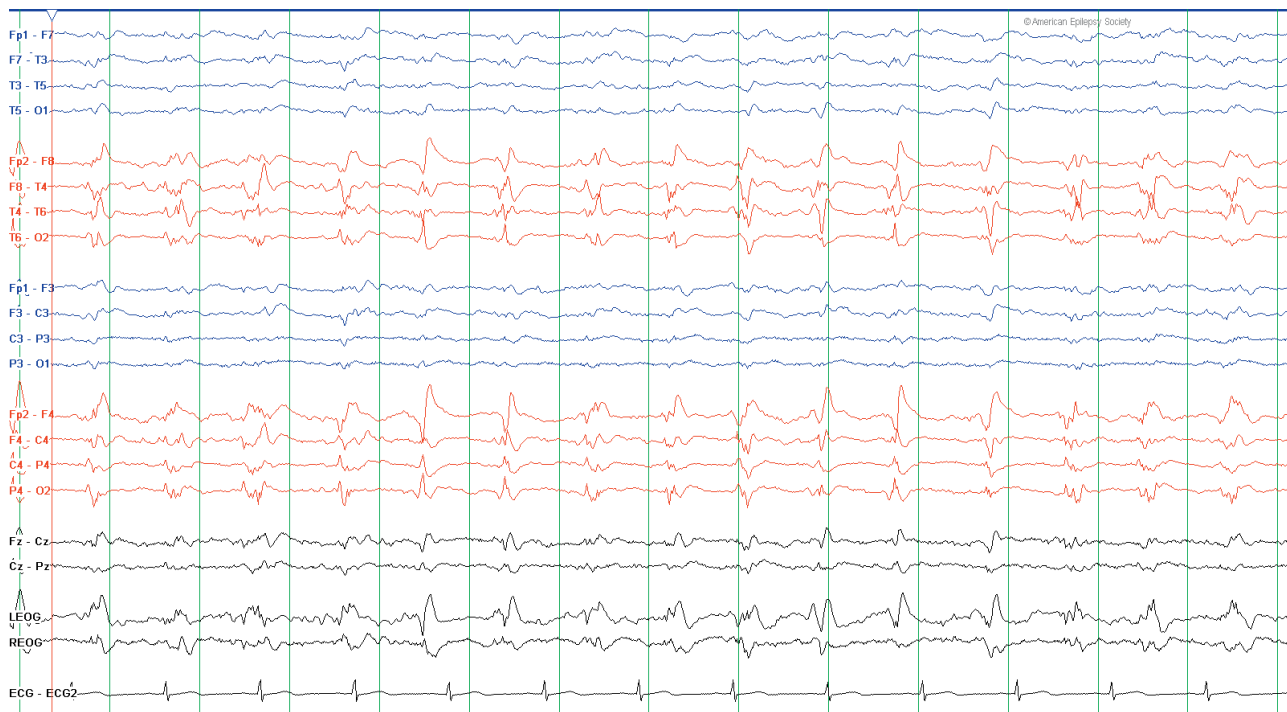


**Figure 80.** Triphasic waves. Triphasic waves can have multiple different EEG presentations. The triphasic waves in (a) and (b) occur singly with variable maxima. The triphasic waves in (c) are more uniform and occur repetitively. Figure courtesy of Lauren C. Frey, MD, University of Colorado.

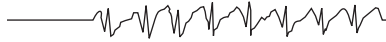Several EEG patterns in comatose or encephalopathic patients need to be distinguished from epileptiform activity. Triphasic waves are EEG waves that are identified by their specific triphasic morphology. A triphasic morphology means that the wave form has three phases, or excursions, around the baseline. The first phase is an excursion above the baseline, the second is below the baseline, and the third returns to above the baseline, making an extended, “m-like” shape. Each phase is longer in duration than the phase before. Triphasic waves (Figure 80) can occur in isolation or in repetitive trains (usually 1.5–2.5 Hz in frequency), can be frontally or more posteriorly maximal, and can be either unilateral or bilateral. Triphasic waves may increase with stimulation and may disappear with benzodiazepine administration. True triphasic waves are not considered to be ictal and, instead, are suggestive of a diffuse encephalopathy that is likely of metabolic origin.



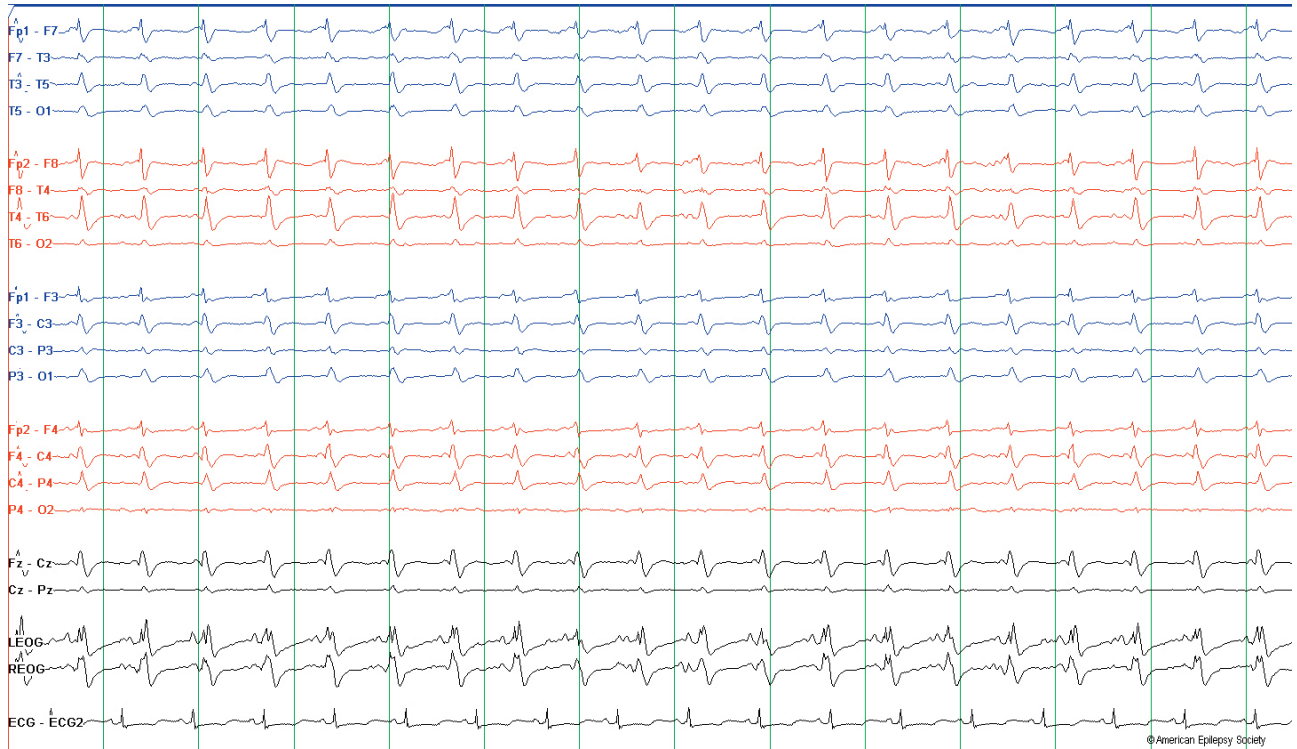LPDs are nearly continuous periodic epileptiform complexes that repeat at a slower frequency than those of NCSE (usually 1 Hz or less) (Figure 81). By definition, LPDs are maximal on one side of the brain or the other, but their field of distribution can include both sides in some patients. Although considered to be an interictal (nonseizure) pattern, LPDs represent a high degree of cortical irritability. Up to 80% of patients with LPDs have had or will also have electrographic seizures. LPDs are extremely difficult to suppress with antiseizure medications and will often self-resolve over days to weeks, as the pathology underlying the brain irritation resolves. The high mortality associated with the occurrence of LPDs on EEG is likely related to the severity of the underlying illness or CNS insult that resulted in the LPDs in the first place. LPDs that occur independently in both hemispheres are called bilateral periodic discharges (biPDs). The hemispheres usually differ in morphology, rate of repetition, and localization from each other. The occurrence of biPDs on EEG generally represents a worse clinical prognosis than the occurrence of LPDs.



**Figure 81.** LPDs. Lateralizing periodic discharges over the right hemisphere. Figure courtesy of Lauren C. Frey, MD, University of Colorado.

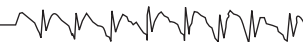

Generalized Periodic Discharges (GPDs) are bisynchronous, nearly continuous periodic epileptiform complexes (Figure 82). GPDs are not felt to represent NCSE, unless they are accompanied by stereotyped behaviors, raising concern for myoclonic status epilepticus. The presence of GPDs on EEG is concerning clinically, as they represent severe encephalopathy from CNS injury.



**Figure 82.** GPDs. Generalized periodic discharges. Longitudinal bipolar montage. Figure courtesy of Lauren C. Frey, MD, University of Colorado.





## References

1. Knowlton RC, Shih J. Magnetoencephalography in epilepsy. *Epilepsia* 2004;45(suppl 4):61–71.
2. Hari R, Salmelin R. Magnetoencephalography: From SQUIDs to neuroscience. Neuroimage 20th anniversary special edition. *Neuroimage* 2012;61:386–396.
3. Malmivuo J. Comparison of the properties of EEG and MEG in detecting the electric activity of the brain. *Brain Topogr* 2012;25:1–19.
4. Tekgul H, Bourgeois BF, Gauvreau K, Bergin AM. Electroencephalography in neonatal seizures: Comparison of a reduced and a full 10/20 montage. *Pediatr Neurol* 2005;32:155–161.
5. Salinsky M, Kanter R, Dasheiff RM. Effectiveness of multiple EEGs in supporting the diagnosis of epilepsy: An operational curve. *Epilepsia* 1987;28:331–334.
6. Tonini C, Beghi E, Berg AT, Bogliun G, Giordano L, Newton RW, Tetto A, Vitelli E, Vitezic D, Wiebe S. Predictors of epilepsy surgery outcome: A meta-analysis. *Epilepsy Res* 2004;62:75–87.
7. Panayiotopoulos CP, Obeid T, Tahan AR. Juvenile myoclonic epilepsy: A 5-year prospective study. *Epilepsia* 1994;35:285–296.
8. Ghogassian DF, d'Souza W, Cook MJ, O'Brien TJ. Evaluating the utility of inpatient video-EEG monitoring. *Epilepsia* 2004;45:928–932.
9. Friedman DE, Hirsch LJ. How long does it take to make an accurate diagnosis in an epilepsy monitoring unit? *J Clin Neurophysiol* 2009;26:213–217.
10. Malow BA, Passaro E, Milling C, Minecan DN, Levy K. Sleep deprivation does not affect seizure frequency during inpatient video-EEG monitoring. *Neurology* 2002;59:1371–1374.
11. Fisher RS, Harding G, Erba G, Barkley GL, Wilkins A; Epilepsy Foundation of America Working Group. Photic- and pattern-induced seizures: A review for the Epilepsy Foundation of America Working Group. *Epilepsia* 2005;46:1426–1441.
12. Privitera MD, Morris GL, Gilliam F. Postictal language assessment and lateralization of complex partial seizures. *Ann Neurol* 1991;30:391–396.
13. Mizrahi EM. Electroencephalographic-video monitoring in neonates, infants, and children. *J Child Neurol* 1994;9(suppl 1):S46–S56.
14. Mastrangelo M, Van Lierde A, Bray M, Pastorino G, Marini A, Mosca F. Epileptic seizures, epilepsy and epileptic syndromes in newborns: A nosological approach to 94 new cases by the 2001 proposed diagnostic scheme for people with epileptic seizures and with epilepsy. *Seizure* 2005;14:304–311.
15. So EL. Value and limitations of seizure semiology in localizing seizure onset. *J Clin Neurophysiol* 2006;23:353–357.
16. Lobello K, Morgenlander JC, Radtke RA, Bushnell CD. Video/EEG monitoring in the evaluation of paroxysmal behavioral events: Duration, effectiveness, and limitations. *Epilepsy Behav* 2006;8:261–266.
17. Chen LS, Mitchell WG, Horton EJ, Snead OC III. Clinical utility of video-EEG monitoring. *Pediatr Neurol* 1995;12:220–224.
18. Cascino GD. Video-EEG monitoring in adults. *Epilepsia* 2002;43(suppl 3):80–93.
19. Benbadis SR, O'Neill E, Tatum WO, Heriaud L. Outcome of prolonged video-EEG monitoring at a typical referral epilepsy center. *Epilepsia* 2004;45:1150–1153.
20. Asano E, Pawlak C, Shah A, Shah J, Luat AF, Ahn-Ewing J, Chugani HT. The diagnostic value of initial video-EEG monitoring in children—Review of 1000 cases. *Epilepsy Res* 2005;66:129–135.
21. Benbadis SR. The EEG in nonepileptic seizures. *J Clin Neurophysiol* 2006;23:340–352.
22. Bodde NM, Brooks JL, Baker GA, Boon PA, Hendriksen JG, Aldenkamp AP. Psychogenic non-epileptic seizures—Diagnostic issues: A critical review. *Clin Neurol Neurosurg* 2009;111:1–9.
23. Hadjikhoutis S, O'Callaghan P, Smith PE. The investigation of syncope. *Seizure* 2004;13:537–548.
24. ILAE. Proposal for revised classification of epilepsies and epileptic syndromes. Commission on Classification and Terminology of the International League Against Epilepsy. *Epilepsia* 1989;30:389–399.
25. Sirven JI. Classifying seizures and epilepsy: A synopsis. *Semin Neurol* 2002;22:237–246.
26. Seino M. Classification criteria of epileptic seizures and syndromes. *Epilepsy Res* 2006;70(suppl 1):S27–S33.
27. Noachtar S, Peters AS. Semiology of epileptic seizures: A critical review. *Epilepsy Behav* 2009;15:2–9.
28. Noachtar S, Remi J. The role of EEG in epilepsy: A critical review. *Epilepsy Behav* 2009;15:22–33.
29. Zangaladze A, Nei M, Liporace JD, Sperling MR. Characteristics and clinical significance of subclinical seizures. *Epilepsia* 2008;49:2016–2021.
30. Loddenkemper T, Kotagal P. Lateralizing signs during seizures in focal epilepsy. *Epilepsy Behav* 2005;7:1–17.
31. Mackay MT, Weiss SK, Adams-Webber T, Ashwal S, Stephens D, Ballaban-Gill K, Baram TZ, M. Duchowny M, Hirtz D, Pellock JM, Shields WD, Shinnar S, Wyllie E, Snead OC III; American Academy of Neurology; Child Neurology Society. Practice parameter: Medical treatment of infantile spasms: Report of the American Academy of Neurology and the Child Neurology Society. *Neurology* 2004;62:1668–1681.
32. Lowenstein DH. Status epilepticus: An overview of the clinical problem. *Epilepsia* 1999;40(suppl 1):S3–S8; discussion S21–S22.
33. Jaitly R, Sgro JA, Towne AR, Ko D, DeLorenzo RJ. Prognostic value of EEG monitoring after status epilepticus: A prospective adult study. *J Clin Neurophysiol* 1997;14:326–334.
34. DeLorenzo RJ, Waterhouse EJ, Towne AR, Boggs JG, Ko D, DeLorenzo GA, Brown A, Garnett L. Persistent nonconvulsive status epilepticus after the control of convulsive status epilepticus. *Epilepsia* 1998;39:833–840.
35. Claassen J, Mayer SA, Kowalski RG, Emerson RG, Hirsch LJ. Detection of electrographic seizures with continuous EEG monitoring in critically ill patients. *Neurology* 2004;62:1743–1748.
36. Drislane FW. Presentation, evaluation, and treatment of nonconvulsive status epilepticus. *Epilepsy Behav* 2000;1:301–314.
37. Ebersole JS, Pedley TA, eds. *Current Practice of Clinical Electroencephalography*. New York: Lippincott Williams & Wilkins, 2003.



38. American Clinical Neurophysiology Society. Minimum technical standards for EEG recording in suspected cerebral death (2006). American Clinical Neurophysiology Society Web site. <http://www.acns.org/pdfs/Guideline%203.pdf>. Accessed Month day, Year.

### Additional Texts and Recommended Readings

- Briel RC, McKeith IG, Barker WA, Hewitt Y, Perry RH, Ince PG, Fairbairn AF. EEG findings in dementia with Lewy bodies and Alzheimer's disease. *J Neurosurg Psychiatry* 1999;66:401–403.
- Fisch B. *Fisch and Spehlmann's EEG Primer: Basic Principles of Digital and Analog EEG*. 3rd ed. City: Elsevier, 1999.
- Gastaut H, Broughton RJ. Chapter title. In: *Epileptic Seizures: Clinical and Electroencephalographic Features, Diagnosis and Treatment*. City: Thomas, 1972:25–37.
- Hirsch LJ, Brenner RP, eds. *Atlas of EEG in Critical Care*. Hoboken, NJ: John Wiley & Sons, 2010.
- Holmes GL, Moshé SL, Royden Jones H Jr, eds. *Clinical Neurophysiology of Infancy, Childhood and Adolescence*. Philadelphia: Butterworth Heinemann Elsevier, 2006.
- Jayalakshmi SS, Mohandas S, Sailaja S, Borgohain R. Clinical and electroencephalographic study of first-degree relatives and probands with juvenile myoclonic epilepsy. *Seizure* 2006;15:177–183.
- Schomer DL, Lopes da Silva F, eds. *Niedermeyer's Electroencephalography: Basic Principles, Clinical Applications, and Related Fields*. 6th ed. Philadelphia: Wolters Kluwer/Lippincott Williams & Wilkins, 2010.
- Sirven J, Stern J. *Atlas of Video-EEG Monitoring*. New York: McGraw-Hill Professional, 2010.
- Steinhoff BJ, Racker S, Herrendorf G, Poser S, Grosche S, Zerr I, Kretzschmar H, Weber T. Accuracy and reliability of periodic sharp wave complexes in Creutzfeldt-Jakob disease. *Arch Neurol* 1996;53:162–166.
- Stern JM, Engel J Jr. *An Atlas of EEG Patterns*. Lippincott Williams & Wilkins, 2004.
- Tatum WO IV, Husain AM, Benbadis SR, Kaplan PW. *Handbook of EEG Interpretation*. New York: Demos Medical Publishing, 2007.
- Yamada T, Meng B. *Practical Guide for Clinical Neurophysiologic Testing*. Vol 1–2. Philadelphia: Wolters Kluwer/Lippincott Williams & Wilkins, 2010–2011.
- Young GB. The EEG in coma. *J Clin Neurophysiol* 2000;17:473–485.

### Appendix 1. The Scientific Basis of EEG: Neurophysiology of EEG Generation in the Brain

The electrical activity measured by scalp EEG recordings is generated by similarly oriented groups of cerebral cortical neurons near the scalp where the recording electrodes are placed. Each scalp electrode collects, at a minimum, an estimated 6 cm<sup>2</sup> synchronous cortical activity. The majority of the electrical activity collected in the EEG is generated by groups of pyramidal neurons. These cells have cell bodies primarily in layers three and five of the cerebral cortex. The electrical activity recorded on the scalp represents the summation of the inhibitory or excitatory postsynaptic potentials (not action potentials—action potentials are too short to be recordable) from thousands of pyramidal cells near each recording electrode. This summated activity can be represented as a field with positive and negative poles (dipole). The dipole vector, or direction of energy flow, is parallel to the orientation of the pyramidal cells generating the activity. Negative dipoles are maximally sensed when they are perpendicular to and heading directly into a recording electrode position. In this case, the positive end of the dipole is subcortical and can be recorded only with depth electrodes. If the electrical source is in a fissure, the dipole can be tangent or parallel.

There are systematic interconnections between cortical neurons, as well as cortical to subcortical connections to structures such as the thalamus, that have well-developed feed-back linkages. Any sinusoidal rhythmic activity seen on the EEG is thought to represent oscillatory communications between the cortex and deeper, subcortical structures. These communication loops occur when the cortex is at rest or is not performing any specific task. Once the cortex has a task to perform, the electrical activity of the cortex desynchronizes, and lower amplitude, faster electrical rhythms take predominance until the cortex completes its task and returns to a resting state. The most well-known example of this is the PDR. This is an oscillatory, 8.5- to 12-Hz rhythm seen in the posterior head regions during relaxed wakefulness with eyes closed. The PDR classically attenuates with eye opening because eye opening starts a stream of visual input that activates the visual cortex at the back of the head. With activation, the visual cortex desynchronizes and transiently disrupts communication with the thalamus in order to process the new visual information. This desynchronization results in transient disappearance of the PDR.

### Appendix 2. Principles of Digital EEG

#### EEG Signal Collection and Display

##### Signal Collection

Scalp EEG electrodes are pasted or glued to the scalp using the International 10-20 System of electrode placement. This system uses the distances between bony landmarks on the head to create a system of lines. Recording electrodes are then placed at intervals of 10 or 20 percent of the total length of these lines. The primary advantage of using such a proportional system is that it will identify the same relative position on the scalp regardless of head size. The standard EEG setup for adults consists of 21 recording electrodes plus 1 ground electrode, and electrodes for a single channel of EKG and to record eye movements. Each electrode position is identified by a letter and number. The letters indicate the position of the electrode on the head: Fp, frontopolar; F, frontal; C, central; T, temporal; P, parietal; O, occipital. Odd numbers are used over the left hemisphere and even numbers over the right hemisphere. A lowercase “z” indicates a midline scalp position. Additional scalp electrodes may be placed at smaller proportional distances within the 10-20 System to more precisely represent the electrical activity within a certain brain region. For



example, the best localization to detect an anterior temporal spike in a patient is often not ideally covered by the 10-20 System arrangement, and special anterior temporal electrodes (T1 and T2) can be added.

#### *Amplification and Filtering*

All EEG activity is recorded with differential amplifiers. These devices measure the electrical activity at one electrode relative to another, thus eliminating much of the common activity between the electrodes (“common mode rejection”). Because artifact, both biologic and ambient, is relatively similar around the head, it will often be substantially eliminated through the use of differential amplifiers. This “cancelling out” of signal leaves the brain activity of interest and can notably improve the signal-to-noise ratio in the recording. The amplifier also increases the voltage difference, so it may be visualized. EEG sensitivity is the ratio of the input voltage to the signal deflection. It is measured in microvolts per millimeters. The commonly used sensitivity is 7  $\mu\text{V}/\text{mm}$  but can be adjusted up or down to make the EEG easier to visualize.

Filters are used to minimize activity of relatively high or low frequency so that the waveforms in the most important range (1–30 Hz) can be recorded clearly and with minimal distortion. At present, EEG machines have three types of filtering. There is a low-frequency filter that removes the amplitude of slow waves, a high-frequency filter that reduces the amplitude of fast waves, and a notch filter that selectively reduces the amplitude of waves in a narrow frequency to remove electrical line interference. In North America, the notch filter is set at 60 Hz. At the current time, these filters tend to be created by analog technology. As a result, the filters are not absolute, and they do not perfectly remove or preserve all frequencies above or below the individual formal settings but instead provide a continuum of gradual filtering; consequently, they cannot get rid of all recorded artifacts and may, in fact, distort them to the extent that pathologic wave forms are no longer recognizable.

#### *EEG Display*

After collection, EEG signal is displayed on the screen in specific montages, or arrangements. As a general rule, modern montages allow for easy visualization of comparable scalp areas, so they may be assessed for symmetry. There are two primary types of display montages: bipolar and monopolar/referential. Bipolar montages consist of chains of electrodes, each one connected to one or two neighboring electrodes. The bipolar longitudinal pattern, also called the “double banana,” is a commonly used bipolar montage. It consists of a display in which each channel connects adjacent electrodes from anterior to posterior in two lines, essentially covering the parasagittal and temporal areas bilaterally. The midline electrodes are also linked in a chain fashion. The bipolar transverse montage links adjacent electrodes in a chain, going from left to right. Monopolar, or referential montages, connect each electrode to a single referential point. This reference can be either another electrode on the scalp or a mathematical combination of signals, such as a mathematical average reference.

Localization of abnormalities in a bipolar recording system involves identifying the head region with the phase-reversal and assuming that the abnormal signal was generated within this head region. Localization of abnormalities in a referential system involves identifying the head region with the highest amplitude abnormalities and assuming that the abnormal signal was generated within this head region.

The major disadvantage of bipolar signal collection is that there can be in-phase cancellation of biological activity. In other words, if the biologic waveform at the two points compared is relatively synchronous, with respect to both time and amplitude, the differential amplifier can “cancel” them out, which can lead to false localization of low-amplitude phenomenon. The strength of referential montages is that in-phase cancellation does not occur. However, there is no perfect reference; the disadvantage of monopolar displays is the chance that the reference will be contaminated with signal, making EEG interpretation more difficult. In EEG interpretation, multiple montages should be used, and all abnormalities should be confirmed on multiple montages to determine that they are pathologic not simply a reflection of the method of signal display.

#### *Advantages of Digital EEG*

Digital EEG is currently the most common EEG recording method. However, it is still relatively new to EEG, thus to ensure consistency among interpretations of paper and digital records, principles for digital EEG collection and storage have been developed. All digital EEG systems should have the following capabilities:

- Post hoc manipulation of EEG signal through application of multiple filters and adjustment of scaling parameters and display montages;
- Digital storage of patient information, real-time technologist comments and recording settings in conjunction with the EEG record; and
- Recording of calibration and biocalibration signals within the record.

In addition, system sample rate and other digitalization parameters should be sufficient to prevent signal aliasing or distortion of the record through the digitalization process. The method and duration of long-term storage of digital EEG records may be governed by medical records statutes—be sure to check local requirements.



### **Appendix 3. Principles of Electrical Safety**

Overall, EEG is very safe for both the technologist and patient. However, there are known risks associated with the procedure. Exposure to electrical current is the most important determinant of injury risk and can cause injuries ranging from skin burns to induction of seizures or ventricular fibrillation. According to Ebersole and Pedley's definitive text, there are multiple potential sources that can allow harmful currents to flow through patients connected to EEG equipment, including currents from improper grounding, leakage, and double-grounding (37). Electrical grounding is very important in preventing leakage of current through the patient in case of aberrant current flow through the EEG equipment. Grounding is dependent on both the fuses within the EEG machine and the use of proper outlets to ground the machine within the room. Leakage currents can be from either stray capacitance or stray inductance and are most dangerous when combined with improper grounding. Double-grounding presents electrical risk to the EEG patient because of the existence of differences in potential between the grounds. These differences in electrical potential create gradients for current flow through the double-grounded patient. Double-grounding is most likely to occur in medical settings where patients are attached to multiple (grounded) devices.

Tips to maintain electrical safety and avoid exposure of patients to current include the following:

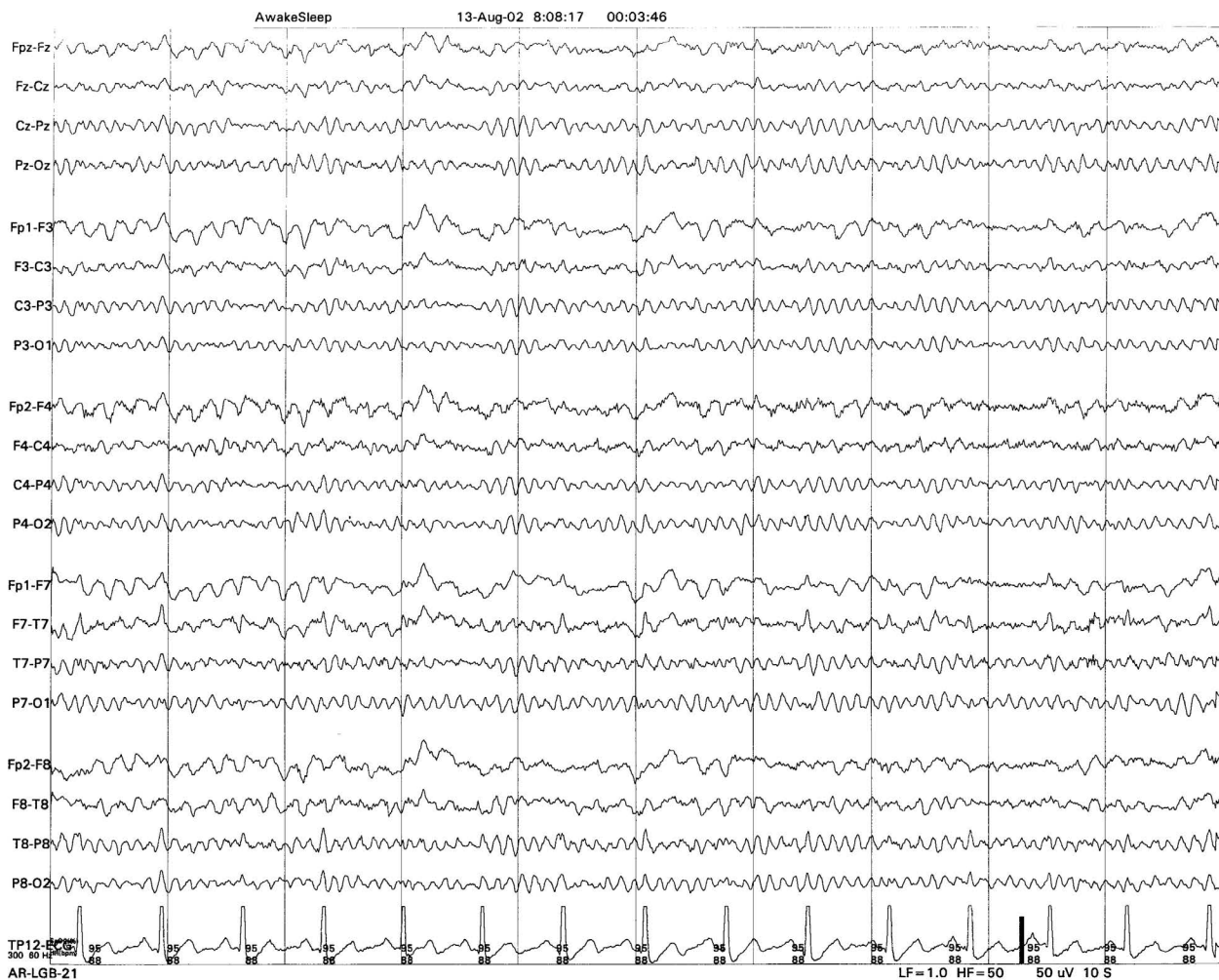
- Establish regular EEG equipment maintenance, including protection with proper fuses.
- Always use a grounding electrode, except in situations (e.g., intensive care unit, operating room) in which other electrical equipment is attached to the patient (double-grounding must be avoided).
- Always connect ground electrodes to the appropriate jack of the input jack box (never to the equipment chassis or another earth ground).
- Always use a three-prong plug. Hospital-grade power outlets should be used whenever possible. Do not use a three-prong to two-prong converter, as the converter does not provide the same protection as an actual grounded plug.
- Do not use extension cords for EEG machines.



### Appendix 4. Common Artifacts During EEG Recording

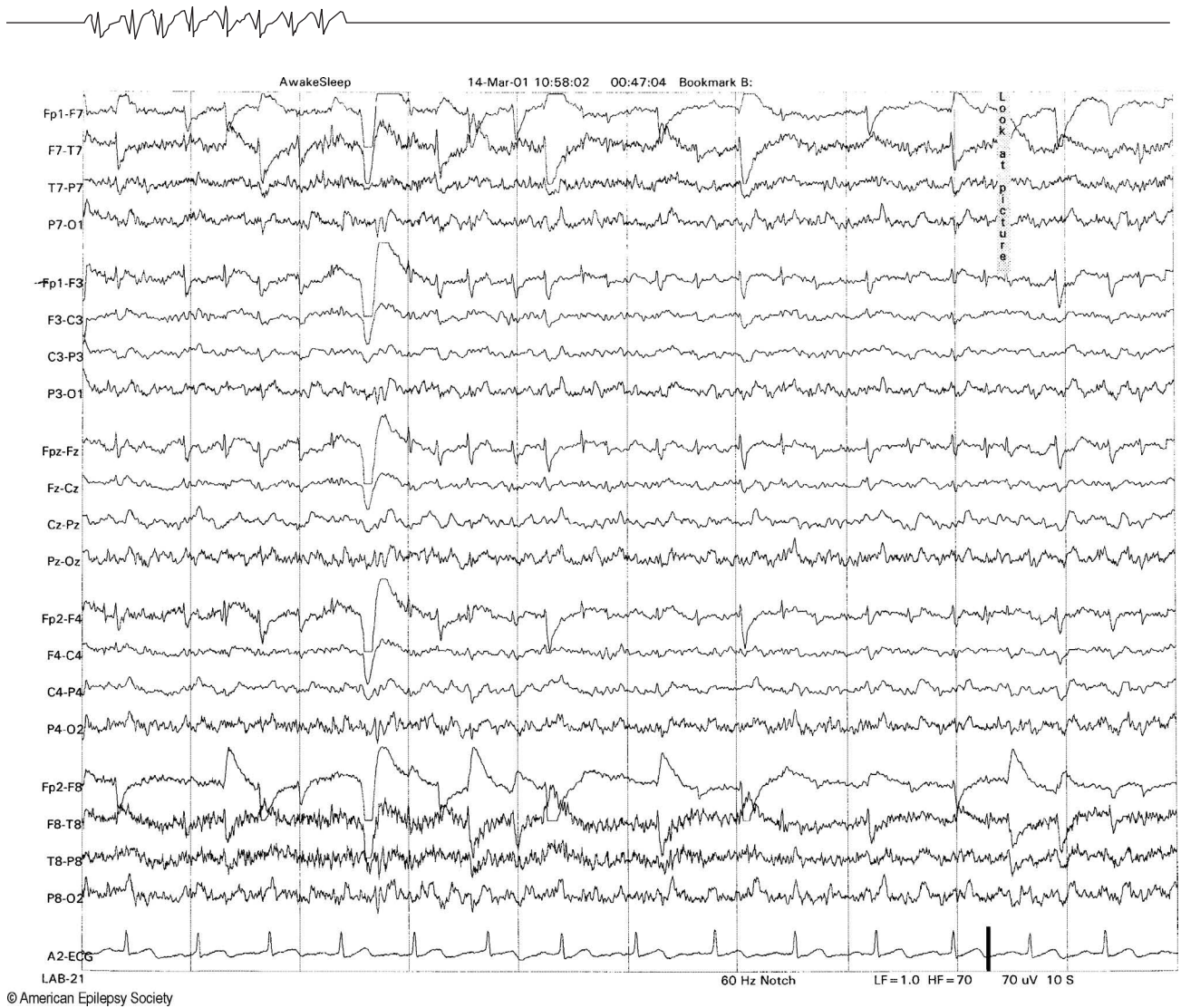Amongst the very primary considerations behind EEG interpretation is to realize that artifact is legion and pervasive. The interpreter must always beware of the possibility that a waveform in question may be an artifact. The two chief categories of artifact are physiological/biological or nonphysiological artifacts, resulting from electrical phenomena or devices in the recording environment. Physiological artifacts may include cardiac, pulse, respiratory, sweat, glossokinetic, eye movement (blink, lateral rectus spikes from lateral eye movement), and muscle and movement artifacts. Examples of each type are shown in the figures below.

#### Eye Movements

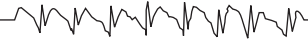

© American Epilepsy Society

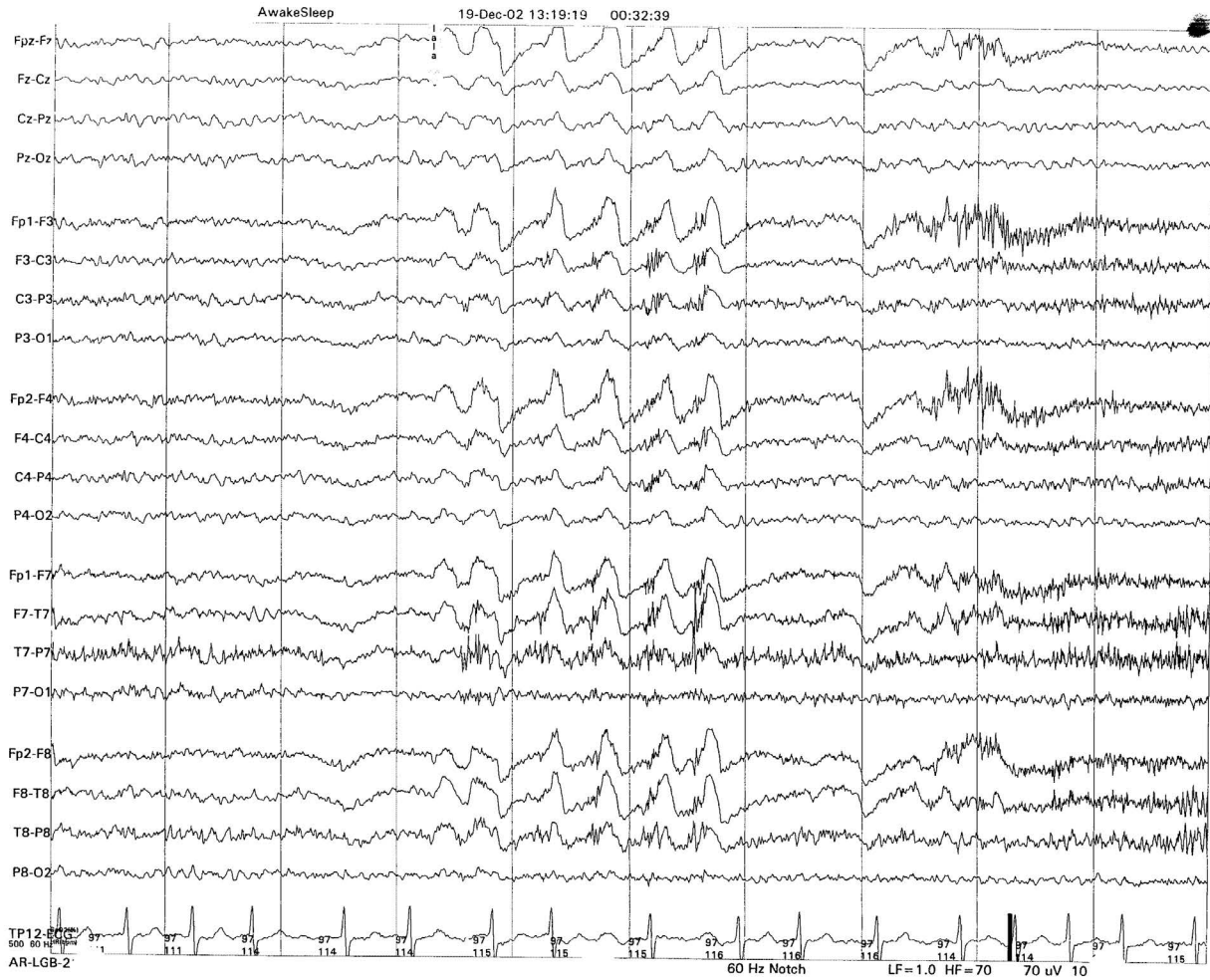
**Figure 83.** Eye flutter evident in the frontopolar and anterior leads.



**Figure 84.** Rapid eye movements generate small spike-like discharges in the frontopolar derivations.

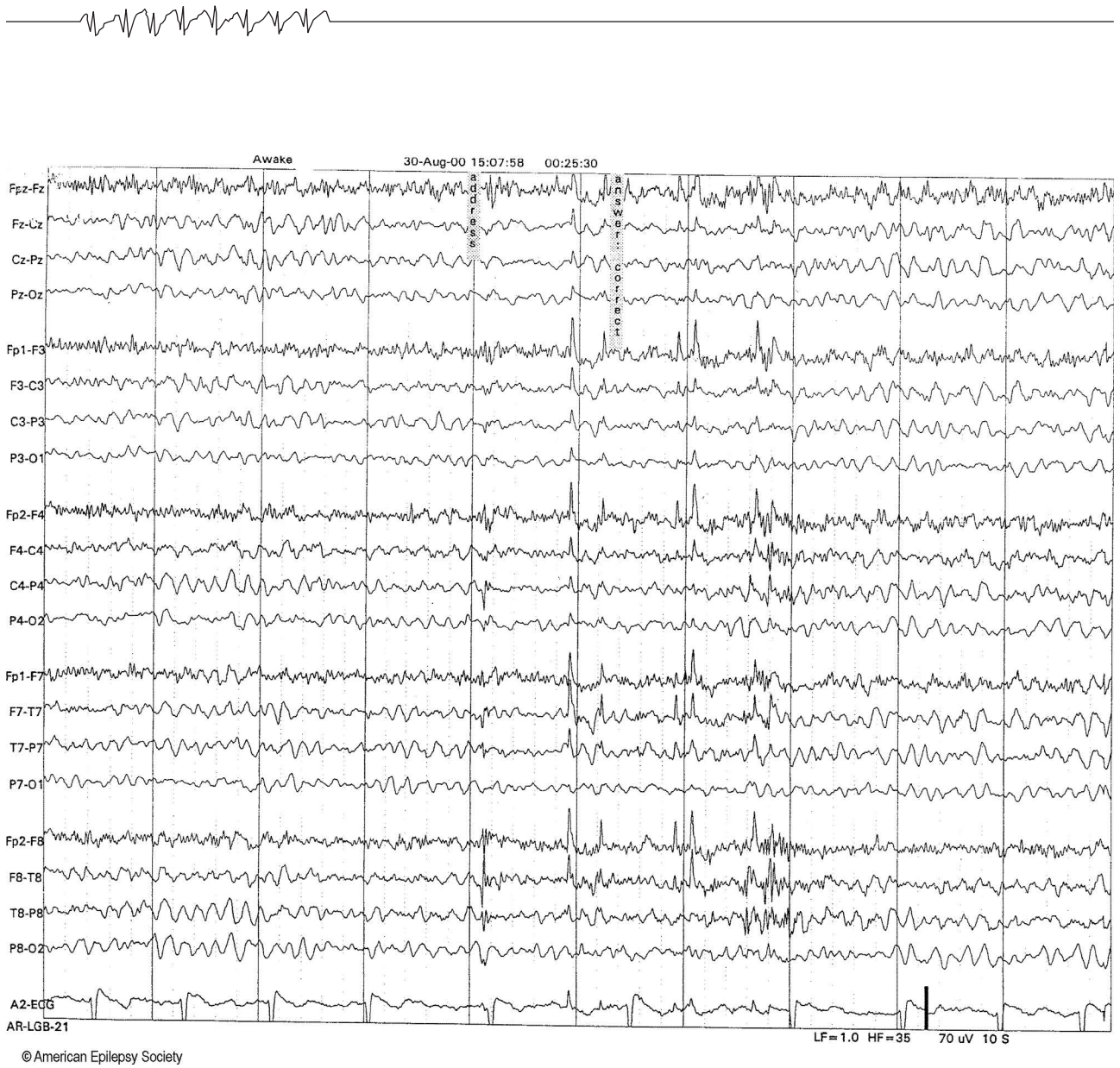


**Tongue Movements, Talking, and Chewing**



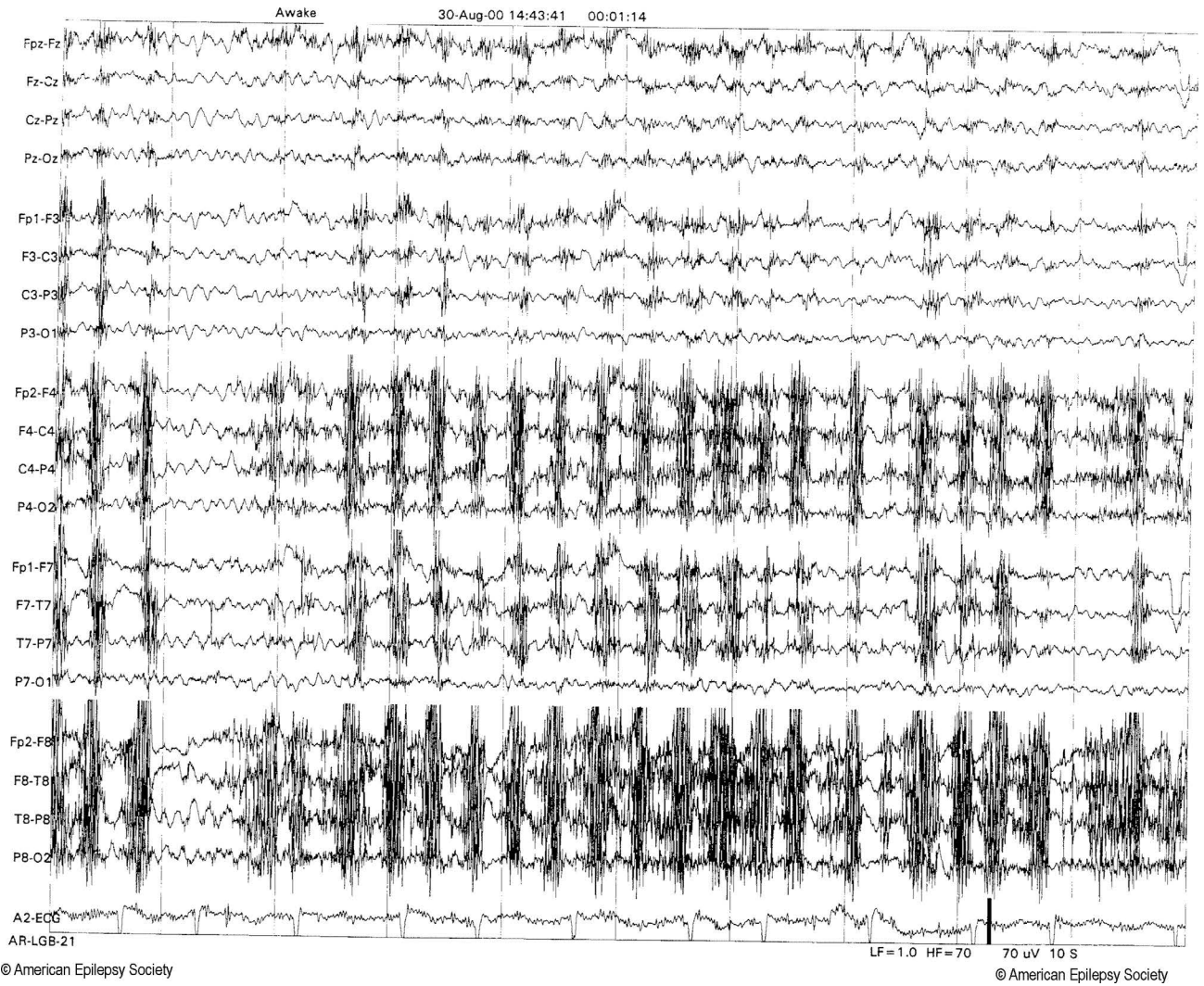
© American Epilepsy Society

**Figure 85.** Glossokinetic potentials from tongue movement, reproducible by having the patient say "la, la."

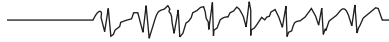

**Figure 86.** Dissimilar metals causing electrostatic artifacts during talking generate spiky waveforms in seconds 5 through 8 of this epoch.

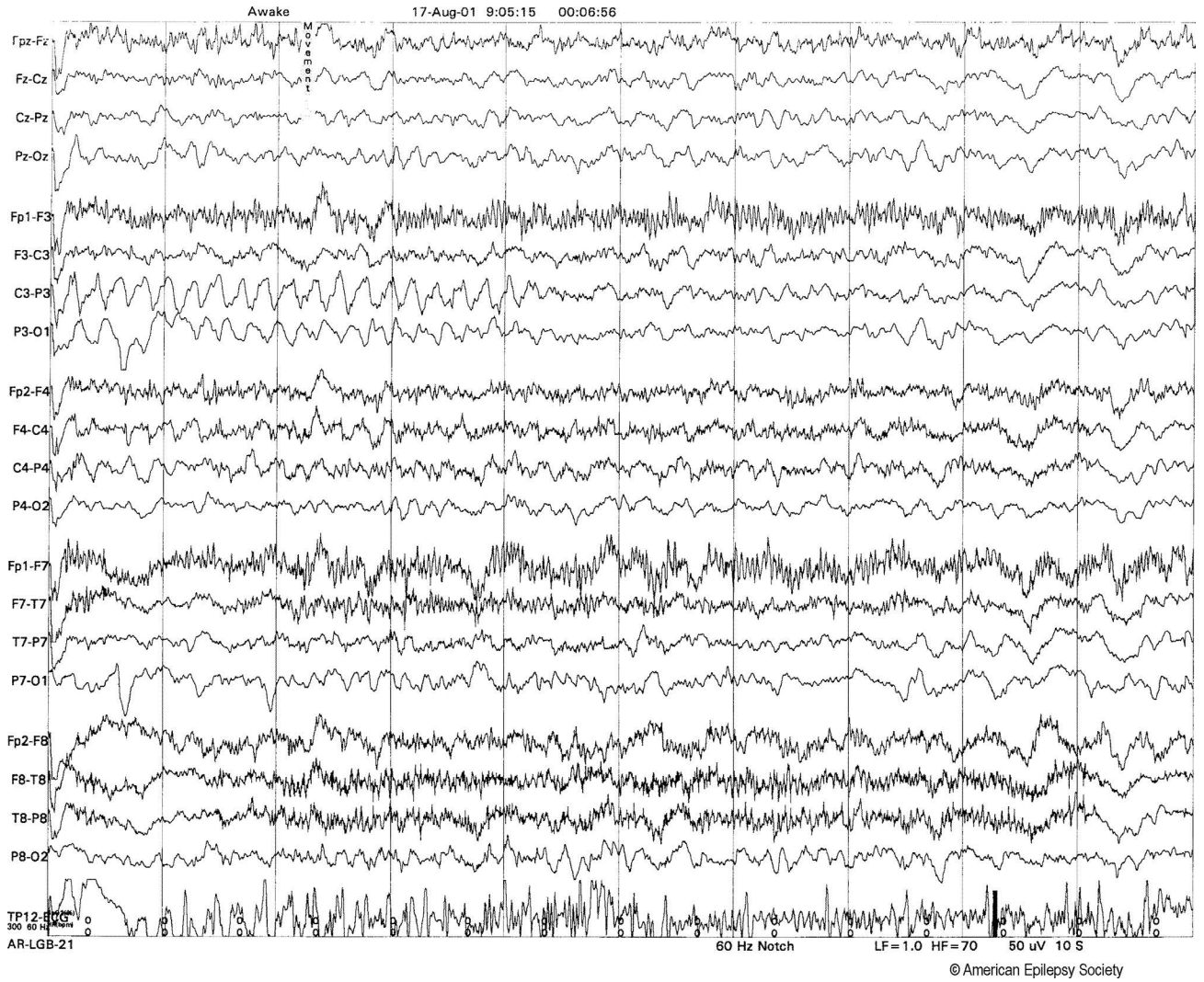




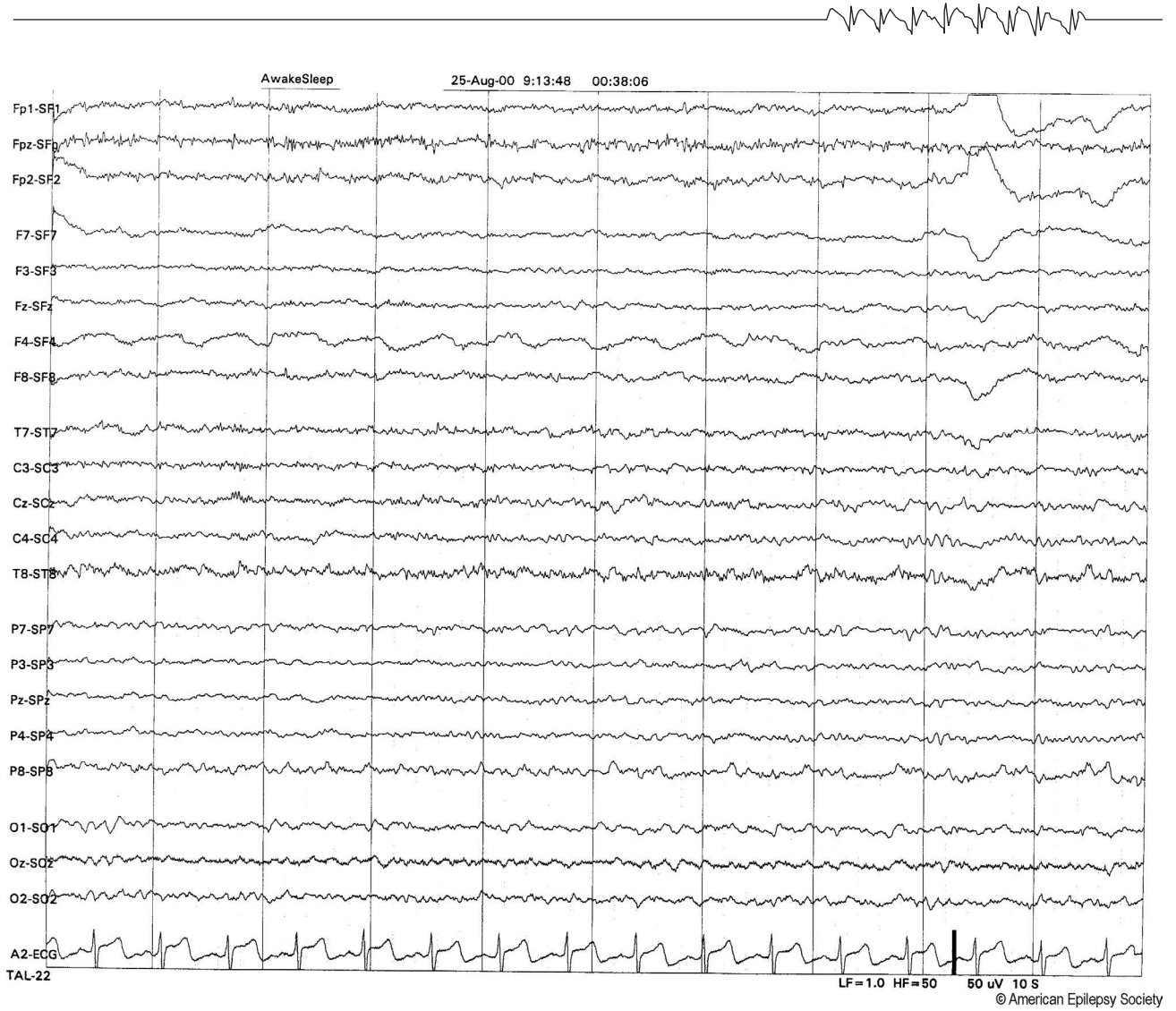**Figure 87.** Chewing artifact.



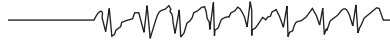**Movement Artifacts**



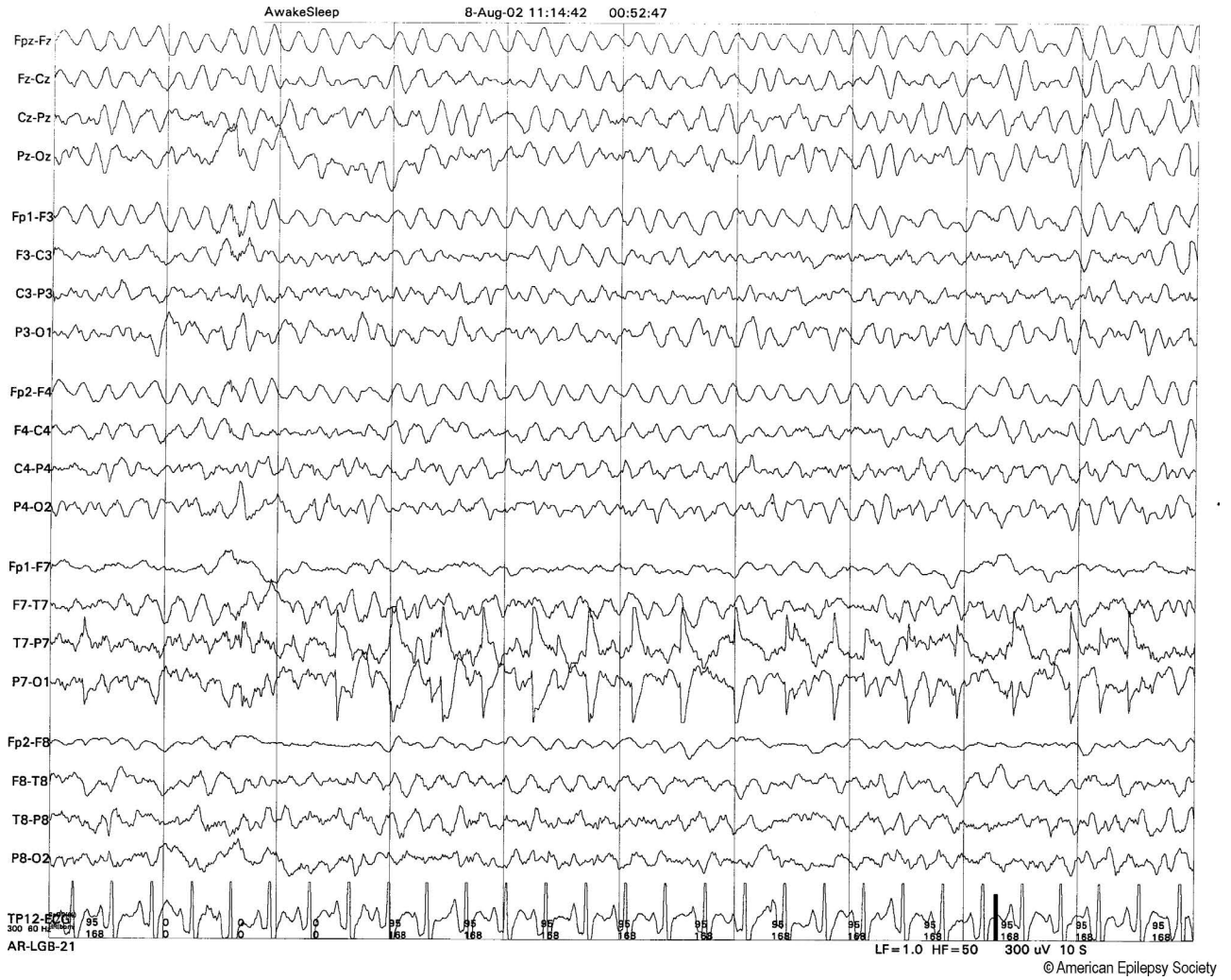**Figure 88.** Movement artifact mimicking a partial seizure discharge at the P3 electrode.



**Figure 89.** Pulse artifact creates rhythmic slow wave artifact at F4. Note the frequency mirrors that of the cardiac cycle.



**Electrode Artifacts**



**Figure 90.** Electrode “pop” artifact at P7 simulates rhythmic seizure activity.

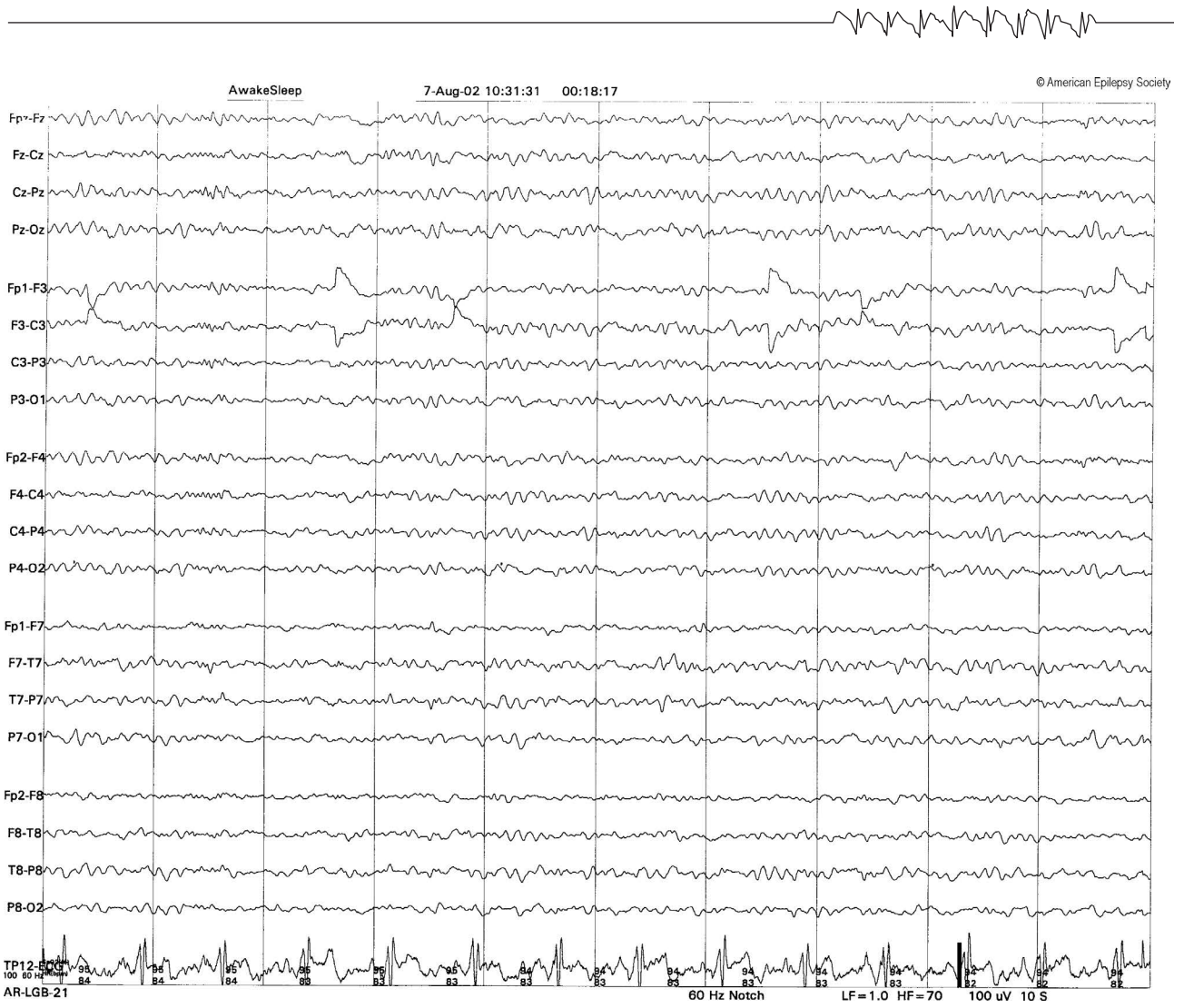
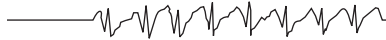
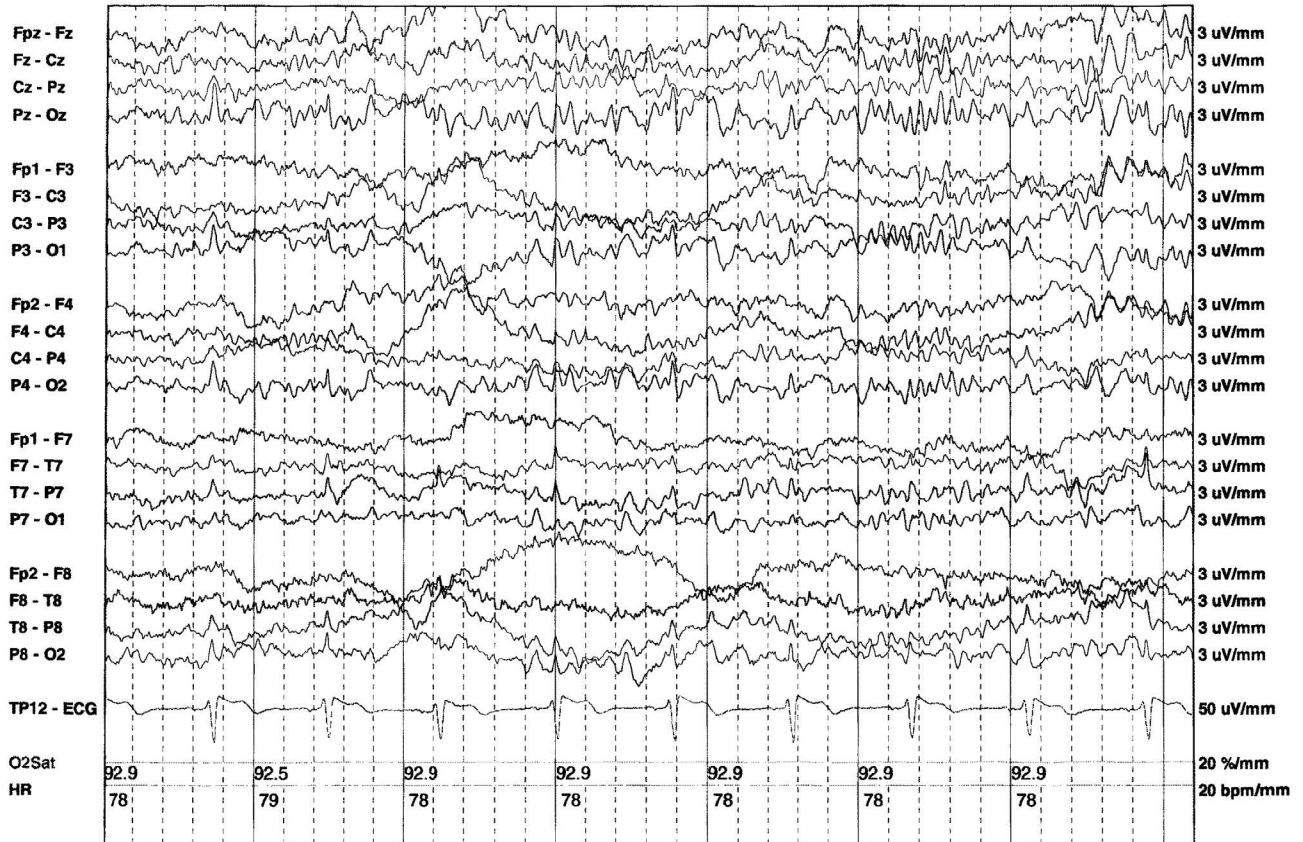
Figure 91. Electrode “pop” artifact at F3.



Sweat Artifact

Creation Date: 13:57:41 Mar 22, 2004

Print Date: 09:36:17 Mar 23, 2004



03/22/2004 14:57:32 - 03/22/2004 14:57:39  
Page 1

7.19 sec/page, 1 sec/div, 30 mm/sec  
Gain:3 uV/mm, LFF:1 Hz, HFF:70 Hz, Notch:Off



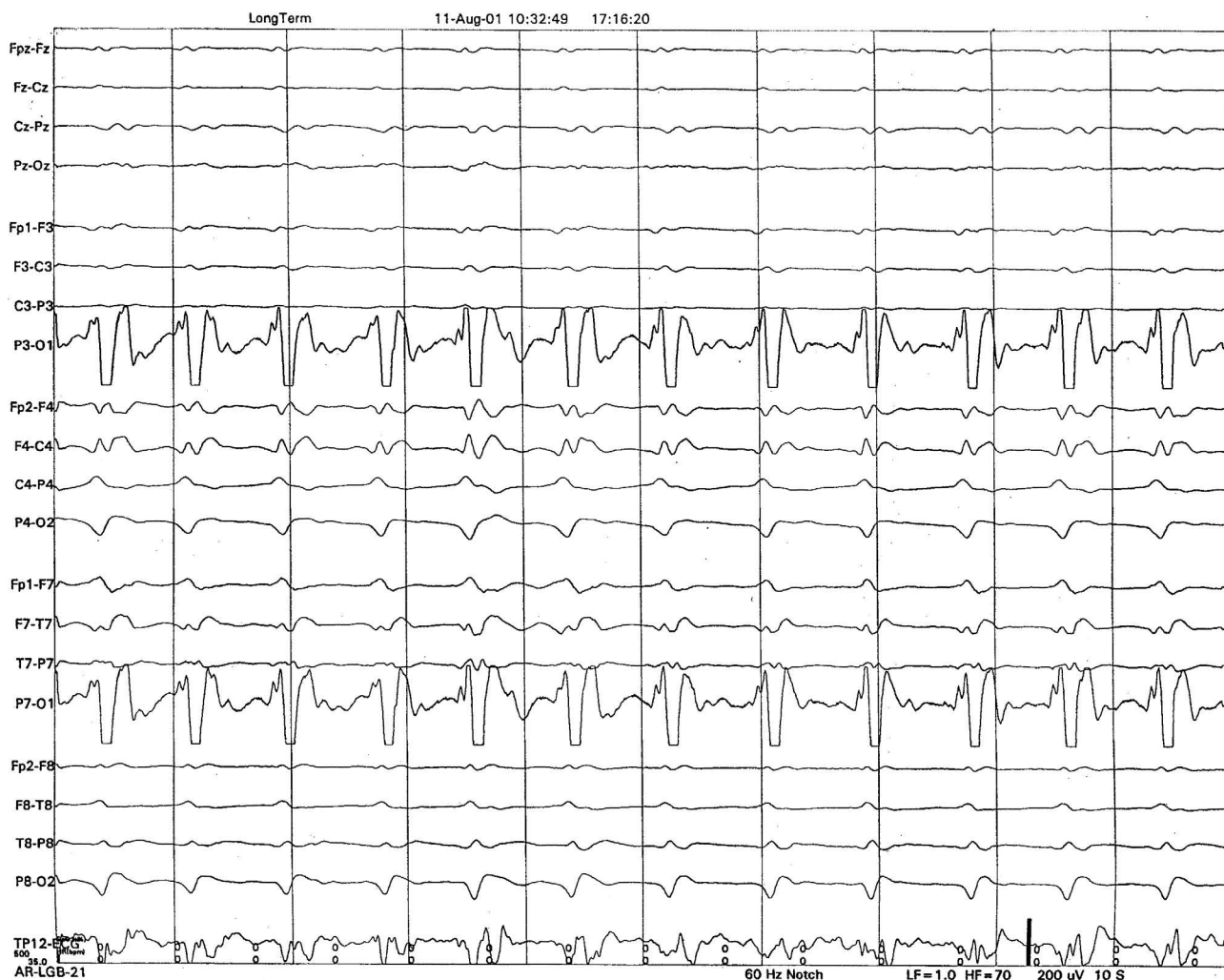© American Epilepsy Society

Figure 92. Sweat artifact.



**Appendix 5. EEG Standards and Examples for the Determination of Brain Death**

EEG may be used as an ancillary test to confirm clinical brain death. Specifications for determining electrocerebral silence (ECS, or electrophysiological brain death) by the American EEG Society (more recently confirmed and updated by the American Clinical Neurophysiology Society in 2006) require the following conditions: the patient should be warmed to a temperature greater than 32°C; no confounding sedative/hypnotic or anesthetic medications should be present; a qualified technologist should conduct the recording; the recording should be performed with at least 16-channel recording; integrity of the recording system should be manually tested by the technologist during the recording; there should be no reactivity of the patient to any somatosensory, auditory, or visual stimulus; the electrode impedances should be maintained between 10 Ω and 10 kΩ; the recording should utilize long (i.e., 10 cm minimum) interelectrode distances (to maximize the opportunity of recording highly suppressed true cerebral activity); other polygraphic variables (ECG, respiration, “dummy patient” for noise monitoring) should be monitored as needed; recording should be in bandwidth from 1 to 30 Hz low/high frequency filter settings; and higher sensitivity settings of at least 2 uV/mm should be used to ensure there is no cerebral activity present for at least 30 minutes in duration. If there is doubt, a repeat study should be performed (38).



**Figure 93.** Electrocerebral silence (brain death). Note the prominent cardiac cycle artifact, especially in O1, with the absence of any discernible cerebral activity.

**Appendix 6. A Brief History of EEG**

Richard Caton (1842–1926), an English scientist, is credited with discovering the electrical properties of the brain, by recording electrical activity from the brains of animals using a sensitive galvanometer, noting fluctuations in activity during sleep and absence of activity following death. Hans Berger (1873–1941), a German psychiatrist, recorded the first human EEGs in 1924. In 1934, Fisher and Lowenback first demonstrated epileptiform spikes. In 1935, Gibbs, Davis, and Lennox described interictal epileptiform discharges and 3-Hz spike-wave patterns during clinical seizures. In 1936, Gibbs and Jasper described focal interictal spikes. The first clinical EEG laboratories were established in the United States in the 1930s and 40s. In 1947, the American EEG Society, later the American Clinical Neurophysiology Society, was founded.