

## Retrospective review of grommet procedures under general versus local anaesthesia among patients undergoing hyperbaric oxygen therapy

Laura Lamprell, Derelle Young, Venkat Vangaveti, John Orton and Anand Suruliraj

### Abstract

(Lamprell L, Young D, Vangaveti V, Orton J, Suruliraj A. Retrospective review of grommet procedures under general versus local anaesthesia among patients undergoing hyperbaric oxygen therapy. *Diving and Hyperbaric Medicine*. 2014 September;44(3):137-140.)

**Introduction:** One significant side effect of hyperbaric oxygen treatment (HBOT) is middle ear barotrauma (MEBT) may require tympanostomy tube (grommet) insertion by the Ear, Nose and Throat service. Where timely HBOT is needed, routine insertion of grommets under local anaesthesia (LA) is becoming common.

**Aims:** To investigate the differences between patients receiving HBOT and concurrent grommets under LA versus general anaesthesia (GA) at The Townsville Hospital (TTH).

**Methods:** A retrospective chart analysis of patients receiving HBOT between 2008 and 2012 and requiring grommets was undertaken.

**Results:** Thirty-one (5%) out of 685 patients treated with HBOT from 2008 to 2012 received grommets. Twelve cases received grommets under LA, and 19 under GA. Twenty out of the 31 cases had grommets following MEBT and the remainder prophylactically. Complications of grommet insertion comprised two cases with blocked grommets. There was a significant difference ( $P = 0.005$ ) in the time in days from ENT referral to HBOT between the LA group (median 1 day, range 0–13 days) and the GA group (median 8 days, range 0–98 days).

**Conclusion:** A greater number of hyperbaric patients received grommets under GA than LA at the TTH. Insertion of grommets under LA was safe, offering advantages to both the patient and the treating team in the setting of HBOT-associated otic barotrauma.

### Key words

Barotrauma, ear barotrauma, ENT, hyperbaric oxygen, hyperbaric oxygen therapy

### Introduction

The Townsville Hospital Hyperbaric Medicine Unit (TTH HMU) is home to a state-of-the-art hyperbaric chamber and is the only facility in Queensland outside of Brisbane, servicing North and West Queensland, the Great Barrier Reef and South Pacific regions. One commonly encountered side effect of hyperbaric oxygen treatment (HBOT) is middle ear barotrauma (MEBT), which may require myringotomy and tympanostomy tube insertion by the Ear, Nose and Throat (ENT) service.<sup>1</sup> The practice of cannula insertion into the tympanic membrane (TM) as a rapid temporary tympanostomy is not used at TTH. Large elective surgery waiting lists coupled with the need for timely treatment for new HBOT referrals means the routine insertion of grommets under local anaesthesia (LA) is becoming more commonplace.<sup>2,3</sup>

The aim of this study was to investigate the differences between patients receiving HBOT and concurrent grommets under either general anaesthesia (GA) or LA in North Queensland.

### Methods

Approval by the Townsville Hospital Human Research Ethics Committee was obtained (HREC/13/QTHS/58). A

retrospective chart review was undertaken. Patients included in the study were required to have been treated by TTH HMU during the five-year period 2008 to 2012 and have received grommets in association with their hyperbaric treatment. Cases were identified from the unit's patient database, and the following data were collected from the patient charts and the database: indication for HBOT; demographic data; date of grommet; time between ENT referral for grommets insertion and recommencement (or commencement) of HBOT; use of LA or GA; grommet type; indication for grommet insertion; grade of MEBT at the time of grommet insertion; number of HBOT sessions before and after grommet insertion; grommet-related complications. Details of the initial HBOT consult were also recorded, particularly where this led to early ENT referral for consideration for prophylactic grommet insertion (i.e., otoscopy findings; observations of the patient's ability to clear their ears or communicate physical distress). Where a single patient had more than one course of HBOT, they were counted as a new case if a new grommet was inserted for the subsequent HBOT course.

### STATISTICAL ANALYSIS

The IBM SPSS 22 (IBM, New York) software was employed to identify any significant differences between LA cases versus GA cases based on comparisons between the

**Table 1**

Summary of data comparing cases treated with grommets under local (LA) or general (GA) anaesthesia; \*  $P = 0.005$

	LA cases	GA cases
No. of patients	12	19
Male/female ratio	8/4	13/6
Age (median (range))	75 (43–88)	66 (43–78)
No. prophylactic grommets	5	6
No. post-barotrauma grommets	7	13
Days from referral to HBOT* (median (range))	1 (0–13)	8(0–98)
Post-grommet complications	0	2
No. pre-grommet HBOT (median (range))	2 (0–30)	0.5 (0–39)
No. post-grommet HBOT (median (range))	25 (2–40)	25 (0–58)

above-mentioned data. Data were checked for normality of distribution using the Kolmogorov-Smirnov test. The Mann-Whitney U Test was used to compare delays with re/commencing treatment between the two groups. The Wilcoxon signed ranks test was employed for comparing the number of treatments pre- and post-grommet insertion between the two groups. A  $P$ -value of  $< 0.05$  was considered statistically significant.

## Results

Thirty-one patients (5%) out of a total of 685 treated with HBOT from 2008 to 2012 received grommets to enable HBOT. Males outnumbered females in keeping with more males than females receiving HBOT at TTH HMU in a recent audit (147 males versus 70 females for 2010–2011).

There were some differences between those patients receiving grommets using GA compared to LA (Table 1). The median age of patients needing grommets was 75 (range 43–88) years for patients who received grommets under LA versus 66 (range 43–78) years for patients who received grommets under GA, although this was not statistically significant. Among these, two men underwent HBOT twice (counted as four male cases in total) with grommets inserted under GA for each. One of these patients had grommets inserted prophylactically prior to both HBOT courses, whereas the other had grommets prophylactically prior to their first HBOT course, but post MEBT for their second HBOT course.

Indications for HBOT included osteoradionecrosis (eight cases), problem wounds (six cases) and radiation proctitis (two cases). The less common indications were osteomyelitis, air embolism, tracheoesophageal fistula, Fournier's gangrene and necrotizing fasciitis.

GA grommet cases outnumbered LA cases (Table 1 and

**Figure 1**

Frequency of grommet procedures under GA versus LA between 2008 and 2012

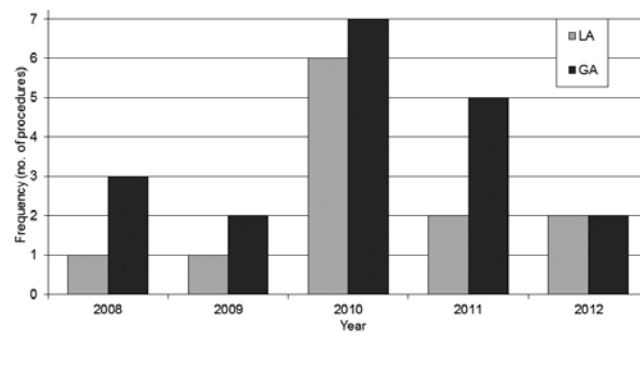


Figure 1). Types of LA used included liquid phenol applied to the tympanic membrane with an applicator, EMLA® cream (a eutectic mixture of lignocaine and prilocaine) and cophenylcaine spray. Three cases received Shah flanged grommets, 17 had Shepard short-stay grommets and in 11 cases the type of grommet was undocumented.

The median time from ENT referral for grommets to the date of re/commencement of HBOT was eight days (range 0–98) for cases receiving GA grommets compared to 1 day (range 0–13) for cases receiving grommets under LA ( $P = 0.005$ ).

Furthermore, 20 out of 31 cases had grommets post MEBT. Among the post-MEBT grommet cases, pre-treatment assessment of Eustachian tube function included documented history-taking (seven patients), success with a Valsalva manoeuvre (five patients), formal audiology (10 patients) and otoscopy (six patients). The difference in the number of post-MEBT cases treated with GA versus LA was not statistically significant.

The median number of HBOT prior to the insertion of grommets was one (range 0–39) indicating a generally short trial period of HBOT prior to the insertion in most cases. Overall, the median number of HBOT post insertion was 25 (range 0–58) treatments ( $P = 0.001$  for the difference between the number of HBOT sessions pre-grommet versus post-grommet). Issues with HBOT prior to grommet insertion were dominated by MEBT (20 out of 31 cases) and slowed descents (three out of 31 cases). Issues arising with HBOT after grommet insertion included blocked grommets in two cases, cardiac issues in two cases, poor compliance and incompatibility with comorbid acute sinusitis and cellulitis respectively.

## Discussion

Anecdotally, the ENT department in Townsville reports a few incidences of primary attempts at grommet procedures under LA that were later referred for a GA where the patient (often young) does not tolerate the procedure. Grommets will

also be inserted simultaneously under GA where the patient has another procedure planned near to the time of the ENT referral, such as a wound dressing change or washout and these cases were classified as a GA grommet for this study. The practice of cannula insertion as a rapid, temporary tympanostomy is not utilised at this facility, as the demand for tympanostomy in the setting of HBOT is satisfactorily met with conventional grommet insertion. The potential for prolonged HBOT is also locally viewed as optimally managed by grommet insertion.

The study found LA to be a safe and effective alternative to GA grommets with complications confined to two blocked grommets able to be cleared with conservative strategies. No grommets required removal and nil required re-insertion. However, the length of follow up, which was 6 months for patients treated in 2012, could be considered brief. As patient discomfort was not formally documented, an accurate measure of pain as a consequence of either LA or GA grommet insertion could not be studied.

#### MEBT AND HBOT

In a prospective study at TTH HMU of 106 patients using multivariate logistic regression, the local cumulative risk of MEBT was 35.8% in the first five HBOTs and 10.3% for needing tympanostomy tubes; 13.2% of the patients required tubes at any time during their HBOT course.<sup>4</sup> The predominant risk factors include Eustachian tube dysfunction, presence of an artificial airway, reduced level of consciousness, head and neck radionecrosis, nasal and paranasal disease, age over 55 years, female gender and previous middle ear surgery.<sup>5</sup> The practice of the TTH HMU is to assess patient risk of MEBT prior to treatment as described above, including history and otoscopic examination followed by a trial of otic equalization techniques. However, not all cases that demonstrated risk factors for MEBT on the initial assessment received grommets in the prophylactic setting. Reasons for this may include: the need for urgent HBOT to proceed; barriers to early access to ENT services; the ease of an initial trial of HBOT versus referring the patient for grommets. This may be influenced by the findings in the aforementioned TTH HMU study.<sup>4</sup> It was concluded that among this local population, it was not possible to accurately predict which patients needed tympanostomy tubes during their HBOT to substantiate a recommendation to place grommets prophylactically in any selected patients; a conclusion shared by others.<sup>4,5</sup>

MEBT is common in HBOT, with the potential for inner ear barotrauma in severe, but rare cases. The diagnosis is based on history and a confirmatory otoscopic examination with Edmond's classification of MEBT utilised at TTH HMU.<sup>6</sup> The only intervention to date is prevention of further MEBT by the cancellation of HBOT or by the insertion of grommets.<sup>7</sup>

The rate of insertion of grommets at TTH HMU reflects the degree of consideration being made for the risks of grommet insertion (cholesteatoma, otorrhoea, persistent TM perforation requiring myringoplasty, early extrusion, tympanosclerosis, retraction pockets, infection, ossicular damage) versus the benefit of not aborting further HBOTs.<sup>8-10</sup> It may also reflect the local tolerance by patients of MEBT in the setting of HBOT, or the efficacy of early education provided by the unit staff regarding MEBT preventative techniques during treatment.

#### LOCAL ANAESTHETICS AND GROMMETS

Local anaesthesia of the TM using iontophoresis was revived in the 1970s.<sup>11</sup> In 1988 the histologic changes in the TM in guinea pig models after application of different LA preparations was studied.<sup>12</sup> An observed loss of epithelium and mucosal cells with tetracaine recovered after three months, whereas hyperplastic connective tissue was seen with Bonain's solution (equal amounts of cocaine hydrochloride, menthol and phenol).<sup>12</sup> A more recent study failed to demonstrate any significant histologic difference in the healing TM among phenol, tetracaine or EMLA®.<sup>13</sup> A double-blind, controlled trial has compared injected anaesthesia versus EMLA concluding that EMLA, was equally effective with a lesser degree of invasiveness for the patient.<sup>14</sup> A 1991 study of the EMLA technique undertook pure tone audiometry before and after each procedure noting no evidence of ototoxicity with EMLA.<sup>15</sup>

More recently safe alternatives to EMLA have been sought, and phenol has been reported as a safe LA in 71 procedures.<sup>16</sup> Visual analogue measures of pain and overall satisfaction with the treatment experience in a double-blind, randomized trial of 41 patients found no statistically significant differences between tetracaine and EMLA.<sup>3</sup>

#### RESEARCH LIMITATIONS AND FUTURE DIRECTIONS

The main limitation of this study is the variability in the adequacy of documentation regarding grades of MEBT, types of LA being used, patient discomfort and the pre-HBOT assessment of Eustachian tube dysfunction. Future research should examine the rate of audiology complications between patients receiving grommets in association with their HBOT versus patients with MEBT who do not receive grommets. Also a review of cost differences between grommet procedures under LA and GA may lead to the increased usage of LA techniques.

#### CONCLUSION

Grommet insertion under LA was associated with shorter timeframes to HBOT. In this study, more patients received grommets under GA. Factors influencing a higher local rate of GA grommets may be the convenience of simultaneous grommet insertion with an upcoming GA procedure, a

surgeon's preference for GA insertion or the weight given to minimising patient discomfort during grommet insertion.

## References

- 1 Bessereau J, Tabah A, Genotelle N, Francais A, Coulange M, Annane D. Middle-ear barotrauma after hyperbaric oxygen therapy. *Undersea Hyperb Med.* 2010;37:203-8.
- 2 Hickey SA, Buckley JG, O'Connor AF. Ventilation tube insertion under local anesthesia. *Am J Otol.* 1991;12:142-3.
- 3 Nichani J, Camilleri AE, Broomfield S, Saeed S. Optimizing local anesthesia for grommet insertion: eutectic mixture of local anaesthetics versus Ametop: a randomized clinical trial. *Otol Neurotol.* 2008;29:658-60.
- 4 Commons KH, Blake DF, Brown LH. A prospective analysis of independent patient risk factors for middle ear barotuma in a multiplace hyperbaric chamber. *Diving Hyperb Med.* 2013;43:143-7.
- 5 Lehm JP, Bennett MH. Predictors of middle ear barotrauma associated with hyperbaric oxygen therapy. *SPUMS Journal.* 2003;33:127.
- 6 Edmonds C. Ear barotrauma. In: Edmonds C, Lowry C, Pennefather J, Walker R, editors. *Diving and subaquatic medicine*, 4th ed. London: Arnold; 2002. p. 73-91.
- 7 Fernau JL, Hirsch BE, Derkay C, Ramasastry S, Schaefer SE. Hyperbaric oxygen therapy: effect on middle ear and eustachian tube function. *Laryngoscope.* 1992;102:48-52.
- 8 Kay DJ, Nelson M, Rosenfeld RM. Meta-analysis of tympanostomy tube sequelae. *Otolaryngol Head Neck Surg.* 2001;124:374-80.
- 9 Stenstrom R, Pless IB, Bernard P. Hearing thresholds and tympanic membrane sequelae in children managed medically or surgically for otitis media with effusion. *Arch Pediatr Adolesc Med.* 2005;159:1151-6.
- 10 Vaile L, Williamson T, Waddell A, Taylor G. Interventions for ear discharge associated with grommets (ventilation tubes). *Cochrane Database Syst Rev.* 2006(2):CD001933. Epub 2006/04/21.
- 11 Echols DF, Norris CH, Tabb HG. Anesthesia of the ear by iontophoresis of lidocaine. *Arch Otolaryngol.* 1975;101:418-21.
- 12 Strutz J, Blessing R, Zollner C. Effects of topical anesthetics on tympanic membrane structure. *Arch Otorhinolaryngol.* 1988;244:381-6.
- 13 Gnuechel MM, Schenk LL, Postma GN. Late effects of topical anesthetics on the healing of guinea pig tympanic membranes after myringotomy. *Arch Otolaryngol Head Neck Surg.* 2000;126:733-5.
- 14 Roberts C, Carlin WV. A comparison of topical EMLA cream and prilocaine injection for anaesthesia of the tympanic membrane in adults. *Acta Otolaryngol.* 1989;108:431-3.
- 15 Bingham B, Hawke M, Halik J. The safety and efficacy of Emla cream topical anesthesia for myringotomy and ventilation tube insertion. *J Otolaryngol.* 1991;20:193-5.
- 16 Robertson A, Whitwell R, Osborne J. Is phenol a safe local anaesthetic for grommet insertion? *J Laryngol Otol.* 2006;120:20-3.

**Conflict of interest:** nil

**Submitted:** 02 March 2014

**Accepted:** 16 July 2014

Laura Lamprell<sup>1</sup>, Derelle Young<sup>2</sup>, Venkat Vangaveti<sup>3</sup>, John Orton<sup>2</sup>, Anand Suruliraj<sup>1</sup>

<sup>1</sup> Department of Otolaryngology, Head and Neck Surgery, The Townsville Hospital, Queensland

<sup>2</sup> Hyperbaric Medicine Unit, The Townsville Hospital, Queensland

<sup>3</sup> School of Medicine and Dentistry, James Cook University, Townsville, Queensland

### Address for correspondence:

Laura Lamprell

Department of Otolaryngology Head and Neck Surgery

The Townsville Hospital

100 Angus Smith Drive

Douglas, Queensland 4814, Australia

Phone: +61-(0)7-4433-1111

Email: <laura.lamprell@gmail.com>

---

The database of randomised controlled trials in hyperbaric medicine maintained by Michael Bennett and his colleagues at the Prince of Wales Hospital Diving and Hyperbaric Medicine Unit, Sydney is at:  
<<http://hboevidence.unsw.wikispaces.net/>>

Assistance from interested physicians in preparing critical appraisals is welcomed, indeed needed, as there is a considerable backlog. Guidance on completing a CAT is provided. Contact Associate Professor Michael Bennett: <[M.Bennett@unsw.edu.au](mailto:M.Bennett@unsw.edu.au)>