

Weber's syndrome and sixth nerve palsy secondary to decompression illness: A case report.

W. PADILLA¹, H.B. NEWTON², S. BARBOSA³

¹Hyperbaric Medicine Unit, Subaquatic Safety Services, Cozumel, Mexico, ²Division of Neuro-Oncology and Dardinger Neuro-Oncology Center, Ohio State University Medical Center & James Cancer Hospital and Solove Research Institute, Columbus, Ohio, USA, ³Division of Neuro-Ophthalmology, Institute of Neurology and Neurosurgery, Mexico City, Mexico

Padilla W, Newton HB, Barbosa S. Weber's syndrome and sixth nerve palsy secondary to decompression illness: A case report. *Undersea Hyperb Med* 2005; 32(2): 95-102. We describe the first case of Weber's Syndrome to present as a manifestation of decompression illness in a recreational scuba diver. Weber's Syndrome is characterized by the presence of an oculomotor nerve palsy and contralateral hemiparesis. The patient was a 55 year-old male with a past medical history of a pulmonary cyst, in whom symptoms developed after a multilevel drift dive to a depth of 89 feet for 53 minutes, exceeding no-decompression limits. Symptom onset was within 30 minutes of surfacing and included the Weber's Syndrome, a sixth nerve palsy, dizziness, nausea, sensory loss, and ataxia. The patient received four U. S. Navy Treatment Tables with complete resolution of all neurological signs and symptoms. The mechanism of injury remains unclear, but may involve aspects of both air gas embolism and decompression sickness. Individuals with pre-existing pulmonary cysts may be at increased risk for dive-related complications.

INTRODUCTION

Although uncommon, severe injury and death can occur during recreational scuba diving (1-3). The DiversAlertNetwork reports that between 900 and 1,000 divers each year are treated for dive-related complications, including approximately 90 fatalities. Many of these complications involve dysfunction of the nervous system. In recreational divers, neurological injuries, mostly involving the spinal cord or cerebrum, are common and may be persistent in some patients (4-6). Spinal cord involvement usually arises from decompression sickness (DCS), and nitrogen bubbles may obstruct the spinal venous plexus (5). Cerebral involvement is more common with pulmonary barotrauma and arterial gas embolism (AGE) (4). In many patients, the exact pathogenesis of neurological injury cannot be determined from the dive profile and clinical picture, and so the event is classified

under the general term decompression illness (DCI) (7).

In this case report we describe an unusual patient with neurological DCI, in whom the focus of injury was to the midbrain, with neuro-ophthalmological findings including a Weber's Syndrome and sixth nerve palsy. To the best of our knowledge, this is the first report of decompression illness manifesting as Weber's Syndrome.

CASE REPORT

The patient was a 55 year-old Caucasian male, certified as an Open Water Diver, with 75 logged dives. Two years prior to his diving accident, a right lower lobe lung mass (2.0 x 1.9 cm) was discovered during a routine medical examination. A diagnostic fiberoptic bronchoscopy and transbronchial biopsy was unsuccessful, and a CT-guided

needle biopsy attempt resulted in a moderate sized pneumothorax, with hemorrhage and air inside the lesion. A second CT-guided biopsy obtained tissue, but the interpretation was equivocal (mild chronic inflammation and fibrosis, anthracotic pigment, no evidence of neoplastic cells). Follow-up chest CT one year prior to the dive accident revealed the mass had enlarged to 2.3 cm. After the diving accident, in the late fall of 2003, the patient had the lesion surgically removed. The pathology revealed a cystic lesion with inflammation and regions of cartilaginous development, most consistent with a bronchogenic cyst with numerous adhesions. Other past medical history included a 15 pack-year history of smoking and severe pneumonia as a young child. There was no history of hypertension or diabetes mellitus.

The diving accident occurred after the patient had performed 20 uncomplicated compressed air dives since his lung lesion biopsies and pneumothorax. Two days prior to the event, he began diving off the coast of Cozumel, Mexico and dove to 118 feet sea water (fsw) (35 meters sea water, msw) on compressed air for 35 minutes without complication. He did not dive the next day, but reports having had five alcoholic beverages that night. On the day of the injury, he performed a multilevel drift dive on compressed air in mild current, with a maximum depth of approximately 89 fsw (27 msw) and a bottom time of 53 minutes. The patient did not report any buoyancy problems and ascents were performed appropriately at 15 to 30 feet per minute. Towards the end of the dive, the dive computer (manufactured by Genesis) warning light indicated that he had exceeded the allowable bottom time for his depth and that a decompression stop was necessary. Accordingly, he waited for 13 minutes at 20 fsw (6 msw) before ascending to the surface. The patient experienced

symptom onset thirty minutes after surfacing with evolution to maximal intensity in five to ten minutes. Symptoms included vertical diplopia and difficulty focusing his vision, dizziness, nausea, gait instability, and right sided heaviness and numbness. Within ten minutes of onset, the patient was transported by car to our medical facility where he arrived 30 minutes later. On initial evaluation, the neurological examination revealed an extensive left partial ophthalmoplegia (with palsy of cranial nerves III and VI), convergent left strabismus, vertical binocular diplopia, mild left ptosis, right horizontal nystagmus, left mydriasis, poorly reactive left pupil, right sided hemiparesis and sensory loss, hemiparetic and ataxic gait, and a tendency to list to the right. No right-sided tremor or athetoid movements were noted. On the general examination there was no evidence of rash or joint abnormalities. Admission blood work included a hematocrit of 50%, CPK of 211.6 U/l, CK MB of 22.7 U/l, leukocyte count of 14.0 K/ μ l, cholesterol of 230 mg/dl, and glucose of 184 mg/dl. Cardiac monitoring performed before and during hyperbaric treatment demonstrated a normal sinus rhythm without evidence for ischemic changes. CT of the head was remarkable only for some mild cortical and sub-cortical atrophy, without evidence of acute or focal lesions within the brainstem or supratentorial white matter (Figure 1). A CT of the chest revealed the previously noted right lung lesion, without evidence for hemorrhage or pneumothorax (Figure 2).

He still complained of diplopia, right-sided weakness, and visual disturbance. He continued receiving treatments inside the chamber once a day for a total of four treatment sessions (two USNTT6 and two USNTT5). After the completion of all four chamber sessions, there was complete resolution of residual symptoms and neurological deficits.

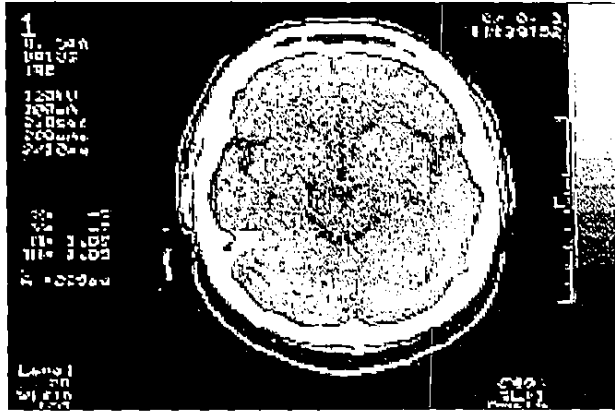


Fig.1. Cranial CT at the level of the midbrain, demonstrating normal anatomy without evidence of hemorrhage or infarction within the brainstem.




Fig 2. Chest CT demonstrating the pulmonary cyst in the right posterior lung field.

DISCUSSION

This patient is the first case of Weber's Syndrome as a manifestation of decompression illness. Weber's Syndrome is more commonly diagnosed after a brainstem stroke or ischemic episode, or secondary to compression from a rostral brainstem mass lesion such as a tumor, hemorrhage, or abscess (9,10). The classical findings in Weber's Syndrome are an acquired ophthalmoplegia due to partial or complete oculomotor nerve palsy (i.e., cranial nerve III), in combination

with a contralateral hemiparesis from corticospinal tract involvement. This is consistent with our patient, who displayed left oculomotor nerve palsy and right hemiparesis at the time of presentation. The neurological examination also revealed other findings indicative of adjacent brainstem damage, including a sixth nerve palsy, an ataxic gait, and hemisensory loss. The neuroanatomical localization of this constellation of findings is to the rostral, ventromedial midbrain on the left side, at the level of the cerebral peduncles, with extension caudally into the upper pons (11,12). Damaged structures include the fascicles of the oculomotor and abducens nerves, fibers of the corticospinal tract as they descend through the crus cerebri, superior cerebellar peduncle, and medial lemniscus (see Figures 3 and 4) (12,13). The region of damage is somewhat patchy in that it does not appear to involve the red nucleus, midline oculomotor nuclear complex, or other structures of the upper pons (e.g., fascicles of the facial nerve, paramedian pontine reticular formation). In addition, the affected neuroanatomical region does not follow a simple vascular distribution, since it involves areas supplied by both the paramedian and short circumferential branches off the basilar artery. The CT scan at the time of admission was normal, as shown in Figure 1, and did not demonstrate any brainstem pathology. However, CT scans are insensitive to brain injury in the posterior fossa and brainstem. A magnetic resonance imaging scan (MRI), if available, might have demonstrated the region of damage within the midbrain and pons, but can still appear normal in some cases of neurological DCI (5,7,14,15).

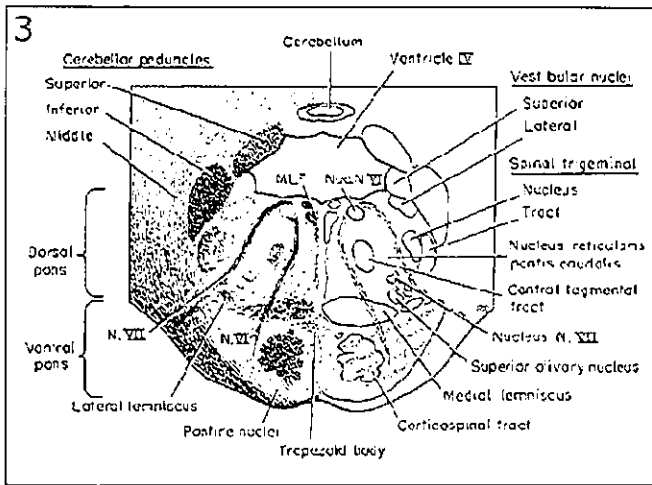


Fig. 3. Line diagram demonstrating the neuroanatomy of the rostral pons. Structures damaged during the episode of DCI are shaded on the right side of the pons and include the corticospinal tract and fascicles of the abducens nerve. Adapted from Carpenter's Human Neuroanatomy, 9th Edition, with permission from Lippincott/Williams & Wilkins Co.

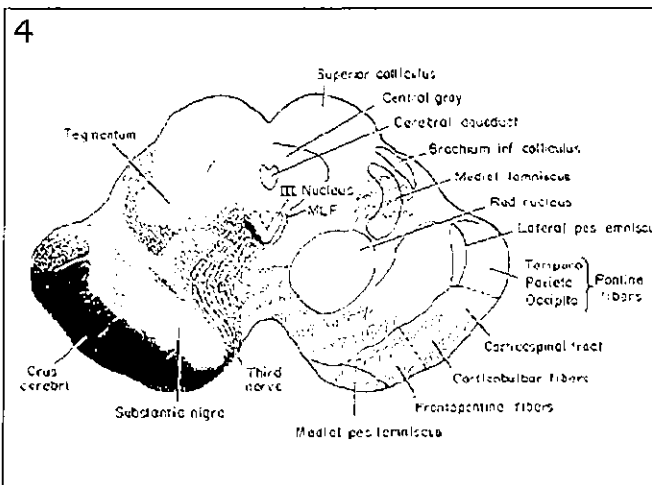


Fig. 4. Line diagram demonstrating the neuroanatomy of the rostral midbrain. Structures damaged during the episode of DCI are shaded on the right side of the midbrain and include the corticospinal tract, oculomotor nerve fascicles, medial lemniscus, and superior cerebellar peduncle. Adapted from Carpenter's Human Neuroanatomy, 9th Edition, with permission from Lippincott/Williams & Wilkins Co.

Although the temporal profile and clinical presentation of the patient's symptoms are most suggestive of DCI, the differential diagnosis would also have to include a transient ischemic attack (TIA) or minor stroke affecting the upper brainstem. It is possible that a TIA or minor stroke, either induced by the rigors of the dive or unrelated to the dive, could have had a similar onset after the dive. However, the spectrum of symptoms and findings noted would be unusual for a TIA, since the patient had a partial ophthalmoplegia and palsy of cranial nerve III (16). Visual deficits in patients with minor ischemia to the posterior circulation are usually homonymous visual field defects. In addition, the symptoms did not resolve for four days, which is beyond the duration limits for a TIA (i.e., ≤ 24 hours), and the patient responded exquisitely to hyperbaric oxygen. For patients in whom the clinical presentation is more equivocal, a work-up for brain ischemia may be warranted. A clinical algorithm for evaluation and treatment of TIA and minor stroke is outlined by Brown and colleagues (16).

The exact etiology of the patient's neurological injury remains unclear. The dive profile, temporal symptom onset, and clinical presentation have features of both AGE and DCS. The dive profile exceeded the limits of typical recreational scuba diving (i.e., for Dive Table analysis, the dive was equivalent to 90 fsw [27 msw] for 60 minutes) and, as suggested by the patient's dive computer, required a 13 minute decompression stop at 20 fsw (6 msw). For this dive profile, the U. S. Navy Standard Air Decompression Table is more conservative, with a decompression stop of 25 minutes at 10 fsw (3 msw) (17). With a dive profile that exceeded no-decompression dive limits and an abbreviated decompression stop, this

patient was clearly at risk for DCS. The ascent to the surface was well controlled and uneventful, and should not have increased the likelihood of AGE. However, the patient did have the right-sided pulmonary cyst, which is a predisposing factor for AGE (18-20). It is possible that cystic micro-rupture during ascent could have resulted in AGE. A more extensive cystic rupture was not consistent with the CT scan of the chest taken after admission. The patient had symptom onset 30 minutes after surfacing, which is long for AGE, but could occur in either syndrome. The symptom complex developed rapidly and affected only the brainstem, without CT or clinical evidence of cortical, subcortical, or spinal cord involvement. This is most consistent with a vascular etiology and an AGE mechanism, with bubble obstruction of the paramedian and short circumferential branches of the basilar artery (7). Although less likely, DCS could also account for this process, since it can affect the cerebral vasculature and parenchymal neural tissues through nitrogen bubble formation (5).

In addition to aggressive rehydration, the patient was treated on USNTT6, including extensions at 60 fsw (18 msw) and 30 fsw (9 msw). This is a standard approach for any recreational diver with neurological DCI (5,7,8,18,21). Hyperbaric oxygen administered with a USNTT6 often improves neurological symptoms in severely injured patients by reducing bubble size and increasing perfusion to ischemic tissues (5,7,21). This is consistent with our patient, who noted improvement of the oculomotor and abducens nerve palsies, with extended range of motion of the left eye, less severe right-sided parasthesias and sensory loss, and reduced nausea after the first chamber session. After one more USNTT6 and two USNTT5 chamber sessions over the next three days, the patient had complete resolution

of all neurological signs and symptoms. The excellent result in this patient suggests that the brainstem damage causing the Weber's Syndrome, sixth nerve palsy, and associated findings were due to ischemia of neural tissues, with minimal if any infarction.

Another factor contributing to the excellent outcome in this patient was the prompt recognition of the problem and initiation of recompression therapy. It is well known that significant delays in recompression therapy worsen prognosis in DCI and increase the likelihood of permanent neurological sequelae (22). Rapid initiation of hyperbaric oxygen therapy will reduce bubble size, improve perfusion, and re-oxygenate ischemic tissues before the more chronic, inflammatory reactions to the presence of bubbles develop (c.g., platelet activation and clumping, cytokine release, complement activation) (5,7).

Recent data suggest that our patient could have been at risk for permanent neurological sequelae because of the high hematocrit of 50% (23). In a review of 58 recreational divers with neurological DCI and 16 control divers, an elevated hematocrit was a negative prognostic factor. Patients with a hematocrit at presentation of 48% or higher were significantly ($p=0.01$) more likely to have neurological sequelae at one month after the diving accident. Severe hemoconcentration is indicative of hypovolemia and increased blood viscosity, and it reduces the perfusion and off-gassing of involved tissues, which can worsen neurological injury. Rapid and aggressive rehydration may have helped with symptom resolution in our patient.

Although Weber's Syndrome and sixth nerve palsy are uncommon manifestations of DCI, this case suggests that even patients with severe injury to the brainstem may respond well to prompt recompression. In addition, individuals with

pre-existing pulmonary cysts are at increased risk for dive-related complications, including AGE or paradoxical venous gas embolism due to bronchopulmonary or arteriovenous shunting (18-20). It remains unclear whether individuals with asymptomatic pulmonary cysts, without a history of thoracic instrumentation or pneumothorax, are also at increased risk for dive-related complications. In advising them, we would recommend caution.

ACKNOWLEDGEMENTS

The authors thank Ryan Smith for research assistance and William Cheshire, M.D. for critical review of the manuscript. Dr. Padilla was supported by the SSS Recompression Chamber Network, especially Mauricio Moreno. Dr. Newton was supported in part by National Cancer Institute CA 16058 and the Esther Dardinger Neuro-Oncology Center Endowment Fund.

REFERENCES

1. Divers Alert Network. Report on Decompression Illness and Diving Fatalities: DAN's annual review of recreational diving injuries and fatalities based on 1998 data. Durham, NC: Divers Alert Network, 2000.
2. Melamed Y, Shupak A, Bitterman H. Medical problems associated with underwater diving. *New Engl J Med* 1992; 326:30-35.
3. Clenney TL, Lassen LF. Recreational scuba diving injuries. *Am Fam Phys* 1996;53: 1761-1766.
4. Greer HD, Massey EW. Neurologic injury from undersea diving. *Neurol Clin* 1992;10: 1031-1045.
5. Newton HB. Neurologic complications of scuba diving. *Am Fam Phys* 2001;63: 2211-2218.
6. Todnem K, Nyland H, Skeidsvoll H, et al. Neurological long term consequences of deep diving. *Br J Indian Med* 1991;48: 258-266.
7. Barratt DM, Harch PG, Van Meter K. Decompression illness in divers: A review of the literature. *The Neurologist* 2002;8: 186-202.
8. U. S. Navy. Recompression treatments when chamber available. U. S. Navy Diving Manual volume 1 (Air Diving). Revision 1, ch. 8, rev. 15. February 1993; Naval Sea Systems Command Publication NAVSEA 0994-LP-001-9110.
9. Miller NR. Walsh and Hoyt's clinical neuro-ophthalmology. Vol 3. Baltimore: Williams & Wilkins, 1985:652-682.
10. Yamana T, Murakami N, Itoh E, Takahashi A. Weber's syndrome of ischemic vascular origin – a clinical and neuroradiologic study. *No To Shinkei* 1993;45: 349-354.

11. Brazis PW. Localization of lesions of the oculomotor nerve: Recent concepts. *Mayo Clin Proc* 1991;66: 1029-1035.
12. Bennett JL, Pelak VS. Neuro-ophthalmology. Palsies of the third, fourth, and sixth cranial nerves. *Ophthalmol Clin N. Am.* 2001;14: 169-185.
13. Parent A. Carpenter's human neuroanatomy. Ninth Edition. Baltimore: Williams & Wilkins, 1996:469-582.
14. Levin HS, Goldstein FC, Norcross K, Amparo EG, Guinto FC, Mader JT. Neurobehavioral and magnetic resonance imaging findings in two cases of decompression sickness. *Aviat Space Environ Med* 1989;60: 1204-1210.
15. Hutzelmann A, Tetzlaff K, Reuter M, Müller-Hülsbeck S, Heller M. Does diving damage the brain? MR control study of divers' central nervous system. *Acta Radiologica* 2000;41: 18-21.
16. Brown RD, Evans BA, Wiebers DO, Petty GW, Meissner I, Dale AJD. Transient ischemic attack and minor ischemic stroke: An algorithm for evaluation and treatment. *Mayo Clin Proc* 1994;69: 1027-1039.
17. U. S. Department of the Navy. 1999. U. S. Navy Diving Manual. Revision 4. NAVSEA 0901-LP-708-8000. Naval Sea Systems Command, 2531 Jefferson Davis Hwy. Arlington, VA 22242-5160.
18. Walker R. Pulmonary Barotrauma. In: Edmonds C, Lowry C, Pennefather J, Walker R, eds. Diving and subaquatic medicine. Fourth edition. London: Arnold, 2002:55-71.
19. Aksenov V, Parsa N, Nicholson W, Saba GW. Arterial gas embolism in tender during treatment of decompression sickness: Case report (abstract). Proc Undersea Hyperbar Med Soc Meeting 2002;82.
20. Bernard N, Grammond P, Lecours R. Double cerebral air gas embolism (CAGE): Lessons from commercial flight and hyperbaric oxygen therapy complications (abstract). Proc Undersea Hyperbar Med Soc Meeting 2003;3.
21. Moon RE. Treatment of diving emergencies. *Critical Care Clin* 1999;15: 429-456.
22. Dick APK, Massey EW. Neurologic presentation of decompression sickness and air embolism in sport divers. *Neurol* 1985;35: 667-671.
23. Boussuges A, Blanc P, Molenat F, Bergmann E, Sainty JM. Haemoconcentration in neurological decompression illness. *Int J Sports Med* 1996;17: 351-355.

