

High incidence of venous and arterial gas emboli at rest after trimix diving without protocol violations

Marko Ljubkovic,¹ Jasna Marinovic,¹ Ante Obad,¹ Toni Breskovic,¹ Svein E. Gaustad,² and Zeljko Dujic¹

¹Department of Physiology, University of Split School of Medicine, Split, Croatia; and ²Department of Circulation and Medical Imaging, Norwegian University of Science and Technology, Trondheim, Norway

Submitted 9 December 2009; accepted in final form 1 September 2010

Ljubkovic M, Marinovic J, Obad A, Breskovic T, Gaustad SE, Dujic Z. High incidence of venous and arterial gas emboli at rest after trimix diving without protocol violations. *J Appl Physiol* 109: 1670–1674, 2010. First published September 2, 2010; doi:10.1152/jappphysiol.01369.2009.—SCUBA diving is associated with generation of gas emboli due to gas release from the supersaturated tissues during decompression. Gas emboli arise mostly on the venous side of circulation, and they are usually eliminated as they pass through the lung vessels. Arterialization of venous gas emboli (VGE) is seldom reported, and it is potentially related to neurological damage and development of decompression sickness. The goal of the present study was to evaluate the generation of VGE in a group of divers using a mixture of compressed oxygen, helium, and nitrogen (trimix) and to probe for their potential appearance in arterial circulation. Seven experienced male divers performed three dives in consecutive days according to trimix diving and decompression protocols generated by V-planner, a software program based on the Varying Permeability Model. The occurrence of VGE was monitored ultrasonographically for up to 90 min after surfacing, and the images were graded on a scale from 0 to 5. The performed diving activities resulted in a substantial amount of VGE detected in the right cardiac chambers and their frequent passage to the arterial side, in 9 of 21 total dives (42%) and in 5 of 7 divers (71%). Concomitant measurement of mean pulmonary artery pressure revealed a nearly twofold augmentation, from 13.6 ± 2.8 , 19.2 ± 9.2 , and 14.7 ± 3.3 mmHg assessed before the first, second, and the third dive, respectively, to 26.1 ± 5.4 , 27.5 ± 7.3 , and 27.4 ± 5.9 mmHg detected after surfacing. No acute decompression-related disorders were identified. The observed high gas bubble loads and repeated microemboli in systemic circulation raise questions about the possibility of long-term adverse effects and warrant further investigation.

technical diving; bubble detection; left ventricular gas emboli; pulmonary artery pressure

SCUBA (self-contained underwater breathing apparatus) diving with compressed air is a frequent professional and recreational activity performed regularly by millions of people. Recent popularization of technical diving resulted in an increased number of individuals conducting deep water excursions using a mixture of oxygen, helium, and nitrogen (trimix). The main purpose for using such breathing gas mixtures is to reduce the percentage of nitrogen in the mixture by adding helium, thus diminishing the negative effects that arise when breathing air under high pressures (nitrogen narcotic effects and increased resistance to breathing). However, decompression procedures for trimix diving are primarily based on theoretical models and have not been completely validated. Furthermore, trimix dives are usually significantly deeper than the air dives and thus

associated with more pronounced and/or different physiological challenges, such as higher ambient pressures, increased average oxygen partial pressures, and formation of venous gas emboli (VGE) of a potentially different nature.

VGE are frequently found in the venous circulation after diving activities and are usually asymptomatic (“silent”). However, the excessive formation of bubbles in various tissues has generally been acknowledged as the main cause of decompression sickness (DCS). After entering the circulation, VGE are carried by the bloodstream to the pulmonary circulation, where they can have mechanical, humoral, and biochemical effects. Occasionally, gas emboli may cross over to the arterial, systemic side of circulation. This VGE crossover has been speculated to increase the risk of decompression injury. Similarly to diving, gas bubbles on the arterial side were also detected in some cases of DCS developed during high-altitude exposure (36). Furthermore, in some animal models, systemic arterial gas bubbles were found in parallel to large amounts of venous bubbles and a neurological form of DCS (38). Moreover, the appearance of arterialized VGE has been used as abort criterion in some decompression experiments (37).

The crossover of VGE to the systemic circulation has usually been linked to patent foramen ovale (PFO) (21). Indeed, PFO is considered as an important risk factor for development of DCS, especially its neurological form (31, 47). Other precipitating factors for development of VGE arterialization and DCS are situations resulting in increased venous return, such as coughing or performing Valsalva maneuver (20), or increased pulmonary artery pressure (PAP) (46). In the absence of PFO, arterialization of VGE was seldom observed (1, 33) and it was ascribed to intrapulmonary shunts. A high percentage of arterializations was reported only during deep chamber saturation excursions from 300 m of seawater (msw) to 250 msw (6). Arterialized emboli were associated with mild knee pains that promptly disappeared following compression to 270 msw, and only one diver reported postdive severe depression with subsequent neurological exam showing changes indicative of a minor hemispherical lesion. Although these divers were not tested for the presence of PFO or intrapulmonary shunts, it is also possible that diving at greater depths or using breathing mixtures other than air alters the VGE production rate or the incidence of arterialization.

Therefore, the main purpose of the present study was to investigate the dynamics of VGE production and potential occurrence of arterializations during a series of trimix dives.

METHODS

Study population. The study enrolled seven divers aged 40.2 ± 9 yr of age (range 31–48), with the average body mass index of 25.15 ± 2.16 kg/m² and height of 1.8 ± 0.1 m. Spirometry indicated mean

Address for reprint requests and other correspondence: Z. Dujic, Dept. of Physiology, Univ. of Split School of Medicine, Soltanska 2, 21000 Split, Croatia (e-mail: zeljko.dujic@mefst.hr).

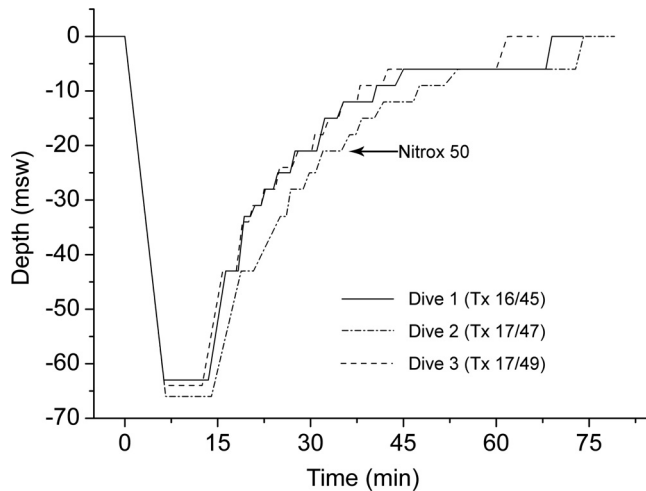


Fig. 1. Dive profiles performed in 3 consecutive days. Shown are the representative diving profiles performed by 1 of the test subjects (*subject 2*). Msw, meters of seawater; Tx, breathing mixture of oxygen, helium, and nitrogen (trimix) where the first number indicates the volume percentage of oxygen and the second the volume percentage of helium; nitrox 50, breathing mixture containing 50% oxygen and 50% nitrogen. Arrow indicates the depth (21 m) where the divers changed their breathing gas to nitrox 50.

forced vital capacity at $119.0 \pm 18.1\%$ and forced expiratory flow in the first second at $109.2 \pm 11.3\%$ of predicted values. All participants were experienced divers and nonsmokers. At the time of the study, the divers showed no signs of acute or chronic illness. All experimental procedures were conducted in accordance with the Declaration of Helsinki and were approved by the Ethics Committee of the University of Split School of Medicine. Each method and potential risks were explained to the participants in detail, and they gave their written informed consent before the onset of the experiments.

Location of the study and dive protocols. The participating divers were active members of Croatian and Slovenian Search and Rescue units, and the measurements were taken during their scheduled exercise in technical diving with trimix. Divers performed three dives in consecutive days, and the representative dive profiles are displayed in Fig. 1. Divers used a breathing mixture of oxygen, helium, and nitrogen (trimix) for descent and ascent up to 21 msw, at which point they switched to nitrox 50 (50% O₂ and 50% N₂) that was used for decompression until resurfacing. Decompression procedures were determined using V-planner software according to Varying Permeability 1 Model (VPM-B) (48). The performed dive profiles were recorded on dive computers (Galileo, Uwatec, Johnson Outdoors, Racine, WI) and downloaded to a PC for the purpose of confirming the diver's adherence to the planned protocols and obtaining other dive parameters such as water temperature and depth. Divers refrained from exercise at least 24 h before diving, during decompression stops, or after the dives since these conditions were reported to affect the production of VGE (11, 12, 14). They all wore dry suits and used regularly serviced open-circuit breathing equipment. Ambient air temperature varied between 25 and 28°C and the bottom water temperature was 14–15°C.

Detection of venous gas emboli. The presence of VGE in circulation was determined and evaluated using a well-established approach in our laboratory (11, 15, 34). The subjects were placed in the left supine position and an echocardiographic investigation with a phase array probe (1.5–3.3 MHz) using Vivid i ultrasonic scanner (GE, Milwaukee, WI) was conducted by an experienced cardiologist (A. Obad). Gas emboli were observed as high-intensity echoes in the pulmonary artery and cardiac chambers. Monitoring was performed at 45, 60, and 90 min after surfacing, at rest and after performing two coughs. Obtained images were evaluated by two independent re-

searchers and graded on a scale from 0 to 5 according to the method described by Eftedal and Brubakk (16). In all divers, an additional echocardiograph investigation with color Doppler imaging was performed to search for potential intracardiac septal defects (such as PFO).

Assessment of pulmonary artery pressure. Transthoracic echocardiography (TTE) was used to estimate mean PAP (mPAP) before and within 120 min after a dive. The transducer was pointed to the outflow tract of the right heart, with pulse wave Doppler sample volume positioned at the level of pulmonary valve annulus. The pulmonary artery flow velocity was averaged over three consecutive cardiac cycles during breath-hold. AccT (time interval in ms between onset and peak of systolic pulmonary artery flow) and RVET (time interval in ms between onset and termination of systolic pulmonary artery flow) were measured. The AccT/RVET ratio for each cardiac cycle was used to calculate mean PAP, where $\log_{10}(\text{mean PAP}) = -2.8(\text{AccT/RVET}) + 2.4$ (25).

Statistical analysis. Bubble grade data are presented as median (range). Mean PAP data are presented as means \pm SD, and the comparisons of the predive and postdive values for each dive were performed using Student's *t*-test for paired samples. The level of statistical significance was set at $P < 0.05$.

RESULTS

All seven divers successfully completed the diving protocols, and no signs or symptoms of DCS were observed or reported. Figure 2 displays a typical four-chamber echocardiographic image recorded in supine resting position 45 min after surfacing. Gas emboli were observed within the right cardiac chambers but also on the left side of the heart. Immediately after performing two forced coughs, the amount of VGE recorded in the right cardiac cavities was transiently increased (not shown). Bubble grade values assessed in the right heart at different time points after each dive are shown in Table 1.

Arterialization of VGE was found in 9 of 21 dives and was detected at least once in 5 of 7 subjects (Table 2). VGE were observed in the left ventricle most commonly during the first and second measurements taken at 45 and 60 min postdive [left ventricular bubble grade values were 2 (2–3)], and in most cases the arterialized VGE disappeared by the time of the last measurement (90 min postdive). All cases of arterialization

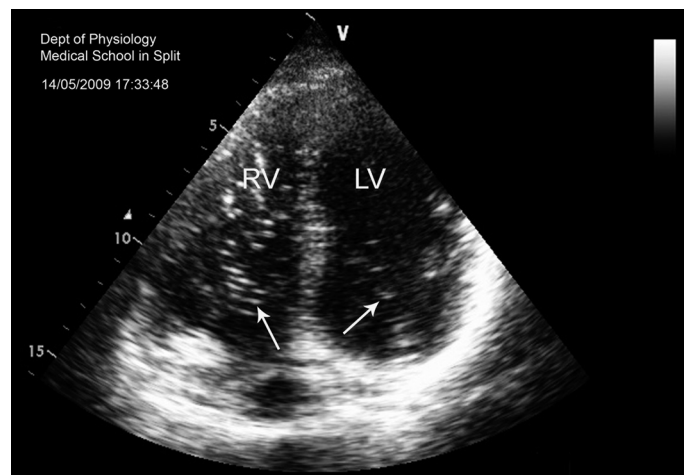


Fig. 2. The presence of gas emboli in the heart after diving. Displayed is an echocardiographic apical 4-chamber view of the heart recorded at 45 min after *dive 1* in 1 of the test subjects. Gas emboli are seen both in the right and left cardiac cavities (arrows). RV, right ventricle; LV left ventricle.

Table 1. *Echographic evaluation of gas emboli in the right heart*

Dive No.	Bubble Grade		
	45'	60'	90'
1	4 (3–4)	3 (3–4)	3 (3–4)
2	3 (1–4)	3 (1–4)	3 (0–4)
3	3 (0–4)	3 (0–4)	2 (0–3)

Values are presented as median (range). Shown are bubble grade values assessed in the right heart at 45, 60, and 90 min after every dive.

were associated with high bubble amounts in the right ventricle (bubble grade 4 in the right heart at each instance of arterialization). PFO was detected in only one diver (*subject 4*).

Mean pulmonary artery pressure values rose significantly from 13.6 ± 2.8 , 19.2 ± 9.2 , and 14.7 ± 3.3 mmHg assessed before the first, second, and the third dive, respectively, to 26.1 ± 5.4 , 27.5 ± 7.3 , and 27.4 ± 5.9 mmHg detected after surfacing.

DISCUSSION

This study demonstrates that after open-sea trimix diving, a right-to-left crossover of the venous gas emboli occurred in 5 of 7 divers and in 9 of 21 dives. A functional PFO was detected in only one diver. The arterializations were present up to 90 min after surfacing and were associated with high bubble grades in right cardiac chambers and increased pressure in the pulmonary artery. Despite the crossover of VGE, no signs or symptoms of DCS were found.

Traditional air decompression tables have been evaluated using the occurrence of DCS as an end point. In the present study, we used a gas bubble grading system as an indicator of decompression and dive stress. The production of VGE can be monitored ultrasonically, using both the precordial Doppler and echocardiographic scanning. Although it has been hypothesized that a large number of pulmonary artery bubbles increases the risk of DCS (18, 41), differences in scaling systems used for grading the bubble amounts complicate the interpretation of the data (17). Diving profiles and decompression protocols performed by this group of divers were based on a trimix bubble model that keeps the predicted bubble volume below some calculated critical level. Although the diving excursions in this study were supposedly conservative according to the decompression algorithm used, a high incidence of high-grade VGE was detected. This may be due to the fact that the critical level is set too high and thus the decompression may not be sufficient.

Despite the high VGE grades observed, no adverse clinical outcomes during the course of the study were detected. However, we reported that even “silent” venous emboli are associated with subtle cardiovascular abnormalities such as reduced left ventricle contractility and brachial artery endothelial dysfunction, which can last more than 24 h after diving (4, 13, 34). Whether these acute asymptomatic changes may eventually increase the risk for development of chronic cardiovascular pathology or other long-term effects, such as osteonecrosis (23), is presently unknown. Considering the paucity of data on VGE formation and effects in trimix diving, and due to the considerable amount of gas bubbles detected in this study, it might prove important to ultrasonically (re)evaluate the trimix

decompression algorithms based on bubble growth and formation to obtain more information about gas separation and bubble dynamics.

In the present study, gas emboli were detected on the arterial side of the circulation in a significant portion of dives. The causes leading to this effect and the anatomic pathway for VGE passage are not completely clear. A functional PFO, which was reported to increase the risk for development of DCS (31, 47) presumably through mediating a large crossover of bubbles to the left heart, was detected in only one of seven divers. On the other hand, the transcappillary passage of VGE seems unlikely since saline-contrast bubbles can be forced through the pulmonary microcirculation only with nonphysiological pressures above 300 mmHg (30). Although this finding was supported in additional studies (7), pretreatment with aminophylline greatly reduced the filtering function of the lungs, allowing bubbles up to 130 μ m in diameter to go through. Recently, a transpulmonary passage of saline-contrast bubbles was reported in almost all healthy subjects during submaximal exercise (19). The existence of these intrapulmonary (I-P) arteriovenous pathways has been documented using 50- and 25- μ m solid microspheres in isolated, ventilated, and perfused human and baboon lungs (28). Moreover, in some subjects the agitated contrast echocardiography revealed that shunting can occur even at supine rest, which was partially attributed to an increase in PAP in this posture (44). In our previous work with submaximal exercise performed after air diving (15), no arterializations were detected. However, whether the I-P shunts are open at rest after trimix diving is unknown.

In addition to the high VGE load, a concomitant increase in pulmonary artery pressure (that was doubled for at least 120 min postdive) may have contributed to the observed arterialization. Furthermore, pulmonary microembolizations and inflicted damage to the pulmonary endothelium (8, 22, 32) could also lead to intrapulmonary redistribution of blood with regional overperfusion of some pulmonary capillaries and their stress failure, as well as endothelial damage-induced increased capillary permeability. It has also been reported that gas embolism to the lung redistributed the perfusion, so that the top of the lung, where most of the bubbles were located, was less perfused (9). Thus areas with possible supersaturation can be created after diving that could also contribute to postdive shunting and prolonged arterializations. Microvascular damage in pulmonary circulation was also found in our recent study with trimix dives (29), where the signs of increased accumulation of extravascular lung water were observed. Furthermore,

Table 2. *Arterialization of gas emboli*

Subject No.	Dive 1			Dive 2			Dive 3		
	45'	60'	90'	45'	60'	90'	45'	60'	90'
1									
2	A	A			A			A	
3									
4				A	A	A	A		
5	A				A	A			
6	A								
7		A							

Displayed are individual data on the presence of gas emboli in the left cardiac chambers at different time points after surfacing. “A” indicates occurrence of arterialization.

deep water excursions usually performed in technical diving often lead to exposure of divers to elevated oxygen levels. We have previously reported a hyperoxia-induced dilatation in large-conduit arteries existing several hours after air diving, with antioxidants partially reversing this phenomenon (35). Since trimix/nitrox diving is associated with even higher and prolonged periods of hyperoxia, the dilating effect of breathed oxygen acting permissively on VGE crossing to the arterial side is possible.

Another issue that might play a role in the observed increase in VGE occurrence at the arterial side of circulation is the nature of the bubbles themselves. In contrast to air diving, in trimix diving the tissues take up an additional inert gas (helium), which can affect the composition of gas emboli and change their physical properties. Although this effect may also enhance the probability of VGE passage to the arterial side, it is still poorly investigated due to a lack of proper mathematical models of trimix bubble dynamics and technical limitations.

All cases of arterialization observed here were accompanied with bubble grade 4 in the right cardiac cavities. This indicates that significant bubble loads are necessary for them to cross over to the arterial side of circulation. However, it is difficult to assess the exact VGE load in the right heart that is required for this to happen. One of the reasons is that the grade 4 from the scaling system used in the present study (16), which was constructed for two-dimensional echocardiography, covers a wide range of bubble loads, from 1 bubble/cm² to almost complete white-out of the right cardiac atrium and ventricle. Therefore, it would be necessary to use a more sensitive scale to grade high bubble concentrations, such as the Kisman-Masurel method for Doppler ultrasound (37). Recently, a more sensitive echocardiographic imaging grading has been suggested by some investigators (37).

One limitation of the present study is the method used for probing the potential existence of PFO or other intracardiac septal defects in the test subjects. Due to the conditions at the field where the entire work was conducted, we were unable to use more sensitive methods such as contrast transesophageal and transthoracic echocardiography, or the transcranial Doppler (24, 43). Consequently, the number of divers with defects such as PFO might be underestimated. However, in the present study 5 of 7 divers from our tested group showed arterialization. Despite the fact that we might have underestimated the number of subjects with PFO, we believe that such a high number of arterializations suggests the VGE crossover mostly occurs via some other pathway (PFO prevalence in the general population is ~25%, while here it would be ~70%).

In the present study, despite the high bubble grade values and the number of arterialization cases, no symptoms of DCS or any neurological distress were observed. This finding raises the question of the significance of arterialized VGE in development of acute decompression-related pathology. Previously, the traditional view of VGE as the central mediators of decompression injury had been challenged in several reports that found that high bubble levels may have a weak positive predictive power for DCS and, contrarily, that divers who developed DCS occasionally had very few bubbles (2, 39). Furthermore, Spencer et al. (42) have shown that 160 bubbles/min observed in the carotid artery during open heart surgery led to no apparent neurological complications. However, having in mind that gas emboli can serve as an interface for

aggregations of platelets (3) or that they were linked to endothelial damage (4, 27, 34), if repeated dives associated with a high incidence of VGE arterializations are to be performed, the possible chronic consequences of recurrent gas microemboli to the brain vasculature should be considered. Furthermore, recent neuroradiological studies reported an increased number of ischemic brain lesions in asymptomatic divers without history of decompression events (26, 40, 45), which may be associated with “silent” cerebral embolism. In addition, neurological injury is currently the most frequent decompression-related problem in sport divers requiring treatment (5). Divers Alert Network (DAN) data from 2003 (10) indicate that most of injured divers with neurological type II DCS (75–90%) have followed dive profiles without performing any procedural error. It is therefore possible that the VGE in the systemic circulation are at least partially responsible for these acute cases of diving-related injury.

In conclusion, the present study demonstrated that the tested trimix profiles, generated by a widely used model of bubble formation, resulted in high VGE levels and arterialization that was evident in human subjects even at supine rest. Although no acute decompression-related disorders were identified, the possibility of long-term adverse effects due to the potentially harmful repeated microemboli in the systemic circulation cannot be excluded. Future studies investigating in more detail the individual susceptibility and the incidence of arterial bubbles in other decompression models and diving procedures appear essential.

ACKNOWLEDGMENTS

We are thankful to the members of the Croatian and Slovenian Search and Rescue diving units for their enthusiastic participation in the study and to Christian Gutvik for insightful comments regarding the gas bubble nature and tissue dynamics. We also thank the reviewers for their comments enabled us to significantly improve the quality of our work.

GRANTS

The work was supported by the Unity Through Knowledge Fund (Project No. 33/08) and Croatian Ministry of Science, Education, and Sports (216-2160133-0130) to Z. Dujic.

DISCLOSURES

S. E. Gaustad was supported by Norwegian Petroleum Directorate, Norsk Hydro, Esso Norge and Statoil under the “dive contingency contract” (No4600002328) with Norwegian Underwater Intervention (NUI).

REFERENCES

1. Bakovic D, Glavas D, Palada I, Breskovic T, Fabijanic D, Obad A, Valic Z, Brubakk AO, Dujic Z. High-grade bubbles in left and right heart in an asymptomatic diver at rest after surfacing. *Aviat Space Environ Med* 79: 626–628, 2008.
2. Bayne CG, Hunt WS, Johanson DC, Flynn ET, Weathersby PK. Doppler bubble detection and decompression sickness: a prospective clinical trial. *Undersea Biomed Res* 12: 327–332, 1985.
3. Bonin B, Straub PW, Schibli R, Buhlmann AA. Blood coagulation during critical decompression following diving experiments with oxygen-helium. *Aerospace Med* 44: 508–512, 1973.
4. Brubakk AO, Duplancic D, Valic Z, Palada I, Obad A, Bakovic D, Wisloff U, Dujic Z. A single air dive reduces arterial endothelial function in man. *J Physiol* 566: 901–906, 2005.
5. Brubakk AO, Neuman TS. (Eds.) *Bennett and Elliott's Physiology and Medicine of Diving* (5th ed.). London: Saunders, 2003.
6. Brubakk AO, Peterson R, Grip A, Holand B, Onarheim J, Segadal K, Kunkle TD, Tonjum S. Gas bubbles in the circulation of divers after ascending excursions from 300 to 250 msw. *J Appl Physiol* 60: 45–51, 1986.

7. **Butler BD, Hills BA.** The lung as a filter for microbubbles. *J Appl Physiol* 47: 537–543, 1979.
8. **Butler BD, Robinson R, Little T, Chelly JE, Doursout MF.** Cardiopulmonary changes with moderate decompression in rats. *Undersea Hyperb Med* 23: 83–89, 1996.
9. **Chang HK, Delaunois L, Boileau R, Martin RR.** Redistribution of pulmonary blood flow during experimental air embolism. *J Appl Physiol* 51: 211–217, 1981.
10. **Divers Alert Network.** *Report on Decompression Illness and Diving Fatalities, 2003.* Durham, NC: DAN, 2003.
11. **Dujic Z, Duplancic D, Marinovic-Terzic I, Bakovic D, Ivancev V, Valic Z, Eterovic D, Petri NM, Wisloff U, Brubakk AO.** Aerobic exercise before diving reduces venous gas bubble formation in humans. *J Physiol* 555: 637–642, 2004.
12. **Dujic Z, Obad A, Palada I, Ivancev V, Valic Z.** Venous bubble count declines during strenuous exercise after an open sea dive to 30 m. *Aviat Space Environ Med* 77: 592–596, 2006.
13. **Dujic Z, Obad A, Palada I, Valic Z, Brubakk AO.** A single open sea air dive increases pulmonary artery pressure and reduces right ventricular function in professional divers. *Eur J Appl Physiol* 97: 478–485, 2006.
14. **Dujic Z, Palada I, Obad A, Duplancic D, Bakovic D, Valic Z.** Exercise during a 3-min decompression stop reduces postdive venous gas bubbles. *Med Sci Sports Exerc* 37: 1319–1323, 2005.
15. **Dujic Z, Palada I, Obad A, Duplancic D, Brubakk AO, Valic Z.** Exercise-induced intrapulmonary shunting of venous gas emboli does not occur after open-sea diving. *J Appl Physiol* 99: 944–949, 2005.
16. **Eftedal O, Brubakk AO.** Agreement between trained and untrained observers in grading intravascular bubble signals in ultrasonic images. *Undersea Hyperb Med* 24: 293–299, 1997.
17. **Eftedal O, Brubakk AO, Nishi RY.** Ultrasonic evaluation of decompression: the relationship between bubble grades and bubble numbers. *Undersea Hyperb Med* 25: 35–36, 1998.
18. **Eftedal OS, Lydersen S, Brubakk AO.** The relationship between venous gas bubbles and adverse effects of decompression after air dives. *Undersea Hyperb Med* 34: 99–105, 2007.
19. **Eldridge MW, Dempsey JA, Haverkamp HC, Lovering AT, Hokanson JS.** Exercise-induced intrapulmonary arteriovenous shunting in healthy humans. *J Appl Physiol* 97: 797–805, 2004.
20. **Garrett JL.** The role of patent foramen ovale in altitude-induced decompression sickness. In: *Hyperbaric Decompression Sickness: Proceedings of a Workshop held at Armstrong Laboratory, Brooks AFB, TX, 16–18 October 1990*, edited by Pilmanis AA. Alexandria, VA: Aerospace Medical Association and Undersea and Hyperbaric Medical Society, 1995, p. 81–96.
21. **Gerriets T, Tetzlaff K, Liceni T, Schafer C, Rosengarten B, Kopsiske G, Algermissen C, Struck N, Kaps M.** Arteriovenous bubbles following cold water sport dives: relation to right-to-left shunting. *Neurology* 55: 1741–1743, 2000.
22. **Hlastala MP, Robertson HT, Ross BK.** Gas exchange abnormalities produced by venous gas emboli. *Respir Physiol* 36: 1–17, 1979.
23. **Jones JP Jr, Neuman TS.** *Dysbaric Osteonecrosis.* London: Saunders, 2003.
24. **Kerut EK, Norfleet WT, Plotnick GD, Giles TD.** Patent foramen ovale: a review of associated conditions and the impact of physiological size. *J Am Coll Cardiol* 38: 613–623, 2001.
25. **Kitabatake A, Inoue M, Asao M, Masuyama T, Tanouchi J, Morita T, Mishima M, Uematsu M, Shimazu T, Hori M, Abe H.** Noninvasive evaluation of pulmonary hypertension by a pulsed Doppler technique. *Circulation* 68: 302–309, 1983.
26. **Knauth M, Ries S, Pohmann S, Kerby T, Forsting M, Daffertshofer M, Hennerici M, Sartor K.** Cohort study of multiple brain lesions in sport divers: role of a patent foramen ovale. *BMJ* 314: 701–705, 1997.
27. **Levin LL, Stewart GJ, Lynch PR, Bove AA.** Blood and blood vessel wall changes induced by decompression sickness in dogs. *J Appl Physiol* 50: 944–949, 1981.
28. **Lovering AT, Stickland MK, Kelso AJ, Eldridge MW.** Direct demonstration of 25- and 50- μ m arteriovenous pathways in healthy human and baboon lungs. *Am J Physiol Heart Circ Physiol* 292: H1777–H1781, 2007.
29. **Marinovic J, Ljubkovic M, Obad A, Breskovic T, Salamunic I, Denoble PJ, Dujic Z.** Assessment of extravascular lung water and cardiac function in trimix SCUBA diving. *Med Sci Sports Exerc* 42: 1054–1061, 2010.
30. **Meltzer RS, Sartorius OE, Lancee CT, Serruys PW, Verdouw PD, Essed CE, Roelandt J.** Transmission of ultrasonic contrast through the lungs. *Ultrasound Med Biol* 7: 377–384, 1981.
31. **Moon RE, Camporesi EM, Kisslo JA.** Patent foramen ovale and decompression sickness in divers. *Lancet* 1: 513–514, 1989.
32. **Nossum V, Hjelde A, Brubakk AO.** Small amounts of venous gas embolism cause delayed impairment of endothelial function and increase polymorphonuclear neutrophil infiltration. *Eur J Appl Physiol* 86: 209–214, 2002.
33. **Obad A, Palada I, Ivancev V, Valic Z, Fabijanic D, Brubakk AO, Dujic Z.** Sonographic detection of intrapulmonary shunting of venous gas bubbles during exercise after diving in a professional diver. *J Clin Ultrasound* 35: 473–476, 2007.
34. **Obad A, Palada I, Valic Z, Ivancev V, Bakovic D, Wisloff U, Brubakk AO, Dujic Z.** The effects of acute oral antioxidants on diving-induced alterations in human cardiovascular function. *J Physiol* 578: 859–870, 2007.
35. **Obad A, Valic Z, Palada I, Brubakk AO, Modun D, Dujic Z.** Antioxidant pretreatment and reduced arterial endothelial dysfunction after diving. *Aviat Space Environ Med* 78: 1114–1120, 2007.
36. **Pilmanis AA, Meissner FW, Olson RM.** Left ventricular gas emboli in six cases of altitude-induced decompression sickness. *Aviat Space Environ Med* 67: 1092–1096, 1996.
37. **Pollock N.** Use of ultrasound in decompression research. *Diving Hyperb Med* 37: 68–72, 2007.
38. **Powell MR.** Physiological significance of Doppler-detected bubbles in decompression sickness. In: *Proceedings of the Twelfth Undersea Medical Society Workshop*, edited by Pearson R. Bethesda, MD: 1977.
39. **Powell MR, Thoma W, Fust HD, Cabarro P.** Gas phase formation and Doppler monitoring during decompression with elevated oxygen. *Undersea Biomed Res* 10: 217–224, 1983.
40. **Reul J, Weis J, Jung A, Willmes K, Thron A.** Central nervous system lesions and cervical disc herniations in amateur divers. *Lancet* 345: 1403–1405, 1995.
41. **Sawatzky KD.** *The Relationship Between Intravascular Doppler-Detected Gas Bubbles and Decompression Sickness After Bounce Dive in Humans* (MSc thesis). Toronto: York University, 1991.
42. **Spencer MP, Lawrence GH, Thomas GI, Sauvage LR.** The use of ultrasonics in the determination of arterial aeroembolism during open-heart surgery. *Ann Thorac Surg* 8: 489–497, 1969.
43. **Stewart MJ.** Contrast echocardiography. *Heart* 89: 342–348, 2003.
44. **Stickland MK, Welsh RC, Haykowsky MJ, Petersen SR, Anderson WD, Taylor DA, Bouffard M, Jones RL.** Intra-pulmonary shunt and pulmonary gas exchange during exercise in humans. *J Physiol* 561: 321–329, 2004.
45. **Tetzlaff K, Friege L, Hutzelmann A, Reuter M, Holl D, Lepow B.** Magnetic resonance signal abnormalities and neuropsychological deficits in elderly compressed-air divers. *Eur Neurol* 42: 194–199, 1999.
46. **Verstappen FT, Bernards JA, Kreuzer F.** Effects of pulmonary gas embolism on circulation and respiration in the dog. I. Effects on circulation. *Pflügers Arch* 368: 89–96, 1977.
47. **Wilmshurst PT, Byrne JC, Webb-Peploe MM.** Relation between interatrial shunts and decompression sickness in divers. *Lancet* 2: 1302–1306, 1989.
48. **Yount DE, Hoffman DC.** On the use of a bubble formation model to calculate diving tables. *Aviat Space Environ Med* 57: 149–156, 1986.