

# Dysbaric osteonecrosis in diving fisherman: a case report

SEHER KURTUL<sup>1</sup>, NEJDIYE GÜNGÖRDÜ<sup>2</sup>

<sup>1</sup>Department of Occupational Disease, Bozyaka Training and Research Hospital, University of Health Sciences, Izmir, Turkey

<sup>2</sup>Department of Occupational Disease, Cerrahpasa Medical Faculty, Istanbul University-Cerrahpasa, Istanbul, Turkey

**KEYWORDS:** Dysbaric osteonecrosis; diver; decompression sickness

## ABSTRACT

**Background:** *Dysbaric osteonecrosis (DON) is defined as avascular bone necrosis, usually involving specific parts of the long bones, which is seen in divers or compressed-air workers due to exposure to pressure. We describe a case of DON in an artisanal diving fisherman working underwater for many years.* **Methods:** *A 48-year-old male case was admitted to the occupational disease outpatient with left shoulder and arm pain for 1-2 years. Since the age of 20, he has been artisanal diving fishing with a hookah at a depth of 20-25 meters in the sea. In 2011, he received hyperbaric oxygen therapy for widespread pain in the whole body due to decompression sickness (DCS). In the case's left shoulder joint x-ray and magnetic resonance imaging, degenerative changes in the acromioclavicular joint and signal changes consistent with osteonecrosis starting from the subcortical area of the humeral head and extending to the proximal shaft of the humerus were observed.* **Conclusions:** *DON is among the most common long-term pathologies in professional divers. In Turkey, as in our case, not applying safe decompression procedures and unsafe diving practices are common among diving fishers. In studies, the frequency of exposure to pressure, duration and depth of dive, insufficient decompression, formation of DCS and increasing age were associated with DON. Today, DON remains an occupational hazard with significant medical and social consequences. Diving fishers should be informed about the sequelae of DCS and trained on the safety measures to be taken.*

## 1. INTRODUCTION

Dysbaric osteonecrosis (DON) is among professional divers' most common long-term pathologies. DON is defined as avascular bone necrosis, usually involving specific parts of the long bones, which is seen in divers or compressed-air workers due to exposure to pressure. In the literature, the prevalence of DON in professional divers varies between 0% and 70.6% [1]. Although osteonecrosis is thought to be due to ischemia, the underlying causes are still unknown. DON is divided into two types A and B type lesions, which have a very different courses in terms of location, clinical prognosis and treatment.

Type A lesions are more common in the hip and shoulder joints and are usually progressive and show signs and symptoms. Type B lesions are not close to the articular surface, are not progressive, and do not show signs and symptoms. DON is observed significantly more frequently in groups that do not follow the diving rules, dive profoundly and are likely to encounter much more exposure to decompression sickness (DCS). It is known that DCS does not always lead to Dysbaric osteonecrosis. The bone examination may be completely normal in a diver who has had DCS several times. In contrast, a diver without DCS or risk diving history may have DON [2, 3].

Received 24.05.2022 - Accepted 14.07.2022

\*Corresponding author: Seher Kurtul, Department of Occupational Disease, Bozyaka Training and Research Hospital, University of Health Sciences, Izmir, Turkey, E-mail: seherkurtul79@gmail.com

In Turkey, diving fishermen work in small cockpit boats to hunt various sea creatures, using compressed air supplied from the surface via a “hookah” system. The hookah system supplies air to the diver through a long hose coming out of the air compressor. This method allows diving fishers to stay undersea longer than the required safe limits. In addition, the desire to earn additional income may cause the safe limits to be exceeded, and DCS may occur many times in diving fishers. We aim to present a case of DON working as a diving fisherman and diagnosed as a result of underwater occupational risks.

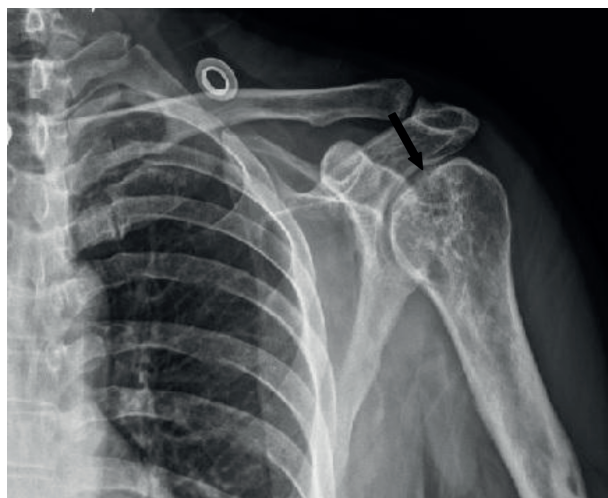## 2. CASE REPORTS

A 48-year-old male case was admitted to the occupational disease outpatient with left shoulder and arm pain for 1-2 years. He has no history of chronic disease, drug use, or cigarette-alcohol habit. Since the age of 20, he has been artisanal diving fishing with a hookah at a depth of 20-25 meters in the sea. During the year, he worked underwater for 6 hours a day, intermittently, every day when the weather conditions were suitable for diving, without obeying the required times while diving into the water and coming to the surface. In 2011, he received hyperbaric oxygen therapy for widespread pain in the whole body due to DCS. He complained of pain in the left shoulder and loss of strength in the left arm

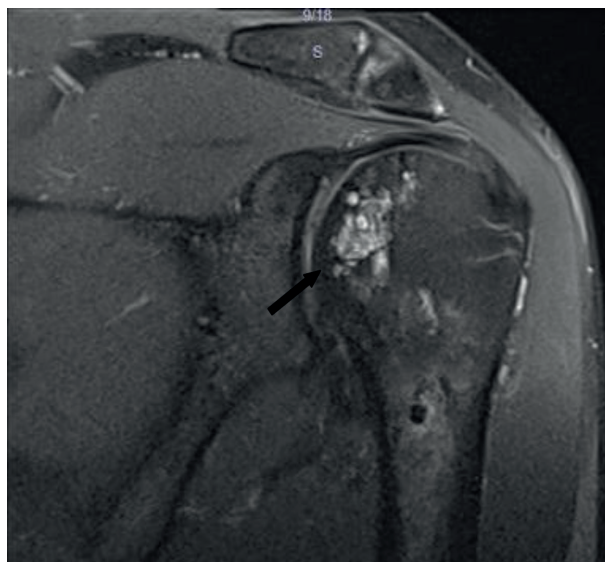
for the last 1-2 years, and he applied to underwater medicine outpatient as his complaints gradually increased. In the case’s left shoulder joint X-ray and magnetic resonance imaging, degenerative changes in the acromioclavicular joint and signal changes consistent with osteonecrosis starting from the subcortical area of the humeral head and extending to the proximal shaft of the humerus were observed (Figure 1, 2).

## 3. DISCUSSION

Although bone disorders in compressed air tunnel workers and divers have been known for many years, it has become understandable after the discovery of X-rays. DON was diagnosed for the first time in compressed air tunnel workers by bone X-ray in 1911 with two different studies. The first diagnosis of DON in divers was much later, in 1941. In the later years, especially after accepting this disease as an occupational disease, studies on the frequency of DON were conducted in various countries and different occupational groups working in compressed air [3]. The prevalence of DON varies considerably between different countries, and in some countries, including our country (Hawaii, Korea, and Japan), the high prevalence is most likely due to the lack of



**Figure 1.** X-ray of the shoulder joint.



**Figure 2.** Magnetic resonance imaging of the shoulder joint.

safe decompression procedures and the greater frequency of unsafe diving practices, especially among divers [4]. In studies, the frequency of exposure to pressure, duration and depth of dive, insufficient decompression, formation of DCS and increasing age were associated with DON. Although it is thought that there is a mechanism associated with inert gas embolism in the aetiology of DON, there is no clear evidence of a cause-effect relationship. It is thought that it is a gradual process that occurs due to more than one dive [5, 6]. Other causes include mechanisms such as hypercoagulability and fat embolism [7].

In a study examining 39 artisanal diving fishermen in Mexico, grade II or higher DON was detected in 30 (76.9%) of them. At least two joints were affected in 22 (56.4%) of 39 fishers. The number of joints with DON was positively correlated with lifetime maximum diving depth and meantime at the bottom of the sea [8]. In 2009, Toklu and Çimsit analyzed the types of equipment used by professional sponge divers and the medical records of those undergoing recompression therapy. They reported that factors such as unsafe diving profiles, resistance to treatment, and a long delay before recompression contribute to DON in sponge divers [9].

In Turkey, professional industrial divers are checked for DON in their periodic examinations. However, in most countries, long bones examinations are performed optionally and medically indicated by diving fishers. DON should be considered in any shoulder or hip pain, even mild severity in all divers. Thus, possible joint loss and complex surgical interventions can be prevented with early examinations.

Today, DON remains an occupational hazard with significant medical and social consequences. Diving fishers should be informed about the sequelae of DCS and trained on the safety measures to be

taken even if it is impossible to eliminate the hazard by following the rules of safe diving, possibly reducing the risk significantly.

**DECLARATION OF INTEREST:** No potential conflict of interest relevant to this article was reported by the authors.

**INFORMED CONSENT STATEMENT:** Written informed consent for publication of their details was obtained from the patient.

## REFERENCES

1. Uguen M, Pougnet R, Uguen A, et al. Dysbaric osteonecrosis in professional divers: two case reports. *Undersea Hyperb Med.* 2015;42(4):363-7.
2. Coleman B, Davis FM. Dysbaric osteonecrosis in technical divers: The new 'at-risk' group? *Diving Hyperb Med.* 2020;50(3):295-299. Doi: 10.28920/dhm50.3.295-299
3. Aktaş Ş: Disbarik osteonekroz. Aktaş Ş (eds): Eğitimciler için dalış sağlığı. İstanbul: Türk deniz araştırmaları vakfı (TÜDAV), 2019;51:113-27.
4. Gempp E, Blatteau JE, Simon O, Stephant E. Musculoskeletal decompression sickness and risk of dysbaric osteonecrosis in recreational divers. *Diving Hyperb Med.* 2009;39(4):200-4.
5. Coulthard A, Pooley J, Reed J, Walder D. Pathophysiology of dysbaric osteonecrosis: a magnetic resonance imaging study. *Undersea Hyperb Med.* 1996;23(2):119-20.
6. Kenney IJ, Sonksen C. Dysbaric osteonecrosis in recreational divers: a study using magnetic resonance imaging. *Undersea Hyperb Med.* 2010 Sep-Oct;37(5):281-8. PMID: 20929185.
7. Miyanishi K, Kamo Y, Ihara H, Naka T, Hirakawa M, Sugioka Y. Risk factors for dysbaric osteonecrosis. *Rheumatology (Oxford).* 2006;45:855-8. Doi: 10.1093/rheumatology/kel013
8. Popa D, Medak A, Chin W, et al. Dysbaric osteonecrosis (DON) among the artisanal diving fishermen of Yucatán, Mexico. *Diving Hyperb Med.* 2020;50(4):391-398. Doi: 10.28920/dhm50.4.391-398
9. Toklu AS, Cimsit M. Sponge divers of the Aegean and medical consequences of risky compressed-air dive profiles. *Aviat Space Environ Med.* 2009;80(4):414-7. Doi: 10.3357/asm.2420.2009