

Effect of hyperbaric oxygen treatment on liver hepatocyte damage in oral candidiasis immunosuppressed rats

Agni Febrina Pargaputri*, Dwi Andriani*, Mardiyanto Riski Hartono*, Kharinna Widowati**

*Oral Biology Department, Faculty of Dentistry Universitas Hang Tuah, Surabaya

**Oral Medicine Department, Faculty of Dentistry Universitas Hang Tuah, Surabaya

Correspondence: agni.febrina@hangtuah.ac.id

Received 12 September 2022; 1st revision 26 October 2022; 2nd revision 21 Desember 2022; Accepted 26 Desember 2022; Published online 28 December 2022

Keywords:

Hepatocyte; hyperbaric oxygen; immunosuppressed; liver damage

ABSTRACT

Background: Liver is an organ that performs a role in metabolism and detoxification of chemical substances. The use of immunosuppressive drugs excessively not only become predisposing factor for oral candidiasis, but also can cause damage and affect liver's function. Hyperbaric oxygen treatment was known to preserve hepatocytes and prevent liver damage. This study was aimed to investigate the effect of hyperbaric oxygen treatment on liver hepatocyte damage in oral candidiasis immunosuppressed rats.

Method: We divided fifteen Wistar rats randomly into three groups: G1 (healthy rats), G2 (immunosuppressed rats with oral candidiasis), and G3 (immunosuppressed rats with oral candidiasis given hyperbaric oxygen). The immunosuppressed condition was made by giving dexamethasone and tetracycline orally for 14 days. Induction of *Candida albicans* 0.1 cc was conducted on the fourth day. Hyperbaric oxygen treatment was given for five days continuously. The histopathological changes in the liver were measured by counting the amount of normal hepatocytes, pycnotic, karyolysis, karyorrhexis, and score of necrosis area using light microscope with 400x magnification.

Result: The amount of pycnotic, karyolysis, and karyorrhexis hepatocytes increased in G2 and decreased significantly in G3, likewise the score of necrosis area. The statistical test using oneway Anova and LSD test showed significant differences ($p < 0,05$) in pycnotic, karyolysis, and karyorrhexis hepatocytes between G1, G2, and G3.

Conclusion: The hyperbaric oxygen treatment effect on liver hepatocyte damage in oral candidiasis immunosuppressed rats.

Copyright ©2022 National Research and Innovation Agency. This is an open access article under the CC BY-SA license (<https://creativecommons.org/licenses/by-sa/4.0/>).

doi: <http://dx.doi.org/10.30659/odj.9.2.319-326>

2460-4119 / 2354-5992 ©2022 National Research and Innovation Agency

This is an open access article under the CC BY-SA license (<https://creativecommons.org/licenses/by-sa/4.0/>)

Odonto : Dental Journal accredited as Sinta 2 Journal (<https://sinta.kemdikbud.go.id/journals/profile/3200>)

How to Cite: Pargaputri *et al.* Effect of hyperbaric oxygen treatment on liver hepatocyte damage in oral candidiasis immunosuppressed rats. Odonto: Dental Journal, v.9, n.2, p.319-326, December 2022

INTRODUCTION

Liver is an organ that performs many different and interrelated functions. The liver plays a role in the metabolism of carbohydrates, proteins, fats, and foreign chemicals. It also become an important key in getting rid of or excreting drugs and other chemical substances into the bile.¹ These chemicals will be detoxified and inactivated so that they become harmless to the body.² Hepatocytes play an important role in liver function. These cells make up most of the volume of liver.³ Drugs and foreign chemicals can cause liver damage by decreasing hepatocytes' resistance and regeneration ability, which in turn can cause harmful effects in liver.²

Immunosuppression is a condition in which a person is unable to oppose infection because of the decreased immune system. One of the causes of immunosuppression is the use of glucocorticoid drugs which not only have inflammatory effects but also immunosuppression effects. This condition also becomes one of the causes of increasing mycosis infection in the oral cavity, which is called oral candidiasis. Oral candidiasis occurs when some predisposing conditions favor *Candida albicans* (*C. albicans*) to become pathogenic.^{4,5}

The host immune system plays a role in maintaining *C. albicans* as normal microorganisms commonly found in the oral cavity in a stable condition.^{6,7} Decrease in the immune system due to immunosuppression will cause a failure in the elimination of *Candida* adhesion in oral mucosa, which in turn predisposes to oral candidiasis.⁷ However, the use of immunosuppressant drugs continuously and excessively not only become predisposing factor for the occurrence of oral candidiasis, but also affect the liver performance.^{8,9} The liver will work harder so that it can damage hepatocyte cells which will then decrease the function of the liver.^{2,9}

The measurement of the magnitude protective effect of the liver can be done with estimate the enzyme activities, then verifying the liver cell histologically. Liver damage is associated with the necrosis of the liver cells, a decline in the level of tissue glutathione, and the elevation of tissue lipid peroxidation and serum levels of several biochemical parameters.¹⁰ Some previous studies showed that the elevation of transaminase enzyme levels can be used to detect and suggests any inflammation or injury in the liver. Measurement of these enzymes can be used as a tool in identifying the safety of substances that enter and are metabolized by the liver.¹¹⁻¹³

Hyperbaric oxygen therapy is known to affect the function of the injured liver.¹⁴ This therapy can increase hepatocyte proliferation in liver damage, and defend hepatocyte necrosis in liver transplantation mice model. The prior study showed that hyperbaric oxygen treatment able to protect hepatocytes from necrosis and apoptosis, as well as to increase sinusoid diameter and microvascular density index in rats model.¹⁵ This treatment has been known to have a protective effect on necrosis of hepatocellular caused by exaggregation of acetaminophen in experimental animals.¹⁶ Hence this study was aimed to investigate the effect of hyperbric oxygen treatment on liver hepatocyte damage in oral candidiasis immunosuppressed rats.

MATERIALS AND METHODS

Materials used in this study were 4% EDTA anticoagulant, 10% ketamine, 2% xylazine hydrochloride, stock of bacteria *C. albicans* ATCC-10231, saburoud agar, phosphat buffer saline, dexamethasone, tetracycline, 100% pure oxygen 2.4 ATA in hyperbaric animal chamber, and betadine solution. This research was approved by the Research Ethics Committee of Dentistry Faculty Universitas Hang Tuah Surabaya (Ref. no:

EC/010/KEPK-FKGUHT/VII/2019). The implementation of this study was in the oral biology laboratory of Dentistry Faculty and biochemistry laboratory of Medical Faculty Universitas Hang Tuah Surabaya, and pathological laboratory of Dr. Ramelan Hospital Surabaya.

The design of this study was a post-test only control group design. Experimental animal models used in this study were fifteen male Wistar rats aged 6 months old, weighed 200-250 grams. The rats were adapted for 7 days before the research, then randomly divided into three groups. G1: group of healthy rats, G2: group of immunosuppressed rats with oral candidiasis, and G3: group of immunosuppressed rats with oral candidiasis given hyperbaric oxygen. The condition of immunosuppression was created by administering dexamethasone 0.5 mg/day and tetracycline 1 %/day orally. After three days, dose was reduced by 10% and continued for 14 days. The induction of *C.*

albicans (ATCC-10231) 6×10^8 0.1 cc was conducted on the dorsum tongue of rats, given once every two days for 12 days.^{17,18}

In the G3 group, the rats were given hyperbaric oxygen treatment 2.4 ATA for 30 minutes at 3 intervals of 5-minute breathing normal air. This treatment was carried out for five days continuously.¹⁷ All rats were sacrificed at the end of the study, then the liver of all rats was taken for examining the histopathological change of hepatocytes. The number of hepatocyte damage was examined by counting the pycnotic, karyolysis, and karyorrhexis features using a light microscope with 400x magnification. The scoring technique of necrosis cells in this study was shown in Table 1.²¹

Statistical analyses were done using Anova test to show the different numbers of hepatocytes among groups, then to show the significant difference among each group, we used the Least Significant Difference (LSD) test.

Table 1. The scoring technique used in this study²¹

Score	Score Notes
1	Necrosis involves 1/3 lobular of liver.
3	Necrosis involves 1/3-2/3 lobular of liver.
4	Necrosis involves > 2/3 lobular of liver.
5	Necrosis involves 1/3-2/3 lobular of liver + bridging necrosis
6	Necrosis involves > 2/3 lobular of liver + bridging necrosis

RESULTS

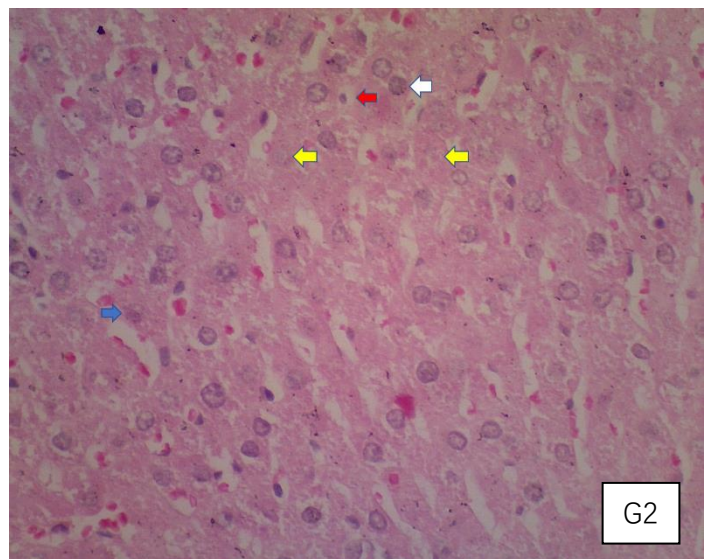
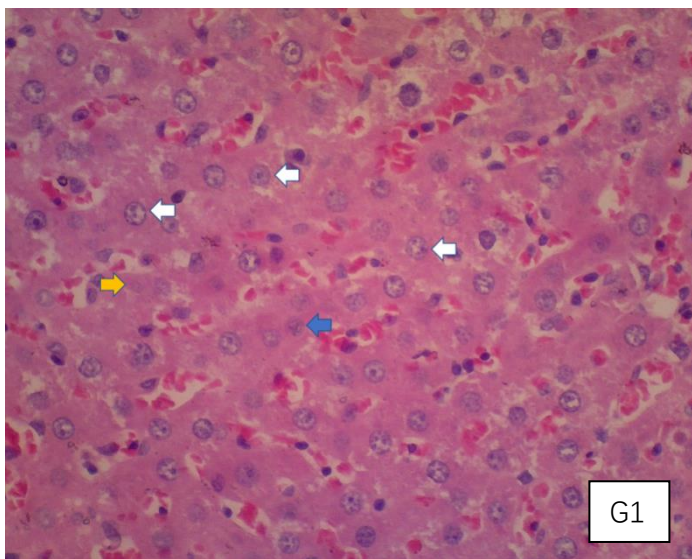
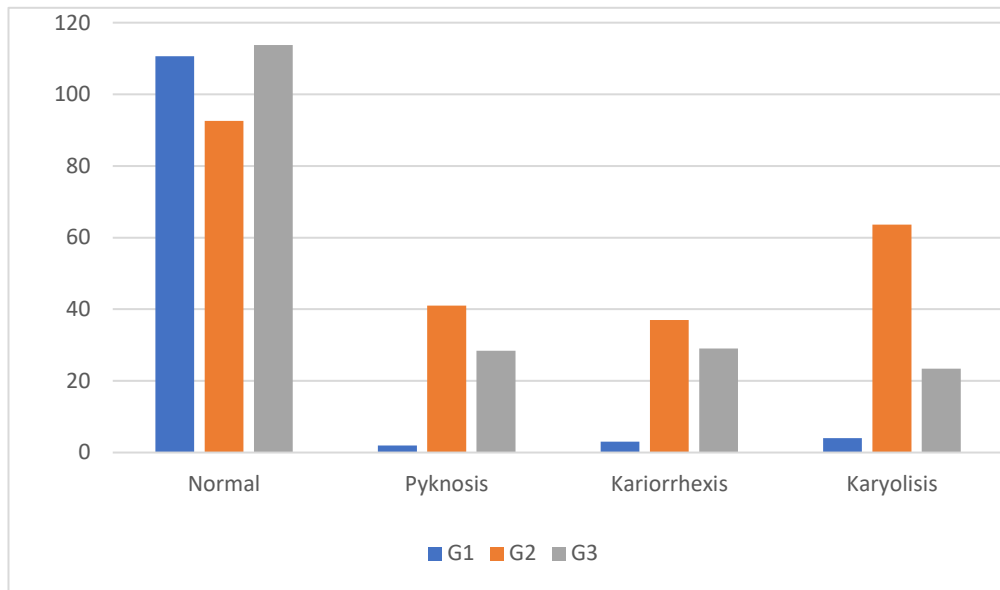
The histopathological changes of hepatocytes in the liver were measured by counting the number of normal hepatocytes, pycnotic, karyorrhexis, and karyolysis. Examination of histopathological changes was used to determine the degree of liver damage. In G2 group showed the highest number of pycnotic, karyorrhexis, and karyolysis hepatocytes, while the G3 decreased significantly (Picture 1). The number of pycnotic,

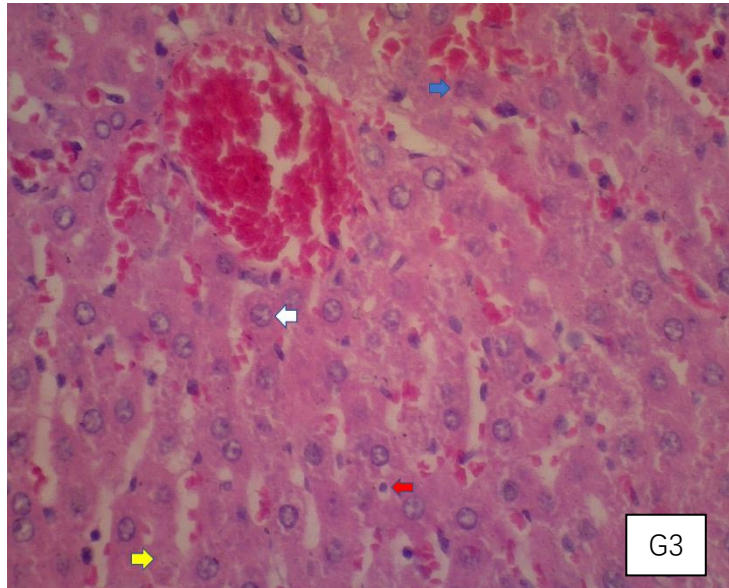
karyorrhexis, and karyolysis hepatocytes showed a significant difference within each group (Table 1), likewise the scores of necrosis area. Histopathological features of liver in all experimental group are shown in Picture 2.

Table 1. Number of hepatocytes (normal, pyknosis, karyolysis, karyorrhexis) and scoring of necrosis area in each group (mean ± SD)

	Normal	Pycnotic	Karyorrhexis	Karyolysis	Necrosis
G1	110.6±11.9 ^a	2±1.6 ^a	3±1.5 ^a	4±3.7 ^a	0±0.0 ^a
G2	92.6±9 ^b	46±14.1 ^b	37±7.1 ^b	63.6±6.7 ^b	1.6±0.5 ^b
G3	113.8±15.6 ^a	28.4±9.5 ^c	29±1.6 ^c	23.4±4.6 ^c	1±0.0 ^c

The different superscript letters showed significant differences at $p < 0.05$.





Picture 2. Histopathological features of normal hepatocyte, pycnotic, karyorrhexis, and karyolysis in each group (G1) group of healthy rats, (G2) group of oral candidiasis immunosuppressed rats, (G3) group of oral candidiasis immunosuppressed rats given hyperbaric oxygen). White arrows: normal hepatocyte cells, red arrows: pycnotic, blue arrows: karyorrhexis, yellow arrows: karyolysis. Haematoxylin Eosin staining with 400x magnification.

DISCUSSION

Based on the result of this study showed that the average number of hepatocyte damage in G2 group was the highest compared to the G1 and G3 (Picture 1). This could be indicated that the administration of immunosuppressant drugs in this study could trigger damage to hepatocytes and decrease the number of normal hepatocytes. The occurrence of this is because the immunosuppressant drugs that have been digested are then absorbed and together the blood flow enters the liver to be detoxified.⁸ The blood containing these drugs after entering the liver will be in direct contact with the liver sinusoid for detoxification process. The process of detoxification beyond the liver's ability will force the liver to work harder and ultimately result in damage to the liver cells.^{2,9} Hepatocyte necrosis emerged due to the excess of toxic compounds that enter the liver or also due to the occurrence of infection in the liver. Before experiencing necrosis, liver cells will experience an inflammatory reaction which then

results in disruption of the balance or integrity of the cell membrane and ends with cell rupture and cytoplasmic discharge. The more toxic compounds that enter the liver, will cause an increase in carrying out the detoxification process. A previous study showed that the higher concentration of drugs or compounds that enter the liver, the result in the response or damage to the liver hepatocytes become higher.²²

The use of dexamethasone as an immunosuppressant drug in this study may lead to hepatocyte damage with several ways. Some evidence showed that glucocorticosteroids affect the gradual elevation of intracellular organelles' fragility with a change in plasma membrane properties and mitochondrial structures, which then lead to a decrease in the number of cells. The previous study stated that dexamethasone reduces mitochondria in treating liver cells and reduces oxidative phosphorylation and active respiration.²³ This may lead to electrolyte balance disturbance through the mechanism that depends on energy,

sodium, and the potassium pump. The flow of potassium ions may occur with the flow of sodium ions, resulting in increased cytoplasmic osmotic pressure, as a result, swollen cells may also occur and cause hydrolysis.²⁴ The use of a high dose of dexamethasone has been known to cause serious side effects as immunosuppression and didn't indicate a protective ability against liver damage.²⁵

In the G3 group, the average number of pycnotic, karyorrhexis, and karyolysis hepatocytes significantly decreased when compared to the G2 group. This suggests that hyperbaric oxygen treatment has an effect to protect the hepatocytes by increasing their proliferation in the injured liver caused by immunosuppressant drugs. Stimulation of hepatocyte proliferation could occur by normalizing the localization of Multidrug resistance-associated protein 2 (Mrp-2) to the apical membrane of the hepatocytes and then activating transporter functions.¹⁵ The result of this study also indicate that hyperbaric oxygen treatment 2.4 ATA can decrease the number of liver hepatocyte damage in oral candidiasis immunosuppressed rats. This treatment can increase sinusoid diameter and microvascular density index so that it can protect hepatocytes from necrosis and apoptosis.¹⁵ The administration of hyperbaric oxygen treatment was very closely related to increasing mitochondrial function in the regeneration of liver cells, furthermore it could stabilize metabolism of energy by increasing oxygen transport to damaged liver tissue. Providing hyperbaric oxygen, would reduce malondialdehyde and increase antioxidant activity which then provides benefits for liver cell regeneration.¹⁵ This therapy was also can inhibit the enhancement of lipid peroxidation, and prevent necrosis of the hepatocytes.^{15,26} It has known that hyperbaric oxygen treatment can regulate the immune system, which is the activity of phagocytosis and angiogenesis can be stimulated.

The previous study showed that this therapy can alleviate pro-inflammatory cytokines production in several animal studies, as measured by the subside of inflammatory cell infiltration and tissue edema. On the other hand, hyperbaric oxygen treatment can enhance the activity of antioxidants, which then provide to diminish inflammation in hepatic injury.¹⁶

The use of immunosuppressant drugs in this study could trigger damage to hepatocytes, which can be seen from the histopathological changes in the liver that showed the degree was mild to moderate.²¹ However, the use of hyperbaric oxygen in this study could protect the liver against injuries associated with the use of immunosuppressant drugs. It may indicate that oxidative stress derived from oxygen-based therapy, at relevant levels, acts as a signaling molecule that can induce the activity of antioxidants and then promote the healing process of injured tissue.^{19,20}

Dexamethasone as an immunosuppressant drug used in this study has been proven to cause immunosuppressed conditions by decreasing the number of leukocytes. Since leukocytes have a crucial role in the innate and adaptive immune system, a decrease in their number may indicate a decrease in the immune system against infection.²⁷ It may lead to suppression of the nonspecific inflammatory response, which then causes predisposing factors for oral candidiasis.²⁸ In this study, the oral candidiasis condition in immunosuppressed rats was confirmed by observing pseudomembranous lesions on rats' tongues and a laboratory examination using chrom agar, which is shown the presence of the *Candida* colony.²⁷

Hyperbaric oxygen treatment can be used to eliminate fungal infections. It is also known as adjuvant therapy in eliminating oral candidiasis infection by *C. albicans*.¹⁷ This therapy also showed has the effect of repairing liver injury.¹⁵ In the

presence of infection, which allows the administration of drugs, it is necessary to consider the administration of drugs that are metabolized by the liver. Furthermore, giving therapy with hyperbaric oxygen can be used as an alternative treatment.

This research showed that the use of immunosuppressant drugs can induce both oral candidiasis and liver hepatocyte damage. However, the limitation of the research is we did not investigate the direct correlation between the occurrence of oral candidiasis and liver hepatocyte damage. Therefore, further research is needed to evaluate its direct correlation under immunosuppressed conditions. Research with a larger sample size of an immunosuppressed model was also required to determine the correlation of histopathological changes in hepatocyte and biochemical parameter levels toward the severity of liver disease.

CONCLUSION

The administration of hyperbaric oxygen treatment 2,4 ATA for five days continuously affect liver hepatocyte damage in oral candidiasis immunosuppressed rats.

ACKNOWLEDGEMENT

The authors wish to acknowledge Universitas Hang Tuah Surabaya for financially supported this research.

REFERENCES

- Guyton and Hall. *Textbook of Medical Physiology*. 12th edition. Singapore : Elsevier; 2014; p.907-8.
- Kendran Anak Agung Sagung, Anak Agung Gde Arjana , Anak Agung Sagung Istri Pradnyantar. *Aktivitas Enzim Alanine-Aminotransferase dan Aspartate Aminotransferase pada Tikus Putih Jantan yang Diberi Ekstrak Buah Pinang*. Buletin Veteriner Udayana. 2017; 9 (2): 132-138.
- Schulze Ryan J, Micah B. Schott, Carol A. Casey, Pamela L. Tuma, and Mark A. McNiven. *The Cell Biology of The Hepatocyte: A Membrane Trafficking Machine*. J. Cell Biol. 2019; 218 (7): 2096–2112.
- Nuri Fitriasaki, Indah Suasani Wahyuni. *Potensi Probiotik Dalam Tatalaksana Oral Candidiasis: Ulasan Sistematis*. ODONTO Dental Journal. 2021; 8 (1): 34-44.
- Addina Aimana Sabila, Ade Ismail A.K, Rochman Mujayanto. *Oral Hygiene Buruk Pasien Rawat Inap Tidak Berkaitan Dengan Pertumbuhan Oral Candidiasis*. ODONTO Dental Journal. 2017; 4 (1): 56-60.
- Shanty Chairani, Sri W Rais, Rani Purba, Nabilah Nazalika. *Comparative Assessment Of Aloe Vera Juice And 0.06% Chlorhexidine On Candida Albicans Plaque*. ODONTO Dental Journal. 2019; 6 (1): 34-39.
- Rahayu RP, Prasetyo RA, Purwanto DA, Kresnadi U, Iskandar RPD, Rubianto M. *The Immunomodulatory Effect Of Green Tea (Camellia sinensis) Leaves Extract On Immunocompromised Wistar Rats Infected By Candida albicans*. Vet World. 2018 Jun;11(6):765-770.
- Meurman JH, Siikala E, Richardson M, Rautemaa R. *Non-Candida albicans Candida yeasts of the oral cavity*. In: Méndez-Vilas A (ed.), *Communicating Current Research and Educational Topics and Trends in Applied Microbiology*. 2017: 719-731.
- Prasetiawan E, Sabri E, Ilyas S. *Gambaran Histologis Hepar Mencit (Mus musculus L.) Strain Ddw Setelah Pemberian Ekstrak N-Heksan Buah Andaliman (Zanthoxylum acanthopodium Dc.) Selama Masa Pra Implantasi Dan Pasca Implantasi*. Sainia Biol. 2012; 1 (1): 40-45.
- Sai Sruthie Arige, Sai Datri Arige, Lakshmana RA. *A Review of Hepatoprotective Activity*. International Journal of Current Research. 2017; 9 (6): 51876-51881
- Hapsari, Amalia Budhi. *Pengaruh Pemberian Simunox Terhadap Kadar Ast Dan Alt Pada Manusia Sehat*. [Tesis]. Universiti Diponegoro, Semarang. 2011
- Antai AB, Eyong MU, Eteng EH, Itam M, Eko M, Ita SO. *Serum Protein and Enzyme Levels in Rats Following Administration Of Ethanolic Leaf Extract Of Ageratum Conyzoides (Goat Weed)*. Nig J Physiol Sci. 2009; 24 (2): 117-120.
- Heegazy AMS, Fouad UA. *Evaluation of Lead Hepatotoxicity: Histological, Histochemical and Ultrastructural Study*. Forensic Med Anat Res. 2015; 2: 70-79.

14. Oter S, Edremitlioglu M, Korkmaz A, Coskun O, Kilic D, Kisa U, et al. *Effects Of Hyperbaric Oxygen Treatment On Liver Functions, Oxidative Status, And Histology In Septic Rats*. Intensive Care Med. 2005; 31(9): 1262-8.
15. Sun Y, Wen Y, Shen C, Zhu Y, You W, Meng Y, et al. *Hyperbaric Oxygen Therapy in Liver Diseases*. Int J Med Sci. 2018; 15 (8): 782-7.
16. Taslipinar MY, I Aydin, U Kaldirim, FN Aydin, M Agilli, YE Eyi, et al. *Hyperbaric Oxygen Treatment and n-Acetylcysteine Meliorateacetaminophen-Induced Liverinjury in a Rat Model*. Human and Experimental Toxicology. 2013; 32(10): 1107–16.
17. Pargaputri AF, Andriani D. *The Effect of Hyperbaric Oxygen Therapy to The Amount Of Lymphocytes In Oral Candidiasis Immunosuppressed Model*. Denta J Kedokt Gigi. 2018; 12 (2): 36-44.
18. Andriani D, Pargaputri AF. *Enhance Of IL-22 Expression in Oral Candidiasis Immunosuppressed Model With Acanthus Illicifolius Extract Therapy*. IOP Conf Ser Earth Environ Sci. 2019; 217: 012056.
19. Lima CX, Sanches MD, Rezende Neto JB, Silva RCO, Teixeira MM, Souza DG, et al. *Hyperbaric Oxygen Therapy Aggravates Liver Reperfusion Injury in Rats*. Acta Cir Bras. 2008; 23 (4): 315-321.
20. Majdina Safina, Dian Mulawarmanti, Yoifah Rizka. *Efektivitas Kombinasi Terapi Oksigen Hiperbarik dan Gel Teripang Emas (Stichopus hermanii) terhadap Peningkatan Jumlah Osteoblas pada Tikus Diabetes Melitus yang Diinduksi Bakteri Porphyromonas gingivalis*. Denta Jurnal Kedokteran Gigi. 2016; 10(1): 31-38.
21. Lukiswanto Bambang Sektiari , Wiwik Misaco Yuniarti, Y. Yosis Motulo. *Effects Of Hyperbaric Therapy On Liver Morphofunctional Of Rabbits (Oryctolagus Cuniculus) After Hind Limb Ischemia-Reperfusion Injury*. Veterinary World. 2017; 10 (11): 1337-42.
22. Indayani, Ningrum Sri. *Pengaruh Pemberian Deksametason terhadap Kerusakan Hepar Tikus Jantan (Rattus norvegicus) Galur Wistar* [Internet]. 2015.
23. Alaa Hussein AL-Safy. *Histopathological Effects Due To Drug Dexamethasone Onthe Liver Of Pregnant White Rats*. Biochem. Cell.Arch. 2020; 20 (1): 703-707. DOI : 10.35124/bca.2020.20.1.703
24. Abdelhalim MA and Jarrar BM. *Gold Nanoparticles Induced Cloudy swelling to Hydropic Degeneration, Cytoplasmic Hyaline Vacuolation, Polymorphism, Binucleation, Karyopyknosis, Karyolysis, Karyorrhexis and Necrosis in The Liver*. Lipids Health Dis. 2011; 22(10): 166-170
25. Halil Eken, Hayrettin Ozturk, Hulya Ozturk, Huseyin Buyukbayram. *Dose-Related Effects Of Dexamethasone On Liver Damage Due to Bile Duct Ligation In Rats*. World J Gastroenterol. 2006; 12(33): 5379-83.
26. Agni Febrina Pargaputri, Dwi Andriani. *Hepatocellular Liver Function of Immunosuppressed Rats with Oral Candidiasis after Hyperbaric Oxygen Treatment: Alanine Transaminase and Aspartate Transaminase Levels*. Archives of Orofacial Sciences. 2021; 16(Supp. 1): 5–9.
27. Ucy Nur Hamida Al Abrori, Nurina Febriyanti Ayuningtyas, Diah Savitri Ernawat, Hening Tuti Hendarti, Meircurius Dwi Condro Surboyo, Desiana Radithia. *Oral Candidiasis in Immunosuppressed Wistar Rats (Rattus norvegicus) Post Dexamethasone Injection at 7.2 mg/kg and 16 mg/kg Doses* . Braz Dent Sci. 2020; 23 (4) : 1-7.
28. Xiaozhu Chu. *Oral Candidiasis: Relation To Systemic Diseases And Medications* . Dentistry 3000. 2017; 5 (1): 1-6.