



## Case report

## A case of transanal barotrauma by high-pressure compressed air leading to transverse colon perforation with extensive colon serosal tear

Takayuki Tanaka<sup>a,b,\*</sup>, Shinichiro Ito<sup>b</sup>, Takahiro Ikeda<sup>a,b</sup>, Shun Yamaguchi<sup>a,b</sup>,  
Shunsuke Kawakami<sup>a</sup>, Tomoo Kitajima<sup>a</sup>, Yusuke Inoue<sup>b</sup>, Kengo Kanetaka<sup>b</sup>, Toru Iwata<sup>a</sup>,  
Susumu Eguchi<sup>b</sup>

<sup>a</sup> Department of Surgery, Nagasaki Rosai Hospital, Japan

<sup>b</sup> Department of Surgery, Nagasaki University Graduate School of Biomedical Sciences, Japan

## ARTICLE INFO

## Keywords:

Compressed air  
colon perforation  
Barotrauma

## ABSTRACT

**Introduction and importance:** Compressed air is used to apply paint, wash vehicles or machines, and remove water droplets after washing the precision instrument. Barotrauma due to high-pressure compressed air is extremely rare.

**Case presentation:** We report a case of transverse colon perforation caused by a compressed air gun in a 20-year-old male. He used a compressed air machine to dust after work, and a coworker inserted compressed air transanally as a joke. Although he returned home once, he consulted a former hospital with worsening abdominal pain. Radiography and computed tomography (CT) revealed a massive amount of free air. The patient was admitted to our hospital. The patient underwent emergency surgery. Transverse colon perforation with extensive serosal tears and massive air bubbles inside the omental bursa were observed. Double-barrel colostomy using transverse colon perforation point for decompression and diverting the stoma at the ileum end was performed with serosal tear repair and abdominal cleaning drainage. Four months after the surgery, the patient underwent colostomy and diverting stoma closure.

**Clinical discussion:** The management of colon injury due to compressed air has two aspects: tension pneumoperitoneum and colon injury. The initial management of tension pneumoperitoneum is converted to open pneumoperitoneum and early emergency operation for colon injury is recommended as soon as full-thickness perforation is diagnosed.

**Conclusion:** Transanal high-pressure compressed air can cause lethal situations, and we encountered a similar case that required surgical intervention.

### 1. Introduction

Barotrauma due to high-pressure compressed air is extremely rare [1]. Most studies have reported that colon perforation due to compressed air occurs in the rectosigmoid junction, sigmoid colon, and sigmoid descending junction [2–4], and there have been few studies on perforation distal to the sigmoid rectum. In general, it is easy to diagnose colonic perforation because severe abdominal distension, pain, and peritoneal signs, such as abdominal rigidity, tenderness, and rebound tenderness, are recognized after exposure to compressed air [5,6], in which massive free air has been observed in several images [7]. Surgical operations for colonic barotrauma include rectal tube decompression,

intraoperative decompression of the bowel in the presence of a distended bowel, resection of severely injured segments of the colon, repair of perforation with proximal diverting colostomy or enterostomy, and drainage and irrigation of the contaminated abdominal cavity [2,8,9].

We report a rare case of transverse colon perforation with an extensive colon serosal tear presenting with tension pneumoperitoneum and salvageable colon perforation.

This work has been reported in line with the SCARE 2020 criteria [10].

\* Corresponding author at: Department of Surgery, Nagasaki Rosai Hospital, 2-12-5 Setogoshi, Sasebo, 857-0134, Nagasaki, Japan.

E-mail address: [pay-it-forward.197675@hotmail.co.jp](mailto:pay-it-forward.197675@hotmail.co.jp) (T. Tanaka).

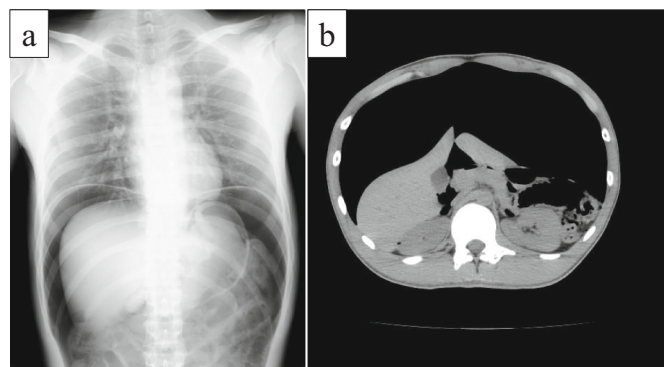
<sup>1</sup> Department of Surgery, Nagasaki University Graduate School of Biomedical Sciences 1-7-1 Sakamoto, Nagasaki, Nagasaki, Japan, 852-8501.

## 2. Case presentation

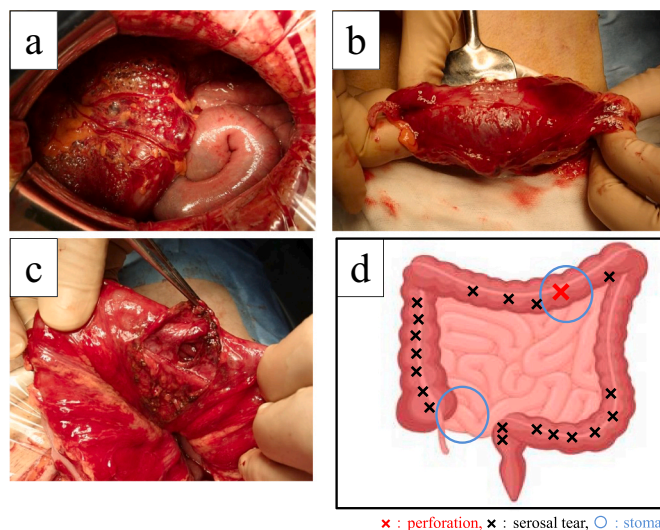
A 20-year-old male used a high-pressure compressed air machine to dust after working with his coworkers. The coworker started to play a prank, attached the compressed air to the patient's anus, and inserted the high-pressure compressed air transanally as a joke. Although he returned home once, he experienced gradual abdominal pain and consulted a former hospital. He underwent radiography and computed tomography (CT), which showed massive free air (Fig. 1a and b), and was diagnosed with perforation. The patient was admitted to our hospital. When he arrived at our hospital, he was in a clouded state of consciousness and pre-shock state. On general examination, he was in a state of respiratory distress and pallor, tachycardia (126/min) with tachypnea (49/min), and a blood pressure of 136/98 mmHg. The Glasgow Coma Scale score was E3 V3 M5. Abdominal examination findings were consistent with perforation peritonitis (distended abdomen, abdominal tenderness, and rigidity). Laboratory tests revealed a white blood cell count of 17,320 cells/mL, CK level of 741 IU/L, LDH level of 271 IU/L, and pH level of 7.253. He was diagnosed with perforation and acidosis, and emergency surgery was performed. On operative findings, the degree of contamination was mild with little dirty ascites and a massive air bubble inside the omental burs (Fig. 2a). Transverse colon perforation with extensive colon serosal tear (Fig. 2b and c) was observed. A schema of the operative findings is shown in Fig. 2d. He underwent double-barrel colostomy using a transverse colon perforation point for decompression and diverting the stoma at the ileum end (Fig. 3a) with serosal tear repair and abdominal cleaning drainage. Postoperative multidisciplinary treatment may have saved the patient's life. Finally, approximately 4 months after the initial surgery, the patient underwent colostomy and diverting stoma closure (Fig. 3b).

## 3. Discussion

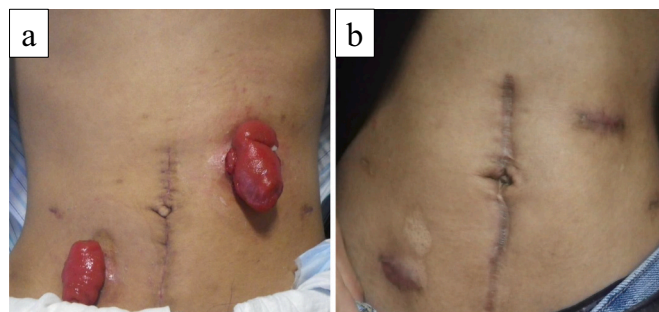
Barotrauma is the physical damage to body tissues caused by a difference in pressure between the gas space inside or in contact with the body and the surrounding gas or fluid. Colonic barotrauma following colonoscopy has been reported, with an incidence of 4 in 10,000 procedures [11–13]. However, colonic barotrauma caused by high-pressure air compressors is rare. Colorectal perforation due to high-pressure compressed air occurs as a result of triggering a high-pressure compressed air jet against the anus or the practice of dusting clothes with compressed air [1]. In general, a normal colon can withstand high intraluminal pressures before rupture occurs. As the pressure increases progressively, the serosal layer is the first to tear, followed by the muscle and the mucosa. Andrews conducted experiments with the intestines of dogs and showed that perforation occurred at a pressure of 0.49–0.88 kg/cm [2,14]. Burt also showed that the average pressure required for complete perforation of the human gastrointestinal tract is 0.29 kg/cm



**Fig. 1.** Preoperative image findings  
a: Radiography revealed massive free air in the abdominal cavity. b: CT revealed massive free air and distention of the colon.



**Fig. 2.** Intraoperative findings and schema  
a: A massive air bubble was observed inside the omental bursa. b: Perforation observed in the transverse colon. c: Multiple extensive longitudinal colon serosal tears are observed throughout the colon. d: Schema showing the perforation, serosal tear, and stoma point.



**Fig. 3.** Physical findings after first and second operation  
a: In the initial operation, the patient underwent double-barrel colostomy using a transverse colon perforation point for decompression and diverting the stoma at the ileum end. b: In the second surgery, the patient underwent colostomy and diverting stoma closure.

[2,15]. In this case, the pressure was 0.7 MPa (7.14 kg/cm<sup>2</sup>), and the value was extremely above 0.29 kg/cm<sup>2</sup>.

Most reported colon injuries due to compressed air occur in the rectosigmoid junction, sigmoid colon, and sigmoid descending junction [2–4], and perforations distal to the rectosigmoid junction have seldom been reported. This may be because the rectum and anus are well supported by pelvic structures and bilateral fixity of the rectosigmoid junction. Thus, injury resulting from high-pressure barotrauma depends on air pressure, airflow velocity, anal resting pressure, and distance between the source and anus [16]. In addition, Sy et al. discussed that during rapid air distention, the inability to produce a total obstruction by the bending of sigmoid and high pressure allows the flow of air proximally to the next anatomical bending, such as splenic flexure and hepatic flexure and ileocaecal valve, resulting in a stepwise closed loop obstruction, causing the other site of the bowel to be injured and perforated, and the comparison of different section of the colon shows that the rectum supports the greatest pressure and the sigmoid, transverse colon, caecum in decreasing strength [3]. While sigmoid colon perforation has been reported in the majority of cases, this case was a rare transverse colon perforation with an extensive colon serosal tear.

Severe abdominal distension, pain, and peritoneal signs, such as abdominal rigidity, tenderness, and rebound tenderness, are recognized

as critical symptoms [5,6] Peritonitis can be easily diagnosed because patients typically complain of abdominal pain and distension after exposure to compressed air. In addition, radiological examinations can reveal a distended colon or large amount of free air in the peritoneal cavity [7]. The patient in our case also visited a former hospital with complaints of abdominal tenderness and distention, and radiography and CT revealed massive free air in the peritoneal cavity. Although the patient exhibited pallor and tachypnea (respiratory rate 49/min), his other vital signs were stable. Therefore, emergency surgery was performed as soon as possible.

The management of colon injury due to compressed air has two aspects: tension pneumoperitoneum and colon injury [17]. Regarding tension pneumoperitoneum, a sudden influx of compressed air may rarely lead to tension pneumoperitoneum. The difference between simple pneumoperitoneum and tension pneumoperitoneum is whether extreme tension in the abdominal space is present, which would cause lethal hemodynamic and respiratory disorder [18,19]. The initial management of tension pneumoperitoneum is converted to open pneumoperitoneum. Therefore, puncturing the abdominal wall with a needle is a simple and useful method to relieve the tension within the pneumoperitoneum and respiratory distress, which should be performed as quickly as possible [1,2,17]. In this case, although respiratory distress was present, the other vital signs were stable. In addition, the perforation was obvious on radiography and CT; therefore, it was deemed safe to treat the patient in the operating room without puncture. Regarding colon injury, early emergency operation is recommended as soon as full-thickness perforation is diagnosed [1,5]. Surgical operations for colonic barotrauma include rectal tube decompression, intraoperative decompression of the bowel in the presence of a distended bowel, resection of severely injured segments of the colon, repair of perforation with proximal diverting colostomy or enterostomy, and drainage and irrigation of the contaminated abdominal cavity [2,8,9]. In this case, the patient underwent double-barrel colostomy using a transverse colon perforation point for decompression and diverting the stoma at the ileum end with serosal tear repair and abdominal cleaning drainage. Finally, the patient was salvageable, and closure of both stoma was possible.

In conclusion, although colonic barotrauma due to high-pressure compressed air may occur as a complication of recreational or improper use, it could lead to a lethal situation. Therefore, knowing the risks of a machine and its safe use are very important. Furthermore, if such cases occur, it is important to treat them according to the surgical strategy for the treatment of colonic barotrauma.

#### Sources of funding

We have no sponsors.

#### Ethical approval

This study has been exempted by our institution.

#### Consent

Written informed consent was obtained from the patient for publication of this case report and any accompanying images. A copy of the written consent is available for review by the Editor-in-Chief of this journal on request.

#### Registration of research studies

This paper is case report. The authors don't need to register this work.

#### Guarantor

Takayuki Tanaka

#### Provenance and peer review

Not commissioned, externally peer-reviewed.

#### CRediT authorship contribution statement

TT: study design, data collection, data analysis, writing.

SI: critical revision

TI: data collection

SY: data collection

SK: data collection

TK: data collection

YI: data collection

KK: critical revision

TI: critical revision and data collection

SE: final approval of the article

#### Declaration of competing interest

There are no conflicts of interest.

#### References

- [1] R.K. Brown, J.H. Dwinelle, Rupture of the colon by compressed air: report of three cases, *Ann. Surg.* 115 (1942) 13–20.
- [2] R.G. Zunzunegui, A.M. Werner, T.C. Gamblin, J.L. Stephens, D.W. Ashley, Colorectal blowout from compressed air: case report, *J. Trauma* 52 (2002) 793–795.
- [3] E.D. Sy, Y.I. Chiu, Y.S. Shan, R.L. Ong, Pneumatic colon injury following high pressure blow gun dust cleaner spray to the perineum, *Int. J. Surg. Case Rep.* 6C (2015) 218–221.
- [4] W.B. Yin, J.L. Hu, Y. Gao, X.X. Zhang, M.S. Zhang, G.W. Liu, et al., Rupture of sigmoid colon caused by compressed air, *World J. Gastroenterol.* 22 (2016) 3062–3065.
- [5] H.H. Suh, Y.J. Kim, S.K. Kim, Colorectal injury by compressed air—a report of 2 cases, *J. Korean Med. Sci.* 11 (1996) 179–182.
- [6] J.C. Coffey, D.C. Winter, S. Sookhai, S.P. Cusack, W.O. Kirwan, Non-iatrogenic perforation of the colon due to acute barotrauma, *Int. J. Color. Dis.* 22 (2007) 561–562.
- [7] Y.J. Park, Rectal perforation by compressed air, *Ann. Surg. Treat. Res.* 93 (2017) 61–63.
- [8] J.Y. Choi, K.S. Park, T.W. Park, W.J. Koh, H.M. Kim, Colon barotrauma caused by compressed air, *Intest. Res.* 11 (2013) 213–216.
- [9] A. Aparicio, M.C. Chamberlain, Neoplastic meningitis, *Curr. Neurol. Neurosci. Rep.* 2 (2002) 225–235.
- [10] T. Franchi R.A. Agha C. Sohrabi, Guideline: updating consensus surgical CAse REport (SCARE) guidelines int, *J. Surg.* 84 (2020) (2020) 226–230.
- [11] J.S. Lin, M.A. Piper, L.A. Perdue, C.M. Rutter, E.M. Webber, E. O'Connor, et al., Screening for colorectal cancer: updated evidence report and systematic review for the US preventive services task force, *JAMA* 315 (2016) 2576–2594.
- [12] S.Y. Kim, H.S. Kim, H.J. Park, Adverse events related to colonoscopy: global trends and future challenges, *World J. Gastroenterol.* 25 (2019) 190–204.
- [13] T.H. Lüning, M.E. Keemers-Gels, W.B. Barendregt, A.C. Tan, C. Rosman, Colonoscopic perforations: a review of 30,366 patients, *Surg. Endosc.* 21 (2007) 994–997.
- [14] E.W. Andrews, Pneumatic rupture of the intestine, or new type of industrial accident, *Surg. Gynecol. Obstet.* 12 (1911) 63–64.
- [15] C.A.V. Burt, Pneumatic rupture of the intestinal canal, *Arch. Surg.* 22 (1931) 875–902.
- [16] L. Bains, A. Gupta, R. Kori, V. Kumar, D. Kaur, Transanal high pressure barotrauma causing colorectal injuries: a case series, *J. Med. Case Rep.* 13 (2019) 133.
- [17] S.J. Kim, S.I. Ahn, K.C. Hong, J.S. Kim, S.H. Shin, Z.H. Woo, Pneumatic colonic rupture accompanied by tension pneumoperitoneum, *Yonsei Med. J.* 41 (2001) 533–535.
- [18] M. Thatte, S.V. Taralekar, K. Raghuvanshi, Colonic barotrauma with tension pneumoperitoneum—review of literature and report of a successfully treated case, *Int. J. Sci. Res. (Ahmedabad)* 3 (2014) 339–341.
- [19] M. Weber, F. Kolbus, J. Dressler, R. Lessig, Survived ileocaecal blowout from compressed air, *Int. J. Legal Med.* 125 (2011) 283–287.