

# Contribution of Hyperbaric Oxygen Therapy in the Management of Gas Gangrene, Necrotizing Fasciitis and Suppuration of the Limbs

Mehdi Abakka<sup>1\*</sup>, MJ Mekkaoui<sup>1</sup>, M. Bouffetal<sup>1</sup>, RA Bassir<sup>1</sup>, M. Kharmaze<sup>1</sup>, MO Lamrani<sup>1</sup>, MS Berrada<sup>1</sup>

<sup>1</sup>Department of Orthopedic and Traumatological Surgery, Hospital University Center Ibn Sina of Rabat, Morocco

DOI: [10.36347/sasjs.2023.v09i04.025](https://doi.org/10.36347/sasjs.2023.v09i04.025)

| Received: 18.03.2023 | Accepted: 23.04.2023 | Published: 28.04.2023

\*Corresponding author: Mehdi Abakka

Department of Orthopedic and Traumatological Surgery, Hospital University Center Ibn Sina of Rabat, Morocco

## Abstract

## Original Research Article

Hyperbaric oxygen therapy (HBOT) is defined as a method of administering inhaled oxygen (O<sub>2</sub>) for therapeutic purposes under a pressure greater than atmospheric pressure. The therapeutic benefits of HBO result, on the one hand, from the physical effects linked to the increase in barometric pressure and the partial pressure of O<sub>2</sub> in the tissues and, on the other hand, from the biological effects linked to the production reactive species of O<sub>2</sub> and nitrogen. These are likely to interact with many molecular processes responsible for the main anti-ischemic, pro-healing and anti-infective effects. Its indications are regularly evaluated within the framework of international consensus conferences. The references in terms of indications for HBO are, on the one hand, the North American consensus of the Undersea and Hyperbaric Medical Society (UHMS) and, on the other hand, the European consensus of the European Committee of Hyperbaric Medicine (ECHM). HBOT is applied through an hyperbaric chamber. It is a complex technique, which requires a strong human and material investment. It includes some contreindications to respect and well-identified risks to take into account.

**Keywords:** Hyperbaric, Anaerobes, Gangrene, Fasciitis.

**Copyright © 2023 The Author(s):** This is an open-access article distributed under the terms of the Creative Commons Attribution 4.0 International License (CC BY-NC 4.0) which permits unrestricted use, distribution, and reproduction in any medium for non-commercial use provided the original author and source are credited.

## INTRODUCTION

Necrotizing fasciitis and gas gangrene are severe, often life-threatening bacterial infections [1]. Two characteristics explain the use of hyperbaric oxygen therapy: the polymorphic nature of the causal microbial flora where anaerobic, strict or aerotolerant germs predominate [2], as well as the necrotizing nature linked to disseminated and extensive microvascular obstruction within the infectious focus [3]. The association of HBO with antibiotic and surgical treatment is based on strong pathophysiological arguments and evidence from experimental models that have demonstrated their beneficial contribution [3, 4].

In this work, we will report the spectacular results of the treatment of these infectious pathologies via the use of the hyperbaric chamber on a series of 8 patients hospitalized in the orthopedic and traumatological surgery department of the CHU Ibn Sina in Rabat during 2022 [5].

## MATERIEL AND METHODS

Our study is a retrospective study on a series of 8 patients, all male, with an average age of 39 years, hospitalized in the traumatology-orthopedics

department of CHU Ibn Sina in Rabat for necrotizing fasciitis and gas gangrene [6, 7] and who received comprehensive care involving surgery, appropriate medical treatment and supplementation via hyperbaric oxygen therapy, which was of considerable benefit [8].

## RESULTS

Our patients were all male with an average age of 39 years, hospitalized in the service for an average period of 35 days and who received appropriate care throughout their stay. Three were hospitalized for gas gangrene and five for necrotizing fasciitis [9, 10]. The early and long-term care was very beneficial. The contribution of the hyperbaric chamber from which they benefited at the Mohammed V Military Hospital with an average number of 15 sessions on average (one session per day), associated with medical and surgical treatment has made it possible to obtain impressive results [11, 12], in particular for two patients who were going to be disarticulated from the lower limb and who recovered completely afterwards [13, 14]. As for patients who presented with necrotizing fasciitis of the thigh or leg, they were able to subsequently benefit from a skin graft, thus allowing complete healing [12].

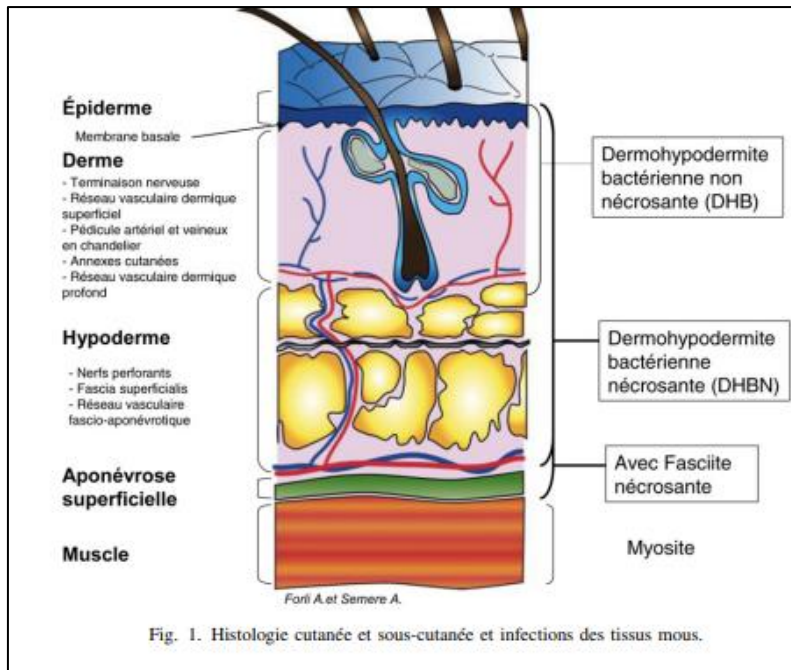


Fig. 1: Cutaneous and subcutaneous histology and soft tissue infections

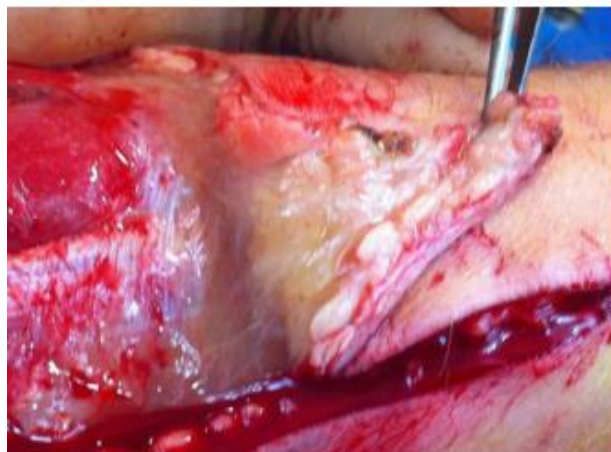

Fig. 2: Superficial aponeurosis aspect during excision, the muscle is healthy

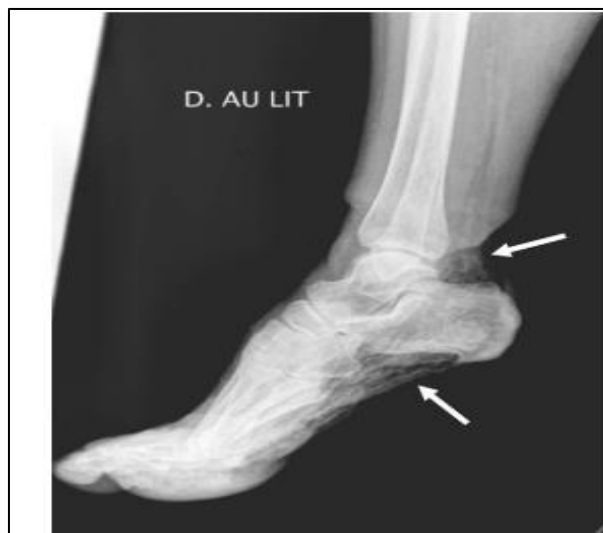
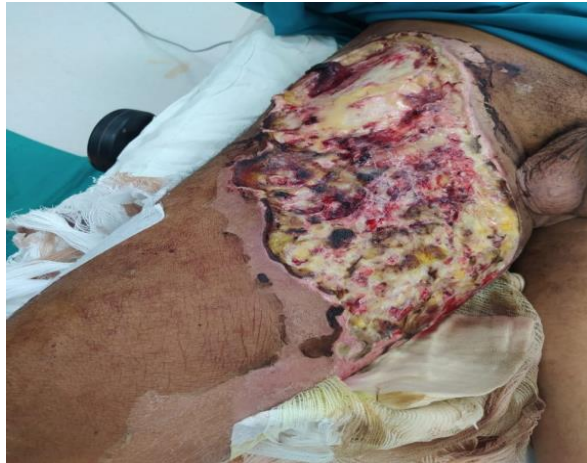
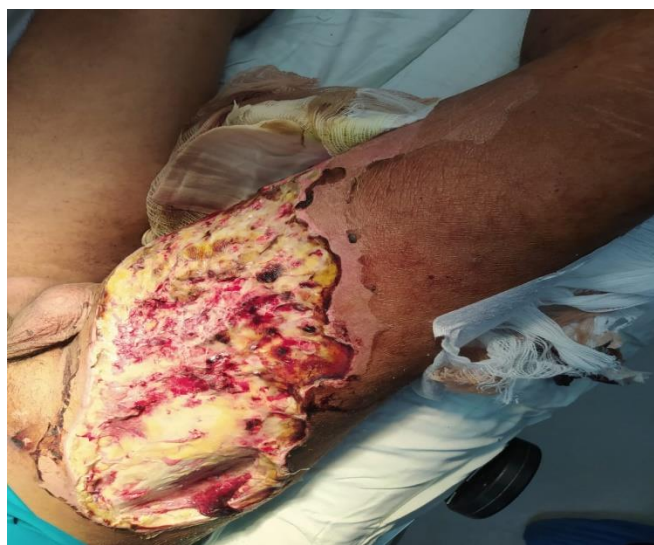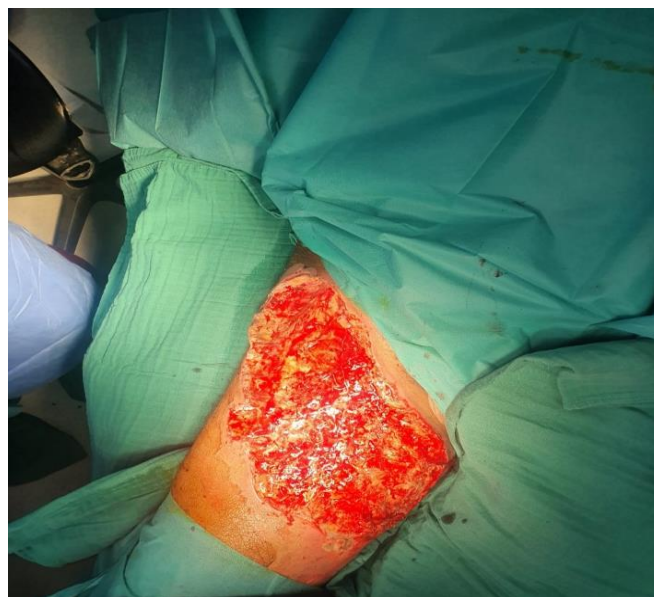Fig. 3: Standard X-ray of a right foot showing the presence of gas



**Fig. 4:** Necrotizing fasciitis of the antero-medial portion of the thigh

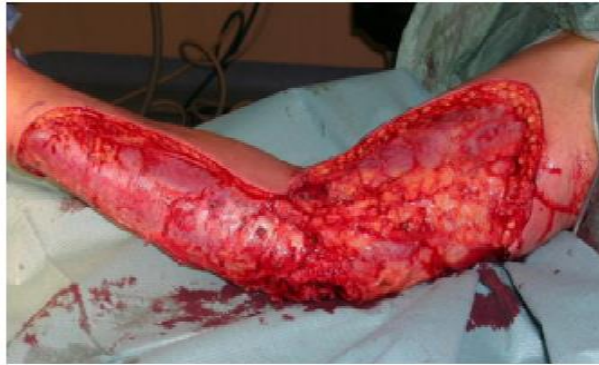

**Fig. 5:** Necrotizing fasciitis of the antero-medial portion of the thigh

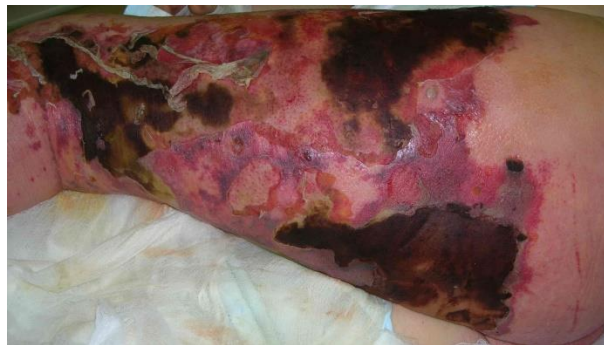

**Fig. 6:** Necrotizing fasciitis of the antero-medial portion of the thigh after debridement





**Fig. 7: Necrotizing bacterial dermo-hypodermatitis (DHBN) of the limb upper right: surgical excision**



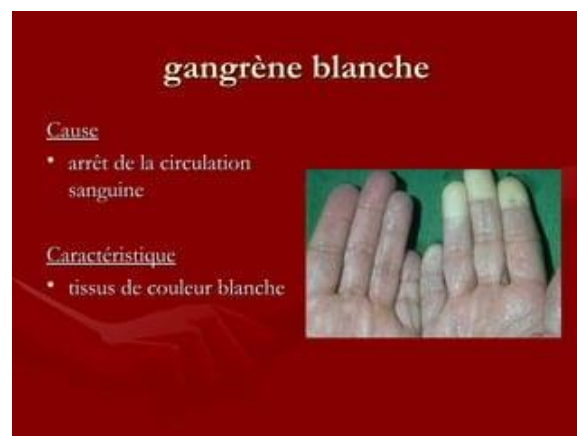**Fig. 8: Necrotic patches of the thigh**

## DISCUSSION

Gangrene is tissue necrosis. It is caused by arterial obstruction by embolism, shock or infection. Its origin is most often linked to the prolonged interruption or extreme slowing down of the blood supply. In the absence of oxygen supply, the tissues die, and then putrefy [11, 12]. There are many types of gangrene [8], including dry gangrene, which occurs because of obstruction or sclerosis of one or more blood vessels,

usually arteritis, embolism or thrombosis. It is characterized by the appearance of dark colored tissue, usually black and dried out [8, 9].

White or milky gangrene occurs following a momentary or lasting stoppage of blood circulation. It is characterized by the appearance of tissues of white color.



Wet gangrene usually occurs over dry gangrene or after a bacterial infection. It is characterized by swelling and decomposition of tissues accompanied by oozing and increasingly abundant putrefaction.

Gas gangrene is characterized by microbial infection with anaerobic germs, and production of gas

within the infected tissue. This occurs after soiling of the wounds with soil, instruments or dirty hands. This results in a crackling sensation, sometimes noticeable when palpating the affected areas. These infections are frequent on war wounds. They remain severe despite antibiotics and the use of hyperbaric oxygen therapy [3].

Gangrene develops rapidly. An onset of gangrene can be stopped and we can hope for a more or less complete repair of the tissues, with a progressive elimination of the destroyed tissues. Antibiotics alone are usually not enough to cure [4].

There are three main principles to stop it:

First, taking antibiotics (+++) slows down the infection.

Then, the intervention of a surgeon who will remove the infected or dead tissue, to stop the spread; this step is also very important and generally avoids amputation [9].

Finally, with hyperbaric oxygen therapy, the patient is placed in a box, a sealed metal tank filled with high-pressure oxygen [6, 14]. The pressure forces oxygen into the tissues to stop the spread of bacteria. Today, antibiotics and surgery are most often used and are the most effective. Currently, 80% of victims with gangrene survive [15].

## CONCLUSION

The use of HBO in the treatment of necrotizing fasciitis is based on pathophysiological arguments and evidence from experimental models. A bundle of arguments favors its use in the most severe cases. In this case, HBO should be seen as a treatment associated with antibiotic and surgical treatment [13]. If the decision to resort to HBO is taken, it must be done while being integrated into the complete therapeutic protocol and without its use running any additional risk to the patient, i.e. in a hyperbaric center equipped and trained to caring for critically ill patients [2].

## REFERENCES

- Oxygénothérapie hyperbare. Rapport de la Haute Autorité de Santé du 31 janvier 2007 (106 pages).
- Delafosse, B., & Motin, J. (1996). Oxygène hyperbare. In: Conférences d'actualisation de la société française d'anesthésie réanimation. Eds Elsevier Paris; 669-87.
- Clair, B. (2009). Infection des parties molles. In : Réanimation médical. Collège National des Enseignants de Réanimation Médicale. Eds Elsevier Masson. Paris: 1058-63.
- Mehta, S., McGeer, A., Low, D. E., Hallett, D., Bowman, D. J., Grossman, S. L., & Stewart, T. E. (2006). Morbidity and mortality of patients with invasive group A streptococcal infections admitted to the ICU. *Chest*, 130(6), 1679-1686.
- Simonsen, S. E., Van Orman, E. R., Hatch, B. E., Jones, S. S., Gren, L. H., Hegmann, K. T., & Lyon, J. L. (2006). Cellulitis incidence in a defined population. *Epidemiology & Infection*, 134(2), 293-299.
- Avril, M. F., & Peyramond, D. (2000). Erysipèle et Fasciite nécrosante : prise en charge. Conférence de consensus de la Société Française de Dermatologie et de la Société de Pathologie Infectieuse de Langue Française. *Med Mal Infect*, 30, 245-6.
- Vincenti-Rouquette, I., Borne, M., Barges, L., & Brinquin, L. (1999). Oxygénothérapie hyperbare en 1999. Principes, indications et limites. *Médecine et armées*, 27, 347-53.
- Borne, M., Vincenti-Rouquette, I., Saby, C., Raynaud, L., & Brinquin, L. (2009). Oxygénothérapie hyperbare. Principes et indications. EMC (Elsevier Masson SAS, Paris), Anesthésie- Réanimation, 36-940-A-10.
- Hodges, A. N. H., Delaney, J. S., Lecomte, J. M., Lacroix, V. J., & Montgomery, D. L. (2003). Effect of hyperbaric oxygen on oxygen uptake and measurements in the blood and tissues in a normobaric environment. *British Journal of Sports Medicine*, 37(6), 516-520.
- Mathieu, D. (2002). Effet de l'oxygénothérapie hyperbare sur le transport de l'oxygène et l'oxygénation tissulaire. In : Traité de Médecine Hyperbare. F Wattel, D Mathieu. Eds ellipses, Lonrai, 50-62.
- Boerema, I., Meyne, N. G., Brummelkamp, W. H., Bouma, S., Mensch, M. H., Kamermans, F., Stern Hanf, M., & van Aalderen. (1960). Life without blood. *Ned Tijdschr Geneesk*, 104, 949-54.
- Mathieu, D., & Wattel, F. (2002). Effets hémodynamiques et microcirculatoires de l'oxygénothérapie hyperbare. In : Traité de Médecine Hyperbare. F Wattel, D Mathieu. Eds ellipses, Lonrai, 64-99.
- Gottrup, F. (2004). Oxygen in wound healing and infection. *World J Surg*, 28, 312-5.
- Bocquet, J., & Bollaert, P. E. (2002). Cicatrisation et oxygénothérapie hyperbare. In : Traité de Médecine Hyperbare. F Wattel, D Mathieu. Eds ellipses, Lonrai.
- Tempe, J. D., Wattel, F., Monteil, H., Borg, J., Schneider, F., Lutun, P., & Bilbault, P. (2002). Effet de l'élévation de la pression partielle d'oxygène sur les bactéries, sur les moyens de défense contre l'infection et la potentialisation de l'action des antibiotiques. Traité de Médecine Hyperbare. F Wattel, D Mathieu. Eds ellipses, Lonrai.