



Hyperbaric oxygen therapy for patients with hypertension after microsurgery of total avulsion of auricle: a case report

Chunqin Liu¹, Mingyi Qin², Xiaojuan Hou³, Yu Li⁴, Zongze He⁵

¹Department of General Medical Subjects, The Fourth Hospital of Hebei Medical University, Shijiazhuang, China; ²Department of Nursing, The Fourth Hospital of Hebei Medical University, Shijiazhuang, China; ³Department of Endocrinology, The Fourth Hospital of Hebei Medical University, Shijiazhuang, China; ⁴Department of Emergency, The Fourth Hospital of Hebei Medical University, Shijiazhuang, China; ⁵Department of Emergency, The Fourth Hospital of Hebei Medical University, Shijiazhuang, China

Contributions: (I) Conception and design: C Liu; (II) Administrative support: M Qin; (III) Provision of study materials or patients: X Hou; (IV) Collection and assembly of data: Y Li; (V) Data analysis and interpretation: Z He; (VI) Manuscript writing: All authors; (VII) Final approval of manuscript: All authors.

Correspondence to: Mingyi Qin. Department of Nursing, The Fourth Hospital of Hebei Medical University, Shijiazhuang 050011, China. Email: qinmingyi120@sina.com.

Background: Total ear avulsion is one of the most serious auricular traumas. Its surgical procedure is complicated and involves high technical difficulty. The auricular blood vessels mostly contain capillaries, and capillary anastomosis reconstruction is difficult. Right ear vascular anastomosis and auricle replantation under microscope are very few cases of successful replantation of total ear avulsion. The lack of blood supply in the amputated ear leads to postoperative blood supply disturbance. At present, there are no reports on the application of hyperbaric oxygen therapy following the replantation of severed ears. Hyperbaric oxygen therapy was used to promote the recovery of vascular microcirculation, reduce complications and improve the survival rate of postoperative ear transplantation.

Case Description: We present a rare case of total ear avulsion in a 53-year-old Chinese man. The patient complained of cutting injury of the right auricle for more than 1 hour. The patient had a history of hypertension for 4 years, and his blood pressure was well controlled by regular administration of valsartan. This paper reports on the treatment experience in a case of microscope-assisted auricular replantation, targeted postoperative treatment, early intervention with hyperbaric oxygen therapy, and individualized nursing care. After 16 days of careful treatment, the patient's avulsion ear survived and he was discharged from the hospital. After 6 months of continuous follow-up, the auricular shape and hearing of the patient reached the ideal standard.

Conclusions: Precise medical and nursing cooperation coupled with meticulous management of the patient throughout the entire process are key factors for the survival of the severed ear. The combined application of microscopic techniques and hyperbaric oxygen therapy improves blood circulation to the anastomosed vessels, accelerates the healing of the replanted ear, and shortens the length of hospital stay. Early hyperbaric oxygen treatment can make postoperative wound heal quickly. Early intervention of hyperbaric oxygen therapy after ear avulsion is helpful to the recovery of patients with ear avulsion. However, the initiation time and duration of intervention need to be further optimized and more evidence is needed to support it.

Keywords: Replant ear avulsion; hyperbaric oxygen; total ear disconnect injury; case report

Submitted Nov 15, 2022. Accepted for publication Jan 10, 2023. Published online Jan 31, 2023.

doi: 10.21037/atm-22-6441

View this article at: <https://dx.doi.org/10.21037/atm-22-6441>

Introduction

Total auricular avulsion is the most serious type of auricular trauma, and its surgery is complicated. At present, few cases of total ear avulsion injury have been reported, and patients with hypertension combined with total ear avulsion are rarer. However, hyperbaric oxygen therapy has not yet been applied for the recovery of ear avulsion after replantation, especially for total ear avulsions. In this paper, hyperbaric oxygen was employed for the first time in the recovery of total ear avulsion after replantation. The present report describes the case of a patient with a total auricular avulsion dissection combined with hypertension who was admitted to our department due to an emergency. This type of case has rarely been reported. Since the auricular vessels are mostly capillaries, the reconstructed anastomosis vessels are thin and the blood supply to the severed ear is insufficient. As a result, blood flow disorders can occur easily after surgery, resulting in the failure of ear replantation. Therefore, improving the vascular microcirculation in the severed ear after surgery, reducing complications, and improving the survival rate of the replanted ear are urgent issues that need to be addressed.

This paper summarizes the experience of a case in which a microscopic vascular and nerve anastomosis technique was employed for the replantation of a severed ear, coupled with early postoperative hyperbaric therapy (1) and individualized nursing care. The treatment points included

Highlight box

Key findings

- Early intervention with hyperbaric oxygen therapy allows the postoperative wound to heal as quickly as possible.

What is known and what is new?

- Studies have shown that hyperbaric oxygen therapy can effectively promote blood circulation in the brain, and also help improve the bad mood of patients after injury and reduce anxiety and depression.
- However, hyperbaric oxygen therapy has not yet been applied for the recovery of ear avulsion after replantation, especially for total ear avulsions. In this paper, hyperbaric oxygen was employed for the first time in the recovery of total ear avulsion after replantation.

What is the implication, and what should change now?

- Early intervention with hyperbaric oxygen therapy following ear avulsion surgery can aid the recovery of patients with ear avulsion. However, the starting time point and duration of intervention require further optimization and more supporting evidence.

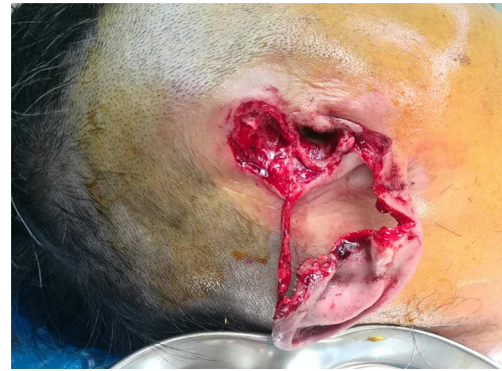

Figure 1 Before surgery.

microscope-assisted auricular replantation, targeted postoperative treatment, early intervention with hyperbaric oxygen therapy (2), and individualized nursing care. After 16 days of careful treatment, the patient was discharged from the hospital, and with continuous follow-up, the patient's ear shape and hearing reached the ideal standard. Early use of hyperbaric oxygen therapy after surgery is a unique treatment method of this case, which plays a vital role in the reconstruction of microcirculation, especially the recovery of blood circulation and survival of the severed ear, and is worth promoting. The meticulous management of the medical and nursing care ensured the success of the operation and is worthy of promotion. We present the following article in accordance with the CARE reporting checklist (available at <https://atm.amegroups.com/article/view/10.21037/atm-22-6441/rc>).

Case presentation

A 53-year-old Chinese man was admitted to the emergency department for 1 hour with a right auricular avulsion dissection injury. The patient complained of cutting injury of the right auricle for more than 1 hour. The patients underwent the following medical check-ups: The soft tissue of the right ear was completely disconnected and only the earlobe was attached (with a width of about 0.5 cm), and the segment edges were uneven and heavily contaminated (*Figure 1*). A small number of blood stains were seen in the external auditory canal of the right ear, the tympanic membrane was intact, no significant abnormalities were seen in the hearing measurements, and there was no pressure pain in the mastoid process. *Previous history*: the patient had a history of hypertension for 4 years, he used to take “valsartan” orally regularly, and his blood pressure was well

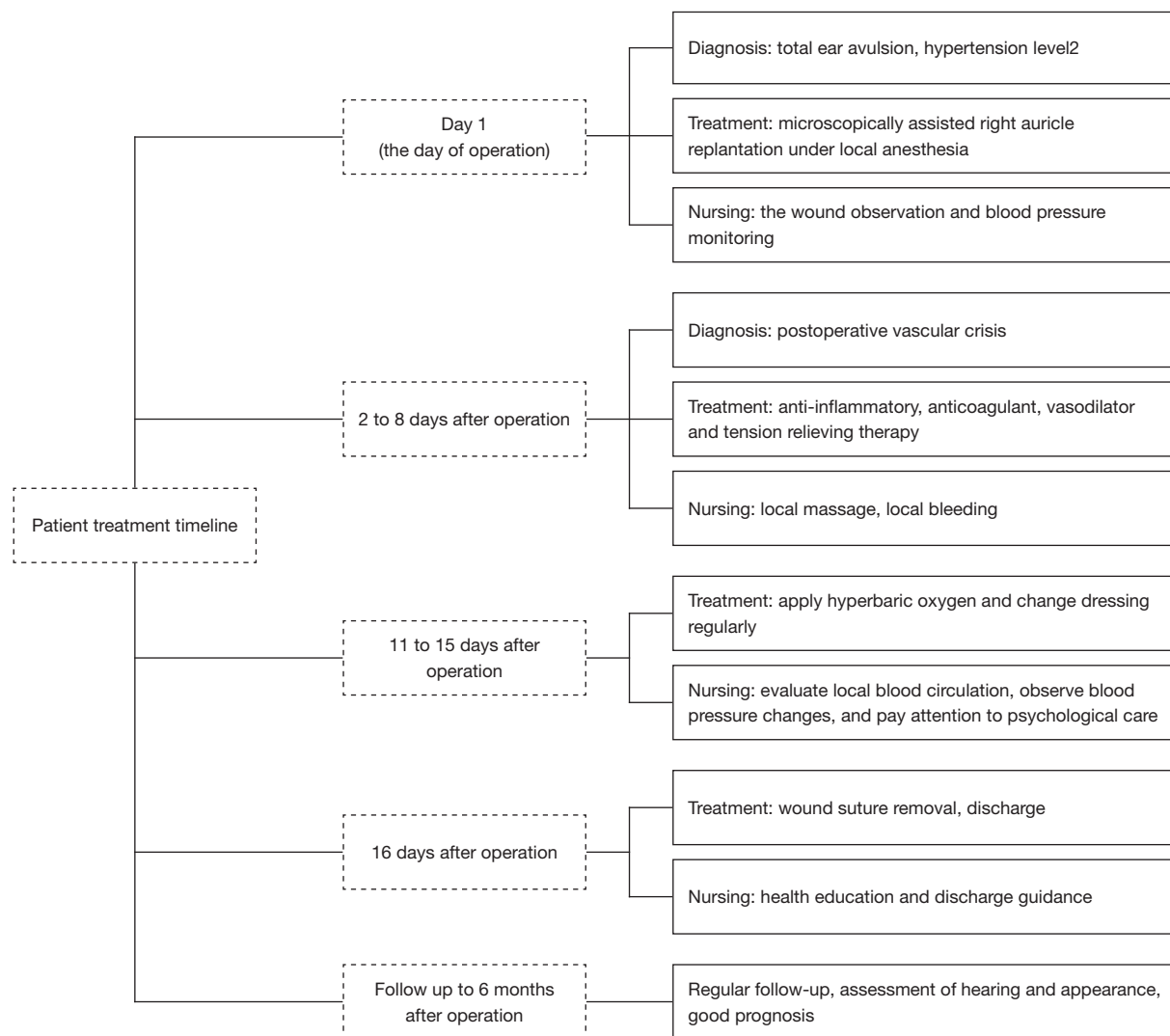


Figure 2 Timeline of interventions and outcomes

controlled. He was diagnosed with right auricular avulsion disruption and hypertension. Timeline of interventions and outcomes is in *Figure 2*.

The patients underwent microscope-assisted right auricular replantation under local anesthetic reinforcement 1 hour after admission. Firstly, the severed ear was disinfected, the necrotic tissue was removed from the cut edge, and the subcutaneous tissue and skin of the middle and lower parts of the ear were sutured in alignment. We then successfully performed microscopic anastomosis of the severed ear stump with the corresponding vessels of the isolated ear over a period of 4 hours. The auricular skin of the affected ear was red and moist, with normal capillary filling time and normal skin temperature.

On the 2nd postoperative day, the affected ear developed a venous crisis, with swelling, purple, capillary filling for more than 1 s, cool skin temperature, and high tension. The right ear was immediately bled with multiple incisions and gently massaged, and heparin saline drops were administered at the incision. Dark red blood was seen coming out of the bleeding port, the bleeding rate was 3–5 drops/5 minutes, and the skin temperature and tension were closely observed during the bleeding. To reduce local hypertension (*Figure 3*), five stitches were intermittently removed from the auricular cavity and the posterior auricular sulcus.

On the 7th day after surgery, the skin temperature and color of the replanted right ear were normal, the patient

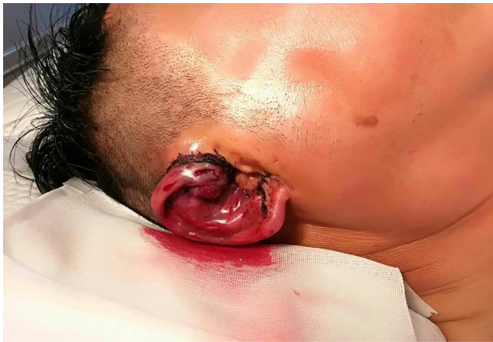

Figure 3 Day 2 postoperatively.

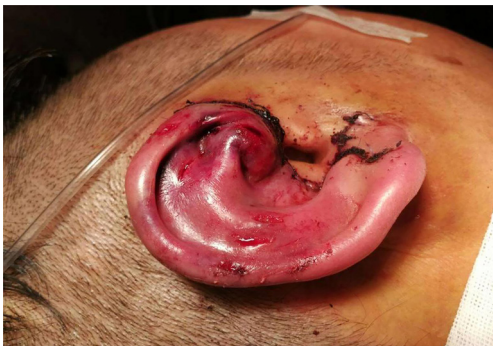

Figure 4 Day 8 after surgery.

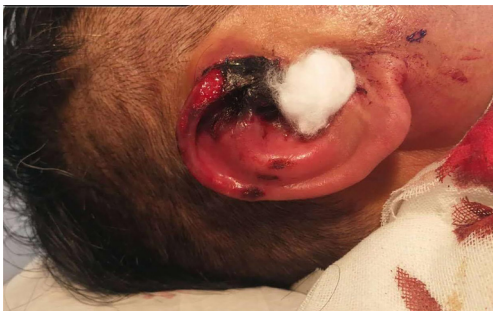

Figure 5 Day 11 after surgery.

was intermittently taken out of bed as prescribed by the doctor, and the ear was closely observed. At 6:30 a.m. on the 8th postoperative day, the patient had a dark purple color on the upper edge of the replanted right ear after sitting up to eat (*Figure 4*); these symptoms were slightly relieved after applying immediate massage and local incisional needle bleeding. At 9:00 a.m., the color of the upper edge of the ear was still purple, continuous blood-letting was performed, and 0.9% normal saline (500 mL) + sodium

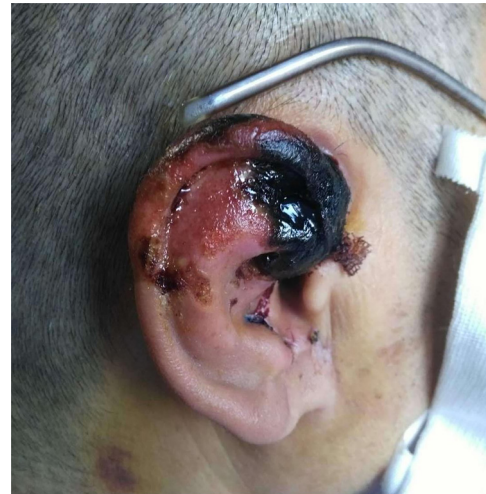

Figure 6 Day 15 after surgery.

heparin (2 mL) was administered slowly under sedation as prescribed. At 10:50 a.m., the color of the upper edge of the replanted right ear was better than before, and the sutures in the earlobe were removed on the same day.

On the 11th postoperative day (*Figure 5*), hyperbaric oxygen therapy was administered seven times consecutively, and the auricular color and skin temperature improved significantly after treatment compared to before treatment (*Figure 6*). The remaining sutures were removed 16 days after surgery, except for the vascular anastomosis. The patient's auricular skin temperature, color, and swelling improved markedly, and he was discharged from the hospital with a good postoperative recovery. Six months after the surgery, the ear was normal in shape and functioned well (*Figure 7*).

Through precise treatment and meticulous care using the measures described below, the patient recovered and was discharged from the hospital. He was placed in a single room after surgery, with an air purifier in the room, appropriate temperature and humidity, intensive care, personalized nursing care, limited visits, continuous low-flow oxygenation at 2–4 liters/min, and vital signs monitoring. Postoperatively, the patient was absolutely bedridden for 1 week, with the head of the bed elevated by 15–20° and placed in a 45° left lateral position with the head braked to promote blood flow back to the affected ear. The patient was given a high-calorie, high-vitamin, easy-to-digest, semi-liquid diet, and his bowel movements were unobstructed and avoided straining. He was also intermittently massaged, given bilateral lower extremity circulation drive-pump therapy

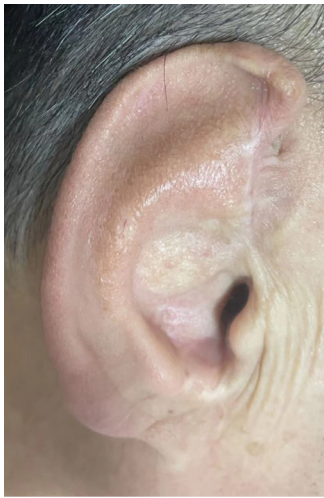

Figure 7 6 months after surgery.

twice a day, and instructed to perform ankle pump exercises to prevent the formation of thrombosis. Postoperatively, low molecular heparin calcium injection (4,100 iu) was administered subcutaneously twice daily, and after 7 days, it was changed to once daily for 6 days. After another 5 days, it was changed to once/8 h, and after a further 3 days, it was changed to once/12 h for 6 days.

For postoperative observation and management of blood flow, a sterile blade incision and intermittent bleeding with needle puncture were performed on the replanted ear as prescribed by the doctor, and manual gentle massage was administered to promote venous blood flow reconstruction in the severed tissue. The nurse was responsible for bleeding the bruised area every 10–15 min by needle prick or blade incision with a sterile needle, and heparin sodium saline drip (saline 20 mL + heparin sodium 5,000 iu) 3–4 drops/time at the needle prick or incision. The right auricular incision was wiped with heparin cotton balls once every 30 min or with heparin saline based on the blood flow from the incision. The patient was instructed not to blow his nose for 1 week after surgery.

Subsequently, a 0.9% NS (250 mL) + Ceftriaxone sodium tazobactam sodium injection (2 g) was administered intravenously twice daily for 15 days to prevent the occurrence of septic chondromalacia in the replanted auricle (3,4). The period from 7 to 10 days after surgery is the high incidence of infection, and alcohol cotton balls were given to promptly wipe the right auricular anastomosis after surgery to remove blood clots. The patient was also given antispasmodic, nerve-nourishing, and vasodilating drugs.

Also, the regular application of antihypertensive drugs and close monitoring of blood pressure changes prevented the occurrence of a vascular crisis in the affected ear due to blood pressure changes.

After evaluating the patient's condition, we administered the hyperbaric oxygen therapy as soon as possible, educated the patient on the relevant knowledge in the chamber, provided special care, and accompanied him into the single-occupancy air pressurized chamber. We then applied a pressure of 2.0 absolute atmosphere, and allowed the patient to initially inhale 100% pure oxygen for 30 minutes and then rested for 10 minutes. This process was repeated twice, and then gradually decreased to normal pressure. The patient left the chamber after 15 minutes of normal breathing in the chamber. His condition was closely observed during the hyperbaric oxygen therapy, and he did not complain of any special discomfort. Hyperbaric oxygen therapy was performed once daily, and the patient underwent hyperbaric oxygen therapy a total of seven times starting 11 days after surgery. The auricular color and skin temperature improved significantly after treatment compared to before.

We established nursing work evaluation indexes for the entire supervision period. The department integrated nursing indexes to establish a list of forms, including skin temperature, color, tension, capillary filling, bleeding time, bleeding speed, vital signs, pipelines, laboratory tests, skin condition, medication, treatment, and changes in condition. The handover was performed strictly in accordance with the content of the form item-by-item with special markings for key contents, and the positive results of the patient and changes in laboratory tests were reported and dealt with promptly through the WeChat and recorded in the nursing instruments and handover reports. All personnel in the treatment group should have an understanding of the condition and should be carried together if they require special examinations, so as to facilitate timely recording and treatment and ensure the continuity and timeliness of the treatment.

Individualized psychological care for our patient, who is a senior intellectual and was worried about the negative impact on future social life, private life, and other aspects, coupled with his anxiety and panic caused by the accident, involved the development of an individualized psychological care program: (I) we listened carefully to the patient's complaints, while giving reassurance to reduce his anxiety and encourage him to voice his concerns/doubts; (II) a competent doctor explained the relevant disease

information in detail to the patient; (III) the doctor in charge comprehensively explained the disease, operation, postoperative cooperation, and prognosis to the patient to reduce his psychological anxiety and increase his confidence in recovery; (IV) psychological counseling was requested from psychologists according to the patient's questions to prevent mood swings; (V) the purpose and process of the operation were carefully explained before each nursing operation to obtain the patient's support and cooperation; (VI) the patient's family were permitted to accompany him when his condition was stable, and their affectionate company and encouragement gave the patient more confidence. Encourage the patient to have more confidence, while at the same time allowing the family members to perform the ideological work, establish good family support, stabilize the patient's emotions, and better cooperate with postoperative treatment.

All procedures performed in this study were in accordance with the ethical standards of the institutional and/or national research committee(s) and with the Declaration of Helsinki (as revised in 2013). Written informed consent was obtained from the patient for publication of this case report and accompanying images. A copy of the written consent is available for review by the editorial office of this journal.

Discussion

Precise medical and nursing cooperation coupled with the meticulous management of patients throughout the process. The ear is mainly composed of soft tissue, with poor blood supply and few nerves, making it difficult to replant severed ears, and the incidence of complications during the postoperative recovery period is high. Therefore, it is especially important to carefully manage the entire perioperative period. Immediately after admission, a high-quality treatment and care team should be formed to accurately assess the patient's condition and develop an individualized treatment and nursing care plan. Close observation, precise treatment, nursing care, health education, and timely management of complications play a key role in the success of the patient's surgery. The meticulous management of medical and nursing care provided in this case ensured the success rate of the surgery and provided valuable experience for future treatment after similar procedures.

The combined application of microscopic techniques and hyperbaric oxygen therapy (5) improved blood circulation

to the anastomosed vessels, accelerated the healing of the replanted ear, and shortened the length of hospital stay. Moreover, the application of microscopic techniques provided a strong guarantee for the revascularization of the severed ear. Early implementation of hyperbaric oxygen therapy (6) in addition to conventional treatment after surgery in cases of stable patient condition assessment can effectively promote wound healing. Furthermore, it can also effectively improve the hypoxic condition of the patient's replanted ear, increase oxygen saturation, accelerate blood return, increase capillary permeability of the anastomosis, effectively improve capillary microcirculation of the replanted ear, increase blood oxygen concentration to improve tissue energy metabolism, improve blood flow to the replanted ear, and reduce the risk of wound infection (7). Studies have shown that hyperbaric oxygen therapy (8) can effectively promote blood circulation in the brain (9), and also help to improve patients' bad mood after injury (10), reduce their anxiety and depression, and pay attention to their psychological care, so that patients actively cooperate with treatment and achieve satisfactory results. Since there are few studies on the effectiveness of hyperbaric oxygen therapy for the replantation of severed ears, further studies should be conducted on the timing and duration of hyperbaric oxygen therapy.

Conclusions

Early intervention with hyperbaric oxygen therapy allows the postoperative wound to heal as quickly as possible. The combination of medical and nursing care can efficiently manage the dangerous postoperative situation of the severed ear. This case shows that early intervention with hyperbaric oxygen therapy combined with postoperative medical and nursing care can improve the success rate of ear replantation.

Acknowledgments

The authors thank Director Ruili Zhao for the surgery and guidance throughout the treatment.

Funding: None.

Footnote

Reporting Checklist: The authors have completed the CARE reporting checklist. Available at <https://atm.amegroups.com/article/view/10.21037/atm-22-6441/rc>

Conflicts of Interest: All authors have completed the ICMJE uniform disclosure form (available at <https://atm.amegroups.com/article/view/10.21037/atm-22-6441/coif>). The authors have no conflicts of interest to declare.

Ethical Statement: The authors are accountable for all aspects of the work in ensuring that questions related to the accuracy or integrity of any part of the work are appropriately investigated and resolved. All procedures performed in this study were in accordance with the ethical standards of the institutional and/or national research committee(s) and with the Declaration of Helsinki (as revised in 2013). Written informed consent was obtained from the patient for publication of this case report and accompanying images. A copy of the written consent is available for review by the editorial office of this journal.

Open Access Statement: This is an Open Access article distributed in accordance with the Creative Commons Attribution-NonCommercial-NoDerivs 4.0 International License (CC BY-NC-ND 4.0), which permits the non-commercial replication and distribution of the article with the strict proviso that no changes or edits are made and the original work is properly cited (including links to both the formal publication through the relevant DOI and the license). See: <https://creativecommons.org/licenses/by-nc-nd/4.0/>.

References

1. Li H, Pan S. Hyperbaric oxygen therapy in orthopaedic related disease. *Chin J Naut Med & Hyperbar Med* 2021;28:276-82.
2. Wang H, Meng M. Progress of research on the effects of hyperbaric oxygen therapy on psychosomatic symptoms such as depression, anxiety, insomnia and headache. *Chin J Naut Med & Hyperbar Med* 2021;28:534-8.
3. Zhao Y, Zhao Z, Liu F. Microanastomosis of vascularized severed ear replantation in 3 cases. *Armed Police Medicine* 2021;32:341-3.
4. Bai J, Tian D, Zhang X, et al. Total auricular dissection and replantation. *Journal of Hebei Medical University* 2018;39:354-6.
5. Jones MW, Cooper JS. Hyperbaric Therapy For Skin Grafts And Flaps. 2022 Aug 10. In: StatPearls [Internet]. Treasure Island (FL): StatPearls Publishing; 2022.
6. Sixth Medical Center of Chinese People's Liberation Army General Hospital. Consensus on "Indications and Contraindications for Hyperbaric Oxygen Therapy" of the Hyperbaric Oxygen Branch of the Chinese Medical Association (2018). *Chin J Naut Med & Hyperbar Med* 2019;26:1-5.
7. Chiang IH, Chen SG, Huang KL, et al. Adjunctive hyperbaric oxygen therapy in severe burns: Experience in Taiwan Formosa Water Park dust explosion disaster. *Burns* 2017;43:852-7.
8. Li J. Clinical application and prospect of hyperbaric oxygen. *Chinese Medical Information Herald* 2021;36:6.
9. Hatibie MJ, Islam AA, Hatta M, et al. Hyperbaric Oxygen Therapy for Second-Degree Burn Healing: An Experimental Study in Rabbits. *Adv Skin Wound Care* 2019;32:1-4.
10. Hajhosseini B, Kuehlmann BA, Bonham CA, et al. Hyperbaric Oxygen Therapy: Descriptive Review of the Technology and Current Application in Chronic Wounds. *Plast Reconstr Surg Glob Open* 2020;8:e3136.

(English Language Editor: A. Kassem)

Cite this article as: Liu C, Qin M, Hou X, Li Y, He Z. Hyperbaric oxygen therapy for patients with hypertension after microsurgery of total avulsion of auricle: a case report. *Ann Transl Med* 2023;11(2):135. doi: 10.21037/atm-22-6441