

Hyperbaric Oxygen Therapy and the Eye

F. K. BUTLER, Jr.¹, C. HAGAN², H. MURPHY-LAVOIE³

¹Navy Medical Lessons Learned Center, Naval Operational Medicine Institute, Pensacola, FL; ² Department of Ophthalmology, Naval Medical Center San Diego, San Diego, CA; ³ Section of Emergency Medicine, Louisiana State University School of Medicine, New Orleans, LA

DISCLAIMER

The opinions expressed in this paper are those of the authors and do not necessarily reflect those of the Department of the Defense or the Department of the Navy.

Butler, Jr., FK, Hagan C, Murphy-Lavoie H. Hyperbaric Oxygen Therapy and the Eye. *Undersea Hyperb Med* 2008; 35(5): 327-381. Hyperbaric oxygen therapy (HBOT) is a primary or adjunctive therapy for a variety of medical disorders including some involving the eye. This paper is the first comprehensive review of HBOT for ocular indications. The authors recommend the following as ocular indications for HBOT: decompression sickness or arterial gas embolism with visual signs or symptoms, central retinal artery occlusion, ocular and periocular gas gangrene, cerebro-rhino-orbital mucormycosis, periocular necrotizing fasciitis, carbon monoxide poisoning with visual sequelae, radiation optic neuropathy, radiation or mitomycin C-induced scleral necrosis, and periorbital reconstructive surgery. Other ocular disorders that may benefit from HBOT include selected cases of ischemic optic neuropathy, ischemic central retinal vein occlusion, branch retinal artery occlusion with central vision loss, ischemic branch retinal vein occlusion, cystoid macular edema associated with retinal venous occlusion, post-surgical inflammation, or intrinsic inflammatory disorders, periocular brown recluse spider envenomation, ocular quinine toxicity, Purtscher's retinopathy, radiation retinopathy, anterior segment ischemia, retinal detachment in sickle cell disease, refractory actinomycotic lacrimal canaliculitis, pyoderma gangrenosum of the orbit and refractory pseudomonas keratitis. Visual function should be monitored as clinically indicated before, during, and after therapy when HBOT is undertaken to treat vision loss. Visual acuity alone is not an adequate measure of visual function to monitor the efficacy of HBOT in this setting. Ocular examinations should also include automated perimetry to evaluate the central 30 degrees of visual field at appropriate intervals. Interpretation of the literature on the efficacy of HBOT in treating ocular disorders is complicated by several factors: frequent failure to include visual field examination as an outcome measure, failure to adequately address the interval from symptom onset to initiation of HBOT, and lack of evidence for optimal treatment regimens for essentially all ocular indications. Because some ocular disorders require rapid administration of HBOT to restore vision, patients with acute vision loss should be considered emergent when they present. Visual acuity should be checked immediately, including vision with pinhole correction. If the patient meets the criteria for emergent HBOT outlined in the paper, normobaric oxygen should be started at the highest inspired oxygen fraction possible until arrangements can be made for HBOT.

INTRODUCTION

The eye and the periocular tissues may benefit from hyperbaric oxygen therapy (HBOT) in certain disorders. This paper reviews the anatomy and physiology of the eye in hyperoxic conditions and HBOT as it pertains to the eye is reviewed. We consider both the ocular disorders that may benefit from HBOT as well as the adverse effects on the eye that may occur as a result of HBOT. Ocular considerations in fitness-to-dive evaluations are outlined as are ocular contraindications to HBOT. Recommendations are also made regarding the timing and scope of pre and post HBOT eye examinations.

LITERATURE SEARCH TECHNIQUE

A PubMed search using the term “hyperbaric oxygen” was performed and 9,479 citations were found as of 7 July 2007. These citations were screened for information on the eye or periocular tissues and included when appropriate.

PERTINENT ANATOMY AND PHYSIOLOGY OF THE EYE

The sensory experience we perceive as vision involves incident light passing through the cornea, the anterior chamber, the pupil, the posterior chamber, the crystalline lens, and the vitreous body before reaching the retina. The cornea provides approximately two-thirds of the refractive power required to focus light on the retina and the lens the other one-third. The anterior chamber, the posterior chamber, and the vitreous body are filled with non-compressible fluid, which means the eye is not adversely affected by changes in pressure (barotrauma) unless a gas space exists adjacent to the eye (as with a facemask) or within the eye (from surgery or trauma).

The retina is comprised of nine distinct layers, with the photoreceptor cells as the outermost and the internal limiting membrane as the innermost layers (1). Light reaching the retina stimulates the photoreceptor cells, which activates the ganglion cells. The confluence of the afferent portions of the ganglion cells (the nerve fiber layer) forms the optic disk. These cells exit the eye as the optic nerve to carry visual stimuli to the occipital cortex of the brain via the optic chiasm and the optic tract. At the middle and posterior aspects, the wall of the globe is composed of three main layers, the outermost fibrous sclera, the vascular uveal tract, and the innermost sensory retina. The uveal tract is further divided into the posterior choroid, the iris visible in the anterior portion of the eye, and the intermediate ciliary body. Vision may be adversely affected by any factor that prevents light from reaching the retina or being sharply focused in the retinal plane. Vision may also be affected by injury to the retina, the occipital cortex, or the afferent neural tissues carrying visual stimuli between these two areas.

The arterial supply to the eye is provided by the ophthalmic artery, one of the branches of cavernous portion of the internal carotid artery. Some branches of the ophthalmic artery (lacrimal, supraorbital, ethmoidals, medial palpebral, frontal, dorsal nasal) supply orbital structures, while others (central artery of the retina, short and long posterior ciliaries, anterior ciliary arteries) supply the tissues of the globe(2). The central retinal artery enters the globe within the optic nerve and serves the inner layers of the retina through its branches. There are approximately twenty short posterior ciliary arteries and usually two long posterior ciliary arteries. The posterior ciliary vessels originate from the ophthalmic artery and supply the uvea, the cilioretinal arteries, the sclera, the margin of the cornea, and the adjacent conjunctiva. The long posterior ciliary arteries

provide blood to the choroid and the outer layers of the retina. The short posterior ciliary arteries also supply the choroid. The anterior ciliary arteries also arise from the ophthalmic artery, supply the extraocular muscles, and anastomose with the posterior ciliary vessels to form the major arterial circle of the iris, which supplies the iris and ciliary body. The optic nerve receives its blood supply from various vessels as it progresses from the surface of the optic nerve head through the orbit, including branches of the central retinal artery, the posterior ciliary arteries, and branches of the ophthalmic artery. In approximately 15%-30% of individuals, a cilioretinal artery is present. This artery is part of the ciliary arterial supply but supplies the macular region of the retina, which subserves central vision.

The O₂ supply to the eye is complex. The human retina has a dual supply; the retinal circulation supplies the inner layers of the retina and the choroidal circulation supplies the outer layers. Normally, the choroidal circulation supplies the majority of the oxygen to the retina, and only the inner layers of the retina are oxygenated from the retinal circulation. Under normoxic conditions, approximately 60% of the retina's oxygen supply comes from the choroidal circulation. Animal work indicates that oxygen from the choroidal circulation diffuses in adequate quantity to the inner layers of the retina under hyperoxic conditions to maintain ganglion cell viability and retinal function even when retinal blood flow has been interrupted (3,4,5). The cornea and lens are avascular structures. The cornea receives oxygen both from the precorneal tear film and the anterior chamber of the eye, while oxygen to the lens is provided by the aqueous and the vitreous (2). If blood flow to the eye is unimpeded but oxygen delivery to the eye is impaired, such as is the case with hypobaric hypoxia, the retinal vessels respond by dilating and ocular blood flow increases markedly (6).

The retinal vessels respond in a similar manner to CO hypoxia (7).

Many vision-threatening eye diseases are associated with hypoxia and accompanied by elevated levels of vascular endothelial growth factor (VEGF), a normal homodimeric soluble glycoprotein growth factor. Chronic retinal hypoxia, however, results in elevated levels of VEGF that trigger neovascularization in the retina, optic disk, and iris. Elevated levels of VEGF also cause increased vascular permeability that may produce loss of vision through macular edema. VEGF isoform 164 has been found to be an important isoform in the pathogenesis of early diabetic retinopathy (8). A number of agents have been developed to block the effect of VEGF and are now being used to treat a variety of ocular conditions.

PHYSIOLOGY OF THE EYE IN HYPEROXIC CONDITIONS

In order to understand the role of HBOT in ocular disorders, it is useful to review the effects of hyperoxia on the normal eye. Air at one atmosphere absolute (ATA) has an oxygen partial pressure (PO₂) of 0.21 ATA and produces an arterial PO₂ of approximately 100 mmHg in healthy young individuals (9). At this PO₂, the hemoglobin saturation approaches 100% and oxyhemoglobin transports the bulk of the oxygen to the body tissues (approximately 20 vol%). The amount of oxygen dissolved in plasma is normally only about 0.31 vol% but this dissolved oxygen fraction increases in proportion to the inspired PO₂. When 100% oxygen is breathed under hyperbaric conditions, for instance at 3 ATA, the oxygen dissolved in the plasma rises to 6 vol%. Since the body tissues at rest typically extract only about 5 vol%, enough plasma dissolved oxygen is available at 3ATA to meet metabolic needs without oxygen from hemoglobin (9).

Because of the retina's dual blood

supply, hyperoxygenation may enable the choroidal blood supply to supply the oxygen needs of the entire retina. Since central retinal artery obstructions are often transient, this phenomenon may enable the retina to survive a period of interrupted blood flow, and studies by Landers in the cat and rhesus monkey demonstrate that this is possible. In that study, when the retinal artery was occluded and the animals ventilated with 100% oxygen at one ATA, a normal or increased oxygen tension was produced in the inner layers of the retina. An arterial PO_2 of 375 to 475 mmHg provided a normal or increased inner retinal PO_2 , even with the central retinal artery occluded (4). Oxygen breathing at 1 ATA has been shown to restore the visual evoked response (VER) to normal despite retinal artery occlusion. A normal VER requires that all layers of the retina function normally and indicates that the inner retinal layers were adequately oxygenated in this model (4).

Hyperbaric oxygen is known to cause retinal vasoconstriction (10-18). As the PO_2 is increased to 2.36 and 3.70 ATA, the retinal vessels become progressively smaller, ¹⁴ and both retinal arterioles and venules are affected (16). At an arterial PO_2 of ~1,950 mmHg, the retinal arteriolar diameter decreases 19% (15). Vucetic noted a retinal arteriole constriction of 9.6% and a retinal venule constriction of 20.6% after 90 minutes of 2.5 ATA partial pressure of oxygen. Ten minutes after the hyperoxic exposure, the vessels had returned to 94.5% and 89.0% of their original size, respectively (11).

Hyperoxic retinal vasoconstriction has led some authors to theorize that retinal oxygenation decreases under hyperoxic conditions (19). This is not the case. Retinal venous hemoglobin oxygen saturation is found to increase from 58% breathing room air to 94% at 2.36 ATA, indicating that the hyperoxygenated choriocapillaris is supplying

enough oxygen to more than offset any decrease in oxygen supply caused by retinal vasoconstriction at high PO_2 (14, 20). Jampol demonstrated that hyperbaric oxygen at 2 ATA in primates markedly increased the preretinal PO_2 , indicating higher inner retinal oxygen levels under hyperoxic conditions (21). Dollery has also confirmed that a hyperoxygenated choroid can supply the oxygen requirements of the entire retina (22). Saltzman noted that while retinal vasoconstriction occurs under hyperoxic conditions, the appearance of bright red blood in the retinal veins indicates that the increase in oxygen transport during hyperoxia more than compensates for a reduction in retinal blood flow resulting from vasoconstriction (16).

Pressure with the fingertip applied on the lateral aspect of the eye through the lid raises intraocular pressure and typically causes a dimming of vision in less than 5 seconds. This phenomenon is believed to be due to retinal ischemia induced by the elevated intraocular pressure. Hyperbaric oxygen at 4 ATA extends the interval from pressure application to dimming of vision to 50 seconds or more but will of course soon produce CNS O₂ toxicity (23).

Jampol also found that normobaric oxygen delivered to the corneal surface of rabbits increased the PO_2 in the anterior chamber from 63.5 to 139.5 mmHg. Hyperbaric oxygen at 2 ATA presented to the corneal surface of air breathing rabbits further raised the anterior chamber PO_2 to 295.2 mmHg (21, 24).

Hyperoxic air (at 3 ATA) has been reported to decrease intraocular pressure from 15.3 mmHg to 12.3 mmHg in 14 volunteers over a mean time of 38 minutes. 100% oxygen at 1ATA also produces a significant decrease in intraocular pressure from 14.8 to 12.7 mmHg. The exact mechanism of the decrease in pressure is not clear, (25) although hyperoxic vasoconstriction is a potential mechanism for the observation. Note that intraocular

pressure measurements describe the difference between the intraocular tissues and the external environment, not the absolute pressure.

HBOT – General Considerations

Breathing oxygen at elevated pressures provides remarkable benefit for patients suffering from certain disorders. The first reported attempt to use hyperbaric therapy for medical disorders was in 1662 (26). It was subsequently popularized as a means of effectively treating decompression sickness in compressed-air tunnel or bridge workers. Hyperbaric therapy was also popularized for treating a number of medical disorders for which it is not effective, (27) leading the American Medical Association in 1928 to disclaim its indiscriminate use (26). Today the Hyperbaric Oxygen Committee of the Undersea and Hyperbaric Medicine Society maintains a list of indications for HBOT based on the peer-reviewed medical literature (28). The UHMS HBOT Committee Report is updated approximately every three years, and these recommendations are considered the gold standard for clinical HBOT practice.

There are a few points regarding treatment with HBOT to be made before discussing HBOT for specific ocular disorders:

1) Not all of the accepted indications for HBOT are based on evidence from randomized, controlled, prospective trials (29). Decompression sickness and arterial gas embolism are the best examples of this point.

2) The optimal oxygen pressure, optimal length of oxygen breathing time, and most advantageous time intervals for repetitive treatments are not precisely defined for most indications for HBOT (30-36).

3) The timing of HBOT administration after symptom onset usually affects the outcome. HBOT works less well or not at all beyond the optimal treatment window.

4) Because the pathophysiology of the

various indications for HBOT varies, so does the critical window for the initiation of HBOT.

5) For acute ocular diseases that threaten life or eyesight and which have been shown to respond to HBOT, aggressive use of HBOT is indicated, especially when other treatment options are less likely to be effective.

6) For chronic diseases in which HBOT's efficacy is more difficult to discern or where it is but one of many therapeutic modalities available to the physician, a more cautious approach to HBOT is indicated.

7) When other effective therapeutic measures are available that are less expensive, more easily administered, and/or entail less inconvenience or risk to the patient, they should be used first - even if HBOT is effective for that disorder.

OCULAR CONSIDERATIONS IN HBOT FITNESS-TO-DIVE EVALUATION

From an ocular perspective, HBOT contraindications are significantly different from those published for fitness-to-dive in divers (37). There is less concern about visual acuity, since the patient may be assisted as needed in the chamber environment. The prescribed convalescent period prior to resumption of diving activity after ocular surgery is not typically relevant to HBOT (except as noted below), since there is no potential for facemask barotrauma or water intrusion into an ocular operative site in a hyperbaric chamber. Glaucoma is not a contraindication to HBOT (37). Several ocular conditions remain, however, as contraindications to HBOT:

1. Presence of a hollow orbital prosthesis. Individuals who have had an eye removed typically have a prosthesis placed in the orbit. There are reports of pressure-induced collapses of hollow silicone orbital implants at depths as shallow as

10 feet (38). Most ocular implants used presently, however, are not hollow and are not a contraindication to diving or HBOT. A hollow orbital prosthesis is a relative contraindication and should not prevent HBOT required to preserve life, neurological function, or vision in the contralateral eye.

2. Presence of an intraocular gas bubble. Intraocular gas is used in selected cases by vitreoretinal surgeons to maintain juxtaposition of the retina to the retinal pigment epithelium and by anterior segment surgeons to maintain juxtaposition of Descemet's membrane to the posterior corneal stroma. Gas in the eye may result in intraocular barotrauma during compression or a CRAO during decompression and is a contraindication to exposure to changes in ambient pressure (39). Intraocular gas bubbles expand even with the relatively small decreases in ambient pressure entailed in commercial air travel (40,41). This expansion causes an increase in intraocular pressure (40, 42) and may cause sudden blindness at altitude due to a pressure-induced closure of the central retinal artery (40, 43). Jackman has shown that intraocular bubbles in the rabbit result in a dramatic decrease in intraocular pressure during compression followed by a marked increase in intraocular pressure upon return to 1 ATA as the bubble expands (44).

An important exception to the rule of intraocular gas bubbles as a contraindication to HBOT is bubbles that occur as a manifestation of decompression sickness. Recompression and HBOT should be undertaken in this instance with the expectation that the normal volume of the anterior chamber, posterior chamber, and vitreous prior to the formation of the bubble due to inert gas supersaturation will prevent compression barotrauma. Resolution of the intraocular bubbles and inert gas supersaturation during HBOT would oppose an expanding gas phase on decompression and a secondary rise in intraocular pressure.

Another exception is the intraocular gas bubbles that occur with intraocular gas gangrene. HBOT is recommended for this disorder as well, although the bubble dynamics during HBOT might well be different from those with inert gas supersaturation.

PRE-HBOT OCULAR EXAMINATION

If emergent HBOT is indicated for an ocular indication, such as DCS, arterial gas embolism (AGE), or central retinal artery occlusion (CRAO), significant delays for ophthalmic consultation and detailed eye examinations may result in worsening of the patient's clinical condition and are not indicated. Visual function should be quantified expeditiously while awaiting HBOT using rapid measures such as visual acuity charts, color vision plates, Amsler grids, near-vision cards, ability to read printed material, and confrontation visual fields. Some of these methods may also be used to follow visual function inside a multiplace chamber during HBOT, and some may be useful even through the window of a monoplace chamber. If ocular signs or symptoms are part of the indication for HBOT, an eye examination by an ophthalmologist should be conducted as soon as feasible after recompression.

Documentation of ocular function prior to beginning HBOT therapy for a non-emergent indication allows the hyperbaric physician to have better objective measures of ocular function so that any benefit of therapy can be documented and any adverse effects of HBOT on the eye, such as hyperoxic myopia, can be quantified accurately. Whenever a patient is being considered for a prolonged course of HBOT, a pre-treatment eye examination is indicated. This exam should include documentation of corrected and uncorrected visual acuity, refraction, color vision, status of the crystalline lens, and fundus

examination. Automated visual perimetry (visual field examination) should be included for indications that include decreased vision as part of the condition. This examination should be repeated periodically when conducting repetitive HBOT.

RECOMMENDED OCULAR INDICATIONS FOR HBOT

The authors recommend HBOT for the ocular disorders listed in this section. The list of recommended ocular indications for HBOT is summarized in Table 1.

Table 1. Ocular Indications for HBOT

Decompression Sickness
Arterial Gas Embolism
Central Retinal Artery Occlusion
Ocular and Periocular Gas Gangrene
Cerebro-Rhino-Orbital Mucormycosis
Periocular Necrotizing Fasciitis
Carbon Monoxide Poisoning with Visual Sequelae
Radiation Optic Neuropathy
Radiation or Mitomycin C-Induced Scleral Necrosis
Periorbital Reconstructive Surgery

Decompression Sickness with Ocular Signs or Symptoms

Decompression Sickness (DCS) results from gas bubble formation in the tissues of individuals who undergo a reduction in ambient pressure without adequate time to eliminate excess inert gas, thus causing gas bubbles in body tissues to form from the resulting supersaturation. Decompression stress also produces bubbles in the tear film and this phenomenon has been proposed as an alternative to Doppler ultrasound as a measure of decompression stress (45).

DCS from either diving or altitude exposure may present with visual signs and/or symptoms such as blurred vision, scotomata, scintillations, diplopia, photophobia, visual field defects, optic neuropathy, branch retinal

artery occlusion, and loss of vision (37, 46-55). Ocular symptoms may occur alone or in combination with other signs and symptoms. Rivera noted visual disturbances in 6.8% of DCS patients in his study of 935 cases and were the sole presenting symptom in 1.4% of cases (54). Visual symptoms have been reported to be the most common presentation of neurological DCS resulting from altitude exposures (52). The acute onset of visual or neurological signs or symptoms proximate to diving or hypobaric exposure is considered decompression sickness or arterial gas embolism and treated with recompression unless another explanation exists for these symptoms (lost contact lens, scopolamine reaction, etc) (37, 46, 49, 56).

In a retrospective study of altitude-related DCS with visual symptoms, a 97% resolution rate was achieved with HBOT administered by US Navy treatment tables (47). Two cases of DCS after altitude exposure in which optic neuritis-like symptoms (blurred vision, retro-orbital pain, and scotomata) were the only presenting complaints have been reported (46, 49). In both cases, the patients underwent multiple HBOT treatments using USN Table 6 with eventual complete resolution of signs/symptoms.

As noted previously, recompression delays for formal eye examinations in patients presenting acutely with DCS or AGE may result in worsening of patient's clinical condition and are not indicated before the initial treatment. Recompression is indicated even if there has been a significant delay between the onset of symptoms and presentation, since untreated or partially treated DCS may worsen without HBOT. Neurological DCS, including visual symptoms, may benefit from HBOT even after a significant delay (46, 49, 57, 58). Additionally, neurological DCS rarely may continue to evolve even several weeks after the precipitating hypo or hyperbaric exposure if HBOT is not undertaken, further emphasizing

the importance of HBOT for DCS even when presentation is delayed (46, 49, 59). When HBOT is conducted for ocular manifestations of DCS, the authors recommend the treatment plans in the U.S. Navy Diving Manual to guide therapeutic decisions (56). DCS patients should receive normobaric oxygen at the highest possible inspired oxygen fraction until they are recompressed (56, 60).

Individuals with DCS or AGE who present with ocular signs or symptoms will require evaluations of their visual status while at depth during recompression to assess the adequacy of treatment and guide treatment decisions. Visual acuity should be measured with a near vision card (with refractive correction for age as appropriate). Color vision should be monitored with pseudo-isochromatic plates at depth and central visual field may be evaluated with Amsler grid testing. This indication for HBOT is approved by the Hyperbaric Oxygen Committee of the UHMS (28).

Arterial Gas Embolism with Visual Signs or Symptoms

Arterial gas embolism (AGE) may result from a variety of mechanisms including diving-induced pulmonary barotrauma with introduction of gas bubbles into the pulmonary venous circulation, altitude exposure (61), the iatrogenic surgical introduction of gas (62-65), and by breathing from a high pressure gas cylinder without benefit of a regulator (66, 67). Visual symptoms associated with AGE include monocular loss of vision (typically from CRAO), homonymous hemianopia, nystagmus, papilledema, and cortical blindness (37). In one report, ten of 91 cases of cerebral arterial gas embolism displayed visual abnormalities (36). Gorman reported a similar 11.2% of cases of AGE displaying visual signs or symptoms (68).

The therapeutic benefit of HBOT in AGE is believed to result from one or more of

the following effects: 1) mechanical reduction of the volume of the gas emboli; 2) reduction of the partial pressure of nitrogen in the blood, thereby increasing the resolution speed of the gas bubble; 3) increasing the oxygenation of hypoxic neural tissue; and 4) decreasing post-embolic cerebral edema (69).

Emergent HBOT as outlined in the U.S. Navy Diving Manual is recommended for AGE and has been shown to be effective in reversing the visual manifestations of AGE when undertaken promptly (66, 67). Treatment for presumed AGE should be administered even when there are significant delays to treatment. AGE resulting from non-diving causes such as surgical procedures, mechanical ventilation, and central venous catheterization often experience delays in diagnosis and treatment, but may benefit from HBOT, even as much as 15-60 hours after the embolic event (69, 70).

Bove et al were among the first to note that treatment with 100% oxygen at 2.8 ATA may provide successful treatment for AGE without initial therapy at 6.0 ATA. Their patient (whose presentation included cortical blindness) was treated twice with USN Table 6 beginning seven hours after the onset of symptoms with gradual resolution of symptoms (70). Although previous guidelines called for immediate recompression of arterial gas embolism patients to 6 ATA (165 FSW) for 30 minutes breathing air or nitrox, Bove's case and subsequent animal studies (34) document the efficacy of HBOT at 60 FSW in treating AGE. Newer treatment guidelines do not call for recompression to 165 FSW unless oxygen breathing at 60 FSW does not produce substantial improvement by the end of the first 20-minute oxygen breathing period (56). This indication for HBOT is approved by the Hyperbaric Oxygen Committee of the UHMS (28).

Central Retinal Artery Occlusion (CRAO)

The outcome of arterial occlusive diseases of the retina depends on the vessel occluded as well as the degree and location of the occlusion. The type of occlusion (thrombosis, embolus, arteritis, or vasospasm) may also affect the outcome (71,72). The classic presentation of CRAO is sudden painless loss of vision in the range of light perception. Vision at the “no light perception” level usually indicates occlusion at the level of the ophthalmic artery with absence of blood flow to either the retinal or the choroidal circulation (1). On dilated fundoscopic exam, patients with CRAO will display a whitish appearance of the macula due to the opaque and edematous nerve fiber and ganglion cell layers. A cherry red spot may be present in the fovea, but this finding may be absent, especially with occlusion of the ophthalmic artery. Cilioretinal arteries are part of the ciliary (not retinal) arterial supply and supply the area of the retina around the macula (central vision area). If a cilioretinal artery is present, central vision may be preserved in the presence of a CRAO, but the peripheral visual fields are typically severely decreased. Intravenous fluorescein angiography (IVFA) shows non-filling of the occluded artery (Figure 1).

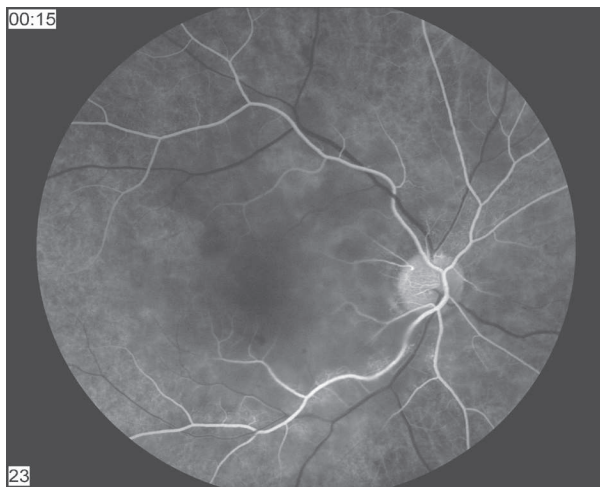


Fig. 1. Central Retinal Artery Occlusion
Photo courtesy of Dr. Steve Chalfin

In the largest published series of CRAO patients, Hayreh describes the outcome of this condition without HBOT. He found that patients with cilioretinal arteries had much better visual outcomes than those who did not. In patients without cilioretinal arteries, 80% had a final visual outcome of count fingers or less and only 1.5% of individuals obtained a final vision of 20/40 or better (71). Although recanalization eventually takes place after CRAO, (73, 74) in relatively few cases does this reperfusion lead to an improvement of vision, presumably because the retinal tissue has been irreversibly damaged during the ischemic period (73). The retina has the highest rate of oxygen consumption of any organ in the body at 13ml/100g/min and is therefore very sensitive to ischemia (75).

Conventional treatment regimens for CRAO have been aimed at promoting downstream movement of the embolus by lowering intraocular pressure and producing vasodilatation. These measures include ocular massage, anterior chamber paracentesis, intraocular pressure-lowering medications, carbogen, and aspirin (1, 72, 73, 75). These modalities have been largely unsuccessful (72, 73, 76). The American Academy of Ophthalmology Basic and Clinical Science Course states that “the efficacy of treatment is questionable” for CRAO (1). More recent treatment modalities include thrombolytic agents (77, 78) and surgical removal of the embolus or thrombus (79, 80). Hayreh states that no current therapy is efficacious for CRAO (71). Acute obstruction of the central retinal artery without HBOT typically results in severe, permanent visual loss (71, 73).

Supplemental normobaric oxygen therapy may help reverse retinal ischemia in CRAO. In order to be effective, supplemental oxygen must be continued until retinal arterial blood flow has recovered sufficiently to maintain inner retinal function under normoxic conditions. If ischemia and cellular hypoxia

have resulted in cell death of the inner layers of the retina, vision will not return when blood flow is re-established (81).

Butler reported a patient who suffered acute loss of vision in his only seeing eye and presented approximately one hour after vision loss. His vision was 20/400 and he had fundus findings of CRAO. He was treated with oxygen administered by reservoir mask at 1ATA in the emergency department and his vision quickly improved to 20/25. After approximately 5 minutes, the supplemental oxygen was discontinued, whereupon vision equally quickly returned to 20/400. This process was repeated several times to confirm the beneficial effect of the supplemental oxygen with the same results. The patient was hospitalized, anticoagulated, and maintained on supplemental oxygen for approximately 18 hours, after which time the central retinal artery presumably recanalized, because removal of the supplemental oxygen no longer caused a decrease in vision. He was discharged with a visual acuity of 20/25 in his only seeing eye (39). In similar cases, Patz reported improvement in two CRAO patients given oxygen at 1 ATA. One patient received oxygen after a four-hour delay to therapy and improvement from 4/200 to 20/70 was maintained after supplemental oxygen therapy was discontinued 4 hours later. The second patient improved from no light perception to 20/200 after a 90 minute treatment delay and maintained this improvement when oxygen was discontinued 3 hours later. In both patients, early discontinuation of oxygen was followed by deterioration of vision within minutes. Improved vision was restored when oxygen breathing was resumed shortly thereafter. This phenomenon was observed several times in both patients (5).

The 1980 study of Augsberger and Magargal emphasized the importance of prompt oxygen treatment to a good outcome. They used paracentesis, ocular massage,

carbogen, acetazolamide, and aspirin to treat 34 consecutive cases of CRAO. Twelve of the 34 patients were successfully treated, with 7 of the 12 being treated within 24 hours of symptom onset. The longest delay to treatment after which treatment was considered successful was 72 hours. The average delay to therapy in the patients with successful outcomes was 21.1 hours, compared to 58.6 hours in those who did not improve. Carbogen inhalation was conducted for 10 minutes every hour during waking hours and 10 minutes every 4 hours at night and continued for 48-72 hours (82). A CRAO patient treated at Duke 10 days after the onset of decreased vision did not have improvement of his hand-motion vision with 9 sessions of HBOT at 2 ATA for 120 minutes each (personal communication – Dr. RE Moon).

Stone et al reported two patients with CRAO of greater than 6 hours duration treated with intermittent carbogen at 1 ATA, retrobulbar anesthesia, and anterior chamber paracentesis. The first patient had vision loss of 6 hours duration. His vision improved from hand motion to 20/20 on the above therapy, with carbogen administered for 10 minutes every hour. The second patient presented 8 hours after onset of visual loss and had improvement from finger counting to 20/25. Carbogen was administered 10 minutes every hour for 48 hours (72).

Carbon dioxide is added to oxygen in carbogen for its vasodilatory effect in an effort to counter hyperoxic vasoconstriction. If the mechanism of improved oxygenation to the retina is diffusion from the choroidal circulation, however, then the addition of CO₂ should not be required to improve oxygenation. Unlike retinal blood flow, choroidal blood flow is not significantly affected by changes in oxygen tension (3, 10).

Another report described a patient with angiographically-documented obstruction of both the central retinal artery and temporal posterior ciliary artery (73). He presented

after 5 hours of visual loss with minimal light perception vision. In addition to ocular massage, anterior chamber paracentesis, timolol, and acetazolamide, he was given carbogen for 10 minutes every hour around the clock. His vision did not improve significantly during his three days of hospitalization, but improved spontaneously approximately 96 hours after onset of vision loss. Vision in the affected eye was documented to be 20/30 one week after discharge. Although the authors of this report do not necessarily ascribe his recovery to any of the treatments, the role of supplemental oxygen in maintaining retinal viability until spontaneous recanalization occurred must be considered, since only rarely do patients with CRAO have spontaneous improvement in vision (73).

Supplemental oxygen at 1ATA may not preserve retinal function in CRAO. This intervention did not reliably prevent inner retinal hypoxia in a rat model when the retinal circulation was occluded by laser photocoagulation (83). If normobaric oxygen does not restore vision in a CRAO patient, emergent HBOT should be considered. HBOT has been successful when normobaric hyperoxia has failed to restore vision in CRAO. Phillips reported a 71 year-old white female patient with CRAO in whom surface oxygen was ineffective in reversing “total vision loss” of approximately 2 hours duration (84). The patient was then compressed to 2.8 ATA on a U.S. Navy Treatment Table 6. As she passed 15 feet during her descent, light perception was restored and at the end of her first air break at 2.8 ATA, she reported full return of vision. She was discharged with a visual acuity of 20/30 in her only seeing eye. A 2+ afferent papillary defect noted prior to treatment had resolved after treatment (84).

As with oxygen administration at 1 ATA, HBOT must be started within the time that retinal tissue can still recover. There is

a point beyond which ischemic tissue can no longer recover even if reperfusion occurs (3). Hayreh et al occluded the ophthalmic artery of rhesus monkeys for varying periods of time. Retinas that went more than 105 minutes without blood flow showed permanent damage. If the duration of occlusion was less than 97 minutes, the retinas recovered their normal function (85). Treatment of CRAO should be aimed at promptly supplying oxygen to the ischemic retina at a partial pressure sufficient to maintain inner retinal viability until restoration of central retinal artery blood flow occurs.

The literature includes cases in which patients with CRAO have regained significant vision even with treatment delays of up to two weeks (86) with the strongest evidence for symptomatic improvement in cases with less than 12 hours of delay (3,75, 87-89). In the clinical setting of CRAO, residual retinal arterial blood flow may be detected by fluorescein angiogram (74, 82). This may help to explain the great variability in visual outcome observed with different delays until treatment. The studies by Hayreh that noted irreversible retinal damage after 105 minutes entailed complete occlusion of the ophthalmic artery, the most severe model of ocular vascular occlusion and one that may not be frequently encountered in the clinical setting.

The treatment options for CRAO patients with symptom durations of several weeks or longer would be expected to provide a minimal chance of improvement, yet some patients have been reported to improve even after prolonged delays, although the details of the level of improvement are limited (90). Henderson and Slade reviewed the records of 16 patients treated with HBOT for CRAO (2.0 ATA of oxygen 90 minutes twice daily for 2-3 days, then once daily until reaching clinical plateau). Eleven of the 16 showed improvement with HBOT. Four of the five patients who showed no improvement had a delay to presentation of

more than 24 hours (91).

Hertzog et al. reported 17 patients with CRAO treated with HBOT. They divided patients retrospectively into 4 treatment groups based on the time from symptom onset to HBOT and noted that HBOT seemed useful in preserving visual function when applied within 8 hours from the onset of visual impairment. These patients were treated with 105 minutes of oxygen at 2.0 ATA three times a day until they ceased to show improvement in visual acuity or for 3-4 days if no improvement occurred, receiving a mean of 29.3 hours of HBOT early in the study and 34.6 hours later in the study. The authors point out that the phrase “Time is Muscle” used in management of myocardial infarctions can be changed to “Time is Vision” in CRAO (75). Takeuchi reported a patient with central retinal artery occlusion occurring after a long surgical procedure to fuse the lumbar spine. Immediate treatment with urokinase, PGE1, stellate ganglion block, and HBOT resulted in improvement of the affected eye (92).

Another paper demonstrated success in three cases of CRAO treated shortly after symptom onset. One patient treated 90 minutes after onset of visual loss had vision improve from light perception to counting fingers after the first 10 minutes of HBOT with subsequent improvement to 20/70 following five days of two 90-minute HBOT treatments at 2.5 ATA daily. Another presented 40 minutes after visual loss and improved from hand movement to 20/20 after 12 treatments at 2.5 ATA in 9 days. A third patient presented 4 hours after the onset of symptoms with finger-counting vision. He received ten 90-minute HBOT treatments at 2.5 ATA with gradual improvement of visual acuity to the 20/30 level. A last patient who was treated with HBOT 6 hours after symptom onset showed no significant improvement in vision (89).

In 2001, Beiran published a retrospective study of 35 patients treated with HBOT

compared to 37 matched controls from another facility where the modality was not available (93). All patients were treated within 8 hours of symptom onset and none of the patients included in the trial had a cilioretinal artery. The patients in the HBOT group received 2.8 ATA of oxygen for 90 minutes twice a day for the first three days and then once daily until no further improvement was seen for 3 consecutive days. In the hyperbaric group, 82% of the patients improved compared to only 29.7% of patients in the control group. Improvement was defined as reading at least 3 lines better on Snellen chart compared to admission. The mean visual acuity for the HBOT group at discharge was 20/70 (93).

Reports that describe failure of HBOT in CRAO sometimes fail to even note the elapsed time from symptom onset to HBOT (17) and HBOT in these cases may have been started well after the window for successful treatment has passed. Miyake reported 53 cases of CRAO and 19 branch retinal artery occlusions treated with HBOT over a 13 year period. He found no significant difference between time to treatment and response to HBOT; however, only 3 patients received HBOT within 24 hours of symptom onset, which places most of his patients outside the window in which improvement from HBOT is most likely to occur. Overall 44% of his patients showed improvement of at least 2 levels on the visual acuity scale after treatment with HBOT despite this delay to treatment. Unfortunately, no distinction was made between patients with cilioretinal arteries and those without (94).

Failure of HBOT has been reported in one case of CRAO in which there was angiographic documentation of a complete obstruction of the involved ophthalmic artery. There must be an intact choroidal circulation for HBOT to reverse the vision loss in CRAO (95).

The reports noted above document

that some patients with CRAO can be treated successfully with oxygen, either at 1 ATA or with HBOT. HBOT is a low-risk therapeutic option with demonstrated benefit in treating CRAO if treatment is begun before the retina suffers irreversible ischemic damage and there is an intact choroidal circulation. There are no alternative therapies with similarly favorable outcomes (71, 76, 96).

The devastating vision loss of untreated CRAO calls for an aggressive approach to employing HBOT for this disorder. Triage personnel should be aware that sudden painless loss of vision of less than 24 hours duration is a medical emergency. Patients with documented or suspected CRAO of less than 24 hours duration should receive supplemental oxygen at the highest fraction attainable immediately (5, 39, 72, 73, 82, 97, 98). Emergent HBOT should be undertaken if this intervention is not rapidly effective in improving vision. The patient should be maintained on supplemental oxygen at the highest possible FIO₂ until HBOT is begun, and then treated with the step-wise protocol outlined in the “Emergent HBOT for Acute Vision Loss” (Treatment Algorithm, Figure 7, See Appendix 2, pg 381). Ocular massage and topical ocular hypotensive agents may be employed adjunctively. While there are some case reports of patients presenting after 24 hours from onset of vision loss obtaining benefit from HBOT, the majority of cases do not respond when treated beyond this point (75, 82, 88, 94, 97, 99). This indication for HBOT has recently been approved by the Hyperbaric Oxygen Committee of the UHMS.

Ocular and Periocular Gas Gangrene

Clostridial gas gangrene (myonecrosis) is a rapidly progressive, life-threatening infection that may cause death within hours if not treated adequately. The use of HBOT for the treatment of anaerobic infections was pioneered by Brummelkamp and his colleagues (100).

The rationale for HBOT in infections caused by obligate anaerobes with is clear and HBOT is standard adjunctive therapy for clostridial myonecrosis (101).

Gas gangrene may occur in the eye, the orbit, and the periocular tissues, although these sites of infection are uncommon. Gas gangrene panophthalmitis may occur following penetrating ocular injuries. Gas bubbles in the anterior chamber should alert the physician to consider this diagnosis (102-104). Other signs may include a red, painful eye, chemosis, coffee-colored discharge from the wound, and a corneal ring abscess (104, 105). The typical outcome from gas gangrene panophthalmitis is loss of the eye but recovery of the patient (103, 104).

Fielden has reported a case of gas gangrene panophthalmitis that was successfully treated with extensive surgical debridement, anti-microbial therapy, and HBOT (106). Bristow noted that gas gangrene panophthalmitis typically requires evisceration of the eye (as was done for this patient) or exenteration of the orbital contents. He used HBOT (3 ATA oxygen for 120 minutes x 6 sessions within the first 30 hours postoperatively) in the patient described in his report because of evidence of spread of infection to the orbital and periocular tissues as well as systemic toxicity. 48 hours after starting HBOT, there was systemic improvement and the patient made a successful recovery (105). This indication for HBOT is approved by the Hyperbaric Oxygen Committee of the UHMS (28).

Cerebro-Rhino-Orbital Mucormycosis

Cerebro-rhino-orbital mucormycosis (CROM) and other necrotizing fungal infections are rare disorders associated with immune compromise, including poorly controlled diabetes mellitus. The inhalation of spores from the causative fungal organisms leads to infection of the palate, nose, orbit, or paranasal

sinuses. The fungus invades blood vessels, particularly arteries, resulting in thrombosis and infarction (107).

The typical presentation of CROM is that of a patient with diabetes or other immune-compromising condition who exhibits unilateral headache, facial pain, nasal stuffiness, facial and/or eyelid swelling, epistaxis, rhinorrhea with a granular or purulent discharge, and fever. Headache or facial pain out of proportion to radiographic findings is characteristic. Mental status changes may ensue (108).

The first human case of mucormycosis with central nervous system involvement was reported by Paltauf in 1885 (108, 109), and the first cure was reported in 1955 (110). Extensive surgical debridement and amphotericin B treatment resulted in improvement in survival to approximately 50% (108, 111). CROM is currently treated with aggressive surgical debridement of the infected tissues, often including orbital exenteration, and amphotericin B. The benefit of HBOT is that it increases tissue oxygenation, thereby improving phagocytosis and augmenting the oxidative burst required for leukocyte microbial killing. HBOT also directly inhibits the growth of some fungi and corrects the acidosis that accompanies vascular invasion by the fungus (112, 113).

HBOT has been reported as a helpful adjunct in halting the progression of orbital mucormycosis (107, 113-121). One report noted that aggressive use of amphotericin B combined with HBOT may spare the patient the need for radical orbital surgery (116). Another noted that treatment with amphotericin B for 6 weeks had been unsuccessful and that the infection was not controlled until HBOT was added to the regimen (115). HBOT regimens used successfully for this disorder include 2 ATA oxygen for 90 minutes a day for two weeks (107) and 3 ATA oxygen for 120 minutes per day (119).

Other authors have disputed the efficacy

of HBOT in CROM. One such report describes 5 CROM patients treated without HBOT. Four of these five patients died, for an 80% mortality in this series (122).

Couch reported the successful use of HBOT in two difficult patients with CROM. Both patients had significant cerebral extension of their disease and were deteriorating despite extensive surgical debridement and amphotericin B. The author note that this clinical picture is almost always associated with a fatal outcome. HBOT was begun (2.5 ATA for 90 minutes daily for 6 days per week) for a total of 79 sessions in one patient and 85 in the second patient. Both patients began to improve clinically after HBOT was started and ultimately survived the infections. The authors note that HBOT was the only aspect of the care that had a temporal association with the beginning of clinical improvement (121).

In the largest series of CROM patients published to date, the authors noted that of the 18 patients with bilateral CROM who were treated with surgery and amphotericin B without HBOT, only four survived. In contrast, 5 of the 6 patients treated with surgery, amphotericin B, and HBOT (2 to 2.5 ATA O₂ for 90 to 120 minutes every 12 to 24 hours) survived (108). Yohai and his co-authors recommend that HBOT be considered as part of the initial therapy of CROM and continued until evidence of disease regression is noted. HBOT is most effective when the interval of from onset of symptoms to initiation of treatment is 6 days or less (108). Bitterman notes that although prospective randomized trials are lacking for the use of HBOT in this disorder, “the cumulative impression from the available literature, the high fatality rate in these conditions, the relative ease of application, and the low rate of adverse effects from HBOT all call for the use of HBOT in treating invasive fungal infections (112).

HBOT may also be useful when a

CROM patient declines aggressive surgical debridement. Price reported such a patient and noted that death seemed imminent until HBOT was initiated (2 ATA O₂ every 12 hours for 2 days, then once a day for a total of 22 treatments). The authors noted that “The rapidity of progress of this disease process indicated near certain rapid demise of this patient.” After her course of HBOT, her condition stabilized and she subsequently recovered from her infection (111).

This indication for HBOT is approved by the Hyperbaric Oxygen Committee of the UHMS (28).

Periocular Necrotizing Fasciitis

Group A streptococci, staphylococci, and other organisms may cause necrotizing soft-tissue infections that progress to septic shock and multiple organ dysfunction syndrome. Approximately 1,000 cases of this disorder occur annually in the United States (123). A history of minor trauma is common, but may not always be present (124-126). The infection spreads along fascial planes and may cause necrosis of the overlying skin. Necrotizing fasciitis may have a mortality rate as high as 38% (127). The perineum and the lower extremities are the most commonly affected sites (32), but this disorder has been reported as a complication of incisional and laser blepharoplasty as well as periocular trauma (126, 128-130). Early recognition is key, followed by resuscitation, antibiotics and aggressive surgical exploration and debridement (32, 127). Treatment for periocular involvement with this disease may include exenteration of the orbital contents (131).

The efficacy of adjunctive HBOT in treating necrotizing soft-tissue infections is supported by a large body of animal and clinical data (32, 101). HBOT has been reported to be a useful adjunct to intravenous antibiotics and surgical debridement in the management of

periocular necrotizing fasciitis (32, 126-129). HBOT enhances bacterial killing capability in leukocytes, stimulates collagen formation, increases tissue oxygen levels, and increases the effectiveness of antibiotics administered (32, 101).

Although some series have shown no advantage to using HBOT in necrotizing fasciitis, (132) a series of 17 necrotizing fasciitis patients treated with HBOT (2.5 ATA for 90 minutes for an average of 7.4 treatments) and 12 controls treated without HBOT noted mortality rates of 23% and 66% in the HBOT and control groups, respectively (123). Another report noted excellent success in 16 patients who received adjunctive HBOT at 2.8 to 3.0 ATA for 90 minutes a day until no evidence of infection was seen at two consecutive wound revisions accomplished after every second HBOT treatment (127). HBOT 2 ATA for 120 minutes daily for 7 days has been used with good results (126).

A meta-analysis of series of necrotizing soft-tissue infections by Moon and colleagues supports the value of HBOT as an adjunct to surgery and antibiotics, with an overall increased survival rate in those patients receiving HBOT (101). HBOT treatments are administered at 2.5 to 3.0 ATA O₂, usually for 90 minutes. Two to four treatments are usually given in the first 24 hours and then two treatments per day until the patient is clinically stable. A total of 5-10 treatments are usually given for clostridial infections; more treatments are often given for mixed infections (101). This indication has been approved by the Hyperbaric Oxygen Committee of the UHMS (28).

Carbon Monoxide Poisoning with Visual Sequelae

Carbon monoxide (CO) poisoning is initiated by CO binding reversibly with hemoglobin with an affinity over 200 times that of O₂, thus displacing oxygen from hemoglobin

and causing tissue hypoxia (133). CO is the most common cause of poisoning worldwide and often results in persistent neuropathologic and cognitive sequelae (134-137). Clinical symptoms may be caused by HbCO levels as low as 16%. A concentration of CO in air of 0.4% raises the HbCO level to approximately 30% and may cause death within an hour (134). Although an elevated carboxyhemoglobin level is a key factor in diagnosing CO poisoning, it does not predict the severity of clinical signs and symptoms (136). Additionally, CO levels measured in the hospital may be low as a result of elapsed time since the CO exposure was discontinued and the administration of supplemental oxygen during hospital transport (134).

The most common signs and symptoms of CO poisoning are non-specific and include headache, dizziness, confusion, nausea, vomiting, and coma (134, 136, 138). Visual loss may also be part of the spectrum of neurological signs and symptoms in patients suffering from CO poisoning (33, 133, 139, 140). Ocular manifestations may begin days after the CO exposure (139) and include optic neuropathy (141), venous engorgement and peripapillary hemorrhages (142), nerve fiber layer hemorrhages, cortical blindness (141), paracentral scotomas, homonymous hemianopias (142), visual field constriction, optic neuritis, extraocular muscle palsies, nystagmus, and pupillary abnormalities (143). A syndrome that resembles the hypoxic retinopathy of altitude with swollen disks, retinal venous tortuosity and engorgement, increased retinal blood flow, flame-shaped and round retinal hemorrhages and cotton-wool exudates has been reported (6, 7, 140, 142, 143). One paper notes that “the earliest and most constant sign of carbon monoxide intoxication is congestion of the retinal veins and hyperemia of the optic disk (142).” Retinal hemorrhages are commonly found in

CO poisoning when fundus examinations are consistently performed (140). Kelley noted that all five of the CO poisoning patients in a case series who had been exposed to CO for more than 12 hours had retinal nerve fiber layer hemorrhages (138). Visual signs and symptoms are often discovered after arousal from coma, but blindness without antecedent coma is also reported (142).

Delayed and recurrent symptoms are common in this disorder. HBOT may be effective even when started a few days after the exposure (139). Weaver and colleagues found that 3 HBOT treatments in the first 24 hours reduced cognitive sequelae from 46% to 25% compared to the normobaric oxygen control group (33). Risk factors for cognitive sequelae include age greater than 36 years and carboxyhemoglobin levels greater than 25% (144).

When available, HBOT is preferred for the treatment of CO poisoning over normobaric oxygen (33, 134, 139, 145), although there is still some disagreement (146). HBOT helps eliminate carboxyhemoglobin, sustains cerebral metabolism, and reduces cerebral edema (133). HBOT has been reported as a useful adjunct in treating visual loss as a late complication of carbon monoxide poisoning (139). The optimal HBOT treatment regimen for CO poisoning has not been well defined (33, 134, 135), but the benchmark is three HBOT sessions in 24 hours as in the Weaver study (33). This indication for HBOT has been approved by the Hyperbaric Oxygen Committee of the UHMS (28).

Radiation Optic Neuropathy

Radiation optic neuropathy (RON) is an uncommon but devastating complication of radiation therapy involving the visual pathways. RON results from ischemia of the optic nerve caused by occlusive obstruction of the arteries supplying the optic nerve head and the retrolaminar aspect of the nerve (147).

The radiation that causes RON is delivered to the ocular or periocular area, typically to treat tumors of the choroid, retina, orbit, paranasal sinuses, cranial fossa, nasopharynx, or hard palate (147, 148). RON is usually seen only after the cumulative total dose of radiation has exceeded 50Gy or after single doses of radiation to the visual tissues of 10 Gy or greater (149). Preventive strategies to minimize this disorder include using dose fractionation of 1.8Gy to a dose of around 45Gy (150).

The onset of RON is typically delayed for a period of months to years after the completion of radiotherapy. The usual delay to onset of RON is 12-18 months with 90% of cases occurring within 3 years of radiation (149, 151). Exactly why the optic nerve radionecrosis is delayed is not precisely understood, but it may be that it results from the target cells being the replicating glial cells and the vascular endothelial cells, both of which have a slow cellular turnover rate (152).

When evaluating visual loss after cranial irradiation, four possibilities should be considered: 1) recurrence of tumor; 2) empty sella syndrome; 3) radiation-induced tumor; and 4) RON (153). Late-onset RON is characterized clinically by vision loss, vasculitis, and optic disc pallor. The etiology of visual loss in this entity is an occlusive vasculitis (154). Histopathology shows necrosis, exudates, ischemic demyelination, and an obliterative endarteritis (148, 151, 155). Posterior optic neuropathy characterized by visual loss with a normal appearance of the optic nerve initially is also a common presentation (152, 156).

RON typically results in blindness (148). The second eye is often affected shortly after the first, but RON in the second eye may be delayed for months after the first (149, 152). Spontaneous improvement or recovery after RON is rare (149). Final vision is no light perception in 45% of affected eyes and worse than 20/200 in another 40% (152). Borruat

reported that 120 patients not treated with HBOT had no spontaneous visual recovery, whereas two of five patients treated with HBOT one day and three weeks after onset had a marked visual recovery. The author recommended a regimen of thirty 90-minute sessions at 2.4 ATA and that therapy be initiated as soon as possible after the onset of visual loss. He also noted that HBOT at 2.4 ATA was more effective than therapy at 2.0 ATA (154). The same author also reported full visual recovery in the more recently affected eye of an RON patient treated promptly (within 2 days) with HBOT (2.4 ATA O₂ for 90 min with 10-minute air breaks at 30 and 60 minutes) twice a day for 2 days, then 5 to 6 times per week for a total of 35 sessions. Three weeks after completion of HBOT, vision in the right eye was 20/20; vision in the other eye, which had been treated without HBOT at its onset of RON 15 days earlier, was light perception only, illustrating dramatically the importance of prompt initiation of HBOT for this disorder (151).

At first glance, outcomes appear to vary widely from the use of HBOT in the treatment of RON, but the delay from the onset of visual complaints until treatment, as well as treatment pressure must be taken into consideration in evaluating these reports. Roden et al reported no benefit of HBOT at 2.0 atm in 13 patients whose delay to treatment was 2 to 12 weeks. Nineteen of the 26 eyes in this study were noted to have disk pallor by the time the patients were referred for evaluation (157).

In contrast, Guy and Schatz noted that two patients who had HBOT for RON started within 72 hours of visual loss had a significant improvement in vision. Vision improved from 20/50 to 20/20 in one patient and from count fingers to 20/40 in the other. HBOT treatment regimen was at 2.8 ATA for 90 minutes once daily x 14 days.¹⁵⁵ The authors emphasize that treatment should be initiated within 48 hours and continued for a full 14 days after restoration

of vision. One of their two patients reported above failed to complete the recommended number of HBOT sessions and suffered a subsequent decrease in vision from 20/40 to 20/300. Two other patients whose HBOT was delayed until two and six weeks after the onset of symptoms had no improvement in their vision (155, 158). Garrott also stresses the importance of beginning HBOT within 2 days for RON (156).

Another paper notes that therapy with HBOT has to be initiated soon after the onset of visual loss to be effective. This paper recommends that HBOT for RON be limited to patients whose symptoms have begun recently and in whom optic nerve pallor has not yet developed. The authors also note that HBOT should be administered at a pressure of at least 2.4 ATA (159).

Boschetti reported a patient with RON that occurred more than 4 years after her radiation therapy that did not respond to steroids and was successfully treated with HBOT. Vision in the left eye had already been completely lost (no light perception) from RON and the right eye was rapidly deteriorating despite the steroid therapy. HBOT was initiated “promptly” for the right eye (exact duration of symptoms not mentioned) with a subsequent marked improvement in the visual field of that eye after 15 days of HBOT (2.2 ATA O₂ for 75 minutes 5 days per week). The author notes that HBOT, though still controversial, seems more promising than any other form of treatment.¹⁶⁰ Other authors have noted that HBOT was effective in stopping the progression of visual loss in patients treated several months after symptom onset. One patient was reported to have stabilization of declining vision after a 14-week delay. The HBOT regimen for this patient was at 2.0 - 2.23 ATA for 60 minutes daily for five weeks (161).

A 63 year-old woman treated with brachytherapy for a choroidal melanoma located

just under the macula in the left eye developed visual loss to the finger-counting level four years after her radiation therapy. Fundus examination revealed both radiation retinopathy and optic neuropathy in the affected eye. Her visual field was severely affected. She received HBOT (2 ATA for 120 minutes x 20 sessions). Two months after treatment, the patient noted marked visual improvement. Although her visual acuity did not change significantly from that immediately after treatment for her macular lesion, her visual field markedly improved. The time from onset of symptoms to HBOT was not mentioned (162).

RON can occur even after stereotactic radiosurgery despite the lower dose of radiation to the optic nerves with this technique. One patient with RON after this procedure suffered visual loss from RON that began 16 months after radiotherapy. HBOT undertaken 6 weeks after the onset of RON was not effective in reversing this patient’s visual loss (163).

There is no other effective treatment for RON at present (155, 164). Lessell in his review of RON states that heparin, warfarin, and corticosteroids are ineffective and that HBOT therapy offers more promise than the alternatives (149). HBOT is often used in conjunction with high-dose corticosteroid therapy (151, 154, 156, 160, 161) and, less commonly, anticoagulation (156, 165). A recent review of RON has noted that both steroids and anticoagulation have been unsuccessful in treating RON (159). Miller states that steroids and anticoagulation are ineffective in treating RON; he also notes the mixed success reported by other authors with HBOT and describes one of his patients who had lost vision from RON in one eye and had MRI findings consistent with early RON in his fellow eye, despite normal visual function and appearance. HBOT was administered according to the protocol described above by Borruat, but was unsuccessful in preventing the development

of clinical RON in the other eye. The patient eventually lost all useful vision in both eyes (152).

The anti-VEGF agent bevacizumab (Avastin) and the prodrug angiotensin-converting enzyme inhibitor ramipiril have shown some promise as emerging treatment options for RON,(148, 164, 166) but their place in the management of this disorder remains to be defined.

Feldmeier and Hampson in their extensive review of the use of HBOT for delayed radiation injury state that the published evidence supports this indication and recommend the use of HBOT for this group of clinical disorders (167). The Hyperbaric Oxygen Committee of the UHMS has approved treatment of RON under the heading of soft tissue radionecrosis (28).

Periorbital Reconstructive Surgery

Gonnering described six patients with challenging periorbital reconstructive surgery who had favorable results from adjunctive HBOT (2.0 ATA for 120 minutes twice a day for 4-5 days). Indications were primarily failing periocular skin flaps and grafts(168). This indication for HBOT has been approved by the Hyperbaric Oxygen Committee of the UHMS (28).

Scleral Necrosis

Pterygium is an actinic condition in which an area of fibrotic tissue extends from the conjunctiva onto the cornea. The disorder is often progressive and may cause ocular discomfort, cosmetic issues, and interference with vision if it extends into the visual axis. Pterygium surgery has a recurrence rate as high as 46% unless preventive measures are incorporated into the surgical excision (169). Preventive measures include beta irradiation, cauterization, topical steroids, thiotepa, mitomycin-C, and conjunctival autograft

(170). Irradiation may result in a small-vessel obliterative endarteritis followed by tissue ischemia and fibrosis. Scleral necrosis is a potentially blinding complication of both beta irradiation and mitomycin-C therapy, since the necrosis may lead to perforation of the globe and endophthalmitis with devastating visual consequences.

Adjunctive HBOT has been shown to reverse this process. One paper reported a patient who developed severe scleral necrosis following pterygium surgery and beta radiation and who was not responding to conventional therapy that included topical antibiotics, topical steroids, lubricants, and patching. HBOT (2 ATA for 90 minutes daily x 14 days) was employed and resulted in marked improvement, first noted after four treatments. The patient went on to make a complete recovery (171). Mitomycin-C may also induce a similar condition and another case report noted that a patient who developed scleral necrosis after mitomycin-C and had likewise deteriorated on conventional therapy was given HBOT (2.5 ATA for 90 minutes daily x 24 days) made a remarkable recovery with improvement noted after day 5 (170).

Radiation-induced scleral necrosis indication for HBOT has been approved by the Hyperbaric Oxygen Committee of the UHMS under the soft tissue radionecrosis heading. Mitomycin C-induced scleral necrosis is not currently addressed in the HBO Committee report (28).

Potential Ocular Indications for HBOT

This section reviews ocular indications for HBOT for which a strong physiological basis exists and/or for which examples have been published documenting HBOT effects in managing these disorders. None of the indications for HBOT in this section have been approved by the Hyperbaric Oxygen Committee of the UHMS at the time of publication (28)

and better evidence defining the role of HBOT is needed in these disorders. As noted earlier, although rapid return of vision is a valuable indicator of efficacy when treating ocular disorders with HBOT, the failure of vision to normalize rapidly does not necessarily indicate a lack of success, especially in disorders such as central retinal vein occlusion and branch retinal vein occlusion, where macular hemorrhage may prevent immediate return of vision. The list of potential ocular indications for HBOT is given in Table 2.

Table 2. Potential Ocular Indications for HBOT

Ischemic Optic Neuropathy
Ischemic Central Retinal Vein Occlusion
Branch Retinal Artery Occlusion with Central Vision Loss
Ischemic Branch Retinal Vein Occlusion
Cystoid Macular Edema Associated with Retinal Venous Occlusion
Cystoid Macular Edema Associated with Post-Surgical Inflammation
Cystoid Macular Edema Associated with Intrinsic Inflammatory Disorders
Periocular Brown Recluse Spider Envenomation
Ocular Quinine Toxicity
Purtscher's Retinopathy
Radiation Retinopathy
Anterior Segment Ischemia
Retinal Detachment in Sickle Cell Disease
Refractory Actinomycotic Lacrimal Canaliculitis
Pyoderma Gangrenosum of the Orbit
Refractory Pseudomonas Keratitis

Ischemic Optic Neuropathy

Non-arteritic ischemic optic neuropathy (NAION) is one of the most widespread visually disabling diseases in the middle-aged and elderly population (172-174). It typically presents as acute unilateral vision loss in patients over 50 years of age. It is characterized by optic disk edema (Figure 2), disk margin hemorrhages, and altitudinal visual field loss in which the inferior field is preferentially affected. This pattern of injury is related to the blood supply to the laminar and retrolaminar optic nerve, which is derived from the short posterior ciliary arteries via the circle of Haller and Zinn, which also has contributions from

the choroidal vessels (174). Most of the blood supply for the prelaminar region of the optic nerve head comes from the short posterior ciliary arteries rather than the peripapillary choroid (174). NAION typically results from perfusion insufficiency in the short posterior ciliary arteries leading to infarction of the retrolaminar portion of the optic nerve.

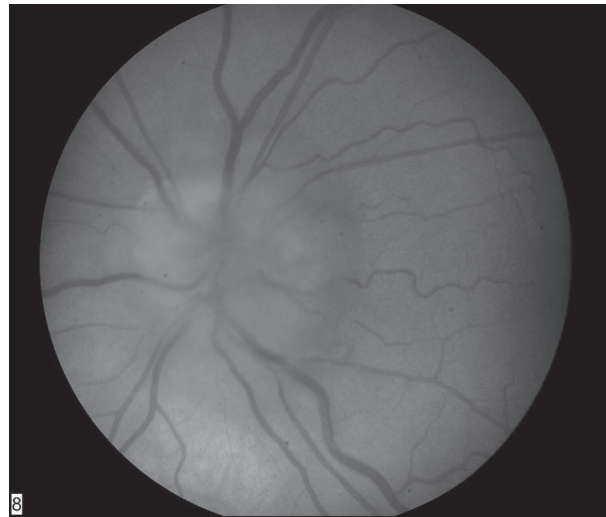


Fig. 2. Anterior Ischemic Optic Neuropathy
Photo courtesy of Dr. Steve Chalfin

Risk factors for NAION include hypertension, diabetes, nocturnal hypotension, and a small-cup-to-disc ratio (175). It has also been associated with the use of erectile dysfunction medications (176). The fellow eye of NAION patients is often sequentially affected. Involvement of the second eye occurs within 3 years in approximately 43% of NAION patients. Treatments employed for NAION have included optic nerve sheath decompression, high-dose steroids, levodopa, carbidopa, and neuroprotective agents, without any modalities being reliably effective to date (173, 175, 177).

The potential for oxygenation of the optic nerve from choroidal branches of the Circle of Haller and Zinn offers a theoretical basis for the use of HBOT in NAION. Reducing intra-axonal optic nerve ischemia

and its resultant edema may interrupt the cycle of microvascular compromise that is thought to occur within the structurally crowded optic disks of patients with NAION (177).

One study reported two NAION patients treated with HBOT (2 ATA for 90 minutes once a day for 18 sessions) and noted improvement in both vision and visual field (178). HBOT was undertaken 3-5 months after the onset of symptoms. The same author had previously published a case series that documented the results of HBOT (2.8 ATA for 60 minutes twice a day for the first three patients, then 2.0 ATA for 90 min daily for the remaining patients for a total of 14-30 sessions) in 9 patients with NAION who had previously been unsuccessfully treated with steroids. He noted that four patients with optic disc atrophy (a sign of long-standing disease) had no improvement with HBOT while 5 other patients without optic atrophy had marked improvement in visual acuity and/or visual field at six-month follow-up. The time between the onset of symptoms and the initial HBOT session ranged from 21 to 84 days (179). A third study from the same first author documented a series of 21 patients (with some overlap from the previous papers) in which 11 control patients were treated with corticosteroids, while the study group received steroids but also got HBOT (2.8 ATA for 60 minutes twice a day for the first three patients, then 2.0 ATA for 90 minutes daily for the remaining patients for 14-30 sessions). The time between the onset of symptoms and the initial HBOT session ranged from 7 to 84 days. Six of ten HBOT patients experienced a marked improvement in visual function, and all but one of these patients had persistent benefit at 6-month follow-up. The authors note that spontaneous improvement in NAION is unusual. Patients with optic atrophy obtained no benefit from HBOT, while those in whom optic atrophy was not evident did improve

(180).

HBOT was used in a 66 year-old woman who presented with a 4-day loss of vision in the right eye. Presenting vision was finger-counting in that eye. She had lost vision in her left eye 3 months previously from an episode of NAION. Fundus examination showed the disk edema and disk margin hemorrhages of NAION. She was treated with HBOT (2.5 ATA for 90 minutes x 5 sessions). Vision improved from finger counting to 6/24 after the second session. No further improvement in vision was observed in the 3 subsequent HBOT sessions, but this improvement remained stable over one year of follow-up. The authors note that: 1) visual acuity OD before treatment was declining and that this decline stopped and vision began to improve immediately after starting HBOT; 2) final vision was better in the treated eye than in the untreated eye; and 3) the patient was legally blind when she entered the chamber, but was not when she left (181).

Arnold reported that 22 eyes of 20 patients with NAION treated with HBOT (2.0 ATA for 90 minutes twice a day for 10 days) showed no benefit compared to 27 untreated controls. Patients were included in this study if they presented within 21 days after their onset of visual loss. The authors' earliest treatment break-out group in these studies was 9 days or less from onset of symptoms and they noted that treatment initiated within 72 hours might have been more effective (177, 182).

Arterial hypotension associated with blood loss during surgery and hemodialysis may also cause ischemic optic neuropathy. Hemodialysis is occasionally associated with dramatic unilateral or bilateral visual loss (183, 184). The etiology of the visual loss in hemodialysis is believed to be hypotension-induced NAION, (184-186) but other etiologies for visual loss in this setting include cerebral infarction (184), Purtscher's type retinopathy (187), and posterior ischemic optic neuropathy

(186). HBOT has been associated with immediate and dramatic return of vision to baseline in a patient who suffered bilateral blindness during hemodialysis. The authors emphasize that early HBOT should be considered for acute visual loss during or immediately after hemodialysis (183).

Fifteen percent of individuals with NAION have been reported to suffer an attack on NAION in the fellow eye during 5-year follow-up (188). Because of the significant potential for NAION to occur in the second eyes of individuals who have already lost vision in the first eye due to this disorder, these patients should be warned to be alert for any decrease in vision in the second eye so that they can seek medical attention promptly and HBOT can be employed in an effort to prevent permanent vision loss.

Arteritic ischemic optic neuropathy (AION) is a related disorder characterized by ischemic damage to the optic nerve associated with giant cell arteritis. The visual loss in this disorder is typically more severe and immediate treatment with high-dose systemic steroids is required to prevent a high percentage of vision loss from occurring in the fellow eye shortly after the index eye (189, 190). Long term tapering and maintenance steroid administration is required to prevent recurrence(189). No reports were found of HBOT being employed in AION, but there is a theoretical rationale for treating this type of ischemic optic neuropathy as well.

Ischemic Central Retinal Vein Occlusion

Central retinal vein occlusion (CRVO) is a relatively common cause of visual loss. Ischemic CRVO with neovascular glaucoma is the most common cause of surgical removal of the eye in North America (191). Risk factors for this disorder include glaucoma, older age, male gender, systemic vascular disorders, and

hyperviscosity syndromes such as multiple myeloma (192). CRVO may also be seen, however, in young adults with no known systemic disease or ocular problems(193). The hallmarks of CRVO are four-quadrant retinal hemorrhage and distended retinal veins (Figure 3). An afferent pupillary defect and severe vision loss are typical of the ischemic variety of CRVO.

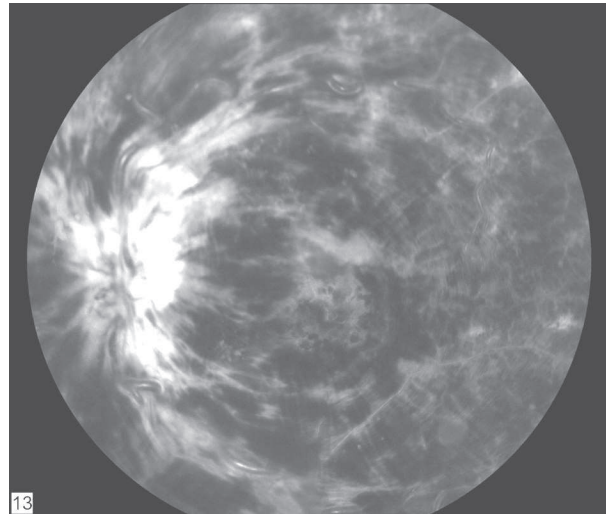


Fig. 3. Central Retinal Vein Occlusion
Photo courtesy of Dr. Steve Chalfin

Vision loss in CRVO may result from macular ischemia, the development of persistent macular edema, and neovascular glaucoma (194). A complicating factor in discussing treatment for CRVO is the need to determine whether one is dealing with ischemic or non-ischemic CRVO. Making this determination may be a clinical challenge, but is crucial because the two entities have different natural histories and outcomes. Nonischemic CRVO does not cause neovascularization and typically has a more benign course, with final visual acuity dependent primarily on the presence and degree of macular edema. Two-thirds of patients with non-ischemic CRVO have final visual acuities of 20/40 or better with no treatment. Some eyes with non-ischemic CRVO, however, may progress to ischemic CRVO (192, 195). 54% of initially non-ischemic CRVO eyes were

reported in one paper to subsequently develop retinal ischemia (192). With ischemic CRVO, there is permanent ischemic damage to the macular ganglion cells, so there is little chance of improvement in visual acuity (195). There is also a significant risk of anterior segment neovascularization, with neovascular glaucoma resulting in 40-50% of cases.¹⁹⁵ Differentiation between ischemic and non-ischemic CRVO may be more difficult than the application of the commonly used criteria of 10 disk diameters of retinal non-perfusion on IVFA (195). The degree of macular ischemia has been found to be a more significant factor affecting the outcome of retinal venous occlusion than macular edema (196). It is important to differentiate ischemic from non-ischemic CRVO when considering invasive therapies such as radial optic neurotomy (197).

The pathophysiology of CRVO is different in several important respects from CRAO. First, the obstruction of the CRV is chronic and is not characterized by the relatively early recanalization and restoration of blood flow seen in CRAO. Hayreh notes: "In both types of CRVO, the retinopathy spontaneously resolves after a variable period. There is marked inter-individual variation in the time that it takes to resolve; it is usually faster in younger than older people (195)." Secondly, the tissue hypoxia produced by CRVO often does not lead to rapid retinal cell death, as CRAO does. This allows the ischemic retinal cells to produce the vascular endothelial growth factors responsible for the neovascularization that is a feature of CRVO, but not typically CRAO. Third, the non-ischemic version of CRVO does not produce macular ganglion cell death, but causes visual loss through macular edema.

The natural history of CRVO has been described by the CRVO Study Group. Visual acuity outcome was found to be largely dependent on visual acuity at presentation, with 65% of individuals presenting with VA 20/40

or better maintaining that level of acuity for the 3-year follow-up period. Individuals with vision 20/200 or less had an 80% chance of having vision at that level or worse at the end of the study. Patients with intermediate levels of visual acuity on presentation had a more variable outcome (198). This paper also noted that one-third of eyes that were initially non-ischemic CRVOs converted to ischemia in the course of the study.

Multiple interventions have been proposed for CRVO. Therapy is often aimed at preventing or reversing the neovascularization that can result in glaucoma, chronic eye pain, and loss of the eye (198). One study postulated that CRVO constitutes a neurovascular compartment syndrome at the site of the lamina cribosa and proposed relieving this pressure by performing a radial incision at the nasal part of the optic nerve head. The authors subsequently did 107 radial optic neurotomies and found that the majority of patients showed rapid normalization of the morphologic fundus findings, with an improvement in visual acuity. The authors noted that surgery performed more than 90 days after the occlusion produced little improvement (199). Another paper studying this technique in 5 patients produced less successful results (200).

Other reports on the therapeutic options for CRVO have been less encouraging, especially with regard to reversing vision loss. Treatments employed in the management of CRVO have included anticoagulants, fibrinolytics, intravitreal corticosteroids, acetazolamide, isovolemic hemodilution, anti-vascular endothelial growth and angiostatic agents, panretinal photocoagulation (PRP), grid pattern photocoagulation, laser-induced chorioretinal anastomosis, and endovascular thrombolysis (194, 201-204). There have been several reports of success in treating CRVO with low-molecular weight heparin (205) and the anti-VEGF agent bevacizumab (191,206).

None of the interventions described above will be useful in restoring vision if the retinal cells have already been irreversibly damaged by hypoxia prior to therapy. The primary benefit of HBOT in ischemic CRVO, then, would be to maintain retinal viability while interventions to restore normal retinal venous outflow are accomplished or spontaneous resumption of flow occurs, although the longer period required for spontaneous resumption of venous flow makes waiting for spontaneous resolution of the impaired retinal blood flow a more problematic choice than in CRAO.

Can HBOT reverse the acute retinal ischemia seen in ischemic CRVO? A recent case report described a 43 year-old male with CRVO OS. Onset of symptoms was two days before presentation. The authors describe the case as an ischemic CRVO with macular edema and retinal hemorrhages, although visual fields were reported to be normal. He was treated with HBOT at 2.4 ATA for 90 minutes on the day of presentation. Vision improved in the affected eye from 20/200 to 20/30 after the first two HBOT treatments. Vision was reported to gradually deteriorate in the time period after HBOT and then to improve again with the next treatment. This observation is an important one because it suggests that the acute administration of HBOT can reverse the retinal cell hypoxia caused by the venous infarct of CRVO, presumably because of the ability of oxygen to diffuse into the retina from the anatomically distinct choroidal circulation that is not affected by the retinal venous occlusion. Daily HBOT was continued for 30 treatments then decreased to 2-3 treatments per week for a total of 60 treatments. Final visual acuity was 20/20 in the affected eye, a remarkable outcome for ischemic CRVO (207). Another report was of a USAF aircraft navigator who presented with a non-ischemic CRVO that progressed to an ischemic CRVO. He was treated with HBOT early in the course of his

disease with return of vision to normal. His vision was reported as 20/17 two years later (208). Less favorable results using HBOT to treat CRVO were reported by Miyamoto, but there was no information available about the interval after onset of the CRVO before HBOT was undertaken in those two studies (196, 209). Gismondi and colleagues reported the use of HBOT to manage CRVO in 3 patients and concluded that it was a useful treatment modality for this disorder (210). HBOT has been mentioned as one of the major therapeutic options in managing CRVO (211).

In summary, there is a strong rationale for HBOT in managing ischemic CRVO and there are case reports documenting success with this treatment modality. As with CRAO, there is likely a window of opportunity beyond which HBOT is less effective, but this window is not well-defined. HBOT may be most effective when used with other measures designed to expedite the restoration of venous outflow. The optimum HBOT treatment regimen for CRVO is not well defined, but both reversal of acute macular ischemia and prevention of neovascular complications from chronic retinal hypoxia should be considered. Outcome measures that should be considered in HBOT for ischemic CRVO should include as a minimum visual acuity, visual fields, and the impact of HBOT on the development of neovascularization and neovascular glaucoma. Although rapid return of vision is a valuable indicator of efficacy when treating ocular disorders with HBOT, the failure of vision to normalize rapidly does not necessarily indicate a lack of success. This is especially true in disorders such as CRVO, where macular hemorrhage may prevent immediate return of vision. If HBOT is effective in preventing hypoxic cell death, vision may improve when the hemorrhage resolves, as has been reported in the hypoxic vasculopathy of high-altitude retinal hemorrhages (212).

The role of HBOT in non-ischemic

CRVO is less clear, especially in view of the more favorable visual prospects in this entity even when untreated. A 57 year-old male with non-ischemic CRVO was treated with 20 sessions of HBOT (2 ATA for 120 minutes) 30 days after the onset of symptoms. After 6 HBOT treatments, his vision improved from 20/250 (20/64 with pinhole) to 20/125-2 (pinhole 20/40). There was no further improvement during the remainder of his HBOT treatments. (Personal communication Dr. RE Moon).

Branch Retinal Artery Occlusion with Central Vision Loss

The presentation of branch retinal artery occlusion (BRAO) is more variable than that of CRAO. If the occluded artery does not supply the central or paracentral visual areas, the occlusion may be clinically silent. 24 of 30 patients with BRAO in one report had visual acuities of 20/40 or better (213). Another study noted that almost 90% of 201 patients with BRAO had visual acuities of 20/40 or better (214). Even when visual acuity is not affected, however, there is typically a permanent visual field defect in the area served by the infarcted retina (1). Neovascular complications of BRAO are unusual but do occur (215). BRAO is seen on ophthalmoscopy as a localized area of whitish opacified retina, although this may develop over the course of hours to days (1). The embolus causing the BRAO may be visible on examination.

Vision loss in BRAO may occasionally be severe. Mason reported five patients with BRAO and severe loss of central vision. He used transluminal neodymium:YAG embolysis to disrupt the embolus and restore flow. All 5 patients had visual acuities ranging from 20/25 to 20/40 the first day after the procedure (216).

If vision loss is severe, HBOT may also have a role in the management of this disorder, with many of the same considerations that apply to CRAO. HBOT must be given

before the affected retina has been irreversibly damaged to have any beneficial effect. A 67 year-old woman with rheumatoid arthritis presented with decreased vision in both eyes for four days. Visual acuity in the right eye was 20/30 and 20/600 in left. She was found to have occlusion of the superotemporal branch of the retinal artery in both eyes and to have arterial sheathing and large cotton-wool patches around both optic discs. IVFA findings were delayed filling of the superotemporal retinal artery in the right eye, no filling in the superotemporal artery in the left eye, and segmental absence of filling in peripheral branches of other major retinal arteries in both eyes. She was treated with HBOT, prostaglandin E1, and urokinase for 2 weeks and had improvement of her vision to the 20/15 level in the right eye and 20/300 in the left (86).

Another series reported 10 patients with BRAO who were treated with HBOT (30 minutes at 2.4 ATA for three sessions on the first day, twice a day on the second and third day, and once daily for at least another four days) in addition to ocular massage, paracentesis, and IV acetazolamide. The authors noted that HBOT seemed to benefit visual acuity in eyes with BRAO (217). In another report, a 32-year old man with a rectal carcinoid and iron-deficiency anemia presented two days after the onset of vision loss. He was found to have a visual acuity of count-fingers in his left eye and fundus findings consistent with BRAO to include milky-white edema in the posterior pole except for the upper temporal area and a cherry-red spot at the fovea. He was treated with stellate ganglion block, HBOT, and ferrous sulfate, but vision improved only minimally (218).

Ischemic Branch Retinal Vein Occlusion with Central Vision Loss

Branch retinal vein occlusion (BRVO) is the second most common cause of retinal

vascular dysfunction after diabetic retinopathy (219). Population-based studies have reported a prevalence of 0.6% (220) and 1.6% (221) in patients over 43 and 48 years old respectively. Most BRVO's occur at arteriovenous crossing sites (222-224) where the artery and vein share a common adventitial sheath. Diseases such as atherosclerosis and hypertension lead to stiffening of the artery and may result in complete or partial compression of the vein.

Presenting symptoms of a BRVO may include sudden painless decrease in vision or scotoma of the affected eye. Fundus findings of BRVO may be found incidentally on routine exam if the affected region does not interfere with the patient's central vision. Early fundus findings include intraretinal hemorrhages and cotton wool spots within the affected region. Macular edema often develops as a result of the venous stasis. The superotemporal quadrant is the region most commonly involved.

Visual outcome after BRVO is variable, with prognosis depending on the site of occlusion, size of the vessel occluded, and the integrity of the perifoveal capillary vascular arcades (225). Like CRVO, visual loss in BRVO results from the short or long term effects of macular edema, macular non-perfusion, or the consequences of neovascularization (219, 226-230). Unlike neovascularization of the iris seen in CRVO, chronic ischemia after a BRVO preferentially stimulates retinal neovascularization that may result in vitreous or intraretinal hemorrhages and tractional retinal detachments (231, 232).

After a critical evaluation of the literature, McIntosh et al reported a lack of strong evidence for many of the interventions advocated for the treatment of BRVO (231). Cystoid macular edema is discussed in the next section. With regard to the neovascular complications of BRVO, PRP has also been reported to provide some benefit (226, 233). Anti-VEGF agents may also be of use in preventing neovascularization. Although there

are reports of HBOT being used for post-retinal vein occlusion cystoid macular edema (discussed below), no reports were found of HBOT being used for BRVO with the primary goal of therapy being to reverse hypoxic macular cell death. The same therapeutic rationale exists for this use as with ischemic CRVO if there is central vision loss due to macular non-perfusion in BRVO.

Cystoid Macular Edema (CME)

Associated with Retinal Vein Occlusion

Cystoid macular edema (CME) is the cystic accumulation of fluid in the macula. Gass originally described CME as the leakage of fluid from perifoveal capillaries that was low in lipid and protein (234) with secondary polycystic expansion of the extracellular spaces (235). CME frequently complicates occlusion of a central or branch retinal vein. If the edema is severe or chronic, it may cause permanent visual loss and retinal damage (236). CME rates after retinal vein occlusions (RVO) of between 30 and 60% have been reported (227, 228, 233, 236, 237). CME may result from retinal capillary engorgement in RVO with the increase in hydrostatic pressure driving fluid out of the retinal capillaries (238) or from increased capillary permeability (239), or a combination of these two mechanisms.

CME typically presents with decreased vision, metamorphopsia (image distortion) or scotoma. Slit-lamp exam findings include loss of the foveal depression, retinal thickening and/or multiple cystoid spaces. Fluorescein angiography in CME shows early foveal leakage with expansion and coalescence over time. In later phases, a "flower-petal" pattern of hyperfluorescence is seen as a result of accumulation of dye within the cystoid spaces.

Multiple interventions have been attempted for the treatment of RVO-associated macular edema. Medical treatments have included the use of carbonic anhydrase

inhibitors (CAI), anti-VEGF agents and topical or intravitreal steroids (240-250). Intravitreal triamcinolone has been shown to improve vision in CME from BRVO and non-ischemic CRVO (251-260). However, in most cases the effect was not sustained and required repeat injections for recurrent edema. Potential complications of intravitreal steroid injections include an increase in intraocular pressure, cataract formation, endophthalmitis, injection-related vitreous hemorrhage and retinal detachment.

A surgical option for BRVO is pars plana vitrectomy (PPV) with lysis of the common adventitial sheath at the site of the affected crossing vessels, thereby relieving the venous compression and potentially reducing hydrostatic pressure and CME (261). The ability of PPV with sheathotomy to improve visual acuity and CME after BRVO has been supported by other reports (262-266). There are also studies that question its efficacy (267, 268). Grid argon laser photocoagulation for CME after RVO is different from previously described PRP in that the laser spots are smaller and delivered with a lighter intensity only within the affected region. This therapy is thought to work by improving RPE barrier function (269) or reducing retinal ischemia (270). Significant side effects of grid laser treatment include paracentral scotoma and inadvertent treatment of the fovea with central vision loss. The Central Retinal Vein Occlusion Study Group evaluated the effect of grid laser photocoagulation on visual acuity for patients with CME associated with ischemic or non-ischemic CRVO. They reported angiographic reduction of the CME, but no improvement of visual acuity and therefore did not recommend grid laser treatment for CRVO patients (269).

The Branch Retinal Vein Occlusion Study Group found a benefit from grid laser photocoagulation in patients with BRVO of more than three months duration, macular edema and visual acuity of <20/40 (219). Some

additional reports have supported the efficacy of grid laser treatment for BRVO-associated macular edema, ²⁷¹⁻²⁷³ while others did not (274, 275). Grid laser photocoagulation is currently the only intervention for BRVO-associated macular edema that is supported by Level I evidence. Grid laser photocoagulation is not indicated for predominantly ischemic maculopathy after RVO (269, 276). Miyamoto noted that the severity of macular ischemia better determines visual prognosis after HBOT than the degree of macular edema (196).

A number of reports have shown HBOT to be of benefit in RVO-associated CME (196, 209, 277-282). HBOT for BRVO-associated CME has been noted to have a more favorable outcome than for CRVO (196, 209). In many reports, visual acuity has been noted to improve rapidly upon the initiation of HBOT, even when other treatment modalities were previously attempted (196, 209, 277-280, 282). Some of these studies reported an improvement of foveal leakage on fluorescein angiogram that correlates to the visual improvement, (196, 209, 282, 283) whereas others show improved visual acuity despite continued macular edema by IVFA testing (280, 284). Hyperoxic vasoconstriction may produce a decrease in RVO-associated CME through reduction of retinal blood flow and decreased retinal venous pressure. HBOT may also reduce the production of VEGF and thereby decrease retinal vascular permeability.

There are potential benefits of HBOT over grid laser photocoagulation. Laser treatment may cause a permanent scotomas and this therapy is not undertaken for 3 months after the RVO to avoid its potential complications in those patients who might spontaneously resolve. HBOT offers a relatively safe treatment option for the 3-month time frame after disease onset and may be repeated if necessary without any permanent visual consequences. If no improvement has been noted with HBOT, grid laser could be added as an adjunct after three

months has elapsed.

As with intravitreal injections of steroids and anti-VEGF agents, there are reports of CME recurrence after HBOT, (280, 283, 285) sometimes with vision regressing back to pre-treatment levels and at other times with only slight regression from the improved vision obtained after HBOT.

Cystoid Macular Edema Associated with Post-Surgical Inflammation

CME may complicate surgical procedures such as cataract extraction, Nd:YAG capsulotomy, and panretinal photocoagulation. CME occurs in approximately 1% of cataract extraction patients, but the incidence may be as high as 20% if the surgery is complicated by posterior capsule rupture and vitreous loss (276). Available therapy for post-surgical CME includes non-steroidal anti-inflammatory agents (NSAIDs), carbonic anhydrase inhibitors, steroids (topical, intravitreal, and periocular), and immunomodulators (276).

HBOT may be a valuable adjunct to the management of patients whose CME does not respond to these measures or in whom side effects have required discontinuation of therapy. Pfoff and Thom reported five patients with chronic CME documented by decreased visual acuity to the 20/40 level or worse and findings consistent with CME on IVFA. All patients had undergone cataract extraction/IOL implantation 7-11 months prior to HBOT (2.2 ATA for 1.5 hours twice a day for 7 days, then 2 hours once a day for the next 14 days). All five patients showed significant improvement in visual acuity with only mild regression upon follow-up, whereas three control patients treated with prednisolone acetate and indomethacin drops did not improve over a three-month treatment period (286). The authors proposed that vasoconstriction of the perifoveal capillaries serves to bring the damaged endothelial junctional complexes closer together, allowing

them to repair themselves and thereby prevent further leakage (286).

Ishida et al reported 12 eyes of CME treated with HBOT (2 ATA for 60 minutes daily for 2-4 weeks). Eight of the cases resulted from BRVO and four from cataract surgery. Seven of the eyes had an improvement in vision as a result of the HBOT (285).

Cystoid Macular Edema Associated with Intrinsic Inflammatory Disorders

Intraocular inflammation may result from localized ocular disorders as well as in association with systemic inflammatory disorders (HLA-B27-associated inflammation, sarcoid, tuberculosis, Lyme disease). Chronic CME is the most common cause of significant visual loss in patients with intraocular inflammation. The pathogenesis of CME in uveitis is not completely understood, but may result from dysfunction of either the inner or the outer blood-eye barrier. Untreated uveitic CME tends to cause progressive injury to the macula (287). Treatment options for CME associated with intrinsic inflammatory disorders include the agents noted above for post-surgical CME (276, 287). Anti-VEGF agents have been used with success in this disorder. Five of 13 patients with uveitic CME refractory to other treatments treated with intravitreal bevacizumab had an improvement of vision of 2 or more lines (287).

HBOT may be useful in this disorder as well. Miyake treated two patients with poor vision from CME; one was from a CRVO and the other from sarcoid uveitis. HBOT was administered at 2 ATA for 60 min and then 3 ATA for 60 minutes twice a day for 25 days. The author noted that: 1) both patients improved markedly with HBOT; 2) both patients had recurrence of CME when HBOT was discontinued; 3) both patients also improved on acetazolamide therapy; and 4) the pattern of macular hyperfluorescence improved with

acetazolamide, but not with HBOT, leading him to suggest that the two therapies had different mechanisms of action (280).

HBOT (2 ATA for 60 minutes daily x 14 to 17 days) provided little lasting benefit in 11 eyes with CME secondary to uveitis, but it was noted that one individual with uveitis of recent onset had a sustained visual improvement after HBOT (288). HBOT (3 ATA for 75 minutes five times a week for 5 weeks) was used to treat a 46 year-old woman with bilateral posterior uveitis and vitritis. She had previously been treated with high-dose steroids, acetazolamide, cyclosporine, and grid laser therapy without success. Her vision prior to HBOT was 20/200 OD and 20/80 OS. HBOT resulted in visual improvement to 20/100 OD and 20/40 OS (289). Although the HBOT had to be repeated to provide continued benefit in this patient, when one eye is legally blind and the other has impaired vision, repeated HBOT may be a very useful therapeutic option when other treatment modalities have been unsuccessful.

Periocular Brown Recluse Spider Envenomation

Brown recluse spider bites may cause local tissue necrosis. Therapy includes dapsone, antibiotics, and steroid administration as well as HBOT. A case of brown recluse bite to the lower eyelid was treated using these modalities and the patient achieved complete recovery (290).

Ocular Quinine Toxicity

Bilateral amaurosis (loss of vision) is a common finding in quinine toxicity, typically occurring when serum levels are over 10 mg/liter (291, 292). Visual loss usually occurs within 24 hours of ingestion of a toxic dose. Tissue hypoxia is thought to be a factor in this disorder, but direct retinal toxicity may be present as well. Although the natural course is usually return of vision, permanent visual

loss may occur (293, 294). Wolff reported two patients with quinine toxicity that presented with bilateral no light perception visual loss and were treated with HBOT (2.4 ATA for 90 minutes x 1 treatment.) Both patients had excellent return of vision shortly following the HBOT. Whether vision would have returned without the HBOT is not known (293). The authors endorse the use of HBOT as a relatively safe therapeutic modality that may help to favorably alter the disease course.

Purtscher's Retinopathy

Purtscher's and Purtscher's-type retinopathy is the term applied to a specific type of vision loss that occurs after significant trauma, acute pancreatitis, chronic renal failure, autoimmune diseases, amniotic fluid embolism, and periocular injections (1). Purtscher's may occur in patients with pancreatitis before they develop abdominal symptoms of this disorder (295, 296). The vision loss is accompanied by a fundus picture that includes large cotton-wool spots, hemorrhages, retinal edema (Figure 4). IVFA typically shows arteriolar obstruction. Activated complement with secondary granulocyte aggregation and leukoembolization may play a part in this disorder (1). Spontaneous visual recovery of at least two Snellen lines is seen in approximately half of cases (297).

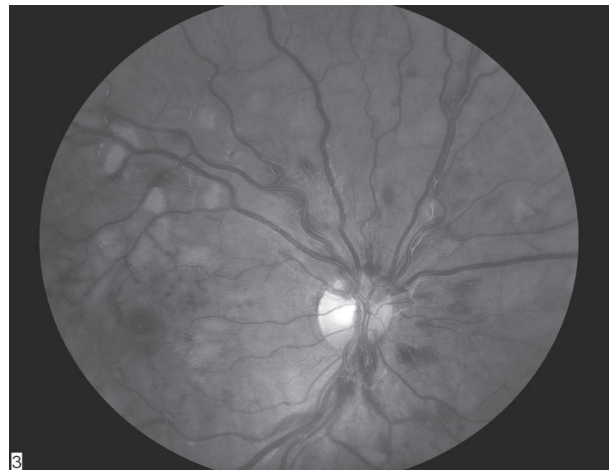

Fig. 4. Purtscher's Retinopathy
Photo courtesy of Dr. Steve Chalfin

There is no effective therapy for this disorder at present (298).

Lin et al reported a patient with Purtscher's retinopathy secondary to chest trauma whose visual function and retinal appearance improved after multiple sessions of HBOT (299).

Radiation Retinopathy

Radiotherapy of head and neck tumors in the vicinity of the eye may result in radiation retinopathy as well as radiation optic neuropathy. Radiation retinopathy was first reported in 1935 (300) and occurs months to years after retinal irradiation. This disorder clinically resembles diabetic retinopathy with retinal hemorrhages, cotton wool spots, lipid exudates, and capillary non-perfusion on IVFA (301) (Figure 5). Although the threshold dose for radiation retinopathy is typically considered to be 2,500 to 3,000cGy, it has been reported after doses of 500 to 1,500 cGy (301). Retinal neovascularization and vitreous hemorrhage may ensue. Laser panretinal photocoagulation has been employed successfully to manage this disorder (301).

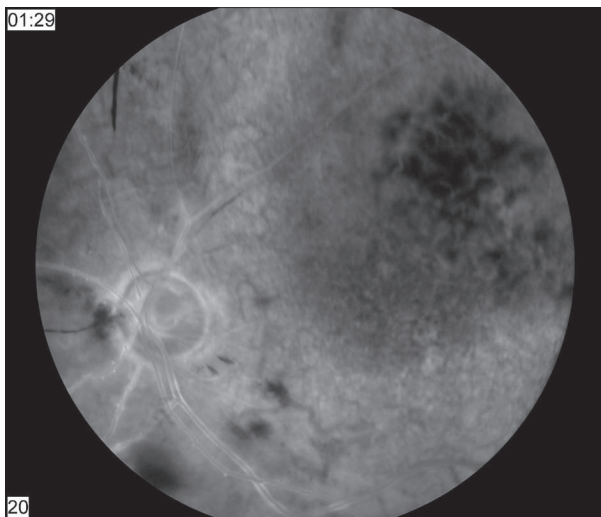


Fig. 5. Radiation Retinopathy and Choroidal Melanoma
Photo courtesy of Dr. Steve Chalfin

One patient with both radiation optic neuropathy and radiation retinopathy was

successfully treated with HBOT. As described in the section for RON, she was treated with brachytherapy for a choroidal melanoma located just under the macula in her left eye developed. Her vision was poor after the radiation due to the location of the tumor in the posterior pole, but she presented with marked decrease in her visual field 4 years after treatment. She received HBOT (2 ATA for 120 minutes x 20 sessions). Although her visual acuity did not change significantly from that immediately after treatment for her macular lesion, her visual field improved markedly. The time from onset of symptoms to HBOT was not mentioned (162).

Anterior Segment Ischemia

Strabismus surgery entails detaching selected extraocular muscles from the globe and re-attaching them in a slightly different location to improve the alignment of the eyes. Anterior segment ischemia (ASI) is an uncommon but potentially serious complication of this surgery. ASI became recognized as a clinical syndrome in the 1950s (302). It is seen in approximately 1 out of every 13,000 strabismus operations (303). Blood supply to the anterior segment of the eye is provided by the long posterior ciliary arteries (approximately 30%) and the anterior ciliary arteries which travel anteriorly in the rectus muscles (approximately 70%) (302). ASI results from the anterior ciliary vessels being disrupted as the extraocular muscles are surgically detached and repositioned. The first pathological specimen diagnosed with ASI was obtained in 1954 from a 76 year-old male who developed a blind, painful eye after retinal detachment surgery in which the lateral rectus muscle was disinserted. The changes seen on histology were consistent with ischemic damage (302). ASI is typically seen when three or more extraocular muscles are operated on in the same procedure, but may occur with two-muscle surgery (304). Children have little risk

of developing this complication, while adults with cardiovascular disease are at higher risk (302).

Patients with ASI present with pain and decreased vision several days after their surgery. Eye examination may reveal striate keratopathy, iris atrophy, immobile pupil, posterior synechiae, cataract, and anterior uveitis with cells and flare in the anterior chamber (302, 305).

Systemic and topical steroids are used to treat ASI. Most patients have good recovery of visual acuity with steroid therapy. Cycloplegics are often used to decrease the pain of ciliary spasm that may accompany ASI (302, 304). Performing strabismus surgery in stages, so that collateral circulation has a chance to develop between surgeries, may help to prevent ASI; using botulinum toxin as an alternative or adjunct to rectus muscle surgery for strabismus is also an effective preventive measure (302).

HBOT has been shown to increase the oxygen tension in the anterior chamber (21) and therefore has potential as treatment option for anterior segment ischemia. In a 1987 paper, believed to be the first report of the use of HBOT to treat anterior segment ischemia, de Smet and his colleagues noted that HBOT (2.5 ATA O₂ for 90 minutes a day, delivered with 5-minute air breaks after each 30 minutes, for 7 days) was successful in treating a patient who presented with anterior segment ischemia. Systemic steroids were withheld from this individual because of a history of tuberculosis (303). HBOT may be an option for individuals with severe ASI that does not respond to steroids or for individuals in whom steroids are contraindicated.

Retinal Detachment in Sickle Cell Disease

Patients with sickle cell disease experience obliteration of retinal arterioles and venules and develop areas of retinal avascularity. This may result in proliferative

vitreoretinopathy, which in many cases progresses to retinal hole formation and retinal detachment. These patients do poorly with standard scleral buckling procedures to repair their detachments, with anterior segment ischemia nullifying what would otherwise be successful surgery (306, 307).

Freilich and his colleagues performed 3 scleral buckling procedures in a hyperbaric chamber with the patient breathing 100% oxygen at 2 ATA. The percentage of sickled red blood cells in one patient decreased from 10% at the start of the procedure to 3.5% at the end of two hours. All patients treated using this unique surgical approach had anatomical success (no recurrence of the detachment) and improvement in their vision 6 to 12 months after their surgery (306, 307). Five additional patients reported by the same author using hyperoxic conditions for surgery also had good results from HBOT (308). The author subsequently provided two year follow-up on these eight patients and reported that their retinas had all remained completely attached and that no new retinal tears had developed. Visual acuity improved in all six of the patients who had had a decrease preoperatively (309). The author concludes that this remarkable success in these difficult surgical cases “merits the continued use of this technique in these difficult cases of detachment of the retina (309).”

Refractory Actinomycotic Lacrimal Canaliculitis

Actinomyces israelii is an anaerobic organism that frequently causes canaliculitis, manifest clinically by inflammation over the medial aspect of the lower eyelid and a characteristic “sulfur-granule” discharge from the inferior punctum. This disorder is usually responsive to penicillin therapy, both systemic and in repeated irrigation of the canaliculus. Surgical evacuation may also be required. Shauly reported a patient in whom a

culture-proven *Actinomyces canaliculitis* was unresponsive to 4 weeks of these measures and who did not improve until HBOT (2.5 ATA for 90 minutes six days a week x 24 sessions) was undertaken. The patient's signs and symptoms resolved promptly after the institution of combined antibiotic/HBOT therapy (310).

Pyoderma Gangrenosum of the Orbit

Pyoderma gangrenosum is an uncommon inflammatory skin disorder associated with inflammatory bowel disease and arthritis. It is characterized by its bluish color, exquisite painfulness, and potential to cause extensive tissue necrosis. It is uncommon in the periocular region, but Newman reported a case in which the lower lid lesion became extremely painful and relentlessly progressive, destroying orbital tissue, perforating the cornea, and eventually requiring evisceration of the eye. Oral and intralesional steroids, improved control of underlying diabetes, and oral clofazimine all failed to produce clinical improvement. The author used four HBOT sessions before eye evisceration followed with ten sessions of HBOT after the surgery. The patient recovered after the surgery and HBOT (311).

Refractory Pseudomonas Keratitis

Chong described a 30 year-old white female with culture-proven soft contact lens-associated *Pseudomonas* keratitis who was getting progressively worse despite topical, oral, and intravenous antibiotics. On her third day after admission, she was begun on a course of HBOT (2.0 ATA for 90 minutes daily). She began to improve after the addition of HBOT to her regimen and 24 hours after her first HBOT treatment, her vision had improved from count fingers to 6/24. HBOT was continued for two more days with progressive improvement and the patient was discharged after six days with a visual acuity of 6/9. Her vision subsequently improved to 6/6 (312).

Other Reported Uses of HBOT

This section contains a number of ocular indications for HBOT for which a theoretical basis for the usefulness of HBOT exists and/or case reports have been published documenting the use of HBOT in managing these disorders. The evidence for these indications is considered to be less strong than that for the disorders listed in the previous two sections. None of the indications for HBOT in this section are approved by the Hyperbaric Oxygen Committee of the UHMS at this time (28). The list of other reported uses for HBOT is summarized in Table 3.

Table 3. Other Reported Uses of HBOT for Ocular Disorders

- Diabetic Retinopathy
- Ocular Manifestations of Multiple Sclerosis
- Retinitis Pigmentosa
- Macular Hole Surgery
- Retinal Detachment
- Uveitis
- Corneal Alkali Burns
- Hydroxyapatite Orbital Implants
- Glaucoma
- Corneal Neovascularization
- Tobacco-Alcohol Amblyopia
- Secondary Keratoendotheliosis
- Sickle Cell Hyphema
- Central Serous Retinopathy

Diabetic Retinopathy

Diabetic retinopathy (DR) is the leading cause of blindness for Americans in the 20-64 year-old age group. The underlying pathophysiology is believed to be an endothelial vasculopathy characterized by loss of pericytes and basement membrane thickening caused by sustained exposure to hyperglycemia (1). Vision loss in diabetic retinopathy can be caused by retinal edema, retinal or optic nerve neovascularization, and/or ischemic macular changes. Elevated levels of vascular endothelial growth factor (VEGF) have been found in both the proliferative and non-proliferative types

of diabetic retinopathy (8). Treatment options for DR and diabetic macular edema (DME) include blood sugar control, laser PRP, grid laser therapy, intravitreal triamcinolone, and intravitreal anti-VEGF agents.

Improvement of a patient with DME from 20/125 in the right eye and 20/320 in the left to 20/63 and 20/160 respectively was noted after HBOT. A decrease in foveal thickness accompanied the improvement in vision. The HBOT was administered in 14 sessions at unspecified pressure/time over 1 month. DME recurred several times in the succeeding months, but each time improved after repeat HBOT. The authors attributed the success of HBOT in this patient to either the hyperoxygenation of the macular tissue or constriction of the retinal vessels (313).

Twenty-two eyes of eleven patients with DME were treated at 2 ATA for one hour twice a day for two weeks and then once a day for the third week. Visual acuity improved by two lines or more in 15 eyes (68%) after HBOT. The improvement in vision diminished over time but at the end of follow-up was still better than pre-treatment. Static visual perimetry was also noted to improve in 76% of eyes (314).

Krott reported five patients (seven eyes) with macular edema (3 diabetics, 1 with CRVO, and 1 with BRVO) treated with HBOT (2.4 ATA for 30 minutes per day x 10-30 treatments). At 15 month follow-up, the mean increase in visual acuity after HBOT was 3.5 lines. Other treatments for macular edema were employed as well (laser, acetazolamide, hemodilution), but HBOT was used after most other approaches had failed (278).

Haddad reported no improvement in three patients with “advanced diabetic retinopathy” treated with HBOT (2 to 3 ATA for periods of 1 hour each) and noted that none of these three patients demonstrated any appreciable change in visual acuity, retinal pathology, or visual fields (17).

A major issue in treating this very common disorder with HBOT is its chronicity. HBOT would likely have to be undertaken on a long-term basis to provide a sustained benefit.

Ocular Manifestations of Multiple Sclerosis

HBOT (2 ATA for 90 minutes daily x 5 days per week for a total of 20 sessions) has been reported to result in improvement in the visual manifestations of MS.³¹⁵ Several review articles, however, have found HBOT (typically given in 20 treatments at 1.75-2.5 ATA, daily for 4 weeks) to be of little value in treating this chronic, progressive neurological disease (316, 317). Neiman observed that ten patients with long-standing MS treated with HBOT (2 ATA for 90 minutes daily x 20 exposures) had a small but statistically insignificant improvement in their visual evoked potentials over that seen in the control group of 9 patients (318). He also noted that subsequent deterioration of their MS occurred more often in the treatment group than in controls at 6-month follow-up.

HBOT is accepted by the Department of Health in the United Kingdom as a modality for MS (319).

Retinitis Pigmentosa

Retinitis pigmentosa (RP) is a heterogenous group of retinal disorders characterized by slowly progressive degeneration of the photoreceptor cells (the rods and cones). Although the majority of RP cases are inherited as X-linked or dominant, approximately 40% of cases are isolated, with no other family members affected. Metabolic factors within the retina may also contribute to the progression of cell death (10). The early stage of RP is often detectable only by the presence of an abnormal electroretinogram. (ERG) Loss of visual field occurs later, with the peripheral field being affected first. Affected individuals lose visual field at rates of 4 to 18%

per year (320). Symptoms progress from light/dark adaptation difficulties to progressive loss of peripheral vision until only a central tunnel of vision remains.

It has been suggested that HBOT may be useful in slowing the progress of RP. One study showed a statistically significant improvement or stability in ERG in 24 patients who received HBOT (2.2 ATA for 90 minutes on a tapering regimen from five times a week for one month to one week a month for 11 months to one week every 3 months for the balance of two years) compared to controls (321). This improvement in retinal ERG did not correlate with an improvement in visual acuity, but this would not be expected when HBOT is performed before the disease has reached end-stage, since the loss of vision moves from peripheral to central with the central island typically being the last sector of the visual field extinguished.

Skogstad reported a 26 year-old man with RP treated with HBOT (2.4 ATA for 97 minutes five days a week x 4 weeks) and noted that he had improvement of his lateral vision at the conclusion of therapy (322).

Oxidative stress, however, has been implicated as potentially contributing to the degenerative process and antioxidant supplements proposed as one possible therapeutic approach to RP. Baumgartner believes that HBOT is likely to be associated with considerable risk of increased oxidative damage to the retina in RP patients. Additionally, HBOT given acutely is unlikely to arrest the process of a disease that is chronic and progressive (320).

Macular Hole Surgery

Macular holes are caused by traction on the retina produced by fibrous attachments to a detaching vitreous body. Vitreoretinal surgery is indicated in some cases to close these holes. One of the complications of this surgery is temporal visual field defects (TVFD). A study

reported that 7 patients with TVFD following macular hole surgery were treated with HBOT while a control group of 5 patients were not. Those patients who received HBOT for a 20-day course had significant recovery from their TVFD (to 91.6% of the preoperative VF area), while those in the control group did not experience this improvement (remained at 79% of their preoperative VF area). Visual acuity was not affected by the HBOT (323).

Retinal Detachment

In experimental retinal detachment, retinal hypoxia caused by the separation of the retina from its normal source of nutrients is a factor in inducing the death of photoreceptor cells. Supplemental normobaric oxygen at 70% was found to reduce cell death in a cat model of retinal detachment (324). Oxygen in this model was also found to limit the proliferation and hypertrophy of Muller cells that are responsible for the proliferative vitreoretinopathy that may complicate retinal detachment surgery (325). No papers were found that used HBOT for retinal detachment in humans, but a theoretical basis exists for this use.

Uveitis

One report of a rabbit model of uveitis noted that HBOT was as effective as topical steroids used alone in treating this disorder and enhanced the efficacy of topical steroids when the two modalities were used together (326).

Corneal Alkali Burns

Hirst et al studied the usefulness of HBOT in corneal alkali burns using a rabbit model. HBOT was administered at 2.4 ATA for 60 min daily for 21 treatments in treating this injury. Using the time to corneal perforation as an end point, no benefit was found from HBOT (327).

Hydroxyapatite Orbital Implants

Ng reported that HBOT did not increase hydroxyapatite vascular ingrowth and possibly delayed fibrovascular maturation in normal sockets in a rabbit model (328). Debacker and his co-authors reported that HBOT did not diminish the likelihood of exposure of hydroxyapatite orbital implants in irradiated orbits in a rabbit model, but did enhance fibrovascular ingrowth in normal orbits after enucleation (329).

Glaucoma

The optic neuropathy of glaucoma has been postulated to result at least partly from optic nerve ischemia and transient improvements in visual fields have been reported in glaucoma patients treated with HBOT (2.0 ATA for 90 min/day x 5 days per week for a total of 30 sessions) (330, 331).

Corneal Neovascularization

Henkind noted that a single prolonged hyperbaric oxygen exposure of 17-37 hours at 1.5 to 2.0 ATA did not produce a change in corneal neovascularization in a rabbit model (332).

Tobacco-Alcohol Amblyopia

Kern and his co-authors have reported that HBOT at 2 ATA (duration and number of treatments not noted) was successful in achieving a “definite improvement” in three of four patients with tobacco-alcohol amblyopia, a type of optic neuropathy (333).

Secondary Keratoendotheliosis

Corneal endothelial dysfunction ranging from mild post-operative corneal edema to bullous keratopathy and opacification of the cornea (secondary keratoendotheliosis) may occasionally complicate cataract removal surgery, although this complication has been reduced by currently used phacoemulsification

techniques and the routine use of viscoelastics during cataract surgery. Recupero reported that hyperbaric oxygen therapy produced improved visual acuity in all twelve of the study patients compared to improvement in only 33% in the 21 control patients (334).

Sickle Cell Hyphema

Approximately 10% of the African-American population in the United States has a sickling hemoglobinopathy. These individuals are more prone to the complications of corneal blood staining and secondary glaucoma should they suffer traumatic hyphema. One report noted that exposing rabbits to oxygen at 2 ATA for two hours increased the PO₂ in the anterior chamber from 63.5 mmHg to over 500 mmHg. This increase was sufficient to prevent or reverse the sickling of injected intracameral human erythrocytes containing sickled hemoglobin. The percent of sickled red cells was 4.1% in the rabbits exposed to hyperoxia compared to 35.7% in controls (335).

Central Serous Retinopathy

Haddad treated a single CSR patient with HBOT (2 ATA for 15 minutes and 3 ATA for 30 minutes) with no change in the patient’s visual acuity or his relative central scotoma (17).

HBOT and the Eye – General Considerations

Many of the general considerations regarding HBOT mentioned previously also apply to HBOT for ocular indications. There are several additional considerations for HBOT as it applies to the eye:

- 1) Patients with acute painless loss of vision that meets the criteria for emergent HBOT outlined below should be triaged rapidly in the emergency department and referred for HBOT as soon as possible to optimize the chance for successful treatment.

2) Normobaric oxygen should be given promptly to patients with eye disorders appropriate for emergent HBOT. This may maintain the viability of affected ocular tissues pending HBOT or, in some cases, provide definitive treatment.

3) Pulmonary oxygen toxicity may complicate HBOT, especially with longer treatment regimens. The timing of multiple HBOT sessions when required must be titrated to minimize pulmonary oxygen toxicity while preventing permanent vision loss from tissue hypoxia.

4) Visual acuity alone is an inadequate outcome measure for HBOT undertaken for ocular disorders that present with loss of vision. Automated measurement of visual field should be performed as well.

5) Education is needed to alert patients and physicians to the vision-saving benefits of HBOT for certain disorders. Eye patients who suffer acute vision loss must appreciate the need to get to the hospital emergency department as soon as possible. Patients who have lost vision in one eye from any cause should be informed to seek medical attention immediately if they suffer an acute loss of vision in their only seeing eye. Individuals who have suffered CRAO, CRVO, or NAION in one eye should in particular be warned to seek emergent medical attention should vision decrease in their fellow eyes. Similarly, individuals at risk for RON must be warned to seek attention immediately for any post-radiation visual loss.

6) HBOT receives little attention in Ophthalmology training programs. For instance, the “The Wills Eye Manual” is a popular handbook produced by the house staff and attendings at one of the leading eye hospitals in the United States that is used as a quick reference for common ocular disorders. The 2008 version of this handbook does not list HBOT in the index (336). Wills is not unusual in this respect, despite the ten ocular indications

for HBOT discussed above that are approved by the HBO Committee of the UHMS where HBOT may be lifesaving or preserve threatened vision. A recent article in Survey of Ophthalmology may reflect a growing awareness of the utility of this modality in Ophthalmology (337).

7) Although rapid return of vision is a valuable indicator of efficacy when treating ocular disorders with HBOT, the failure of vision to normalize rapidly does not necessarily indicate a lack of success. As previously discussed, this is especially true in disorders such as central retinal vein occlusion, where macular hemorrhage may prevent immediate return of vision.

Emergent HBOT in Patients with Acute Vision Loss

The differential diagnosis in patients who present with acute painless loss of vision includes CRAO, retinal detachment, CRVO, BRVO, BRAO, choroidal neovascularization with subretinal hemorrhage, vitreous hemorrhage, and ischemic optic neuropathy. It may take hours to days and an Ophthalmology consult to establish a definitive diagnosis for the vision loss. In the interim, whatever potential that may exist to restore vision with HBOT might be lost.

Considering that at least five of the relatively common ocular disorders producing acute, painless loss of vision have the potential to benefit from HBOT, the authors propose the following approach to managing patients with acute loss of vision:

1) Patients who present with acute painless loss of vision of recent onset should be triaged as “*Emergent.*”

2) Visual acuity should be checked immediately. If vision with the patient’s current spectacles or contact lenses is 20/200 or worse, cannot be improved significantly with pinhole, and the patient meets the other criteria listed in Table 4, then (s)he should be considered for

emergent HBOT.

3) The patient should be started immediately on supplemental normobaric oxygen at the highest possible inspired oxygen fraction.

4) If vision is restored by oxygen at 1 ATA and HBOT is not necessary, maintain on oxygen at an inspired fraction sufficient to maintain the improvement in vision until ophthalmologic consultation can be obtained. Titrate supplemental oxygen as clinically appropriate thereafter.

5) If visual acuity does not improve to near baseline within five minutes after starting supplemental oxygen and there are no contraindications to HBOT, refer for emergent HBOT. Maintain supplemental oxygen until HBOT is initiated. Even though vision has not responded to the normobaric oxygen, the increased oxygenation produced by this intervention may be helpful in maintaining retinal viability until HBOT is initiated.

6) Compress to 2.4 ATA on 100% oxygen.

7) If no response within 5 minutes,

compress to 2.8 ATA and perform USN Treatment Table 6. (If the diagnosis is DCS or AGE, follow the USN Diving Manual treatment protocols instead).

8) Upon surfacing from the HBOT, refer the patient emergently to an ophthalmologist.

9) The decision regarding further management should be made jointly by the Ophthalmologist and hyperbaric consultant.

10) In general, if vision improves with HBOT, the HBOT should be titrated to obtain as much improvement in visual function as possible while avoiding or minimizing pulmonary oxygen toxicity.

Note: a) HBOT should be administered in all cases if the loss of vision was associated with a recent hyperbaric or hypobaric exposure, b) HBOT should be administered if the history is suggestive of radiation optic neuropathy or for vision loss that occurs during or immediately after hemodialysis; c) Consultation with an Ophthalmologist is desirable but should not delay HBOT; d) All patients with acute, painless, severe vision loss should be referred emergently to an ophthalmologist if not treated with emergent

Table 4. Emergent HBOT in Patients with Acute Vision Loss: Selection Criteria

HBOT is indicated emergently in patients who present with acute vision loss and meet the following criteria:

- Presentation within 24 hours of vision loss
- Corrected visual acuity 20/200 or worse
- Visual acuity still 20/200 or worse with pinhole testing
- Age > 40
- No pain associated with the vision loss
- No history of acute onset of flashes or floaters prior to vision loss
- No history of recent eye surgery or eye trauma

Notes:

1. HBOT should be administered in all cases if the loss of vision was associated a recent exposure to a hyperbaric environment or unpressurized high-altitude conditions.
2. HBOT should be administered in all cases if the history is suggestive of radiation optic neuropathy or for vision loss that occurs during or immediately after hemodialysis.
3. Consultation with an ophthalmologist is desirable if it can be obtained without delaying HBOT.
4. All patients with acute, painless, severe vision loss should be referred emergently to an ophthalmologist if not treated with emergent HBOT so that potentially reversible causes of vision loss may be identified and treated. Patients for whom emergent HBOT is undertaken should be evaluated by an ophthalmologist following the HBOT.

HBOT so that potentially reversible causes of vision loss may be identified and treated. Patients for whom emergent HBOT is undertaken should be evaluated by an ophthalmologist following HBOT. The decision and treatment algorithms for emergent HBOT for acute loss of vision are summarized in Figures 6 and 7 (Fig 6. see Appendix 1, page 380; Fig. 7, see Appendix 2, page 381).

SYSTEMIC COMPLICATIONS OF HBOT

Pulmonary

The clinically important manifestations of O₂ toxicity in the pressure ranges used for HBOT involve the lung. Prolonged or repeated exposure to oxygen levels above the toxicity threshold of 0.5 ATA will result in chest pain, cough, and decreased vital capacity with a shorter latent period to toxicity as PO₂ increases. The initial onset of pulmonary O₂ toxicity in humans breathing oxygen continuously at 1 ATA is ~18 hours (338). The onset of pulmonary oxygen toxicity can be significantly delayed by using intermittent air breaks during the hyperbaric exposure (339). Changes in the 1-second forced expiratory volume and mid-expiratory flow rate precede both clinical symptoms and changes in forced vital capacity in volunteers undergoing a 10-day course of oxygen at 2.5 ATA for 95 minutes a day (340). A longer course of 21 HBOT sessions at 2.4 ATA for 90 minutes on consecutive days produced non-productive cough as well as significant decreases in FEV1 and mid-expiratory flow rate in four of twenty patients studied. There were no changes in forced vital capacity or peak expiratory flow (341). However, this reduction in pulmonary function was not considered of clinical significance unless repeated treatment series are contemplated or pulmonary function is reduced before treatment. More aggressive oxygen exposures may result in much more rapid onset of pulmonary oxygen toxicity (59).

Central Nervous System Oxygen (CNS)

The most dramatic sign of CNS O₂ toxicity is convulsions. Other signs and symptoms include muscle twitching, nausea, tinnitus, confusion, and dysphoria, which may precede the onset of a convulsion. However, convulsions may occur without any antecedent warning symptoms (342). CNS O₂ toxicity is characterized by sudden onset of symptoms and (usually) a rapid relief from symptoms once the PO₂ is reduced to non-toxic levels.

Oxygen pressures above 1.3 ATA may result in CNS O₂ toxicity. The likelihood of developing CNS O₂ toxicity increases with increasing exposure time and PO₂. Other factors that increase susceptibility to CNS oxygen toxicity are immersion, exercise, elevated levels of inspired CO₂, and cold stress (342-344).

The dry, resting conditions of HBOT reduce but do not eliminate the risk of CNS O₂ toxicity. CNS O₂ toxicity is rare in dry chambers at pressures of 2.0 ATA and less. One recent paper noted only two convulsions from CNS O₂ toxicity in 10,028 treatments, most of which were 45 FSW for 90 min exposures (345). Witucki and colleagues reported no convulsions in 19,377 HBOT exposures for chamber attendants breathing oxygen at 45 FSW for 15 or 30 minutes (346). If CNS O₂ toxicity is encountered, oxygen breathing should be discontinued immediately (56). In most cases, symptoms resolve within minutes, although some episodes progress to convulsions despite a reduction in PO₂. Uncomplicated CNS O₂ toxicity is typically without sequelae, and oxygen breathing may be resumed 15 minutes after the CNS symptoms subside. Should symptoms recur a second time, the patient's PO₂ should be reduced prior to continuing treatment.

Cardiovascular

HBOT may cause elevations in blood pressure in both hypertensive and non-

hypertensive patients. Peripheral resistance increases by about 30% while heart rate and cardiac output fall by about 20% (11). This side effect of HBOT may be an important consideration in patients with poor left ventricular function.

OCULAR COMPLICATIONS OF HBOT

Ocular Manifestations of CNS Oxygen Toxicity

Visual symptoms are a well-recognized manifestation of CNS O₂ toxicity (343, 344, 347). The most commonly described ocular symptoms of CNS O₂ toxicity are eyelid twitching, blurred vision, and visual field constriction, although the latter symptom represents retinal oxygen toxicity, as described below. Visual hallucinations (343) and transient unilateral loss of vision (347) have also been reported.

Retinal Oxygen Toxicity

Oxygen can be directly toxic to the eye (348). At 1 ATA, O₂ has not been shown to produce adverse ocular effects in adult humans. O₂ at this partial pressure typically results in pulmonary toxicity before the eye is affected (349). As early as 1935, Behnke reported a reversible decrease in peripheral vision after oxygen breathing at 3.0 ATA (350). Lambertsen and Clark and colleagues also observed a progressive decrease in peripheral vision associated with hyperoxia (13, 351). A decrease in peripheral vision was noted after approximately 2.5 hours of O₂ breathing at 3.0 ATA in a dry chamber. This decrease was progressive until O₂ breathing was discontinued. The average decrement in visual field was 50%. Recovery was complete in all subjects after 45 minutes of air breathing (351). A decrease in ERG amplitude was noted as well, but did not correlate directly with the size of the visual field defect and returned to normal more slowly after the termination of the exposure (351). Visual acuity and visual

cortical evoked responses remained normal in all subjects. A 4-hour exposure to 1 ATA of O₂, in contrast, produced no change in visual acuity or visual fields (352). The changes in visual field noted above probably represent a form of retinal O₂ toxicity rather than CNS O₂ toxicity in that they are predictable, evolve slowly, and resolve slowly after the discontinuation of the hyperoxic exposure. Retinal O₂ toxicity is not commonly reported as a complication of HBOT, but the incidence may be underreported since visual fields are not typically performed during the course of HBOT and any defects would be expected to resolve shortly after return to normoxia. Moreover, repetitive HBOT is almost always administered at 2.0 to 2.5 ATA and for shorter times than those documented to cause retinal O₂ toxicity.

Retinal O₂ toxicity has been studied in animal models. Hyperbaric oxygen administered in severe enough exposures results in photoreceptor cell death preceded by attenuation of the electroretinogram (353, 354). Beehler exposed dogs to hyperoxia (680 to 760 mmHg of oxygen) continuously for 72 hours. All animals were either dead at the end of the exposure or died shortly thereafter due to pulmonary complications but half of the animals were found to have ocular lesions as a result of this exposure. The eye findings included bilateral retinal detachments, corneal haze, chemosis, and hyphema (355). Four-hour exposures of rabbits to 3 ATA or 40-48 hours of exposure to 1 ATA O₂ resulted in destruction of the retinal photoreceptor cells (13, 354). Sodium-potassium ATPase has been shown to be inhibited by hyperbaric oxygen and this may be a factor in retinal O₂ toxicity (356).

Hyperoxia is especially toxic to the immature retina, causing vasoconstriction and subsequent failure of normal vascularization in the retinas of infants given high doses of supplemental oxygen (357). Retrolental fibroplasia was first described in 1942 by Terry

(358). It became the leading cause of blindness in preschool children in the 1950s (359). Once it was determined that hyperoxia was the main causative factor in this disorder, the incidence of blindness was greatly reduced by limiting the inspired PO_2 .

Lenticular Oxygen Toxicity

Hyperoxic Myopia. Progressive myopic changes are a known complication of repetitive HBOT treatments (348, 360-366). The rate of myopic change is reported to be approximately 0.25 diopters per week and is progressive throughout the course of HBOT (365). Hyperoxic myopia is generally attributed to oxidative changes causing an increase in the refractive power of the lens, since studies have shown that axial length and keratometry readings did not reveal a corneal curvature or axial length basis for the myopic shift (360, 363, 365, 366). Reversal of the myopic shift after discontinuation of HBOT usually occurs within 3-6 weeks, but may take as long as 6-12 months(361). In a series of 26 patients exposed daily to 2.5 ATA oxygen for 60 minutes with an additional 30 minutes each of O_2 during compression and decompression, Lyne noted that a rate of myopic change of about 0.5 diopters a month, with the change being progressive throughout therapy and slowly reversible after HBOT was completed. Two patients were observed to have a myopic shift of 5.5 diopters (366).

The PO_2 in HBOT typically varies from 2.0-3.0 ATA depending on the treatment protocol used, but hyperoxic myopia has also been reported in a closed-circuit mixed-gas SCUBA diver at a PO_2 of 1.3 ATA, lower than typically used in HBOT (367). This myopic shift resolved over one month after finishing the series of hyperoxic dives.

Hypermetropic changes after HBOT exposures have also been reported (368, 369).

Cataracts. Cataract formation has

been reported by Palmquist and co-authors in patients undergoing a prolonged (150 or more exposures) course of daily HBOT therapy at 2.0-2.5 ATA (364). Seven of fifteen patients with clear lenses at the start of therapy developed cataracts during their course of treatment. Fourteen of these fifteen patients received total HBOT of between 300 and 850 hours. The lens opacities noted were not completely reversible after HBOT was discontinued. Gesell and Trott reported de novo cataract formation in a 49 year-old woman who underwent 48 HBOT treatments for chronic refractory osteomyelitis of the sacrum and recurrent failure of a sacral flap (370). Hyperoxic myopia and cataract formation may represent two points on the continuum of severity of lenticular oxygen toxicity. The high success rate of modern cataract surgery makes cataract formation an easily manageable complication of HBOT, and this side effect is not necessarily an indication to discontinue therapy if the patient's clinical indication for continuation of HBOT is sufficiently strong.

Vitreous Hemorrhage

Vitreous hemorrhage has been reported once during HBOT. The patient had proliferative diabetic retinopathy with a previous vitreous hemorrhage in the right eye and retinal neovascularization in the left eye. After the eighth in a series of HBOT sessions, he reported decreased vision in his left eye and was found to have had a vitreous hemorrhage in that eye as well. The authors suggest that the fragile neovascular vessels of proliferative diabetic retinopathy may have an increased tendency to hemorrhage during HBOT. They recommend blood sugar normalization and control of hypertension prior to treating such patients with HBOT (371).

Other Toxic Ocular Effects: Guinea pigs subjected to lethal exposures of 3 and 5 ATA O_2 developed cellular damage to both the corneal

endothelial cells and the lens epithelial cells (372). Animals exposed to 1 ATA O₂ for 48 hours have been shown to develop inflammatory retinal detachments, conjunctivitis, iritis, and hypotony (359).

MINIMIZING OCULAR COMPLICATIONS FROM HBOT

Winkle demonstrated that exposing post-RK corneas to 100% nitrogen via goggles at 1 ATA for 2 hours caused a significant hyperopic shift of 1.24 diopters and corneal flattening of 1.19 diopters in post-RK eyes. The individuals in this study were breathing air during the study period. Corneal thickness increased in both post-RK and control eyes but was not associated with a hyperopic shift in control eyes (373). This demonstrates that the PO₂ the pre-corneal gas space is more important than inspired PO₂ in determining the physiological effect of the gas mix on the cornea.

Use of an oronasal mask instead of a hood was suggested by Anderson as a means of decreasing hyperoxic myopia by reducing the PO₂ in the cornea, aqueous, and lens (365). This method lowers the effective O₂ dose to the eye. A reduction of hyperoxic myopia during HBOT by approximately 50% has been reported by using an oronasal mask instead of a hood for oxygen administration (374).

SUMMARY

HBOT has not traditionally been widely used in the management of ocular disorders. There are a number of ocular conditions, however, for which HBOT may reverse profound vision loss. The authors recommend aggressive use of HBOT for the indications listed when vision loss is severe and the patient is within the time window for HBOT to be effective. Further studies will help to define which ocular disorders are best treated with

HBOT, the critical window of opportunity for each, and which HBOT treatment regimens provide the best outcomes.

ACKNOWLEDGMENTS

The authors thank Drs. Steve Chalfin, David Harris, Tim Peterson, Richard Moon, Steve O'Connell, Brett Hart, and Paul Cianci for reviewing this manuscript and providing comments. Thanks also to Dr. Chalfin for the excellent photographs used in this paper. Additional thanks to Ms. Valerie McCann and Ms. Ruth Spears of the Naval Operational Medicine Institute Medical Library and Ms. Bienvenido Sol, Elnora Sanchez, Carol Que Duong, Jalene Wilburn, Julie Kleckner, Mr. Marco Murillo, and Ms. Kathleen Parker, Simona Konecna, Mary Tapp, and Donna Murico of the Medical Library at Naval Medical Center, San Diego for invaluable assistance in preparing this paper. Thanks also to Ms. Shirley Lowe for administrative assistance.

REFERENCES

1. Regillo D, Chang TS, Johnson MW, et al. Retina and Vitreous: American Academy of Ophthalmology Basic and Clinical Science Course - Section 12. San Francisco: American Academy of Ophthalmology; 2007.
2. Cibis GW, Beaver HA, Johns K, et al. Basic and Clinical Science Course: Fundamentals and Principles of Ophthalmology. American Academy of Ophthalmology, San Francisco 2006:38-40.
3. Li HK, Dejean BJ, Tang RA. Reversal of visual loss with hyperbaric oxygen treatment in a patient with Susac syndrome. *Ophthalmology* 1996;103:2091-8.
4. Landers MB, 3rd. Retinal oxygenation via the choroidal circulation. *Trans Am Ophthalmol Soc* 1978;76:528-56.
5. Patz A. Oxygen inhalation in retinal arterial occlusion; a preliminary report. *Am J Ophthalmol* 1955;40:789-95.
6. Butler FK, Harris DJ, Reynolds RA. Altitude Retinopathy on Mount Everest 1989. *Ophthalmology* 1992;99:739-46.
7. Resch H, Zawinka C, Weigert G, Schmetterer L, Garhofer G. Inhaled carbon monoxide increases retinal and choroidal blood flow in healthy humans. *Invest Ophthalmol Vis Sci* 2005;46:4275-80.
8. Ishida S, Usui T, Yamashiro K, et al. VEGF164 is proinflammatory in the diabetic retina. *Invest Ophthalmol Vis Sci* 2003;44:2155-62.
9. Piantadosi CA. Physiology of hyperbaric hyperoxia. *Respir Care Clin N Am* 1999;5:7-19.
10. Yu DY, Cringle SJ. Retinal degeneration and local oxygen metabolism. *Exp Eye Res* 2005;80:745-51.

11. Vucetic M, Jensen PK, Jansen EC. Diameter variations of retinal blood vessels during and after treatment with hyperbaric oxygen. *Br J Ophthalmol* 2004;88:771-5.
12. Polkinghorne PJ, Bird AC, Cross MR. Retinal vessel constriction under hyperbaric conditions. *Lancet* 1989;2:1099.
13. Nichols CW, Lambertsen C. Effects of high oxygen pressures on the eye. *N Engl J Med* 1969;281:25-30.
14. Frayser R, Saltzman HA, Anderson B, Jr., Hickam JB, Sieker HO. The effect of hyperbaric oxygenation on retinal circulation. *Arch Ophthalmol* 1967;77:265-9.
15. Anderson B, Saltzman HA. Hyperbaria, hyperoxia, and the retinal and cerebral vessels. *Headache* 1965;5:73-7.
16. Saltzman HA, Hart L, Sieker HO, Duffy EJ. Retinal vascular response to hyperbaric oxygenation. *JAMA* 1965;191:114-6.
17. Haddad HM, Leopold IH. Effect of hyperbaric oxygenation on microcirculation: use in therapy of retinal vascular disorders. *Invest Ophthalmol* 1965;4:1141-51.
18. Jacobson I, Harper AM, McDowall DG. The effects of oxygen under pressure on cerebral blood-flow and cerebral venous oxygen tension. *Lancet* 1963;25:19.
19. Herbststein K, Murchland JB. Retinal vascular changes after treatment with hyperbaric oxygen. *Med J Aust* 1984;140:728-9.
20. James PB. Hyperbaric oxygen and retinal vascular changes. *Med J Aust* 1985;142:163-4.
21. Jampol LM. Oxygen therapy and intraocular oxygenation. *Trans Am Ophthalmol Soc* 1987;85:407-37.
22. Dollery CT, Bulpitt CJ, Kohner EM. Oxygen supply to the retina from the retinal and choroidal circulations at normal and increased arterial oxygen tensions. *Invest Ophthalmol* 1969;8:588-94.
23. Carlisle R, Lanphier EH, Rahn H. Hyperbaric oxygen and persistence of vision in retinal ischemia. *J Appl Physiol* 1964;19:914-8.
24. Jampol LM, Orlin C, Cohen SB, Zanetti C, Lehman E, Goldberg MF. Hyperbaric and transcorneal delivery of oxygen to the rabbit and monkey anterior segment. *Arch Ophthalmol* 1988;106:825-9.
25. Gallin-Cohen PF, Podos SM, Yablonski ME. Oxygen lowers intraocular pressure. *Invest Ophthalmol Vis Sci* 1980;19:43-8.
26. Moon RE, Camporesi EM. Hyperbaric oxygen therapy: from the nineteenth to the twenty-first century. *Respir Care Clin N Am* 1999;5:1-5.
27. Cunningham OJ. Oxygen therapy by means of compressed air. *Anesth Analg* 1927;6:64-6.
28. Feldmeier JJ, ed. Hyperbaric Oxygen 2003: Indications and Results - The Hyperbaric Oxygen Therapy Committee Report. Dunkirk, Undersea and Hyperbaric Medical Society, 2003.
29. Bennett MH, Lehm JP, Mitchell SJ, Wasiak J. Recompression and adjunctive therapy for decompression illness. *Cochrane Database Syst Rev* 2007:CD005277.
30. Dias MD, Fontes B, Pogetti RS, Birolini D. Hyperbaric oxygen therapy: types of injury and number of sessions. *Undersea Hyperb Med* 2008;35:53-60.
31. Cianci PB, Slade JB. Delayed treatment of decompression sickness with short, no-break air tables: a review of 140 cases. *Aviat Space Environ Med* 2006;77:1003.
32. Jallali N, Withey S, Butler PE. Hyperbaric oxygen as adjuvant therapy in the management of necrotizing fasciitis. *Am J Surg* 2005;189:462-6.
33. Weaver LK, Hopkins RO, Chan KJ, et al. Hyperbaric oxygen for acute carbon monoxide poisoning. *N Engl J Med* 2002;347:1057-67.
34. McDermott JJ, Dutka AJ, Koller WA, Flynn ET. Effects of an increased PO₂ during recompression therapy for the treatment of experimental cerebral arterial gas embolism. *Undersea Biomed Res* 1992;19:403-13.
35. Bond JG, Moon RE, Morris DL. Initial table treatment of decompression sickness and arterial gas embolism. *Aviat Space Environ Med* 1990;61:738-43.
36. Brooks GJ, Green RD, Leitch DR. Pulmonary barotrauma in submarine escape trainees and the treatment of cerebral arterial air embolism. *Aviat Space Environ Med* 1986;57:1201-7.
37. Butler FK, Jr. Diving and hyperbaric ophthalmology. *Surv Ophthalmol* 1995;39:347-66.
38. Isenberg SJ, Diamant A. Scuba diving after enucleation. *Am J Ophthalmol* 1985;100:616-7.
39. Butler FK. The Eye in the Wilderness. In: Wilderness Medicine; Auerbach PS, ed: St Louis, Mosby; Fifth Edition 2007.
40. Kokame GT, Ing MR. Intraocular gas and low-altitude air flight. *Retina* 1994;14:356-8.
41. Mills MD, Devenyi RG, Lam WC, Berger AR, Beijer CD, Lam SR. An assessment of intraocular pressure rise in patients with gas-filled eyes during simulated air flight. *Ophthalmology* 2001;108:40-4.
42. Lincoff H, Weinberger D, Stergiu P. Air travel with intraocular gas. II. Clinical considerations. *Arch Ophthalmol* 1989;107:907-10.
43. Polk JD, Rugaber C, Kohn G, Arenstein R, Fallon WF, Jr. Central retinal artery occlusion by proxy: a cause for sudden blindness in an airline passenger. *Aviat Space Environ Med* 2002;73:385-7.
44. Jackman SV, Thompson JT. Effects of hyperbaric exposure on eyes with intraocular gas bubbles. *Retina* 1995;15:160-6.
45. Mekjavic IB, Campbell DG, Jaki P, Dovsak PA. Ocular bubble formation as a method of assessing decompression stress. *Undersea Hyperb Med* 1998;25:201-10.

46. Steigleman A, Butler F, Chhoeu A, O'Malley T, Bower E, Giebner S. Optic neuropathy following an altitude exposure. *Aviat Space Environ Med* 2003;74:985-9.
47. Fitzpatrick DT. Visual manifestations of neurologic decompression sickness. *Aviat Space Environ Med* 1994;65:736-8.
48. Hsu AA, Wong TM, How J, Tan J, Tan KT. Retinal artery occlusion in a diver. *Singapore Med J* 1992;33:299-301.
49. Butler FK. Decompression sickness presenting as optic neuropathy. *Aviat Space Environ Med* 1991;62:346-50.
50. Butler FK. Ocular Manifestations of Decompression Sickness. In: Gold T, Weinstein G, eds. *The Eye in Systemic Disease*. Philadelphia: JB Lippincott, 1990:469-71.
51. Liepmann M. Accommodative and convergence insufficiency after decompression sickness. *Arch Ophthalmol* 1981;99:453.
52. Davis JC, Sheffield PJ, Schuknecht L, et al. Altitude decompression sickness: hyperbaric therapy results in 145 cases. *Aviat Space Environ Med* 1977;48:722-30.
53. Summitt JK, Berghage TE. Review of Diving Accident Reports 1968. U.S. Navy Experimental Diving Unit Research Report 11-70, 1970.
54. Rivera JC. Decompression Sickness among Divers: An Analysis of 935 Cases. *Mil Med* 1964;129:314-34.
55. Van Der Aue O, Dufner G, Behnke A. The treatment of decompression sickness - an analysis of one hundred and thirteen cases. *J Industr Hyg Toxicol* 1947;29:359-66.
56. U.S. Navy Diving Manual. Washington, DC: Naval Sea Systems Command Publication SS521-AG-PRO-010 (0910-LP-103-8009); Revision 5, 2005: Chapter 3.
57. Butler FK. Central nervous system oxygen toxicity in closed circuit SCUBA divers III. U.S. Navy Experimental Diving Unit Research Report 5-86, 1986.
58. How J, Chan G. Management of delayed cases of decompression sickness-3 case reports. *Singapore Med J* 1973;14:582-5.
59. Butler FK, Jr., Pinto CV. Progressive ulnar palsy as a late complication of decompression sickness. *Ann Emerg Med* 1986;15:738-41.
60. Longphre JM, Denoble PJ, Moon RE, Vann RD, Freiburger JJ. First aid normobaric oxygen for the treatment of recreational diving injuries. *Undersea Hyperb Med* 2007;34:43-9.
61. Rudge FW. Altitude-induced arterial gas embolism: a case report. *Aviat Space Environ Med* 1992;63:203-5.
62. Wherrett CG, Mehran RJ, Beaulieu MA. Cerebral arterial gas embolism following diagnostic bronchoscopy: delayed treatment with hyperbaric oxygen. *Can J Anaesth* 2002;49:96-9.
63. Brundin J, Thomasson K. Cardiac gas embolism during carbon dioxide hysteroscopy: risk and management. *Eur J Obstet Gynecol Reprod Biol* 1989;33:241-5.
64. Grace DM. Air embolism with neurologic complications: a potential hazard of central venous catheters. *Can J Surg* 1977;20:51-3.
65. Gutman FA, Zegarra H. Ocular complications in cardiac surgery. *Surg Clin North Am* 1971;51:1095-103.
66. Mitchell SJ, Benson M, Vadlamudi L, Miller P. Cerebral arterial gas embolism by helium: an unusual case successfully treated with hyperbaric oxygen and lidocaine. *Ann Emerg Med* 2000;35:300-3.
67. Pao BS, Hayden SR. Cerebral gas embolism resulting from inhalation of pressurized helium. *Ann Emerg Med* 1996;28:363-6.
68. Gorman DF. Arterial gas embolism as a consequence of pulmonary barotrauma. In: Desole J, ed: *Diving and Hyperbaric Medicine - Proceedings of the IX Congress of the European Undersea Biomedical Society*. Barcelona: EUBS, 1978:347-368.
69. Bitterman H, Melamed Y. Delayed hyperbaric treatment of cerebral air embolism. *Isr J Med Sci* 1993;29:22-6.
70. Bove AA, Clark JM, Simon AJ, Lambertsen CJ. Successful therapy of cerebral air embolism with hyperbaric oxygen at 2.8 ATA. *Undersea Biomed Res* 1982;9:75-80.
71. Hayreh SS, Zimmerman MB. Central retinal artery occlusion: visual outcome. *Am J Ophthalmol* 2005;140:376-91.
72. Stone R, Zink H, Klingele T, Burde RM. Visual recovery after central retinal artery occlusion: two cases. *Ann Ophthalmol* 1977;9:445-50.
73. Duker JS, Brown GC. Recovery following acute obstruction of the retinal and choroidal circulations - a case history. *Retina* 1988;8:257-60.
74. David NJ, Norton EW, Gass JD, Beauchamp J. Fluorescein angiography in central retinal artery occlusion. *Arch Ophthalmol* 1967;77:619-29.
75. Hertzog LM, Meyer GW, Carson S, Strauss MB, Hart GB. Central retinal artery occlusion treated with hyperbaric oxygen. *J Hyperbaric Medicine* 1992;7:33-42.
76. Neubauer AS, Mueller AJ, Schriever S, Gruterich M, Ulbig M, Kampik A. Minimally invasive therapy for clinically complete central retinal artery occlusion-results and meta-analysis of literature. *Klin Monatsbl Augenheilkd* 2000;217:30-6.
77. Petterson JA, Hill MD, Demchuk AM, et al. Intra-arterial thrombolysis for retinal artery occlusion: the Calgary experience. *Can J Neurol Sci* 2005;32:507-11.
78. Weber J, Remonda L, Mattle HP, et al. Selective intra-arterial fibrinolysis of acute central retinal artery occlusion. *Stroke* 1998;29:2076-9.
79. Garcia-Arumi J, Martinez-Castillo V, Boixadera A, Fonollosa A, Corcostegui B. Surgical embolus

- removal in retinal artery occlusion. *Br J Ophthalmol* 2006;90:1252-5.
80. Tang WM, Han DP. A study of surgical approaches to retinal vascular occlusions. *Arch Ophthalmol* 2000;118:138-43.
 81. Mangat HS. Retinal artery occlusion. *Surv Ophthalmol* 1995;40:145-56.
 82. Augsburger JJ, Magargal LE. Visual prognosis following treatment of acute central retinal artery obstruction. *Br J Ophthalmol* 1980;64:913-7.
 83. Yu DY, Cringle SJ, Yu PK, Su EN. Intraretinal oxygen distribution and consumption during retinal artery occlusion and graded hyperoxic ventilation in the rat. *Invest Ophthalmol Vis Sci* 2007;48:2290-6.
 84. Phillips D, Diaz C, Atwell G, Chimak J, Ullman S, et al. Care of sudden blindness: a case report of acute central retinal artery occlusion reversed with hyperbaric oxygen therapy. *Undersea Hyperb Med* 1999;26 (Supp):23-4.
 85. Hayreh SS, Kolder HE, Weingeist TA. Central retinal artery occlusion and retinal tolerance time. *Ophthalmology* 1980;87:75-8.
 86. Matsuo T. Multiple occlusive retinal arteritis in both eyes of a patient with rheumatoid arthritis. *Jpn J Ophthalmol* 2001;45:662-4.
 87. Weinberger AW, Siekmann UP, Wolf S, Rossaint R, Kirchhof B, Schrage NF. Treatment of acute central retinal artery occlusion (CRAO) by hyperbaric oxygenation therapy (HBO)-pilot study with 21 patients. *Klin Monatsbl Augenheilkd* 2002;219:728-34.
 88. Yotsukura J, Adachi-Usami E. Correlation of electroretinographic changes with visual prognosis in central retinal artery occlusion. *Ophthalmologica* 1993;207:13-8.
 89. Beiran I, Reissman P, Scharf J, Nahum Z, Miller B. Hyperbaric oxygenation combined with nifedipine treatment for recent-onset retinal artery occlusion. *Eur J Ophthalmol* 1993;3:89-94.
 90. Hirayama Y, Matsunaga N, Tashiro J, Amemiya T, Iwasaki M. Bifemelane in the treatment of central retinal artery or vein obstruction. *Clin Ther* 1990;12:230-5.
 91. Henderson LT, Slade JB. Central retinal artery occlusion and hyperbaric oxygen therapy. *Undersea Hyperb Med* 2004;31:309.
 92. Takeuchi M, Morita K, Nakatsuka H, et al. A case of central retinal artery occlusion after anterior posterior fusion of the lumbar spine. *Masui* 2001;50:899-901.
 93. Beiran I, Goldenberg I, Adir Y, Tamir A, Shupak A, Miller B. Early hyperbaric oxygen therapy for retinal artery occlusion. *Eur J Ophthalmol* 2001;11:345-50.
 94. Miyake Y, Horiguchi M, Matsuura M, et al. Hyperbaric oxygen therapy in 72 eyes with retinal arterial occlusion. In: Bove AA, Bachrach AJ, Greenbaum LJ, eds. Ninth International Symposium on Underwater and Hyperbaric Physiology. Bethesda: Undersea and Hyperbaric Medical Society, 1987:949-953.
 95. Mori K, Ohta K, Nagano S, Toshinori M, Yago T, Ichinose Y. A case of ophthalmic artery obstruction following autologous fat injection in the glabellar area. *Nippon Ganka Gakkai Zasshi* 2007;111:22-5.
 96. Hayreh SS, Podhajsky P. Ocular neovascularization with retinal vascular occlusion. II. Occurrence in central and branch retinal artery occlusion. *Arch Ophthalmol* 1982;100:1585-96.
 97. Murphy-Lavoie H, Harch P, VanMeter K. Effect of hyperbaric oxygen on central retinal artery occlusion. UHMS Scientific Assembly, Australia, 2004.
 98. Perkins SA, Magargal LE, Augsburger JJ, Sanborn GE. The idling retina: reversible visual loss in central retinal artery obstruction. *Ann Ophthalmol* 1987;19:3-6.
 99. Anderson B, Jr., Saltzman HA, Heyman A. The Effects of Hyperbaric Oxygenation on Retinal Arterial Occlusion. *Arch Ophthalmol* 1965;73:315-9.
 100. Brummelkamp WH, Hogendyk J, Boerema I. Treatment of anaerobic infections by drenching the tissues with oxygen under high atmospheric pressure. *Surgery* 1961;49:299-302.
 101. Clark LA, Moon RE. Hyperbaric oxygen in the treatment of life-threatening soft-tissue infections. *Respir Care Clin N Am* 1999;5:203-19.
 102. Gopal L, Basti S, Parikh V, Badrinath SS. Gas gangrene panophthalmitis is a rare condition that can occur following penetrating injury with retained intraocular foreign body. *Retina* 1992;12:74.
 103. Wilk CM, Ruprecht KW, Lang GK. Fulminant gas gangrene panophthalmia following perforating scleral injury. *Klin Monatsbl Augenheilkd* 1989;195:243-7.
 104. Kurz GH, Weiss JF. Gas gangrene panophthalmitis. Report of a case. *Br J Ophthalmol* 1969;53:323-6.
 105. Bristow JH, Kassab B, Sevel D. Gas gangrene panophthalmitis treated with hyperbaric oxygen. *Br J Ophthalmol* 1971;55:139-42.
 106. Fielden MP, Martinovic E, Ells AL. Hyperbaric oxygen therapy in the treatment of orbital gas gangrene. *J AAPOS* 2002;6:252-4.
 107. De La Paz MA, Patrinely JR, Marines HM, Appling WD. Adjunctive hyperbaric oxygen in the treatment of bilateral cerebro-rhino-orbital mucormycosis. *Am J Ophthalmol* 1992;114:208-11.
 108. Yohai RA, Bullock JD, Aziz AA, Markert RJ. Survival factors in rhino-orbital-cerebral mucormycosis. *Surv Ophthalmol* 1994;39:3-22.
 109. Paultauf A. Mycosis mucorina: ein beitrag zur kenntniss der menschlichen fadenpilzkrankungen. *Virchows Arch* 1885;102:543-64.
 110. Harris JS. Mucormycosis; report of a case. *Pediatrics* 1955;16:857-67.
 111. Price JC, Stevens DL. Hyperbaric oxygen in the treatment of rhinocerebral mucormycosis.

- Laryngoscope* 1980;90:737-47.
112. Bitterman H. Hyperbaric oxygen for invasive fungal infections. *Isr Med Assoc J* 2007;9:387-8.
 113. Ferguson BJ, Mitchell TG, Moon R, Camporesi EM, Farmer J. Adjunctive hyperbaric oxygen for treatment of rhinocerebral mucormycosis. *Rev Infect Dis* 1988;10:551-9.
 114. Guevara N, Roy D, Dutruc-Rosset C, Santini J, Hofman P, Castillo L. Mucormycosis--early diagnosis and treatment. *Rev Laryngol Otol Rhinol (Bord)* 2004;125:127-31.
 115. Chassaing N, Valton L, Kany M, et al. Rhinocerebral fungal infection successfully treated with supplementary hyperbaric oxygen therapy. *Rev Neurol (Paris)* 2003;159:1178-80.
 116. Pelton RW, Peterson EA, Patel BC, Davis K. Successful treatment of rhino-orbital mucormycosis without exenteration: the use of multiple treatment modalities. *Ophthal Plast Reconstr Surg* 2001;17:62-6.
 117. Lithander J, Louou A, Worthing E, et al. Orbital entomophthoromycosis in an infant: recovery following surgical debridement, combination antifungal therapy and use of hyperbaric oxygen. *Br J Ophthalmol* 2001;85:374-5.
 118. Bell S, Mahoney L. Mucormycosis: a case study. *Crit Care Nurse* 2000;20:18-23.
 119. Kemper J, Kuijper EJ, Mirck PG, Balm AJ. Recovery from rhinocerebral mucormycosis in a ketoacidotic diabetic patient: a case report. *J Laryngol Otol* 1993;107:233-5.
 120. Melero M, Kaimen Maciel I, Tiraboschi N, Botargues M, Radisic M. Adjunctive treatment with hyperbaric oxygen in a patient with rhino-sinuso-orbital mucormycosis. *Medicina (B Aires)* 1991;51:53-5.
 121. Couch L, Theilen F, Mader JT. Rhinocerebral mucormycosis with cerebral extension successfully treated with adjunctive hyperbaric oxygen therapy. *Arch Otolaryngol Head Neck Surg* 1988;114:791-4.
 122. Schmidt JM, Poublon RM. Rhinocerebral mycosis in immunocompromised patients. A case report and review of the literature. *Rhinology* 1998;36:90-3.
 123. Riseman JA, Zamboni WA, Curtis A, Graham DR, Konrad HR, Ross DS. Hyperbaric oxygen therapy for necrotizing fasciitis reduces mortality and the need for debridements. *Surgery* 1990;108:847-50.
 124. Knudtson KJ, Gigantelli JW. Necrotizing fasciitis of the eyelids and orbit. *Arch Ophthalmol* 1998;116:1548-9.
 125. Marshall DH, Jordan DR, Gilberg SM, Harvey J, Arthurs BP, Nerad JA. Periocular necrotizing fasciitis: a review of five cases. *Ophthalmology* 1997;104:1857-62.
 126. Kronish JW, McLeish WM. Eyelid necrosis and periorbital necrotizing fasciitis. Report of a case and review of the literature. *Ophthalmology* 1991;98:92-8.
 127. Gozal D, Ziser A, Shupak A, Ariel A, Melamed Y. Necrotizing fasciitis. *Arch Surg* 1986;121:233-5.
 128. Goldberg RA, Li TG. Postoperative infection with group A beta-hemolytic Streptococcus after blepharoplasty. *Am J Ophthalmol* 2002;134:908-10.
 129. Suner IJ, Meldrum ML, Johnson TE, Tse DT. Necrotizing fasciitis after cosmetic blepharoplasty. *Am J Ophthalmol* 1999;128:367-8.
 130. Jordan DR, Mawn L, Marshall DH. Necrotizing fasciitis caused by group A streptococcus infection after laser blepharoplasty. *Am J Ophthalmol* 1998;125:265-6.
 131. Puri P, Innes JR. Necrotizing fasciitis of the orbit: early recognition and treatment a key to success. *Eur J Ophthalmol* 2001;11:180-2.
 132. Shupak A, Shoshani O, Goldenberg I, Barzilai A, Moskuna R, Bursztein S. Necrotizing fasciitis: an indication for hyperbaric oxygenation therapy? *Surgery* 1995;118:873-8.
 133. Shochat G. Carbon monoxide toxicity. E-medicine website. (Accessed 8 January 2007).
 134. Stoller KP. Hyperbaric oxygen and carbon monoxide poisoning: a critical review. *Neurol Res* 2007;29:146-55.
 135. Thom SR. Hyperbaric-oxygen therapy for acute carbon monoxide poisoning. *N Engl J Med* 2002;347:1105-6.
 136. Piantadosi CA. Carbon monoxide poisoning. *N Engl J Med* 2002;347:1054-5.
 137. Hampson NB. Pulse oximetry in severe carbon monoxide poisoning. *Chest* 1998;114:1036-41.
 138. Kelley JS, Sophocleus GJ. Retinal hemorrhages in subacute carbon monoxide poisoning. Exposures in homes with blocked furnace flues. *JAMA* 1978;239:1515-7.
 139. Ersanli D, Yildiz S, Togrol E, Ay H, Qyrdedi T. Visual loss as a late complication of carbon monoxide poisoning and its successful treatment with hyperbaric oxygen therapy. *Swiss Med Wkly* 2004;134:650-5.
 140. Denniston A. Carbon monoxide poisoning and the eye. *J R Soc Med* 2001;94:425-6.
 141. Simmons IG, Good PA. Carbon monoxide poisoning causes optic neuropathy. *Eye* 1998;12:809-14.
 142. Dempsey LC, O'Donnell JJ, Hoff JT. Carbon monoxide retinopathy. *Am J Ophthalmol* 1976;82:692-3.
 143. Bilchik RC, Muller-Bergh HA, Freshman ME. Ischemic retinopathy due to carbon monoxide poisoning. *Arch Ophthalmol* 1971;86:142-4.
 144. Weaver LK, Valentine KJ, Hopkins RO. Carbon monoxide poisoning: risk factors for cognitive sequelae and the role of hyperbaric oxygen. *Am J Respir Crit Care Med* 2007;176:491-7.
 145. Hampson NB, Little CE. Hyperbaric treatment of patients with carbon monoxide poisoning in the

- United States. *Undersea Hyperb Med* 2005;32:21-6.
146. Silver S, Smith C, Worster A. Should hyperbaric oxygen be used for carbon monoxide poisoning? *CJEM* 2006;8:43-6.
 147. Bhandare N, Monroe AT, Morris CG, Bhatti MT, Mendenhall WM. Does altered fractionation influence the risk of radiation-induced optic neuropathy? *Int J Radiat Oncol Biol Phys* 2005;62:1070-7.
 148. Finger PT. Anti-VEGF bevacizumab (Avastin) for radiation optic neuropathy. *Am J Ophthalmol* 2007;143:335-8.
 149. Lessell S. Friendly fire: neurogenic visual loss from radiation therapy. *J Neuroophthalmol* 2004;24:243-50.
 150. Jones B, Comins C, Dale RG. Several important omissions in two recent articles concerned with radiation optic neuropathy. *Radiother Oncol* 2004;70:211-2.
 151. Borruat FX, Schatz NJ, Glaser JS, Feun LG, Matos L. Visual recovery from radiation-induced optic neuropathy. The role of hyperbaric oxygen therapy. *J Clin Neuroophthalmol* 1993;13:98-101.
 152. Miller NR. Radiation-induced optic neuropathy: still no treatment. *Clin Experiment Ophthalmol* 2004;32:233-5.
 153. Sallet G, Kestelyn P. Radiation-induced optic neuropathy. *Bull Soc Belge Ophthalmol* 1992;243:99-107.
 154. Borruat FX, Schatz NJ, Glaser JS, Matos L, Feuer W. Radiation optic neuropathy: report of cases, role of hyperbaric oxygen therapy, and literature review. *Neuro-Ophthalmology* 1996;16:255-66.
 155. Guy J, Schatz NJ. Hyperbaric oxygen in the treatment of radiation-induced optic neuropathy. *Ophthalmology* 1986;93:1083-8.
 156. Garrott H, O'Day J. Optic neuropathy secondary to radiotherapy for nasal melanoma. *Clin Experiment Ophthalmol* 2004;32:330-3.
 157. Roden D, Bosley TM, Fowble B, et al. Delayed radiation injury to the retrobulbar optic nerves and chiasm: clinical syndrome and treatment with hyperbaric oxygen and corticosteroids. *Ophthalmology* 1990;97:346-51.
 158. Guy J, Schatz NJ. Effectiveness of hyperbaric oxygen in treating radiation injury to the optic nerves and chiasm. *Ophthalmology* 1990;97:1246-7.
 159. Levy RL, Miller NR. Hyperbaric oxygen therapy for radiation-induced optic neuropathy. *Ann Acad Med Singapore* 2006;35:151-7.
 160. Boschetti M, De Lucchi M, Giusti M, et al. Partial visual recovery from radiation-induced optic neuropathy after hyperbaric oxygen therapy in a patient with Cushing disease. *Eur J Endocrinol* 2006;154:813-8.
 161. Munoz S, Arruga J, Martin N. Radiation optic neuropathy treated with hyperbaric oxygen and steroids: stabilization after late treatment. *Neuro-Ophthalmology* 2004;28:259-64.
 162. Gall N, Leiba H, Handzel R, Pe'er J. Severe radiation retinopathy and optic neuropathy after brachytherapy for choroidal melanoma treated by hyperbaric oxygen. *Eye* 2007;21:1010-2.
 163. Girkin CA, Comey CH, Lunsford LD, Goodman ML, Kline LB. Radiation optic neuropathy after stereotactic radiosurgery. *Ophthalmology* 1997;104:1634-43.
 164. Ryu S, Kolozsvary A, Jenrow KA, Brown SL, Kim JH. Mitigation of radiation-induced optic neuropathy in rats by ACE inhibitor ramipril: importance of ramipril dose and treatment time. *J Neurooncol* 2007;82:119-24.
 165. Danesh-Meyer HV, Savino PJ, Sergott RC. Visual loss despite anticoagulation in radiation-induced optic neuropathy. *Clin Experiment Ophthalmol* 2004;32:333-5.
 166. Finger PT, Chin K. Anti-vascular endothelial growth factor bevacizumab (Avastin) for radiation retinopathy. *Arch Ophthalmol* 2007;125:751-6.
 167. Feldmeier JJ, Hampson NB. A systematic review of the literature reporting the application of hyperbaric oxygen prevention and treatment of delayed radiation injuries: an evidence based approach. *Undersea Hyperb Med* 2002;29:4-30.
 168. Gonnering RS, Kindwall EP, Goldmann RW. Adjunct hyperbaric oxygen therapy in periorbital reconstruction. *Arch Ophthalmol* 1986;104:439-43.
 169. Sebban A, Hirst LW. Pterygium recurrence rate at the Princess Alexandra Hospital. *Aust N Z J Ophthalmol* 1991;19:203-6.
 170. Bayer A, Mutlu FM, Sobaci G. Hyperbaric oxygen therapy for mitomycin C-induced scleral necrosis. *Ophthalmic Surg Lasers* 2002;33:58-61.
 171. Green MO, Brannen AL. Hyperbaric oxygen therapy for beta-radiation-induced scleral necrosis. *Ophthalmology* 1995;102:1038-41.
 172. Hayreh SS, Zimmerman MB. Nonarteritic anterior ischemic optic neuropathy: natural history of visual outcome. *Ophthalmology* 2008;115:298-305.
 173. Matthews MK. Nonarteritic anterior ischemic optic neuropathy. *Curr Opin Ophthalmol* 2005;16:341-5.
 174. Olver JM, Spalton DJ, McCartney AC. Microvascular study of the retrolaminar optic nerve in man: the possible significance in anterior ischaemic optic neuropathy. *Eye* 1990;4:7-24.
 175. Desai N, Patel MR, Prisant LM, Thomas DA. Nonarteritic anterior ischemic optic neuropathy. *J Clin Hypertens* 2005;7:130-3.
 176. Hayreh SS, Zimmerman MB. Incipient nonarteritic anterior ischemic optic neuropathy. *Ophthalmology* 2007;114:1763-72.
 177. Arnold AC, Hepler RS, Lieber M, Alexander JM. Hyperbaric oxygen therapy for nonarteritic anterior ischemic optic neuropathy. *Am J Ophthalmol* 1996;122:535-41.
 178. Bojic L, Ivanisevic M, Gosovic G. Hyperbaric oxygen therapy in two patients with non-arteritic

- anterior optic neuropathy who did not respond to prednisone. *Undersea Hyperb Med* 2002;29:86-92.
179. Bojic L, Kovacevic H, Andric D, Karaman-Kraljevic K, Cagalj S. The effects of hyperbaric oxygen on visual functions in ischaemic optic neuropathy. *Arh Hig Rada Toksikol* 1994;45:19-24.
 180. Bojic L, Cerovski B, Bucan K, et al. Hyperbaric oxygen for the treatment of nonarteritic anterior ischemic optic neuropathy. *Acta Med Croatica* 1995;49:133-6.
 181. Beiran I, Rimon I, Weiss G, Pikkell J, Miller B. Hyperbaric oxygenation therapy for ischemic optic neuropathy. *Eur J Ophthalmol* 1995;5:285-6.
 182. Arnold AC, Levin LA. Treatment of ischemic optic neuropathy. *Semin Ophthalmol* 2002;17:39-46.
 183. Keynan Y, Yanir Y, Shupak A. Hyperbaric therapy for bilateral visual loss during hemodialysis. *Clin Exp Nephrol* 2006;10:82-4.
 184. Wells M, Foroozan R. Transient visual loss may anticipate occipital infarction from hemodialysis. *Am J Kidney Dis* 2004;43:29-33.
 185. Cuxart M, Matas M, Picazo M, Sans R, Juvanet J, Osuna T. Acute bilateral visual loss in a hemodialysed patient. *Nefrologia* 2005;25:703-5.
 186. Buono LM, Foroozan R, Savino PJ, Danesh-Meyer HV, Stanescu D. Posterior ischemic optic neuropathy after hemodialysis. *Ophthalmology* 2003;110:1216-8.
 187. Arora N, Lambrou FH Jr, Stewart MW, Vidrine-Parks L, Sandroni S. Sudden blindness associated with central nervous symptoms in a hemodialysis patient. *Nephron* 1991;59:490-2.
 188. Newman NJ, Scherer R, Langenberg P, et al. The fellow eye in NAION: report from the ischemic optic neuropathy decompression trial follow-up study. *Am J Ophthalmol* 2002;134:317-28.
 189. Hayreh SS, Zimmerman B. Management of giant cell arteritis. Our 27-year clinical study: new light on old controversies. *Ophthalmologica* 2003;217:239-59.
 190. Hayreh SS, Podhajsky PA, Zimmerman B. Ocular manifestations of giant cell arteritis. *Am J Ophthalmol* 1998;125:509-20.
 191. Boyd SR, Zachary I, Chakravarthy U, et al. Correlation of increased vascular endothelial growth factor with neovascularization and permeability in ischemic central vein occlusion. *Arch Ophthalmol* 2002;120:1644-50.
 192. Glacet-Bernard A, Coscas G, Chabanel A, Zourdani A, Lelong F, Samama MM. Prognostic factors for retinal vein occlusion: a prospective study of 175 cases. *Ophthalmology* 1996;103:551-60.
 193. Fong AC, Schatz H. Central retinal vein occlusion in young adults. *Surv Ophthalmol* 1993;37:393-417.
 194. Mohamed Q, McIntosh RL, Saw SM, Wong TY. Interventions for central retinal vein occlusion: an evidence-based systematic review. *Ophthalmology* 2007;114:507-19.
 195. Hayreh SS. Management of central retinal vein occlusion. *Ophthalmologica* 2003;217:167-88.
 196. Miyamoto H, Ogura Y, Honda Y. Hyperbaric oxygen treatment for macular edema after retinal vein occlusion-fluorescein angiographic findings and visual prognosis. *Nippon Ganka Gakkai Zasshi* 1995;99:220-5.
 197. Bhatt UK. Radial optic neurotomy in retinal vein occlusion. *Am J Ophthalmol* 2004;137:970-1.
 198. The Central Retinal Vein Occlusion Study Group. Natural history and clinical management of central retinal vein occlusion. *Arch Ophthalmol* 1997;115:486-91.
 199. Hasselbach HC, Ruefer F, Feltgen N, et al. Treatment of central retinal vein occlusion by radial optic neurotomy in 107 cases. *Graefes Arch Clin Exp Ophthalmol* 2007;245:1145-56.
 200. Weizer JS, Stinnett SS, Fekrat S. Radial optic neurotomy as treatment for central retinal vein occlusion. *Am J Ophthalmol* 2003;136:814-9.
 201. Madhusudhana KC, Newsom RS. Central retinal vein occlusion: the therapeutic options. *Can J Ophthalmol* 2007;42:193-5.
 202. Feltgen N, Junker B, Agostini H, Hansen LL. Retinal endovascular lysis in ischemic central retinal vein occlusion: one-year results of a pilot study. *Ophthalmology* 2007;114:716-23.
 203. Shahid H, Hossain P, Amoaku WM. The management of retinal vein occlusion: is interventional ophthalmology the way forward? *Br J Ophthalmol* 2006;90:627-39.
 204. The Central Retinal vein Occlusion Study Group. A randomized clinical trial of early panretinal photocoagulation for ischemic retinal vein occlusion. *Ophthalmology* 1995;102:1434-44.
 205. Lee YH, Lee JY, Kim YS, Kim DH, Kim J. Successful anticoagulation for bilateral central retinal vein occlusions accompanied by cerebral venous thrombosis. *Arch Neurol* 2006;63:1648-51.
 206. Spandau UH, Ihloff AK, Jonas JB. Intravitreal bevacizumab treatment of macular oedema due to central retinal vein occlusion. *Acta Ophthalmol Scand* 2006;84:555-6.
 207. Wright JK, Franklin B, Zant E. Clinical case report: treatment of a central retinal vein occlusion with hyperbaric oxygen. *Undersea Hyperb Med* 2007;34:315-9.
 208. Johnson GP. Cases from the aerospace medicine residents' teaching file: Case #38. A navigator with nonischemic central retinal vein occlusion progressing to ischemic central retinal vein occlusion. *Aviat Space Environ Med* 1990;61:962-5.
 209. Miyamoto H, Ogura Y, Wakano Y, Honda Y. The long term results of hyperbaric oxygen treatment for macular edema with retinal vein occlusion.

- Nippon Ganka Gakkai Zasshi* 1993;97:1065-9.
210. Gismondi A, Colonna S, Micalella F, Metrangolo C. Hyperbaric oxygen therapy in thrombotic occlusion of the central retinal vein. *Minerva Med* 1981;72:1413-5.
 211. Greiner KH, Lang GE. Risk-adapted management of central vein occlusions. *Ophthalmologe* 1999;96:736-40.
 212. Lang GE, Kuba GB. High-altitude retinopathy. *Am J Ophthalmol* 1997;123:418-20.
 213. Yuzurihara D, Ijima H. Visual outcome in central retinal and branch retinal artery occlusion. *Jpn J Ophthalmol* 2004;48:490-2.
 214. Ros MA, Magargal LE, Uram M. Branch retinal artery obstruction: a review of 201 eyes. *Ann Ophthalmol* 1989;21:103-7.
 215. Yamamoto K, Tsujikawa A, Hangai M, Fujihara M, Iwawaki T, Kurimoto Y. Neovascular glaucoma after branch retinal artery occlusion. *Jpn J Ophthalmol* 2005;49:388-90.
 216. Mason JO 3rd, Nixon PA, Albert MA Jr. Transluminal nd:YAG laser embolysis for branch retinal artery occlusion. *Retina* 2007;27:573-7.
 217. Aisenbrey S, Krott R, Heller R, Krauss D, Rossler G, Heimann K. Hyperbaric oxygen therapy in retinal artery occlusion. *Ophthalmologe* 2000;97:461-7.
 218. Imai E, Kunikata H, Udono T, Nakagawa Y, Abe T, Tamai M. Branch retinal artery occlusion: a complication of iron-deficiency anemia in a young adult with a rectal carcinoid. *Tohoku J Exp Med* 2004;203:141-4.
 219. Branch Retinal Vein Occlusion Study Group. Argon laser photocoagulation for macular edema in branch vein occlusion. *Am J Ophthalmol* 1984;98:271-82.
 220. Klein R, Klein BE, Moss SE, Meuer SM. The epidemiology of retinal vein occlusion: the Beaver Dam Eye Study. *Trans Am Ophthalmol Soc* 2000;98:133-41.
 221. Mitchell P, Smith W, Chang A. Prevalence and associations of retinal vein occlusion in Australia. The Blue Mountain Eye Study. *Arch Ophthalmol* 1996;114:1243-7.
 222. Kumar B, Yu DY, Morgan WH, Barry CJ, Constable IJ, McAllister IL. The distribution of angioarchitectural changes within the vicinity of the arteriovenous crossing in branch retinal vein occlusion. *Ophthalmology* 1998;105:424-7.
 223. Weinberg D, Dodwell DG, Fern SA. Anatomy of arteriovenous crossings in branch retinal vein occlusion. *Am J Ophthalmol* 1990;109:298-302.
 224. Frangieh GT, Green WR, Barraquer-Somers E, Finkelstein D. Histopathologic study of nine branch retinal vein occlusions. *Arch Ophthalmol* 1982;100:1132-40.
 225. Clemett RS, Kohner EM, Hamilton AM. The visual prognosis in retinal branch vein occlusion. *Trans Ophthalmol Soc U K* 1973;93:523-35.
 226. The Branch Retinal Vein Occlusion Study Group. Argon laser scatter photocoagulation for prevention of neovascularization and vitreous hemorrhage in branch vein occlusion: a randomized clinical trial. *Arch Ophthalmol* 1986;104:34-41.
 227. Gutman FA, Zegarra H. Macular edema secondary to occlusion of retinal veins. *Surv Ophthalmol* 1984;26:462-70.
 228. Greer DV, Constable IJ, Cooper RL. Macular edema and retinal branch vein occlusion. *Aust J Ophthalmol* 1980;8:207-9.
 229. Gutman FA, Zegarra H. The natural course of temporal retinal branch vein occlusion. *Trans Am Acad Ophthalmol Otolaryngol* 1974;78:178-92.
 230. Michels RG, Gass JD. The natural course of retinal branch vein obstruction. *Trans Am Acad Ophthalmol Otolaryngol* 1974;78:166-77.
 231. McIntosh RL, Mohamed Q, Saw SM, Wong TY. Interventions for branch retinal vein occlusion: an evidence-based systematic review. *Ophthalmology* 2007;114:835-54.
 232. Clemett RS. Preretinal membranes. *Trans Ophthalmol Soc N Z* 1984;36:25-30.
 233. Hayreh SS. Classification of central retinal vein occlusion. *Ophthalmology* 1983;90:458-74.
 234. Gass JDM, Norton EDW. Cystoid macular edema and papilledema following cataract extraction: a fluorescein fundoscopic and angiographic study. *Arch Ophthalmol* 1966;76:221-4.
 235. Gass JD, Anderson DR, Davis EB. A clinical, fluorescein angiographic, and electron microscopic correlation of cystoid macular edema. *Am J Ophthalmol* 1985;100:82-6.
 236. Coscas G, Gaudric A. Natural course of nonaphakic cystoid macular edema. *Surv Ophthalmol* 1984;28 (Suppl):471-84.
 237. Quinlan PM, Elman MJ, Bhatt AK, Mardesich P, Enger C. The natural course of central retinal vein occlusion. *Am J Ophthalmol* 1990;110:118-23.
 238. Dick JSB, Jampol LM, Haller JA. Macular edema. In: Ryan SJ, ed: *Retina*. St. Louis: Mosby, 2001:973-985.
 239. Vinos SA, Youssri AI, Luna JD, et al. Upregulation of vascular endothelial growth factor in ischemic and non-ischemic human and experimental retinal disease. *Histol Histopathol* 1997;12:99-109.
 240. Schaal KB, Hoh AE, Scheuerle A, Schutt F, Dithmar S. Bevacizumab for the treatment of macular edema secondary to retinal vein occlusion. *Ophthalmologe* 2007;104:285-9.
 241. Rabena MD, Pieramici DJ, Castellarin AA, Nasir MA, Avery RL. Intravitreal bevacizumab (Avastin) in the treatment of macular edema secondary to branch retinal vein occlusion. *Retina* 2007;27:419-25.
 242. Iturralde D, Spaide RF, Meyerle CB, et al. Intravitreal bevacizumab (Avastin) treatment of macular edema in central retinal vein occlusion: a short-term study. *Retina* 2006;26:279-84.

243. Tamura H, Miyamoto K, Kiryu J, et al. Intravitreal injection of corticosteroid attenuates leukostasis and vascular leakage in experimental diabetic retina. *Invest Ophthalmol Vis Sci* 2005;46:1440-4.
244. Rosenfeld PJ, Fung AE, Puliafito CA. Optical coherence tomography findings after an intravitreal injection of bevacizumab (Avastin) for macular edema from central retinal vein occlusion. *Ophthalmic Surg Lasers Imaging* 2005;36:336-9.
245. Antonetti DA, Wolpert EB, DeMaio L, Harhaj NS, Scaduto RC. Hydrocortisone decreases retinal endothelial cell water and solute flux coincident with increased content and decreased phosphorylation of occludin. *J Neurochem* 2002;80:667-77.
246. Gardner TW, Antonetti DA, Barber AJ, Lieth E, Tarbell JA. The molecular structure and function of the inner blood-retinal barrier. Penn State Retina Research Group. *Doc Ophthalmol* 1999;97:229-37.
247. Nauck M, Karakiulakis G, Perruchoud AP, Papakonstantinou E, Roth M. Corticosteroids inhibit the expression of the vascular endothelial growth factor gene in human vascular smooth muscle cells. *Eur J Pharmacol* 1998;341:309-15.
248. Nauck M, Roth M, Tamm M, Eickelberg O, et al. Induction of vascular endothelial growth factor by platelet-activating factor and platelet-derived growth factor is down-regulated by corticosteroids. *Am J Resp Cell Mol Biol* 1998;16:398-406.
249. Cox SN, Hay E, Bird AC. Treatment of chronic macular edema with acetazolamide. *Arch Ophthalmol* 1988;106:1190-5.
250. Marmor MF, Maack T. Enhancement of retinal adhesion and subretinal fluid resorption by acetazolamide. *Invest Ophthalmol Vis Sci* 1982;23:121-4.
251. Park CH, Jaffe GJ, Fekrat S. Intravitreal triamcinolone acetonide in eyes with cystoid macular edema associated with central retinal vein occlusion. *Am J Ophthalmol* 2003;136:419-25.
252. Jonas JB, Akkoyun I, Kreissig I, Degenring RF. Diffuse diabetic macular oedema treated by intravitreal triamcinolone acetonide: a comparative, non-randomized study. *Br J Ophthalmol* 2005;89:321-6.
253. Ozkiris A, Evereklioglu C, Erkilic K, Ilhan O. The efficacy of intravitreal triamcinolone acetonide on macular edema in branch retinal vein occlusion. *Eur J Ophthalmol* 2005;15:96-101.
254. Avitabile T, Longo A, Reibaldi A. Intravitreal triamcinolone compared with macular laser grid photocoagulation for the treatment of cystoid macular edema. *Am J Ophthalmol* 2005;140:695-702.
255. Williamson TH, O'Donnell A. Intravitreal triamcinolone acetonide for cystoid macular edema in nonischemic central retinal vein occlusion. *Am J Ophthalmol* 2005;139:860-6.
256. Chen SD, Lochhead J, Patel CK, Frith P. Intravitreal triamcinolone acetonide for ischaemic macular oedema caused by branch retinal vein occlusion. *Br J Ophthalmol* 2004;88:154-5.
257. Bashshur ZF, Ma'luf RN, Allam S, Jurdi FA, Haddad RS, Nouredin BN. Intravitreal triamcinolone for the management of macular edema due to nonischemic central retinal vein occlusion. *Arch Ophthalmol* 2004;122:1137-40.
258. Ip MS. Intravitreal injection of triamcinolone: an emerging treatment for diabetic macular edema. *Diabetes Care* 2004;27:1794-7.
259. Greenberg PB, Martidis A, Rogers AH, Duker JS, Reichel E. Intravitreal triamcinolone acetonide for macular oedema due to central retinal vein occlusion. *Br J Ophthalmol* 2002;86:247-8.
260. Jonas JB, Kreissig I, Degenring RF. Intravitreal triamcinolone acetonide as treatment of macular edema in central retinal vein occlusion. *Graefes Arch Clin Exp Ophthalmol* 2002;240:782-3.
261. Osterloh MD, Charles S. Surgical decompression of branch retinal vein occlusions. *Arch Ophthalmol* 1988;106:1469-71.
262. Kumagai K, Furukawa M, Ogino N, Larson E, Uemura A. Long-term visual outcomes after vitrectomy for macular edema with foveal hemorrhage in branch retinal vein occlusion. *Retina* 2007;27:584-8.
263. Mason J3rd, Feist R, White M Jr, Swanner J, McGwin G Jr, Emond T. Sheathotomy to decompress branch retinal vein occlusion: a matched control study. *Ophthalmology* 2004;111:540-5.
264. Mester U, Dillinger P. Vitrectomy with arteriovenous decompression and internal limiting membrane dissection in branch retinal vein occlusion. *Retina* 2002;22:740-6.
265. Shah GK, Sharma S, Fineman MS, Federman J, Brown MM, Brown GC. Arteriovenous adventitial sheathotomy for the treatment of macular edema associated with branch retinal vein occlusion. *Am J Ophthalmol* 2000;129:104-6.
266. Opremack EM, Bruce RA. Surgical decompression of branch retinal vein occlusion via arteriovenous crossing sheathotomy: a prospective review of 15 cases. *Retina* 1999;19:1-5.
267. Cahill MT, Kaiser PK, Sears JE, Fekrat S. The effect of arteriovenous sheathotomy on cystoid macular oedema secondary to branch retinal vein occlusion. *Br J Ophthalmol* 2003;87:1329-32.
268. LeRouic JF, Beggani RA, Rumen F, et al. Adventitial sheathotomy for decompression of recent onset branch retinal vein occlusion. *Graefes Arch Clin Exp Ophthalmol* 2001;239:747-51.
269. The Central Retinal Vein Occlusion Study Group. Evaluation of grid pattern photocoagulation for macular edema in central vein occlusion. *Ophthalmology* 1994;102:1425-33.
270. Molnar I, Poitry S, Tsacopoulos M, Gilodi N, Leuenberger PM. Effect of laser photocoagulation

- on oxygenation of the retina in miniature pigs. *Invest Ophthalmol Vis Sci* 1985;26:1410-4.
271. Blankenship GW, Okun E. Retinal tributary vein occlusion. History and management by photocoagulation. *Arch Ophthalmol* 1973;89:363-8.
 272. Campbell CJ, Wise GN. Photocoagulation therapy of branch retinal vein obstructions. *Am J Ophthalmol* 1973;75:28-31.
 273. Krill AE, Archer D, Newell FW. Photocoagulation in complications secondary to branch retinal vein occlusion. *Arch Ophthalmol* 1971;85:48-60.
 274. Shilling JS, Jones CA. Retinal branch vein occlusion: a study of argon laser photocoagulation in the treatment of macular oedema. *Br J Ophthalmol* 1984;68:196-8.
 275. Wetzig PC. The treatment of acute branch vein occlusion by photocoagulation. *Am J Ophthalmol* 1979;87:65-73.
 276. Tranos PG, Wickremasinghe SS, Stangos NT, Topouzis F, Tsinopoulos I, Pavesio CE. Macular edema. *Surv Ophthalmol* 2004;49:470-90.
 277. Jansen EC, Nielsen NV. Promising visual improvement of cystoid macular oedema by hyperbaric oxygen therapy. *Acta Ophthalmol Scand* 2004;82:485-6.
 278. Krott R, Heller R, Aisenbrey S, Bartz-Schmidt KU. Adjunctive hyperbaric oxygenation in macular edema of vascular origin. *Undersea Hyperb Med* 2000;27:195-204.
 279. Kiryu J, Ogura Y. Hyperbaric oxygen treatment for macular edema in retinal vein occlusion: relation to severity of retinal leakage. *Ophthalmologica* 1996;210:168-70.
 280. Miyake Y, Awaya S, Takahashi H, Tomita N, Hirano K. Hyperbaric oxygen and acetazolamide improve visual acuity in patients with cystoid macular edema by different mechanisms. *Arch Ophthalmol* 1993;111:1605-6.
 281. Mandai M, Ogura Y, Honda Y. Effects of hyperbaric oxygen treatment on macular edema. *Folia Ophthalmol Jpn* 1990;41:578-83.
 282. Ogura Y, Takahashi M, Ueno S, Honda Y. Hyperbaric oxygen treatment for chronic cystoid macular edema after branch retinal vein occlusion. *Am J Ophthalmol* 1987;104:301-2.
 283. Roy M, Bartow W, Ambrus J, Fauci A, Collier B, Titus J. Retinal leakage in retinal vein occlusion: reduction after hyperbaric oxygen. *Ophthalmologica* 1989;198:78-83.
 284. Xu YN, Huang JG. Hyperbaric oxygen treatment for cystoid macular edema secondary to retinal vein occlusion. *Zhonghua Yan Ke Za Zhi* 1991;27:216-8.
 285. Ishida K, Suzuki A, Ogino N. Oxygenation under hyperbaric pressure for cystoid macular edema. *Jpn J Clin Ophthalmol* 1989;43:1171-4.
 286. Pfoff DS, Thom SR. Preliminary report on the effect of hyperbaric oxygen on cystoid macular edema. *J Cataract Refract Surg* 1987;13:136-40.
 287. Coma MC, Sobrin L, Onal S, Christen W, Foster CS. Intravitreal bevacizumab for treatment of uveitic macular edema. *Ophthalmology* 2007;114:1574-9.
 288. Okinami S, Nihira M, Iwaki M, Sunakawa M, Arai I. Hyperbaric oxygen therapy for cystoid macular edema in uveitis. *Jpn J Clin Ophthalmol* 1992;46:199-201.
 289. Suttorp-Schulten MS, Riemsdag FC, Rothova A, van der Kley AJ. Long-term effect of repeated hyperbaric oxygen therapy on visual acuity in inflammatory cystoid macular oedema. *Br J Ophthalmol* 1997;81:329.
 290. Jarvis RM, Neufeld MV, Westfall CT. Brown recluse spider bite to the eyelid. *Ophthalmology* 2000;107:1492-6.
 291. Boland ME, Roper SM, Henry JA. Complications of quinine poisoning. *Lancet* 1985;1:384-5.
 292. Dyson EH, Proudfoot AT, Prescott LF, Heyworth R. Death and blindness due to overdose of quinine. *Br Med J* 1985;291:31-3.
 293. Wolff RS, Wirtschafter D, Adkinson C. Ocular quinine toxicity treated with hyperbaric oxygen. *Undersea Hyperb Med* 1997;24:131-4.
 294. Bacon P, Spalton DJ, Smith SE. Blindness from quinine toxicity. *Br J Ophthalmol* 1988;72:219-24.
 295. Sharma AG, Kazim NA, Elliott D, Houghton O, Abrams GW. Purtscher's retinopathy that occurred 6 months before acute pancreatitis. *Am J Ophthalmol* 2006;141:205-7.
 296. Sanders RJ, Brown GC, Brown A, Gerner EW. Purtscher's retinopathy preceding acute pancreatitis. *Ann Ophthalmol* 1992;24:19-21.
 297. Agrawal A, McKibbin M. Purtscher's retinopathy: epidemiology, clinical features and outcome. *Br J Ophthalmol* 2007;91:1456-9.
 298. Carrera CR, Pierre LM, Medina FM, Pierre-Filho Pde T. Purtscher-like retinopathy associated with acute pancreatitis. *Sao Paulo Med J* 2005;123:289-91.
 299. Lin YC, Yang CM, Lin CL. Hyperbaric oxygen treatment in Purtscher's retinopathy induced by chest injury. *J Chin Med Assoc* 2006;69:444-8.
 300. Foster-Moore R. Radiation retinopathy. Transactions of the Ophthalmological Societies of the UK 1935;55:3-26.
 301. Quinn AG, Clemett RS. Retinopathy after low-dose retinal irradiation. *Aust N Z J Ophthalmol* 1993;21:193-7.
 302. Saunders RA, Bluestein EC, Wilson ME, Berland JE. Anterior segment ischemia after strabismus surgery. *Surv Ophthalmol* 1994;38:456-66.
 303. de Smet MD, Carruthers J, Lepawsky M. Anterior segment ischemia treated with hyperbaric oxygen. *Can J Ophthalmol* 1987;22:381-3.
 304. Murdock TJ, Kushner BJ. Anterior segment ischemia after surgery on two vertical rectus muscles augmented with lateral fixation sutures. *J AAPOS* 2001;5:323-4.
 305. Pfister RR. The intraocular changes of anterior

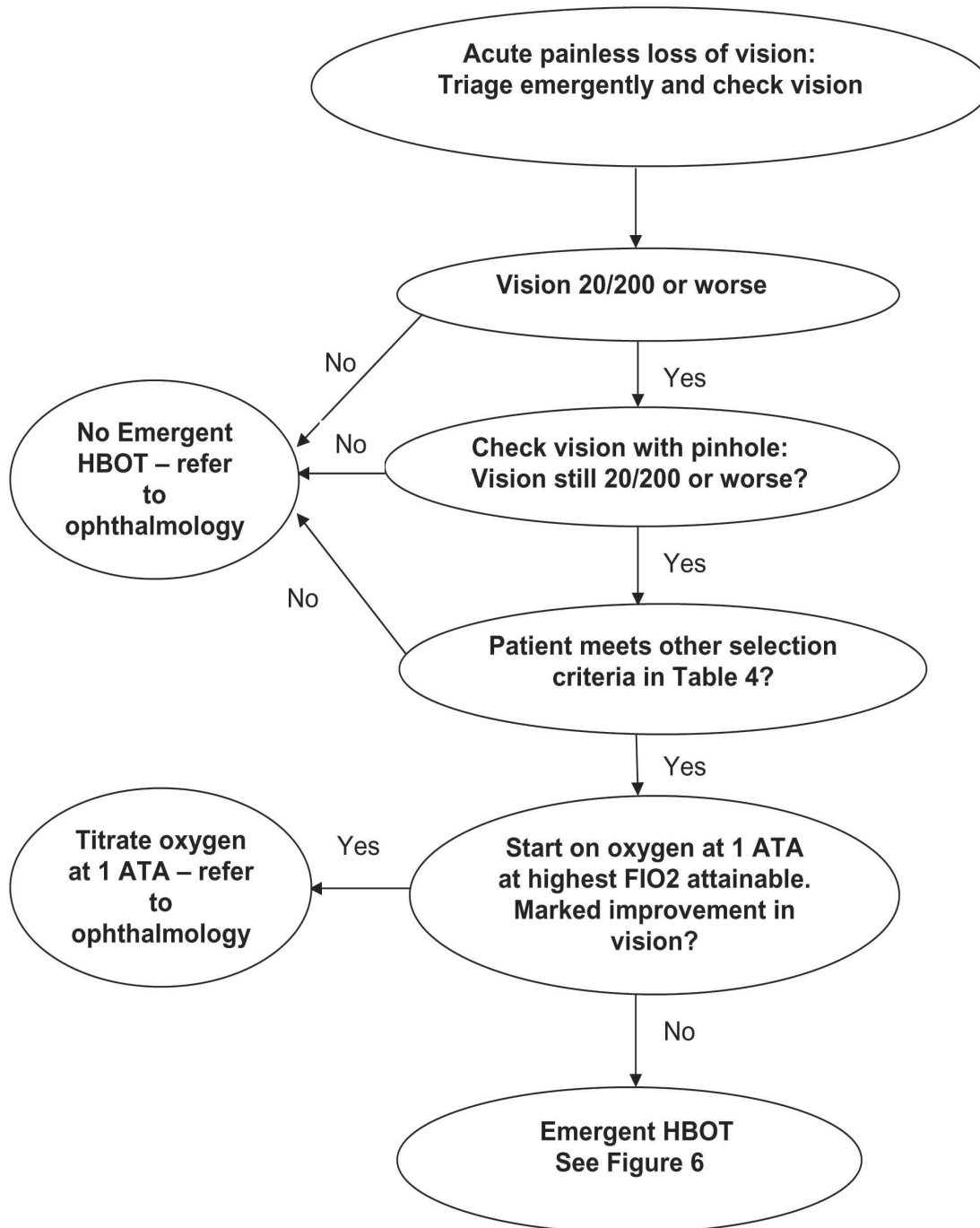
- segment necrosis. *Eye* 1991;5:214-21.
306. Freilich DB, Seelenfreund MH. Hyperbaric oxygen, retinal detachment, and sickle cell anemia. *Arch Ophthalmol* 1973;90:90-3.
 307. Freilich DB, Seelenfreund MH. The use of hyperbaric oxygen in the treatment of retinal detachment in patients with sickle cell disease. *Isr J Med Sci* 1972;8:1458-61.
 308. Freilich DB, Seelenfreund MH. Further studies in the use of hyperbaric oxygen in retinal detachment with sickle cell anemia. *Mod Probl Ophthalmol* 1975;15:313-7.
 309. Freilich DB, Seelenfreund MH. Long-term follow-up of scleral buckling procedures with sickle cell disease and retinal detachment treated with the use of hyperbaric oxygen. *Mod Probl Ophthalmol* 1977;18:368-72.
 310. Shauly Y, Nachum Z, Gdal-On M, Melamed Y, Miller B. Adjunctive hyperbaric oxygen therapy for actinomycotic lacrimal canaliculitis. *Graefes Arch Clin Exp Ophthalmol* 1993;231:429-31.
 311. Newman WD, Frank HJ. Pyoderma gangrenosum of the orbit. *Eye* 1993;7:89-94.
 312. Chong R, Ayer CJ, Francis IC, Coroneo MT, Wolfers DL. Adjunctive hyperbaric oxygen in pseudomonas keratitis. *Br J Ophthalmol* 2007;91:560-1.
 313. Averous K, Erginay A, Timsit J, Haouchine B, Gaudric A, Massin P. Resolution of diabetic macular oedema following high altitude exercise. *Acta Ophthalmol Scand* 2006;84:830-1.
 314. Ogura Y, Kiryu J, Takahashi K, Honda Y. Visual improvement in diabetic macular edema by hyperbaric oxygen treatment. *Nippon Ganka Gakkai Zasshi* 1988;92:1456-60.
 315. Fischer BH, Marks M, Reich T. Hyperbaric oxygen treatment of multiple sclerosis: a randomized, placebo-controlled, double-blind study. *N Engl J Med* 1983;308:181-6.
 316. Bennett M, Heard R. Hyperbaric oxygen therapy for multiple sclerosis. *Cochrane Database Syst Rev* 2004:CD003057.
 317. Bennett M, Heard R. Treatment of multiple sclerosis with hyperbaric oxygen therapy. *Undersea Hyperb Med* 2001;28:117-22.
 318. Neiman J, Nilsson BY, Barr PO, Perrins DJ. Hyperbaric oxygen in chronic progressive multiple sclerosis: visual evoked potentials and clinical effects. *J Neurol Neurosurg Psychiatry* 1985;48:497-500.
 319. Perrins DJ, James PB. Hyperbaric oxygen therapy and multiple sclerosis. *Undersea Hyperb Med* 2002;29:236-8.
 320. Baumgartner WA. Etiology, pathogenesis, and experimental treatment of retinitis pigmentosa. *Med Hypotheses* 2000;54:814-24.
 321. Vingolo EM, Pelaia P, Forte R, Rocco M, Giusti C, Rispoli E. Does hyperbaric oxygen (HBO) delivery rescue retinal photoreceptors in retinitis pigmentosa? *Doc Ophthalmol* 1999;97:33-9.
 322. Skogstad M, Bast-Pettersen R, Tynes T, Bjornsen D, Aaserud O. Treatment with hyperbaric oxygen. Illustrated by the treatment of a patient with retinitis pigmentosa. *Tidsskr Nor Laegeforen* 1994;114:2480-3.
 323. Kuroki AM, Kitaoka T, Taniguchi H, Amemiya T. Hyperbaric oxygen therapy reduces visual field defect after macular hole surgery. *Ophthalmic Surg Lasers* 2002;33:200-6.
 324. Mervin K, Valter K, Maslim J, Lewis G, Fisher S, Stone J. Limiting photoreceptor death and deconstruction during experimental retinal detachment: the value of oxygen supplementation. *Am J Ophthalmol* 1999;128:155-64.
 325. Lewis G, Mervin K, Valter K, et al. Limiting the proliferation and reactivity of retinal Muller cells during experimental retinal detachment: the value of oxygen supplementation. *Am J Ophthalmol* 1999;128:165-72.
 326. Ersanli D, Karadayi K, Toyran S, et al. The efficacy of hyperbaric oxygen for the treatment of experimental uveitis induced in rabbits. *Ocul Immunol Inflamm* 2005;13:383-8.
 327. Hirst LW, Summers PM, Griffiths D, Bancroft J, Lillicrap GR. Controlled trial of hyperbaric oxygen treatment for alkali corneal burn in the rabbit. *Clin Experiment Ophthalmol* 2004;32:67-70.
 328. Ng JD, Nunery WR, Martin RT, Ng PA, Bonnin JM, Elkins AD. Effects of hyperbaric oxygen therapy on hydroxyapatite orbital implant vascularization in rabbits. *Ophthal Plast Reconstr Surg* 2001;17:254-63.
 329. DeBacker CM, Dutton JJ, Proia AD, Halperin EC, Wagle TN, Holck DE. The influence of hyperbaric oxygen therapy and irradiation on hydroxyapatite ocular implant exposure and fibrovascular ingrowth in New Zealand white rabbits. *Ophthal Plast Reconstr Surg* 1999;15:412-9.
 330. Bojic L, Kovacevic H, Andric D, Romanovic D, Petri NM. Hyperbaric oxygen dose of choice in the treatment of glaucoma. *Arh Hig Rada Toksikol* 1993;44:239-47.
 331. Bojic L, Racic G, Gosovic S, Kovacevic H. The effect of hyperbaric oxygen breathing on the visual field in glaucoma. *Acta Ophthalmol (Copenh)* 1993;71:315-9.
 332. Henkind P. Hyperbaric oxygen and corneal neovascularisation. *Lancet* 1964;2:836-8.
 333. Kern M, Sommerauer P, Wocheslander E, Schuhmann G, Kohek P, Stolze A. Use of hyperbaric oxygen therapy in patients with tobacco-alcohol amblyopia. *Fortschr Ophthalmol* 1986;83:312-4.
 334. Recupero SM, Cruciani F, Picardo V, Sposato PA, Tamanti N, Abdolrahimzadeh S. Hyperbaric oxygen therapy in the treatment of secondary keratoendotheliosis. *Ann Ophthalmol* 1992;24:448-52.
 335. Wallyn CR, Jampol LM, Goldberg MF, Zanetti

- CL. The use of hyperbaric oxygen therapy in the treatment of sickle cell hyphema. *Invest Ophthalmol Vis Sci* 1985;26:1155-8.
336. Ehlers JP, Shah CP, eds. The Wills Eye Manual. Baltimore: Lippincott Williams and Wilkins, 2008:442-3.
337. Oguz H, Sobaci G. The use of hyperbaric oxygen therapy in ophthalmology. *Surv Ophthalmol* 2008;53:112-20.
338. Donald KW. Oxygen and the Diver. Worshester: The Spa, Ltd, 1992:104.
339. Hendricks PL, Hall DA, Hunter WL Jr, Haley PJ. Extension of pulmonary O₂ tolerance in man at 2 ATA by intermittent O₂ exposure. *J Appl Physiol* 1977;42:593-9.
340. Shupak A, Abramovich A, Adir Y, et al. Effects on pulmonary function of daily exposure to dry or humidified hyperbaric oxygen. *Respir Physiol* 1997;108:241-6.
341. Thorsen E, Aanderud L, Aasen TB. Effects of a standard hyperbaric oxygen treatment protocol on pulmonary function. *Eur Respir J* 1998;12:1442-5.
342. Butler FK, Smith DJ. United States Navy Diving Techniques and Equipment. In: Bove and Davis Diving Medicine. Bove AA, ed. Philadelphia: WB Saunders, Fourth Edition, 2004:372-87.
343. Butler FK, Thalmann ED. Central nervous system oxygen toxicity in closed circuit scuba divers II. *Undersea Biomed Res* 1986;13:193-223.
344. Butler FK, Thalmann ED. Central nervous system oxygen toxicity in closed circuit SCUBA divers. In: Bachrach AJ, Matzen MM, eds. Underwater Physiology VIII: Proceedings of the Eighth Symposium in Underwater Physiology. Bethesda: Undersea Medical Society; 1984:15-30
345. Pontani BA, Alexander K, Williams RL. 10,000 dives: a comprehensive review of 14 years of experience. *Undersea Hyperb Med* 2007;34:273.
346. Witucki P, Grover I, Ducknick J, Neuman T. Incidence of oxygen seizures in HBO chamber attendants. *Undersea Hyperb Med* 2007;34:250.
347. Nichols CW, Lambertsen CJ, Clark JM. Transient unilateral loss of vision associated with oxygen at high pressure. *Arch Ophthalmol* 1969;81:548-52.
348. Clark JM Thom S. Oxygen under pressure. In: Brubakk AO NT, ed. Bennett and Elliott's Physiology and Medicine of Diving. London: WB Saunders, 2003:358-418.
349. Kinney JS. Human Underwater Vision: Physiology and Physics. Bethesda: Undersea and Hyperbaric Society, 1985:158.
350. Behnke AR, Forbes HS, Motley EP. Circulatory and visual effects of oxygen at 3 atmospheres pressure. *Am J Physiol* 1935;114:436-42.
351. Lambertsen CJ, Clark JM, Gelfand R. Definition of tolerance in continuous hyperoxia in man: an abstract report of Predictive Studies V. In: Proceedings of the Ninth International Symposium on Underwater and Hyperbaric Physiology. Bove AA, bachrach AJ, Greenbaum LJ, eds. Bethesda: Undersea and Hyperbaric Medical Society, 1987:717-735.
352. Miller EF. Effect of breathing 100 per cent oxygen upon visual field and visual acuity. *J Aviat Med* 1958;29:598-602.
353. Bridges WZ. Electroretinographic manifestations of hyperbaric oxygen. *Arch Ophthalmol* 1966;75:812-7.
354. Noell WK. Effect of high and low oxygen tension on the visual system. In: Schaeffer KE, ed. Environmental effects on consciousness. New York: MacMillan, 1962:3-18.
355. Beehler CC, Newton NL, Culver JF, Tredici T. Ocular Hyperoxia. *Aerosp Med* 1963;34:1017-20.
356. Ubels JL, Hoffert JR. Ocular oxygen toxicity: the effect of hyperbaric oxygen on retinal Na⁺-K⁺ ATPase. *Exp Eye Res* 1981;32:77-84.
357. Patz A. The effect of oxygen on immature retinal vessels. *Invest Ophthalmol* 1965;4:988-99.
358. Terry TL. Extreme prematurity and fibroblastic overgrowth of persistent vascular sheath behind each crystalline lens: a preliminary report. *Am J Ophthalmol* 1942;25:203.
359. Beehler CC. Oxygen and the eye. *Aeromed Rev* 1964;3:1-21.
360. Fledelius HC, Jansen EC, Thorn J. Refractive change during hyperbaric oxygen therapy. A clinical trial including ultrasound oculometry. *Acta Ophthalmol Scand* 2002;80:188-90.
361. Thom SR, Clark JM. The toxicity of oxygen, carbon monoxide, and carbon dioxide. In: Bove AA, ed. Bove and davis Diving Medicine. Philadelphia; WB Saunders, 1997:131-145.
362. Ross ME, Yolton DP, Yolton RL, Hyde KD. Myopia associated with hyperbaric oxygen therapy. *Optom Vis Sci* 1996;73:487-94.
363. Anderson B, Shelton D. Axial length in hyperoxic myopia. 1987:607-11.
364. Palmquist BM, Philipson B, Barr PO. Nuclear cataract and myopia during hyperbaric oxygen therapy. *Br J Ophthalmol* 1984;68:113-7.
365. Anderson B, Jr., Farmer JC, Jr. Hyperoxic myopia. *Trans Am Ophthalmol Soc* 1978;76:116-24.
366. Lyne AJ. Ocular effects of hyperbaric oxygen. *Trans Ophthalmol Soc U K* 1978;98:66-8.
367. Butler FK, White E, Twa M. Hyperoxic myopia in a closed-circuit mixed-gas scuba diver. *Undersea Hyperb Med* 1999;26:41-5.
368. Evanger K, Haugen OH, Aanderud L, Thorsen E, Pierscionek BK. Hypermetropia-succeeded myopia after hyperbaric oxygen therapy. *Optom Vis Sci* 2006;83:195-8.
369. Fledelius HC, Jansen E. Hypermetropic refractive change after hyperbaric oxygen therapy. *Acta Ophthalmol Scand* 2004;82:313-4.
370. Gesell LB, Trott A. De novo cataract development

- following a standard course of hyperbaric oxygen therapy. *Undersea Hyperb Med* 2007;34:389-92.
371. [McCartney PJ, McCartney PW. Vitreous haemorrhage after hyperbaric oxygen therapy. *Eye* 1994;8:705-6.](#)
372. [Nichols CW, Yanoff M, Hall DA, Lambertsen CJ. Histologic alterations produced in the eye by oxygen at high pressure. *Arch Ophthalmol* 1972;87:417-21.](#)
373. [Winkle RK, Mader TH, Parmley VC, White LJ, Polse KA. The etiology of refractive changes at high altitude after radial keratotomy: hypoxia vs hypobaria. *Ophthalmology* 1998;105:282.](#)
374. [Evanger K, Haugen OH, Irgens A, Aanderud L, Thorsen E. Ocular refractive changes in patients receiving hyperbaric oxygen administered by oronasal mask or hood. *Acta Ophthalmol Scand* 2004;82:449-53.](#)

APPENDIX I - Figure 6

Emergent HBOT for Acute Painless Loss of Vision Decision Algorithm



APPENDIX 2 - Figure 7

Emergent HBOT for Acute Painless Loss of Vision Treatment Algorithm

