

REVIEW ARTICLE

C. Corey Hardin, M.D., Ph.D., *Editor*

Decompression Sickness and Arterial Gas Embolism

Simon J. Mitchell, M.B., Ch.B., Ph.D., Michael H. Bennett, M.B., B.S., M.D., and Richard E. Moon, M.D.

From the School of Medicine, University of Auckland, and the Department of Anaesthesia, Auckland City Hospital — both in Auckland, New Zealand (S.J.M.); Prince of Wales Clinical School, University of New South Wales, and Wales Anaesthesia, Prince of Wales Hospital — both in Sydney (M.H.B.); and the Departments of Anesthesiology and Medicine, Duke University Medical Center, and the Center for Hyperbaric Medicine and Environmental Physiology, Duke University — both in Durham, North Carolina (R.E.M.). Prof. Mitchell can be contacted at sj.mitchell@auckland.ac.nz or at the Department of Anaesthesiology, University of Auckland, Private Bag 92019, Auckland 1142, New Zealand.

N Engl J Med 2022;386:1254-64.

DOI: 10.1056/NEJMr2116554

Copyright © 2022 Massachusetts Medical Society.

DECOMPRESSION SICKNESS, IN WHICH BUBBLES FORMED FROM DISSOLVED gas (usually nitrogen) cause tissue and vascular injury after a reduction in environmental pressure, may occur in diving, aviation, and spaceflight. Arterial gas embolism, in which bubbles introduced into the arterial circulation cause multifocal ischemia, may occur after diving-related, iatrogenic, or accidental pulmonary barotrauma or by direct iatrogenic introduction of gas into the vasculature. Because it may be difficult to clinically differentiate decompression sickness from arterial gas embolism in divers and the treatment protocols for the two disorders are the same, the term “decompression illness” is sometimes used to indicate the presence of decompression sickness, arterial gas embolism, or both, but the separate terms are used here. Divers with nonspecific symptoms may present to clinicians who have received no specific training during medical school or residency in dealing with these disorders, which can pose challenges in the differential diagnosis and choice of appropriate treatment.

HISTORY

The compressor technology required for diving was developed in the 1800s but was applied initially to coal shafts below the water table in the Loire Valley, in France. Flooding was prevented by pressurizing these shafts with the use of pneumatic pumps designed by Jacques Triger. Decompression sickness during that project was reported by Pol and Wattelle, who recorded joint pain, paralysis, coma, and death.¹ They also observed that the pain resolved on reentry into the pressurized environment, which was the first indication of a possible treatment.

Compressed-air technology, with pressurized dry work spaces (caissons), was first used in the United States for construction of the Eads Bridge, in St. Louis. The on-site physician, Alphonse Jaminet, observed decompression sickness and reported increased urine specific gravity in the affected workers. He recommended supine positioning, leg elevation, and oral fluids, a protocol that he affirmed on the basis of his personal experience of paralysis and aphasia after he underwent a provocative decompression (i.e., decompression of a nature that might presage decompression sickness); he self-treated by drinking beef tea and rum.²

Several similar projects followed, including construction of the Brooklyn Bridge, for which Andrew Smith provided medical oversight. He recommended the use of a separate chamber for recompression of injured men,³ but it was not until 1889, when Ernest Moir took over New York’s Hudson River Tunnel project, that such a facility was built and used. Immediate recompression of injured workmen reduced the death rate from 25% per annum to 2 deaths among 120 men in 15 months.⁴ In the same year, Snell reported similar efficacy for early recompression during construction of the Blackwall Tunnel under the Thames, in London.⁵ Reporting on another New York project, the East River Tunnels, Frederick Keays confirmed the

efficacy of early recompression in 3692 cases of decompression sickness, with a cure obtained in more than 90% of cases involving only pain and 60% of cases with central nervous system involvement.⁶

In parallel, early diving with compressed gas supplied from the surface was reported to result in cases of decompression sickness (sometimes fatal) in sponge and pearl divers.⁷ The first approaches to planning decompression on the basis of gas kinetic modeling were introduced by J.S. Haldane around the same time.⁸

Most modern diving is recreational, with divers breathing air through a self-contained, underwater breathing apparatus (scuba). Exhaled gas is usually expelled into the water; however, gas can be conserved with the use of rebreathing units. Rebreathers developed between world wars used 100% oxygen to facilitate clandestine dives without bubbles. Modern rebreathers combine oxygen and a diluent gas to maintain a constant partial pressure of inspired oxygen, irrespective of the depth.

In saturation diving, divers live in a hyperbaric environment at a pressure similar to that at the depth of the worksite and travel down to the worksite in a pressurized diving bell, from which they exit and work. Tissues become saturated with inert gas, and divers require a single, very slow decompression on project completion.⁹

In the 1930s, it was observed that decompression sickness could occur during rapid decompression to a high altitude in unpressurized aircraft, typically to more than 5500 m. In World War II, aircraft could fly at altitudes approaching 12,200 m, sometimes resulting in decompression sickness manifested as limb pain and cutaneous and neurologic symptoms.¹⁰ In this context, chest pain, cough, cyanosis, and syncope became known as “chokes.”¹¹ Reducing tissue nitrogen levels by prebreathing 100% oxygen attenuated the risk, a technique that was inconsistently applied during World War II but is now routine for high-altitude aircraft crew, since it reduces severe decompression sickness. Most altitude-induced cases now consist of limb pain.¹²

Since the International Space Station is maintained at sea-level pressure, an astronaut performing extravehicular activity undergoes substantial decompression to space-suit pressure (0.3 atmospheres absolute [ATA], or 30.4 kPa, equivalent to an altitude of 9100 m). The risk of decompression sickness induced by extravehicular

activity has been reduced by prolonged oxygen prebreathing combined with mild exercise to denitrogenate the astronaut before staged decompression. In 60 years of spaceflight, only one case of decompression sickness (knee pain) has been reported, by Michael Collins in 1966 during the Gemini 10 flight.¹³

Oxygen for the treatment of decompression sickness was first recommended by Paul Bert after he observed that oxygen administration in decompressed animals resulted in the resolution of intravascular bubbles.¹⁴ Hermann von Schrötter subsequently suggested the use of oxygen breathing to facilitate safer decompression, as well as treatment of decompression sickness with hyperbaric oxygen,¹⁵ techniques routinely used today. Studies supporting the increased efficacy of hyperbaric oxygen were performed in dogs and then later in humans, pioneered by Albert Behnke of the U.S. Navy.¹⁶ A review of air-breathing recompression failures led to the development and routine use of oxygen-breathing recompression, primarily to increase the gradient for the diffusion of inert gas from bubbles and tissue to arterial blood.¹⁷

PATHOPHYSIOLOGY

DECOMPRESSION SICKNESS

Bubble formation is presumed to be the primary mechanism of injury in decompression sickness. Divers absorb inert gas (nitrogen when air breathing) into tissues when breathing compressed gas during a dive, with more gas absorbed on deeper or longer dives. During the ascent, the partial pressure of dissolved gas in tissues may exceed ambient pressure (supersaturation), which leads to the formation of bubbles in those tissues or in the blood passing through them. This may also occur during rapid ascent from sea level to high altitude. The resulting venous gas emboli are small (19 to 700 μm)¹⁸ but extremely common after diving¹⁹ or rapid altitude exposure.²⁰ They are usually filtered by pulmonary capillaries and are asymptomatic. However, venous gas emboli can reach the arterial circulation by overwhelming the filtering capacity of the pulmonary capillary network or through intrapulmonary or intracardiac right-to-left shunts, such as atrial septal defects and patent foramen ovale (PFO).

The presence of a PFO increases the probability of cerebral, spinal cord, inner ear, and cuta-

neous decompression sickness,²¹⁻²³ presumably because tiny, arterialized venous gas emboli arriving in the capillaries of supersaturated tissues after a dive grow through inward diffusion of gas.²⁴ The vulnerability of the brain, which is highly perfused (thus rapidly eliminating inert gas) and unlikely to be supersaturated after a dive, probably arises from exposure to high numbers of small, arterialized venous gas emboli, perhaps coalesced to form larger bubbles, as has been reported after a strongly positive bubble contrast test for PFO.²⁵

Bubble formation within tissue may cause mechanical disruption and focal hemorrhage, particularly in white matter.²⁶ Even small intravascular bubbles may have physical effects, with inflammatory and thrombogenic host responses. Small doses of arterial gas can initiate a progressive decline in cerebral blood flow, an effect abolished by neutrophil depletion.²⁷ Intravascular bubbles may strip endothelial cells from the underlying basement membrane,²⁸ resulting in impaired regulation of vascular tone, plasma leak, and hypovolemia.²⁹ Through this mechanism, a high load of venous gas emboli can injure pulmonary capillaries and induce pulmonary edema.³⁰ Even without gross mechanical damage, bubble contact with endothelium can initiate the opening of transient receptor potential vanilloid ion channels, calcium entry, mitochondrial dysfunction, and cell death.³¹ Changes in the coagulation system after decompression include a slight reduction in circulating platelets due to activation and increased consumption,^{32,33} as well as increased circulating fibrin monomer.³⁴

Manifestations of decompression sickness in rats have been reduced by pretreatment with the glycoprotein IIb/IIIa receptor antagonist abciximab.³⁵ Decompression sickness-resistant male rats have increased prothrombin times and reduced circulating factor X levels.³⁶ Complement activation has also been reported.³⁷ Circulating microparticle levels are elevated after diving. The cause of this elevation is uncertain, but microparticles may play a proinflammatory role in decompression sickness.³⁸

ARTERIAL GAS EMBOLISM

Arterial gas embolism can occur in divers if expanding compressed gas is trapped in the lungs as ambient pressure falls during the ascent to the surface, causing rupture of alveolar-capillary membranes and gas entry into the pulmonary

vasculature. This may follow breath holding and hyperinflation of the entire lung, or it may be associated with local disease such as bronchial obstruction or bullae, in which regional gas elimination is slower, causing focal hyperexpansion.³⁹ Arterial gas embolism can occur after an ascent to the surface from a depth as shallow as 1 m (pressure change, 0.1 atm).⁴⁰ There are also many accidental and iatrogenic causes of arterial gas embolism (see Table S1 in the Supplementary Appendix, available with the full text of this article at NEJM.org).⁴¹

Large intraarterial bubbles may cause arterial occlusion, ischemia, and infarction. Secondary effects in the brain after bubble-induced ischemia are probably similar to processes that occur after a stroke, including excitatory neurotransmitter release, oxidative stress, inflammation, and an immune response.⁴² Unlike solid thrombi in stroke, obstructing bubbles in arterial gas embolism may resolve or be redistributed into the venous circulation spontaneously or in response to recompression. In doing so, they may cause endothelial injury, inflammation, and plasma leak.

PRESENTATION AND DIAGNOSIS

Among divers, decompression sickness appears to be significantly more common than arterial gas embolism. In two recent case series, comprising 3018 cases, only 6.5% were diagnosed as arterial gas embolism.^{43,44}

DECOMPRESSION SICKNESS

In recreational scuba diving, the incidence of decompression sickness is low (0.4 to 1 case per 10,000 dives),^{43,45} but the risk is higher for deeper, longer dives and for dives in which decompression requirements are violated. The manifestations of decompression sickness are described in Table 1.^{44,46,47} These manifestations can occur singly or in combinations; the most severe cases typically have multiple manifestations. The proportion of cases in which each symptom occurs, shown in Table 1, is approximate; the specific proportion varies among subgroups of divers and according to specific characteristics of the dive. For example, inner ear decompression sickness is more common after deeper diving,⁴⁸ and musculoskeletal pain is the most prevalent form after saturation diving⁴⁹ and in altitude-induced decompression sickness.¹²

The manifestations may arise during decom-

Table 1. Clinical Manifestations of Decompression Sickness (DCS) According to Organ System.*

Affected Organ System and Manifestations	% of DCS Cases	Description
Musculoskeletal: pain	50–65	Often described as a deep, boring ache in shoulder, elbow, hip, or knee area, unaffected by joint movement, usually without local tenderness; may be multifocal and poorly localized
Cutaneous		
Rash and itch	5–10	An erythematous, poorly demarcated patch, often itchy, or a more clearly circumscribed, reticular rash with cyanotic discoloration (cutis marmorata or livedo racemosa); usually a truncal or proximal distribution
Patchy paresthesia	40–50	Nondermatomal distribution; often described as tingling
Lymphatic: subcutaneous swelling	1–5	Truncal distribution, similar to that of rash, particularly involving upper chest and shoulders
Spinal cord		
Motor weakness	20–25	Typically, paraplegia or quadriplegia with upper motor neuron signs; severity ranges from subtle to dense
Numbness or dense paresthesia	20–30	Dorsal columns appear to be vulnerable; proprioception may be affected
Bladder and sphincter dystonia	1	Bladder also becomes insensate; urinary retention
Girdle, chest, back, or abdominal pain	1–5	Typically, a premonitory symptom that precedes other spinal symptoms
Inner ear		
Vestibular: vertigo, ataxia	10–20	Usually accompanied by nausea and nystagmus; 75% of inner ear DCS cases have no other symptoms
Cochlear: hearing loss, tinnitus	1–5	Cochlear manifestations are less common than vestibular manifestations in DCS
Brain (cerebral): cognitive impairment, scotomata, visual field changes, focal weakness, ataxia	5–10	Typically, mild executive dysfunction (e.g., impaired concentration or memory); gross focal lesions considered to be less common in DCS than in AGE
Cardiopulmonary: dyspnea, cough, chest pain (“the chokes”)	1–5	Typically associated with provocative events such as rapid ascent or omitted decompression after deep dives
Cardiovascular: hemoconcentration, shock, coagulopathy	<1	Rare; typically associated with provocative events such as rapid ascent or omitted decompression after deep dives
Constitutional, including fatigue, malaise, headache	20–40	Often described as similar to a viral infection

* Approximate proportions of divers affected are based on data from various sources^{44,46,47} and the experience of the authors. AGE denotes arterial gas embolism.

pression from long, deep exposures but more typically arise early after the return to surface pressure. For example, in a series of 5278 cases of decompression sickness (49 of which included arterial gas embolism), symptoms developed within 1 hour after the diver resurfaced in 73% of the mild cases and in 98% of the severe cases, and 99% of all symptoms appeared within 6 hours.⁵⁰ A later onset is possible, even more than 24 hours after the dive, especially if there is postdive exposure to high altitude (e.g., a commercial flight),⁵¹ which is a common scenario among divers returning from vacation; such divers may seek help from family practitioners. In decompression sickness caused by an ascent to high altitude, symptoms may arise at high altitude or

after the return to ground level (in 23% and 77% of 528 cases, respectively, in one series).¹²

Symptoms are diverse and nonspecific, potentially posing a diagnostic challenge. All symptoms listed in Table 1 arise commonly from other causes and are easily attributed to more familiar diagnoses. Simply put, if the patient has been scuba diving and has become sick, then a high index of suspicion for decompression sickness or another diving disorder should be maintained.

In evaluating the likelihood of decompression sickness, several factors are important to consider, including compliance with recommended dive profiles (depth, duration, and ascent rate) provided by “dive tables” or personal diving com-

puters. A violation of those recommendations (e.g., missing recommended decompression stops) increases the risk of decompression sickness. Compliance reduces the risk but does not rule out the diagnosis, although in the case of some dives that are well within recommended limits, decompression sickness can be effectively ruled out. Dives shallower than 6 m cannot induce decompression sickness,⁵² but arterial gas embolism is certainly possible. Other risk factors include deeper dives (e.g., deeper than 21 m), rapid ascents, cold water dives, hardworking dives (i.e., those involving greater-than-normal physical exertion), and a history of decompression sickness. The compatibility of symptoms with decompression sickness (Table 1), the time to the onset of symptoms (few arise after more than 6 hours), and plausible alternative explanations all need to be considered. Table 2 shows a typical differential diagnosis, with potentially discriminating features noted.

Ideally, for any case of decompression sickness, a complete neurologic examination should be performed. Maneuvers that are sensitive for the detection of common diving-related neurologic syndromes include testing for Romberg's sign, sharpened Romberg's test,⁵³ and tests of gait and tandem gait (forward and backward with eyes open and with eyes closed).

ARTERIAL GAS EMBOLISM

Symptoms of arterial gas embolism develop quickly and often dramatically. In one series, symptoms occurred during the ascent, at the surface, or within 5 minutes after arrival at the surface in 107 of 116 diving cases (92%).⁵⁴ Latency longer than 10 minutes is rare. The ascent is often rapid, with panic-induced breath holding after an underwater mishap. Nevertheless, arterial gas embolism can occur during a normal ascent.⁵⁴ Clinical manifestations usually suggest cerebral involvement, with arterial gas often distributed in multiple cerebrovascular territories, with multifocal manifestations. In the series noted above, the most common initial manifestation was loss of consciousness (in 39% of cases), followed by confusion (37%), dizziness and presyncope (30%), hemiplegia (27%), visual changes (21%), headache (20%), dysphasia (11%), and seizures (11%).⁵⁴ In approximately half the cases, there were obvious symptoms of underlying pulmonary barotrauma, such as chest pain

and hemoptysis. Spontaneous recovery or improvement occurred in approximately half the cases, but there were relapses in some of those cases.⁵⁴ As with decompression sickness, it is important to consider the differential diagnosis for arterial gas embolism (Table 2).

Arterial gas embolism due to iatrogenic or other causes unrelated to diving is diagnostically challenging and easily overlooked unless air entrainment is directly observed. Arterial gas embolism can cause strokelike events during high-risk medical procedures and may also explain failure to wake, seizures, delirium, or strokelike manifestations after high-risk surgery (Table S1).

DIAGNOSTIC TESTS

In this era of heavy diagnostic reliance on investigation, decompression sickness and arterial gas embolism remain largely clinical diagnoses. There are no specific biomarkers, and even magnetic resonance imaging is not sensitive for the detection of acute spinal cord decompression sickness, despite clinically significant functional impairment.⁵⁵ Similarly, computed tomography is not sensitive enough to rule out arterial gas embolism.^{56,57} Diagnostic investigations often do not contribute to decisions about treatment (especially in divers) and should not delay definitive treatment. However, investigations to rule out strongly suspected alternative diagnoses may sometimes be appropriate.^{56,58} Since pulmonary injury is possible in patients with arterial gas embolism, plain chest radiography, with the patient in the supine position, or chest ultrasonography is advisable (if either technique can be performed in a timely manner) to rule out pneumothorax before recompression. Venous gas emboli, which can be detected with the use of ultrasonography, may be present in some cases of decompression sickness, but this finding is neither sensitive nor specific for the diagnosis of decompression sickness, in part because many manifestations are triggered by in situ tissue bubbles, which are not detectable with current technology.

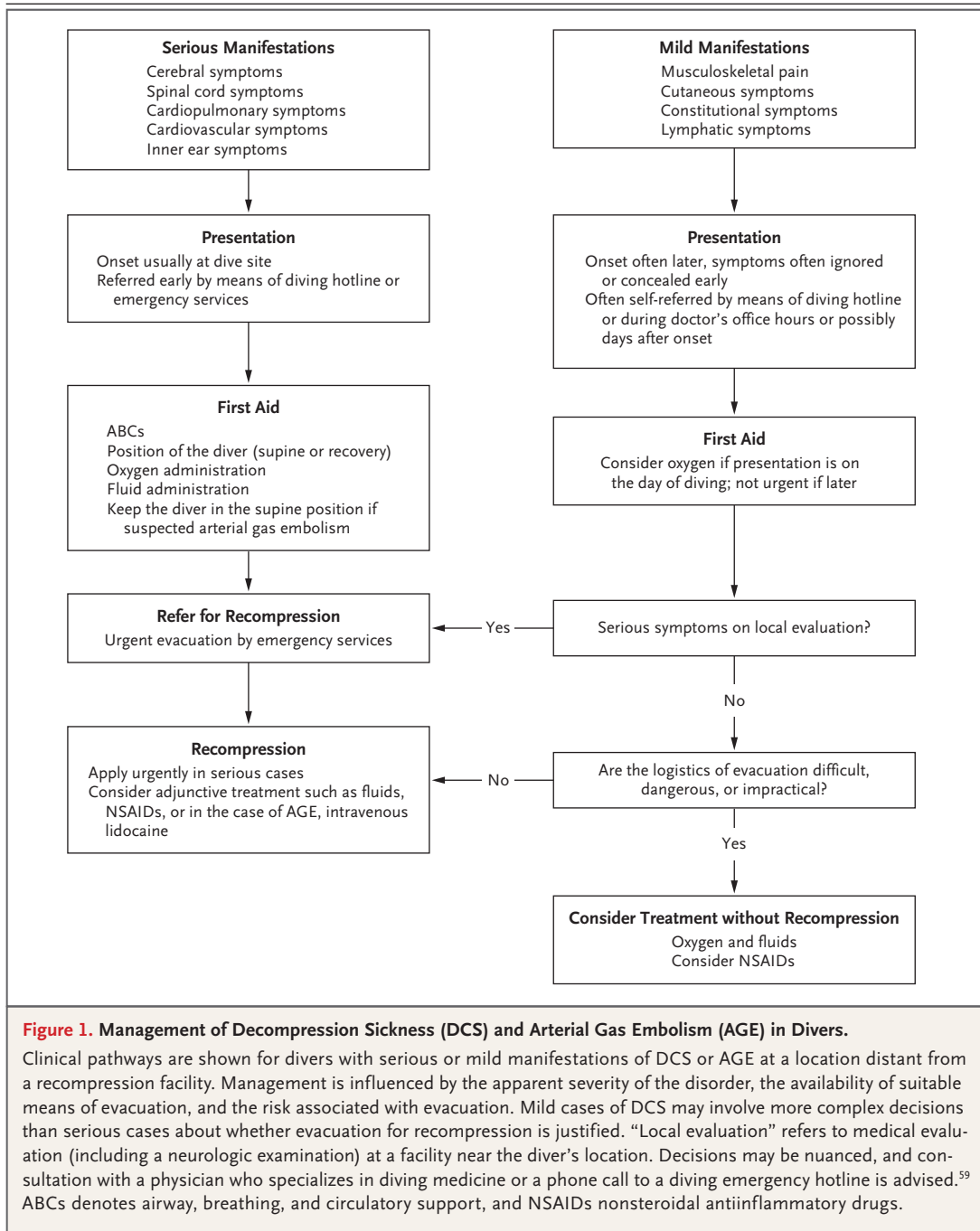
TREATMENT

Appropriate treatment choices are influenced by the severity of the clinical findings on presentation and the circumstances. Two broad scenarios

Table 2. Differential Diagnosis of DCS and AGE in Divers.*

Diving Condition and Key Features	Differential Diagnosis	Distinguishing Features of the Differential Diagnosis
Inner ear DCS: cochlear symptoms are less common (33%) than vestibular symptoms (92%) ⁴⁷ ; symptoms begin during ascent or early after surfacing (within 60 min in 85% of cases); vertigo is typically sustained	Inner ear barotrauma	Often associated with ear pain during descent; symptoms begin before surfacing in >50% of cases; cochlear symptoms are more common in barotrauma (94%) ⁴⁷
	Vestibular migraine	Previous episodes unrelated to diving; often followed by typical headache
	Alternobaric vertigo	Caused by differing pressures in the middle ear during ascent or descent; always transient (lasting <1 min)
	Benign paroxysmal positional vertigo	Typically recurrent (previous episodes unrelated to diving) and transient (duration of <1 min)
	Seasickness	Common self-misdiagnosis; does not cause true vertigo or hearing loss
Spinal DCS: symptoms usually evolve relatively rapidly (within 1–2 hr after surfacing)	Epidural hematoma or abscess	Anticoagulant therapy associated with risk of hematoma; abscess usually causes systemic symptoms of infection, probably present before diving
	Transverse myelitis, Guillain-Barré syndrome, MS	Typically slow evolution (potentially over a period of days); with MS, there is often a history of previous events unrelated to diving
Cardiopulmonary DCS: onset within 30 min after surfacing; provocative dives (e.g., >25 m, rapid ascent, omitted decompression)	Immersion pulmonary edema	Symptom onset before ascent in many cases and may occur on dives that would not cause DCS
	Near drowning	History of panic or water aspiration during dive or at surface after dive
	Myocardial infarction	History of angina or risk factors; symptoms may occur before ascent
Musculoskeletal DCS: may be multifocal	Musculoskeletal injury	Usually unifocal and associated with a history of trauma or an activity (e.g., lifting or straining) likely to cause injury; may be stereotypic in the case of a recurrent injury
Constitutional DCS (fatigue, malaise, headache)	Viral or bacterial infection	Often associated with other symptoms such as coryza and fever
	Carbon dioxide retention	Common cause of headache after diving, particularly dives involving hard work
Cerebral DCS	Carbon monoxide toxicity	May cause confusion and unconsciousness, but often with onset before ascent
Mixed neurologic and constitutional DCS	Toxic seafood ingestion	Ciguatera, paralytic shellfish poisoning, puffer fish poisoning; may cause nausea and vomiting, perioral paresthesia, and progressive, relatively slow onset of weakness
AGE: onset within seconds to minutes after surfacing; often follows a rapid or panicked ascent	Stroke	Occurrence within minutes after surfacing from a dive is a possible but unlikely coincidence
	Seizure	A history of seizures (epilepsy) may be present
	Aura before migraine	Previous events unrelated to diving; often followed by the typical headache
	Facial baroparesis	Caused by barotrauma to facial nerve in middle ear; history of middle ear pain during dive; upper and lower face involved, whereas AGE spares upper face
	Carotid or vertebral dissection	May be preceded by some form of neck trauma or strain; there may be anterior or posterior neck pain

* MS denotes multiple sclerosis.



with management pathways are shown in Figure 1. These scenarios are generalized, and each case should be considered on the basis of its individual characteristics.

FIRST AID

Standard resuscitation interventions should be performed, if required. Particular first-aid measures for suspected decompression sickness or

arterial gas embolism include the positioning of the diver, oxygen administration, and fluid administration.

The diver should be placed in the supine or recovery position to maintain and protect the airway, if required. Horizontal positioning also helps maintain arterial blood pressure in the presence of hypovolemia, albeit with a somewhat higher intracranial pressure than with the head

up. Neurologic deterioration on standing has been observed.²⁵

The highest possible fraction of inspired oxygen should be administered promptly after the onset of symptoms. This intervention can be optimized in a conscious, breathing diver by using several systems, such as a demand valve or nonrebreather mask.⁶⁰ Of 1045 consecutive divers who received oxygen as first aid, 14% had complete relief of symptoms and 51% had reduced symptoms; the cohort also had significantly lower odds of requiring multiple recompression treatments than 1186 divers who did not receive oxygen.⁶¹

Divers are often relatively dehydrated as a result of multiple factors, including immersion diuresis.⁶² An active pre-dive hydration strategy has been shown to reduce post-dive venous gas emboli counts.⁶³ If fully conscious, injured divers should drink noncarbonated, noncaffeinated, nonalcoholic fluid, ideally containing some sodium and glucose. Drinking water is acceptable if there is no better alternative.⁶⁴ In severe cases involving hemoconcentration and shock, intravenous infusion of non-glucose-containing, isotonic crystalloids is preferred and may be lifesaving.⁶⁴ In less severe cases, prompt infusion of a liter of fluid, followed by maintenance hydration that is sufficient to result in normotension and a urine output exceeding 0.5 to 1 ml per kilogram of body weight per hour is considered appropriate.

Early consultation with a diving medicine facility where recompression can be undertaken is recommended. If no such facility is available locally, advice should be sought from 24-hour specialist advisory services, which are available worldwide.⁵⁹ Divers with serious symptoms should be transferred as soon as practicable for recompression. The choice of retrieval platform is complex and depends on local resources, weather, and the clinical status of the patient. Oxygen administration should be continued, and the altitude in unpressurized, aeromedical evacuations should be minimized (ideally, <300 m).

DEFINITIVE TREATMENT

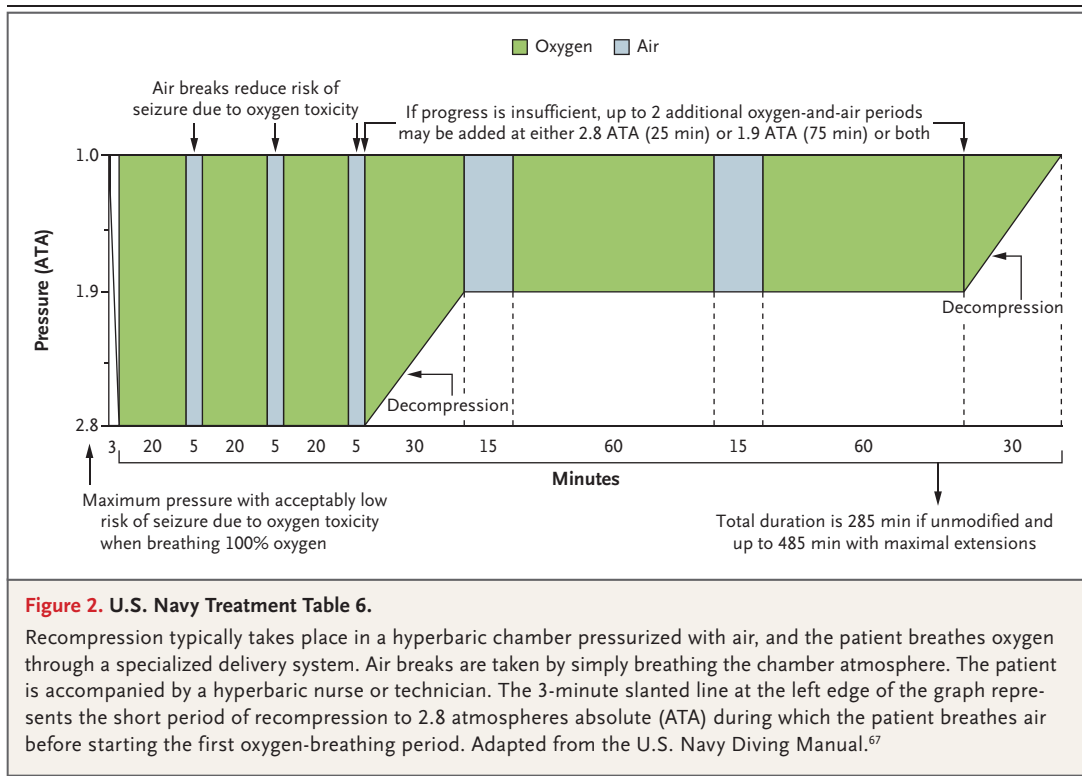
Recompression in a hyperbaric chamber is the definitive treatment for decompression sickness and arterial gas embolism. One aim of recompression is to reduce bubble volume, thus reducing symptoms caused by mechanical disruption of tissue and relieving ischemia by promoting

the redistribution of intravascular bubbles. Use of recompression during air breathing has been known to be effective, as compared with no recompression, since the late 1800s, particularly when applied early after injury.⁴ However, the therapeutic benefit of air recompression is largely complete once the treatment pressure is reached, and the inevitable absorption of more nitrogen requires a long, gradual decompression.

Oxygen recompression markedly enhances the diffusion gradient for inert gas from bubbles to blood, and hyperbaric oxygen has potentially relevant antiinflammatory effects such as attenuating leukocyte adherence⁶⁵ and reducing micro-particles.⁶⁶ The U.S. Navy Treatment Table 6 (Fig. 2) recommends treatment for decompression sickness with an initial 2.8-ATA oxygen recompression⁶⁷ and has been the most commonly used initial recompression protocol since the 1970s. It can be prolonged or repeated if the initial response is poor in serious cases. Alternative treatment tables that use a higher maximum pressure and oxygen-helium mixes (to avoid oxygen toxicity) have been used, primarily for the treatment of severe neurologic symptoms, but there is insufficient evidence to establish them as a standard of care.⁶⁸ In divers with residual symptoms after completion of the first recompression treatment, it is usual to continue treatment with shorter, once-daily oxygen recompressions between 2.0 ATA and 2.8 ATA until symptoms have resolved or no further improvement is evident.

Recompression became a standard of care for treating decompression sickness and arterial gas embolism despite the lack of high-quality clinical evidence.⁶⁹ Oxygen tables were introduced before the common use of randomized, controlled trials in establishing best practices, and the therapeutic benefit was immediate, with a very high success rate when oxygen tables were used quickly after symptom onset.⁷⁰ Subsequent experience with recreational diving, in which immediate recompression is rarely possible, suggests that the response deteriorates with increasing time from injury to compression, especially in serious cases of neurologic decompression sickness^{71,72} and arterial gas embolism.⁵⁷

Mild symptoms of altitude-induced decompression sickness that resolve after descent, with a normal neurologic examination, can be treated with hydration and 100% oxygen for at least 2 hours, followed by 24 hours of observa-



tion. Symptoms that persist after the return to ground level or develop at ground level and neurologic signs or symptoms should be treated with hyperbaric oxygen as described above.

A potential solution to the problem of delayed recompression at sites with difficult access to a chamber is in-water recompression. This approach remains controversial because of potential hazards such as hypothermia and an underwater seizure due to oxygen toxicity. However, published evidence of the efficacy of short, shallow recompression (at approximately 10 m), administered very early,⁷³ and experience from the 2018 Thailand cave rescue, showing that careful management and use of a full-face mask can protect the airway if a diver becomes unconscious,⁷⁴ have provided the basis for qualified endorsement of in-water recompression with the use of oxygen by divers with appropriate equipment and training.⁶⁴

In consideration of the natural history of mild decompression sickness,⁷⁵ a consensus has developed that some mild cases can be adequately treated with the use of surface oxygen and fluids, without recompression, particularly if evacuation for recompression is impractical or dangerous (Fig. 1).^{64,75} The definition of mild decom-

pression sickness includes musculoskeletal pain and cutaneous and constitutional symptoms. However, since divers may underreport or attempt to ignore more serious symptoms, a neurologic examination is strongly recommended before designating a case as mild and as not warranting evacuation for recompression. Such decisions should always involve a physician who specializes in diving medicine.⁶⁴

Many drugs have been considered for first aid or adjuncts to recompression. In a randomized, double-blind, placebo-controlled trial involving divers with mainly mild decompression sickness, adjunctive tenoxicam (a nonsteroidal antiinflammatory drug [NSAID]) reduced the number of recompressions required to reach full recovery or a plateau. These findings suggest that NSAIDs may be useful as adjunctive treatment for mild decompression sickness.⁷⁶ Intravenous lidocaine is neuroprotective in animal models of brain injury, including arterial gas embolism,⁷⁷ and has been investigated in patients undergoing cardiac surgery, who may be harmed by arterial bubbles.⁷⁸ A meta-analysis suggests that this intervention may have a neuroprotective effect in humans.⁷⁹ Lidocaine may be considered in patients with arterial gas embolism⁸⁰ but is not a

standard of care. Fractionated heparin is indicated for thromboprophylaxis in immobile patients with spinal cord decompression sickness.⁸⁰ More detailed information about these drugs and experimental adjuvants is provided in Table S2.

SUMMARY

Decompression sickness and arterial gas embolism are characterized by nonspecific symptoms

and are easily misdiagnosed if a recent patient history of diving and potential iatrogenic causes for arterial gas embolism are not kept in mind. Recompression and hyperbaric oxygen are the definitive treatments for each condition. Diving hotlines that provide 24-hour expert advice are available.⁵⁹

Disclosure forms provided by the authors are available with the full text of this article at NEJM.org.

We thank Drs. Isabelle Vallée and Lars Mielke for help in translating French and German articles.

REFERENCES

- Pol B, Watelle TJJ. Mémoire sur les effets de la compression de l'air appliquée au creusement des puits à houille. Ann Hyg Pub Med Leg 1854;2:241-79.
- Jaminet A. Physical effects of compressed air, and of the causes of pathological symptoms produced on man, by increased atmospheric pressure employed for the sinking of piers, in the construction of the Illinois and St. Louis Bridge over the Mississippi River at St. Louis, Missouri. St. Louis, MO: Ennis, 1871.
- Smith AH. Effects of high atmospheric pressure, including the caisson disease. Brooklyn: Eagle Print, 1873.
- Moir EW. Tunnelling by compressed air. J Soc Arts 1896;44:567-86.
- Snell EH. Compressed air illness: or, so-called caisson disease. London: HK Lewis, 1896.
- Keays FL. Compressed-air illness, with a report of 3692 cases. Publications of Cornell University Medical College 1909; 2:1-55.
- Blick G. Notes on diver's paralysis. Br Med J 1909;2:1796-8.
- Boycott AE, Damant GC, Haldane JS. The prevention of compressed-air illness. J Hyg (Lond) 1908;8:342-443.
- Imbert JP, Balestra C, Kiboub FZ, Loennechen Ø, Eftedal I. Commercial divers' subjective evaluation of saturation. Front Psychol 2019;9:2774.
- Bachrach WH. Information obtained from high altitude combat veterans. Aviation Physiologists Bulletin 1944;7:2-12.
- Ferris EB, Engel GL, Romano J. The clinical nature of high-altitude decompression sickness. In: Fulton JF, ed. Decompression sickness: caisson sickness, diver's and flier's bends and related symptoms. Philadelphia: WB Saunders, 1951:4-52.
- Weien RW, Baumgartner N. Altitude decompression sickness: hyperbaric therapy results in 528 cases. Aviat Space Environ Med 1990;61:833-6.
- Collins M. The hairy ride aboard Gemini 10, a 'bridge' on our way to the moon. Smithsonian 1988;19:42-57.
- Bert P. Barometric pressure: researches in experimental pressure. Hitchcock MA, trans. Bethesda, MD: Undersea Medical Society, 1978.
- von Schrötter H. Der Sauerstoff in der Prophylaxe und Therapie der Luftdruckerkrankungen. Berlin: August Hirschwald, 1906.
- Behnke AR, Shaw LA. The use of oxygen in the treatment of compressed air illness. Naval Medical Bulletin 1937;35:61-72.
- Workman RD. Treatment of bends with oxygen at high pressure. Aerosp Med 1968;39:1076-83.
- Hills BA, Butler BD. Size distribution of intravascular air emboli produced by decompression. Undersea Biomed Res 1981;8:163-70.
- Dunford RG, Vann RD, Gerth WA, et al. The incidence of venous gas emboli in recreational diving. Undersea Hyperb Med 2002;29:247-59.
- Ballidin UI, Pilmanis AA, Webb JT. Central nervous system decompression sickness and venous gas emboli in hypobaric conditions. Aviat Space Environ Med 2004;75:969-72.
- Cantais E, Louge P, Suppini A, Foster PP, Palmier B. Right-to-left shunt and risk of decompression illness with cochleovestibular and cerebral symptoms in divers: case control study in 101 consecutive dive accidents. Crit Care Med 2003;31:84-8.
- Hartig F, Reider N, Sojer M, et al. Livedo racemosa — the pathophysiology of decompression-associated cutis marmorata and right/left shunt. Front Physiol 2020;11:994.
- Germonpré P, Lafère P, Portier W, Germonpré F-L, Marroni A, Balestra C. Increased risk of decompression sickness when diving with a right-to-left shunt: results of a prospective single-blinded observational study (the "Carotid Doppler" study). Front Physiol 2021;12:763408.
- Wilmshurst PT, Byrne JC, Webb-Peploe MM. Neurological decompression sickness. Lancet 1989;1:731.
- Banham ND, Saw J, Hankey GJ, Ghia D. Cerebral arterial gas embolism proven by computed tomography following trans-thoracic echocardiography using bubble contrast. Diving Hyperb Med 2020;50:300-2.
- Dick EJ Jr, Broome JR, Hayward IJ. Acute neurologic decompression illness in pigs: lesions of the spinal cord and brain. Lab Anim Sci 1997;47:50-7.
- Helps SC, Gorman DF. Air embolism of the brain in rabbits pretreated with mechlorothamine. Stroke 1991;22:351-4.
- Nossum V, Koteng S, Brubakk AO. Endothelial damage by bubbles in the pulmonary artery of the pig. Undersea Hyperb Med 1999;26:1-8.
- Brunner FP, Frick PG, Buehlmann AA. Post-decompression shock due to extravasation of plasma. Lancet 1964;1:1071-3.
- Zwirewich CV, Müller NL, Abboud RT, Lepawsky M. Noncardiogenic pulmonary edema caused by decompression sickness: rapid resolution following hyperbaric therapy. Radiology 1987;163:81-2.
- Sobolewski P, Kandel J, Klinger AL, Eckmann DM. Air bubble contact with endothelial cells in vitro induces calcium influx and IP3-dependent release of calcium stores. Am J Physiol Cell Physiol 2011;301(3):C679-C686.
- Philp RB. A review of blood changes associated with compression-decompression: relationship to decompression sickness. Undersea Biomed Res 1974;1:117-50.
- Pontier J-M, Vallée N, Bourdon L. Bubble-induced platelet aggregation in a rat model of decompression sickness. J Appl Physiol (1985) 2009;107:1825-9.
- Levin LL, Stewart GJ, Lynch PR, Bove AA. Blood and blood vessel wall changes induced by decompression sickness in dogs. J Appl Physiol Respir Environ Exerc Physiol 1981;50:944-9.
- Lambrechts K, Pontier J-M, Mazur A, et al. Mechanism of action of antiplatelet drugs on decompression sickness in rats: a protective effect of anti-GPIIb/IIIa therapy. J Appl Physiol (1985) 2015;118:1234-9.
- Lautridou J, Dugrenot E, Amérand A, et al. Physiological characteristics associated with increased resistance to decompression sickness in male and female rats. J Appl Physiol (1985) 2020;129:612-25.
- Ward CA, McCullough D, Fraser WD. Relation between complement activation and susceptibility to decompression sickness. J Appl Physiol (1985) 1987;62:1160-6.
- Thom SR, Bennett M, Banham ND, et al. Association of microparticles and neutrophil activation with decompression sickness. J Appl Physiol (1985) 2015;119:427-34.
- Goffinet CM, Simpson G. Cerebral arterial gas embolism in a scuba diver with a primary lung bulla. Diving Hyperb Med 2019;49:141-4.
- Hampson NB, Moon RE. Arterial gas

- embolism breathing compressed air in 1.2 metres of water. *Diving Hyperb Med* 2020;50:292-4.
41. Moon RE. Hyperbaric treatment of air or gas embolism: current recommendations. *Undersea Hyperb Med* 2019;46:673-83.
 42. Iadecola C, Buckwalter MS, Anrather J. Immune responses to stroke: mechanisms, modulation, and therapeutic potential. *J Clin Invest* 2020;130:2777-88.
 43. Denoble PJ, ed. DAN annual diving report 2019 edition: a report on 2017 diving fatalities, injuries, and incidents. Durham, NC: Divers Alert Network, 2019:113. (<https://www.ncbi.nlm.nih.gov/books/NBK562527/>).
 44. Azzopardi CP, Caruana J, Matity L, Muscat S, Meintjes WJ. Increasing prevalence of vestibulo-cochlear decompression illness in Malta — an analysis of hyperbaric treatment data from 1987–2017. *Diving Hyperb Med* 2019;49:161-6.
 45. Hubbard M, Davis FM, Malcolm K, Mitchell SJ. Decompression illness and other injuries in a recreational dive charter operation. *Diving Hyperb Med* 2018;48:218-23.
 46. Vann RD, Freiburger JJ, Caruso JL, et al. Report on decompression illness, diving fatalities, and project dive exploration. Durham, NC: Divers Alert Network, 2003:42.
 47. Haas RM, Hannam JA, Sames C, et al. Decompression illness in divers treated in Auckland, New Zealand, 1996–2012. *Diving Hyperb Med* 2014;44:20-5.
 48. Lindfors OH, Räisänen-Sokolowski AK, Hirvonen TP, Sinkkonen ST. Inner ear barotrauma and inner ear decompression sickness: a systematic review on differential diagnostics. *Diving Hyperb Med* 2021;51:328-37.
 49. Berghage TE. Decompression sickness during saturation dives. *Undersea Biomed Res* 1976;3:387-98.
 50. Xu W, Liu W, Huang G, Zou Z, Cai Z, Xu W. Decompression illness: clinical aspects of 5278 consecutive cases treated in a single hyperbaric unit. *PLoS One* 2012;7(11):e50079.
 51. St Leger Dowse M, Howell S, Smerdon GR. Flying after diving: a questionnaire-based evaluation of pre-flight diving behaviour in a recreational diving cohort. *Diving Hyperb Med* 2021;51:361-7.
 52. Van Liew HD, Flynn ET. Direct ascent from air and N₂-O₂ saturation dives in humans: DCS risk and evidence of a threshold. *Undersea Hyperb Med* 2005;32:409-19.
 53. Fitzgerald B. A review of the sharpened Romberg test in diving medicine. *SPUMS J* 1996;26:142-6.
 54. Leitch DR, Green RD. Pulmonary barotrauma in divers and the treatment of cerebral arterial gas embolism. *Aviat Space Environ Med* 1986;57:931-8.
 55. Saadi A, Ferenczi EA, Reda H. Spinal decompression sickness in an experienced scuba diver: a case report and review of literature. *Neurohospitalist* 2019;9:235-8.
 56. Hatling D, Høgetset A, Guttormsen AB, Müller B. Iatrogenic cerebral gas embolism — a systematic review of case reports. *Acta Anaesthesiol Scand* 2019;63:154-60.
 57. Beevor H, Frawley G. Iatrogenic cerebral gas embolism: analysis of the presentation, management and outcomes of patients referred to the Alfred Hospital hyperbaric unit. *Diving Hyperb Med* 2016;46:15-21.
 58. Blatteau J-E, Morin J, Roffi R, Druelle A, Sbardella F, Castagna O. Clinical problem solving: mental confusion and hypoxaemia after scuba diving. *Diving Hyperb Med* 2020;50:181-4.
 59. DAN World. DAN 24-hour hotline numbers (http://www.danap.org/emergency/hotline_numbers.php).
 60. Blake DF, Crowe M, Lindsay D, et al. Comparison of tissue oxygenation achieved breathing oxygen using different delivery devices and flow rates. *Diving Hyperb Med* 2020;50:34-42.
 61. Longphre JM, Denoble PJ, Moon RE, Vann RD, Freiburger JJ. First aid normobaric oxygen for the treatment of recreational diving injuries. *Undersea Hyperb Med* 2007;34:43-9.
 62. Williams STB, Prior FGR, Bryson P. Hematocrit change in tropical scuba divers. *Wilderness Environ Med* 2007;18:48-53.
 63. Gempp E, Blatteau JE, Pontier J-M, Balestra C, Louge P. Preventive effect of pre-dive hydration on bubble formation in divers. *Br J Sports Med* 2009;43:224-8.
 64. Mitchell SJ, Bennett MH, Bryson P, et al. Pre-hospital management of decompression illness: expert review of key principles and controversies. *Diving Hyperb Med* 2018;48:45-55.
 65. Buras JA, Stahl GL, Svoboda KK, Reenstra WR. Hyperbaric oxygen downregulates ICAM-1 expression induced by hypoxia and hypoglycemia: the role of NOS. *Am J Physiol Cell Physiol* 2000;278(2):C292-C302.
 66. Thom SR, Bhopale VM, Yang M. Micro-particle-induced vascular injury in mice following decompression is inhibited by hyperbaric oxygen: effects on microparticles and interleukin-1 β . *J Appl Physiol* (1985) 2019;126:1006-14.
 67. Department of the Navy. Volume 5: Diving medicine and recompression chamber operations. In: U.S. Navy diving manual, revision 7. Washington, D.C.: Naval Sea Systems Command, 2016:17-44 (https://www.navsea.navy.mil/Portals/103/Documents/SUPSALV/Diving/US%20DIVING%20MANUAL_REV7.pdf?ver=2017-01-11-102354-393).
 68. Bennett MH, Mitchell SJ, Young D, King D. The use of deep tables in the treatment of decompression illness: the Hyperbaric Technicians and Nurses Association 2011 workshop. *Diving Hyperb Med* 2012;42:171-80.
 69. Bennett MH, Lehm JP, Mitchell SJ, Wasiak J. Recompression and adjunctive therapy for decompression illness. *Cochrane Database Syst Rev* 2012;5:CD005277.
 70. Thalmann ED. Principles of US Navy recompression treatments for decompression sickness. In: Bennett PB, Moon RE, eds. *Diving accident management*. Kensington, MD: Undersea and Hyperbaric Medical Society, 1996:75-95.
 71. Andre S, Lehot H, Morin J, et al. Influence of prehospital management on the outcome of spinal cord decompression sickness in scuba divers. *Emerg Med J* 2022 February 07 (Epub ahead of print).
 72. Moon RE, Mitchell SJ. Hyperbaric oxygen for decompression sickness. *Undersea Hyperb Med* 2021;48:195-203.
 73. Doolette DJ, Mitchell SJ. In-water recompression. *Diving Hyperb Med* 2018;48:84-95.
 74. van Waart H, Harris RJ, Gant N, et al. Deep anaesthesia: the Thailand cave rescue and its implications for management of the unconscious diver underwater. *Diving Hyperb Med* 2020;50:121-9.
 75. Mitchell SJ, Doolette DJ, Wacholz CJ, Vann RD, eds. Management of mild or marginal decompression illness in remote locations: workshop proceedings. Durham, NC: Divers Alert Network, 2005 (<https://www.uhms.org/uhm-search/management-of-mild-or-marginal-decompression-illness-in-remote-locations-workshop-proceedings.html>).
 76. Bennett M, Mitchell S, Dominguez A. Adjunctive treatment of decompression illness with a non-steroidal anti-inflammatory drug (tenoxicam) reduces compression requirement. *Undersea Hyperb Med* 2003;30:195-205.
 77. Mitchell SJ. Lidocaine in the treatment of decompression illness: a review of the literature. *Undersea Hyperb Med* 2001;28:165-74.
 78. Mitchell SJ, Merry AF. Perspective on cerebral microemboli in cardiac surgery: significant problem or much ado about nothing? *J Extra Corpor Technol* 2015;47:10-5.
 79. Habibi MR, Habibi V, Habibi A, Soleimani A. Lidocaine dose-response effect on postoperative cognitive deficit: meta-analysis and meta-regression. *Expert Rev Clin Pharmacol* 2018;11:361-71.
 80. Moon RE, ed. *Adjunctive therapy for decompression illness*. Kensington, MD: Undersea and Hyperbaric Medical Society, 2003.