



[Indian J Dermatol](#). 2017 Jan-Feb; 62(1): 66–78.

PMCID: PMC5286756

doi: [10.4103/0019-5154.198052](https://doi.org/10.4103/0019-5154.198052)

PMID: [28216728](https://pubmed.ncbi.nlm.nih.gov/28216728/)

## Marine and Other Aquatic Dermatoses

[Surg Capt. Jandhyala Sridhar](#) and [Surg Cdr. Rajeev Deo](#)<sup>1</sup>

*From the Department of Dermatology, INHS Asvini, Mumbai, Maharashtra, India*

<sup>1</sup>*Diving School, Naval Base, Kochi, Kerala, India*

**Address for correspondence:** *Surg Capt. Jandhyala Sridhar, Department of Dermatology, INHS Asvini, Colaba, Mumbai - 400 005, Maharashtra, India. E-mail: [sridharjandhya@yahoo.com](mailto:sridharjandhya@yahoo.com)*

Received 2016 Aug; Accepted 2016 Dec.

[Copyright](#) : © 2017 Indian Journal of Dermatology

This is an open access article distributed under the terms of the Creative Commons Attribution-NonCommercial-ShareAlike 3.0 License, which allows others to remix, tweak, and build upon the work non-commercially, as long as the author is credited and the new creations are licensed under the identical terms.

### Abstract

Occupational and recreational aquatic activity predisposes our population to a wide variety of dermatoses. Sunburn, urticaria, jellyfish stings, and contact dermatitis to rubber equipment are common allergies that are encountered in the aquatic environment. Among the infections, tinea versicolor, intertrigo, and verruca vulgaris are widespread. Swimmer's itch may occur due to skin penetration by schistosome cercariae, while free-floating nematocysts of marine coelenterates may precipitate seabather's eruption. "Suit squeeze" due to cutaneous barotrauma and lymphoedematous peau d'orange due to decompression are rare, described entities. This review serves as a ready reckoner for Indian dermatologists and medical practitioners to identify and manage these conditions.

**Keywords:** *Aquatic dermatoses, diving, marine, swimming*

#### What was known?

- Sizeable sections of the Indian population are exposed to the aquatic environment
- Potential skin effects include bites, stings, infections, and allergies.

### Introduction

"All is born of water, all is sustained by water" Goethe

The Aquatic World: Water constitutes two-thirds of the surface area of our planet. Since the beginning of time, the aquatic environment has shaped the very character of our planet and has profoundly influenced human civilization. India has a long coastline measuring 7516.6 km bordering nine states and four union territories; its 73 coastal districts are home to 14.2% of her total population.<sup>[1]</sup> Its

coastal biodiversity encompasses marine algae, seagrasses, mangroves, and aquatic animals including crustaceans, echinoderms, reptiles, pisces, and mammals [Table 1].[2] An estimated 4 million fishermen depend on the seas for their livelihood. Eight major rivers and numerous tributaries crisscross about 15,000 km of the Indian landmass. Most major cities of India are located on the banks of rivers that provide livelihood to a large number of people. A sizeable section of the population is thus exposed to the aquatic environment and its potential effects.

Table 1

Coastal biodiversity of India

<b>Aquatic lifeform</b>	<b>Genera and species</b>
Marine algae	217 genera 844 species
Seagrasses	6 genera 14 species
Mangroves	25 families, 43 genera, 39 species
	Associated flora: 420
	Associated fauna: 1862
Crustaceans	2934 species
Molluscs	3370 species
Echinoderms	765 species
Hard corals	218 species
Fishes	2546 species
Reptiles	5 sea turtle species
	26 sea snake species
Marine mammals	25 reported from Indian waters
	3 species of cetaceans: Irrawaddy dolphin, Ganges River dolphin, and Sperm whale

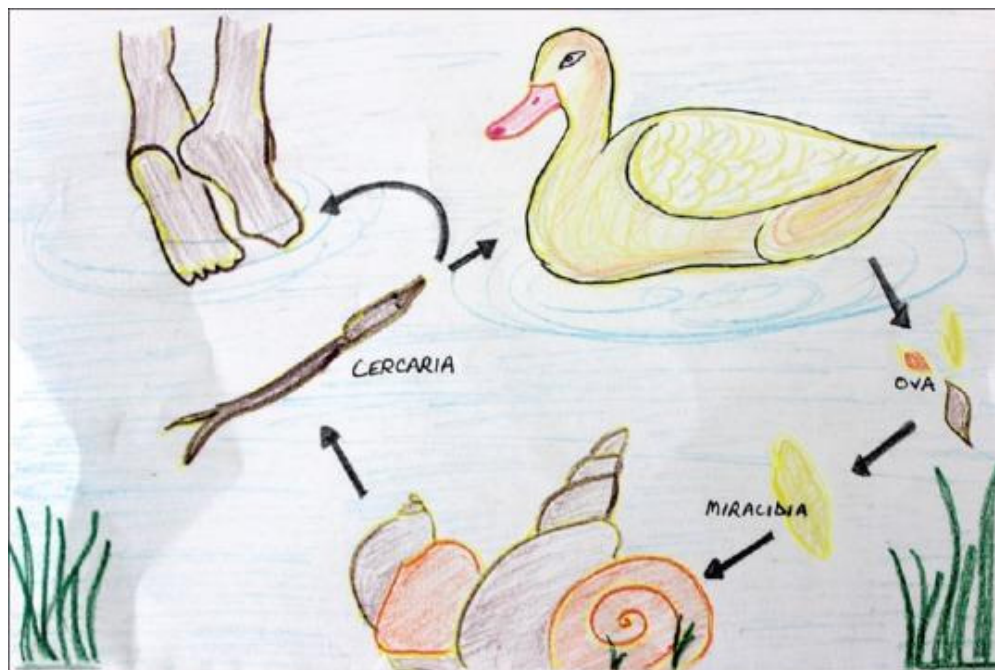
The human skin has lipids which differ from those of aquatic animals. As a result, it is susceptible to the deleterious effects of maceration, infection, allergy, venomous bites and stings of aquatic animals, and extremes of temperature. Aquatic dermatoses constitute the assortment of cutaneous conditions that are encountered in swimmers, divers, fishers, and tourists who participate in activities on or in the water. Certain conditions are specifically associated with freshwater or saltwater while others may occur in both settings. This article addresses the physical findings, treatment recommendations, and preventive measures for dermatoses encountered in marine and freshwater settings.

### Dermatoses Common to Both Marine and Freshwater Environments

Infections, infestations, and bites

Swimmer's itch (Syn: Schistosome dermatitis, cercarial dermatitis, and clam-digger's itch)

Cause: Cercarial dermatitis is a condition that occurs in both marine and freshwater habitats caused by mammalian and avian schistosomes of family *Schistosomatidae*. Freshwater species of *Schistosoma*, marine species of *Austrobilharzia* and *Ornithobilharzia*, and freshwater/marine species of *Trichobilharzia*, *Gigantobilharzia*, *Anserobilharzia*, *Allobilharzia*, and *Dendrotilharzia* have been implicated.[3] Although the first report of cercarial dermatitis was from Mysore, Karnataka, in 1948, the condition has been subsequently reported in hitherto unknown regions such as the Doon Valley of Uttarakhand,[4] with similar trends reported worldwide. Consequently, cercarial dermatitis is now regarded as an emerging disease.[3] Birds and rodents, the definitive hosts, excrete schistosome ova into the water that mature into free-swimming miracidia. These miracidia infect snails and transform into cercaria larvae that penetrate the human stratum corneum using proteolytic enzymes. Humans represent the final hosts as the larvae eventually die within the skin [Figure 1]. The immunogenic enzymes of the cercariae result in sensitization 2 weeks after the first contact. Subsequent exposure results in lesions within hours.[4]



[Figure 1](#)

Life cycle of schistosomes causing swimmer's itch

Clinical features: This self-limiting eruption occurs most commonly on skin not covered with swimwear and presents with pain, prickling, and pruritus several hours after initial exposure. Erythematous macules, papules, and urticaria can be seen around sites of penetration. Signs and symptoms typically worsen 12–24 h after exposure as vesicles and pustules may develop. Lesions spontaneously resolve within 3–7 days. Systemic symptoms, though rare, include fever, chills, and lymphadenopathy.[5]

Management: Antihistamines and topical corticosteroids are usually sufficient to control the pruritus; systemic steroids are rarely necessary.[5] The use of wetsuits and aggressive towel drying after swimming in potentially infested waters could prevent the symptoms.[6]

Swimming pool granuloma (Syn: Fish tank granuloma, fish fancier's granuloma)

Cause: Swimming pool granuloma is caused by atypical mycobacteria, including *Mycobacterium marinum* and *Mycobacterium scrofulaceum*, residing in both fresh and salt waters – swimming pools, beaches, rivers, lakes, and aquaria. Potential vectors include fish, snails, shellfish, dolphins, and water fleas.[5]

Clinical features: Verrucous plaques or nodules occur over the extremities, especially the fingers and bony prominences about 6 weeks after inoculation. A sporotrichoid pattern may be seen in up to 20% of cases due to lymphatic spread of the infection.[7] Occasionally, lesions may ulcerate.

Histopathological examination and culture are confirmatory. Infections confined to the skin may heal spontaneously over months. *M. marinum* invades deeper tissues, such as tendon sheaths, bursae, bones, and joints in up to 29% of cases,[8] irrespective of the patient's immunological state. Patients usually do not seek medical attention until their symptoms worsen.[9]

Management: *M. marinum* is resistant to the antituberculosis medications isoniazid, pyrazinamide, and para-aminosalicylic acid and shows intermediate sensitivity to streptomycin. Ethambutol, rifampicin, clarithromycin, minocycline/doxycycline, ciprofloxacin, and trimethoprim-sulfamethoxazole have been used.[6] The recommended approach is to use combination of two active agents until 1–2 months after resolution of lesions or for a minimum of 6 months. Clarithromycin and ethambutol combination treatment may be optimally suited in terms of efficacy and tolerability. Rifampicin is to be added when there is osteomyelitis or other deeper-structure involvement. Other combinations that have also been used include ethambutol-rifampicin, clarithromycin-rifampin, minocycline-clarithromycin, minocycline-rifampicin, and rifampicin-streptomycin.[9] Clarithromycin monotherapy has been used with some success.[5] Lenalidomide is a thalidomide derivative used for chronic lymphocytic leukemia rapidly resolved refractory and chronic *M. marinum* skin infection in one patient.[10] Because the organism does not tolerate temperatures above 33.8°C, hot compresses can be used in conjunction with these antibiotics.[5] Surgical excision has also been used in the treatment of this infectious disease.

**Swimmer's ear (Otitis externa)** Cause: Otitis externa in swimmers is usually caused by *Pseudomonas aeruginosa* or *Staphylococcus aureus*.<sup>[11]</sup> *Candida albicans* and *Aspergillus* species are the common fungal pathogens responsible for the condition. The incidence of otitis externa in swimmers exceeds that of nonswimmers by five times.[5] Impairments in the integrity of the skin of the ear canal such as by the use of cotton ear buds to dry the ears, preexisting atopy, or sebopsoriasis that allow the entry of infection may be a trigger. Otitis externa is known to be strongly associated with saturation diving.[12] Local trauma and prolonged exposure to high humidity and temperature are thought to predispose saturation divers to otitis externa.

Clinical features: There is pain and pruritus in the external auditory canal, aggravated upon auricular movement. Otorrhea and hearing loss may occur due to oedema and secretions in the ear canal. Regional lymphadenopathy is noted in severe cases. Elderly swimmers with diabetes are prone to developing malignant otitis externa as the infection invades the underlying temporal bone.[5]

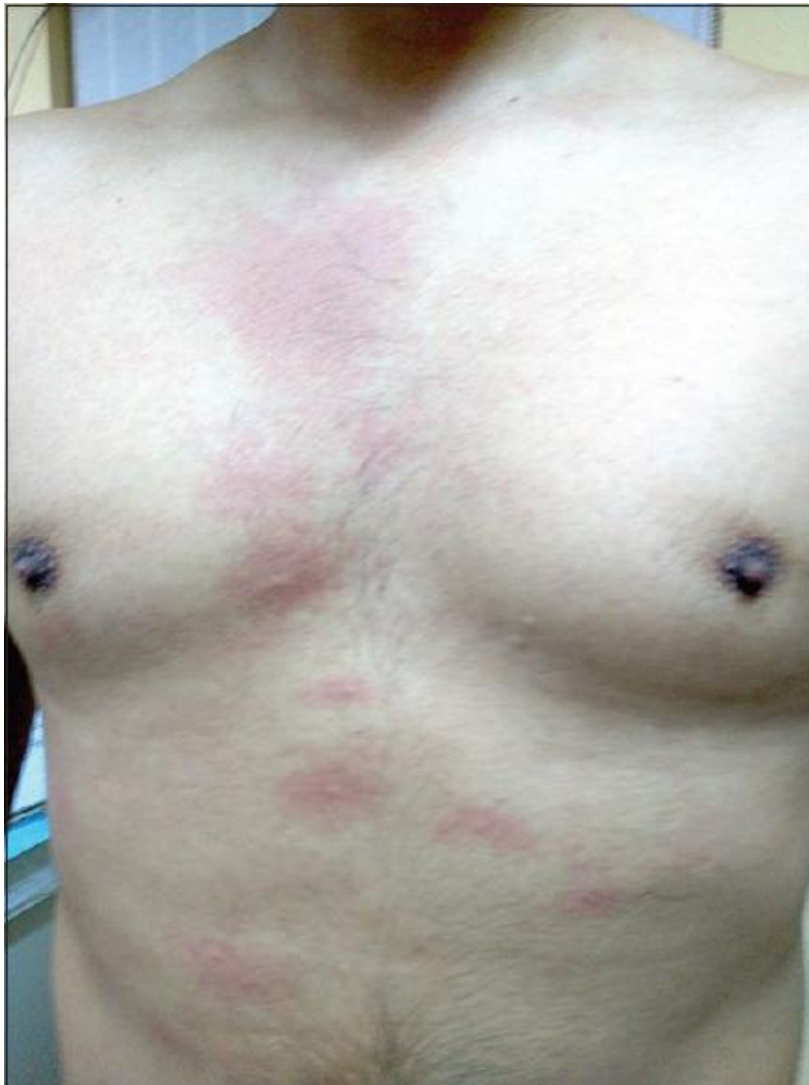Management: Antibiotic and corticosteroid eardrops are to be applied twice daily for a maximum of 1 week. Prolonged use of such drops might promote otomycosis and fungal otitis externa. Patients are advised to halt swimming till symptoms improve. They have to be cautioned against using cotton buds especially after a swim when the skin is saturated with water as it is more susceptible to injury. The self-cleaning and self-drying mechanism of the external ear canal, the latter by simple evaporation, needs emphasis. Hard and poorly fitting earplugs can scratch the ear canal skin and set off an episode. When earplugs are used during an acute episode, either disposable plugs are recommended, or used plugs must be cleaned and dried properly to avoid contaminating the healing ear canal with infected discharge. After prolonged swimming, swimmers prone to external otitis can dry the ears using a small



battery-powered ear dryer, available with many sports and online retailers. Alternatively, drops containing dilute acetic acid (vinegar diluted 3:1) or Burow's solution (a buffered mixture of aluminum sulfate and acetic acid) may be used.[5]

**Diving suit dermatitis** Cause: Wearing a scuba diving suit washed in freshwater contaminated by *P. aeruginosa* serotypes O:10 and O:6 may cause diving suit dermatitis.[13] The humid microclimate that is maintained in the alveoli of the neoprene is favorable to the survival of *P. aeruginosa*. Occlusion and overhydration of the stratum corneum and saline abrasion due to seawater predispose to the infection. With repeated immersion, divers lose the antimicrobial benefits of sebum, acid mantle, and normal flora.

**Clinical features:** The condition usually presents with diffuse, scattered, erythematous papules on the trunk and extremities [Figure 2]. Rarely, divers may exhibit fever, headache, and malaise.



[Figure 2](#)

Diving suit dermatitis

Management: Diving suits should be cleaned with 0.45% lactic acid after each use; furthermore, divers should shower immediately after diving. Oral antibiotics such as ciprofloxacin 500 mg twice daily are used.[5]

**Bikini bottom** Cause: Bikini bottom is a deep bacterial folliculitis caused by *Streptococcus* or *Staphylococcus aureus* that occurs in swimmers who wear wet, occlusive swimwear for long periods. [14]

Clinical features: Firm, deep nodules occur along the inferior gluteal crease.

Management: First-line treatment consists of oral antibiotics such as ciprofloxacin 500 mg twice daily. Preventive methods include cleaning diving suits with 0.45% lactic acid after each use and showering immediately after diving.[14]

**Pitted keratolysis** Cause: Pitted keratolysis (PK) is caused by *Dermatophilus congolensis*, a species of *Corynebacterium* or *Kytococcus sedentarius* (formerly *Micrococcus sedentarius*), a Gram-positive bacterium. These invade the stratum corneum of the soles softened by sweat and moisture. Exposure to water and/or hyperhidrosis always precedes the development of the infection. Patients often complain of “sliminess” of the soles.[15]

Clinical features: The condition presents as small crateriform pits 1–3 mm in diameter, located on the pressure-bearing areas such as balls of toes and heel.[15] The most common sites of onset of PK are the pressure-bearing areas such as the ventral aspect of the toe, ball of the foot, and the heel. The next most common site is a friction area, the interface of the toes. Lesions are rarely seen on the nonpressure-bearing locations. Some of the primary lesions originate as a small defect along the plantar furrow, which gradually grows into the characteristic crateriform pit.

Management: Excess moisture needs to be eliminated. Persistent infection responds to topical or oral erythromycin, topical clindamycin, or topical 5% benzoyl peroxide.[5,15]

**Athlete's foot** (Syn: *Tinea pedis*) Cause: Shed skin on pool decks, shower floors, and changing rooms may carry dermatophyte fungi of the genera *Trichophyton*, *Epidermophyton*, and *Microsporum*. [16] The risk of infection increases in swimmers and divers due to an impaired cutaneous barrier. Wet skin also promotes the spread of fungi normally confined to intertriginous zones. The condition is thus extremely common in the aquatic setting. Adult males with a previous history of athletes' foot have a higher risk of contracting the fungal infection. Hyperhidrosis, diabetes, and immunocompromised states also increase the risk.[16,17]

Clinical features: Athlete's foot presents commonly as macerated, interdigitate lesions but may also manifest in a moccasin and/or inflammatory/bullous pattern. Without secondary prophylaxis, the infection commonly recurs.[5]

Management: Oral antifungal agents such as itraconazole 200 mg daily or terbinafine 250 mg daily for 2–6 weeks are advisable. Wearing sandals while on pool decks or public shower floors may help prevent occlusion. Regular, twice weekly application of topical antifungal agents may prevent tinea pedis infections in athletes.[18]

**Pityriasis versicolor** (Syn: *Tinea versicolor*, *dermatomycosis furfuracea*, *tinea flava*, and *achromia parasitica*)

Cause: Pityriasis versicolor is a superficial fungal infection caused due to *Malassezia* spp. that are saprophytes that normally inhabit the skin. The condition is extremely common in tropical coastal locations, especially during the warm humid summers. The great majority of cases occur in adolescents and youths, which might be attributable to hormonal changes and/or changes in the secretion of sebum. [19] Athletes and swimmers are naturally predisposed to the infection.

Clinical features: As its name suggests, pityriasis versicolor can manifest in multiple different colors, including white, pink, tan, dark brown, and even black. Typically, sebaceous gland-bearing regions, especially the back and chest, are affected.[19] Individual patches typically display a fine scale. Papules, annular or atrophic plaques may occasionally be present.[19,20] Affected individuals often complain of pruritus. Recurrence is common.

Treatment: For mild to moderate disease, topical selenium sulfide 2.5%, sodium thiosulfate 25% with salicylic acid 1%, clotrimazole 1%, and ketoconazole 2% are effective.[21] Patients with severe disease or frequent relapses may require systemic therapy with fluconazole or itraconazole.

**Warts (Syn: Verruca vulgaris) Background:** These are benign epithelial tumors caused by human papilloma virus that occur more commonly among swimmers. A case-control study found that swimmers were 1.81 times more likely to have warts compared to nonswimmers.[22] Another study found that 27% of swimmers who used communal showers developed plantar warts.[23] Shared equipment such as diving suits and fins are responsible for a higher incidence among divers.

Clinical features: Common warts may affect the dorsa of the feet and are flesh-colored, rough, hyperkeratotic papules found singly or in groups. Autoinoculation may lead to warts on adjacent surfaces of fingers and toes. Plantar warts are thick, hyperkeratotic lesions on the soles, especially on the heel, metatarsal head region, and plantar toe, and can be painful. The black dots (thrombosed capillaries) visualized on physical examination are diagnostic of warts, helping the clinician differentiate a wart from a corn or callosity.

Management: Mechanical destruction methods include liquid nitrogen, cautery, and curettage. Chemical destruction methods entail the application of salicylic acid, imiquimod, fluorouracil (5-FU), squaric acid dibutylester, and diphenylcyclopropenone beneath an adhesive bandage. Recalcitrant warts may require injection of *Candida*, mumps antigen, or bleomycin.[24]

**Molluscum contagiosum (Syn: Water warts) Background:** Molluscum contagiosum, caused by a pox virus, has a higher incidence between 2% and 10% among swimmers.[25] A Japanese study noted that molluscum occurred in 7.5% of swimmers and in 3.6% of nonswimmers.[26] Shared mouthpieces and wetsuits among divers can also transmit the infection.

Clinical features: Infected athletes present with pearly-white or skin-colored papules and nodules, with larger lesions having a central dimple or umbilication. Occasionally, host immune response to the viral antigen causes “molluscum dermatitis.” The infection usually resolves spontaneously in healthy individuals without scarring.

Management: Most lesions will resolve spontaneously within 1 year. Destructive therapies include curettage, liquid nitrogen, trichloroacetic acid, and cantharidin. Topical 5-FU or imiquimod also help clear molluscum.[24]

## Contact dermatoses

**Swimwear and dive equipment Background:** Allergic contact reactions to swim goggles, caps, masks, nose clips, ear plugs, and flippers/fins often occur after exposure to rubber accelerators, such as isopropyl paraphenylenediamine, dibutylthiourea, and mercaptobenzothiazole used in the assembly of black neoprene rubber padding [Table 2].[5,27] Other components of swim gear that may elicit a contact allergy include diphenylthiourea, para-tertiary-butylphenol-formaldehyde resin, and ethyl butylthiourea found in swim suits.[28] Contact allergies also occur as a result of exposure to phenol formaldehyde resin and benzoyl peroxide present in swimming goggles.[29] In addition, toxic contact reactions to rubber may provoke contact depigmentation.

Table 2

Freshwater contact dermatoses

Contact dermatosis	Offending agent
Swim goggle dermatitis	Dibutylthiourea (rubber accelerator)
Nose clip and ear plug dermatitis	Rubber accelerator compounds
Diving mask dermatitis	IPPD
Wetsuit dermatitis	Dibutylthiourea, diethylthiourea, diphenylthiourea, para-tertiary-butyl phenol-formaldehyde resin ethyl butylthiourea
Swim fin dermatitis	IPPD, dibutylthiourea, diethylthiourea
Swim cap dermatitis	Mercaptobenzothiazole

IPPD: Isopropylparaphenylenediamine

Clinical features: Individuals with contact dermatitis to swim caps, ear plugs, and nose clips present with well-defined, erythematous, scaling plaques and occasionally vesicles over areas in direct contact with the offending agent. Wetsuit dermatitis manifests as a pruritic, vesicular, or eczematous eruption on the neck, trunk, and extremities.[5] These reactions may subside with postinflammatory hyperpigmentation or depigmentation.

Management: A short course of medium potency (Class III–IV) topical corticosteroids treats the condition effectively. Topical immunomodulators may help for milder and chronic conditions.[5] Severe cases may require a short course of systemic corticosteroids.

### Miscellaneous dermatoses

**Aquagenic pruritus** Cause: Shelley coined the term “aquagenic pruritus” in 1970. In 1985, Steinman brought out the following criteria for the diagnosis of aquagenic pruritus:

- Severe pruritus, prickling, stinging, or burning sensation after contact with water
- Discomfort that develops within minutes of water contact
- No visible skin changes
- No concurrent skin disease, internal disorder, or medication that can explain the discomfort
- Exclusion of aquagenic, cholinergic, cold, heat, and vibratory urticaria and symptomatic dermographism
- Exclusion of polycythemia rubra vera.



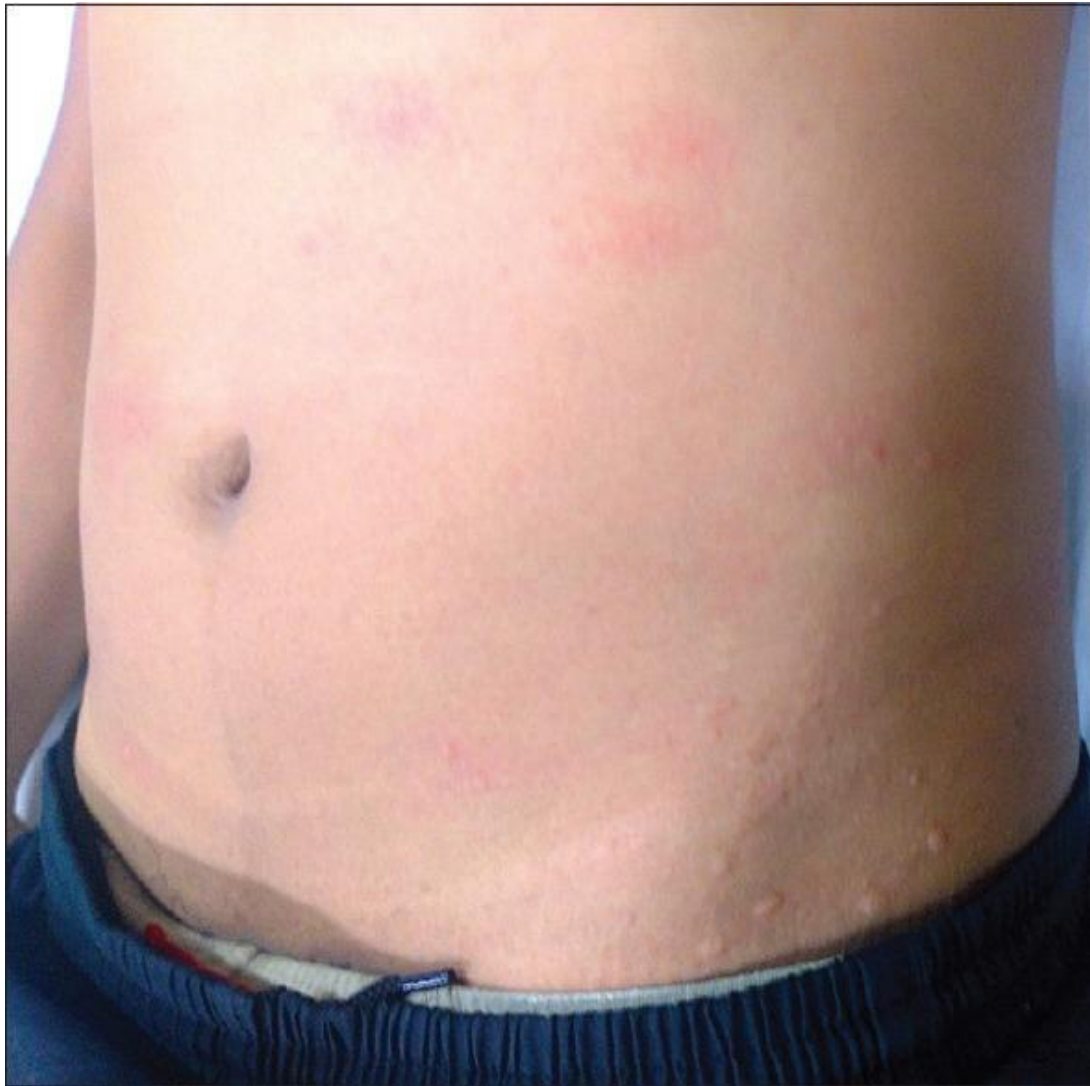Clinical features: Swimmers and divers experience pruritus or a tingling, burning, or stinging sensation that occurs without visible skin changes at sites of contact with water of any temperature. These symptoms last between 10 min and 2 h.[5,30]

Management: Psoralen ultraviolet A (PUVA) and ultraviolet B (UVB) phototherapy may relieve patients' pruritus.[31] Antihistamines are ineffective.

### Aquagenic urticaria

Cause: Aquagenic urticaria is a rare form of physical urticaria that occurs upon contact with water from any source or of any temperature.[32]

Clinical features: The presence of urticarial wheals differentiates the condition from aquagenic pruritus [Figure 3]. The condition may be further differentiated from cold-induced urticaria by placing an ice cube wrapped in a plastic bag over the forearm and looking for a wheal at the site upon rewarming the skin.[5] Rarely, systemic symptoms, including headache and respiratory distress, may occur.[32]



**Figure 3**

Aquagenic urticaria

Management: Patients usually respond to antihistamines and anticholinergics. Alternative treatments include PUVA and UVB.[32]

### Cold urticaria

Cause: Water conducts body heat twenty times better than air. Thus, divers and swimmers, even in the tropics, routinely get exposed to cold stimulus. Essential acquired cold urticaria represents the most common type of cold urticaria, but secondary causes include cryoglobulinemia and connective tissue disorders. One should also rule out familial cold autoinflammatory syndrome, a type of periodic fever characterized by episodes of urticaria, fever, and joint pain, following generalized exposure to cold.[5]

Clinical features: Cold urticaria manifests with well-defined, intensely pruritic, erythematous, edematous papules along cold-exposed skin surfaces with or without systemic symptoms. After a plastic-wrapped ice cube is placed on the forearm for several minutes, a square urticarial plaque will develop during rewarming of the skin. Affected divers may also lose consciousness and experience anaphylaxis, which can result in drowning.[33]

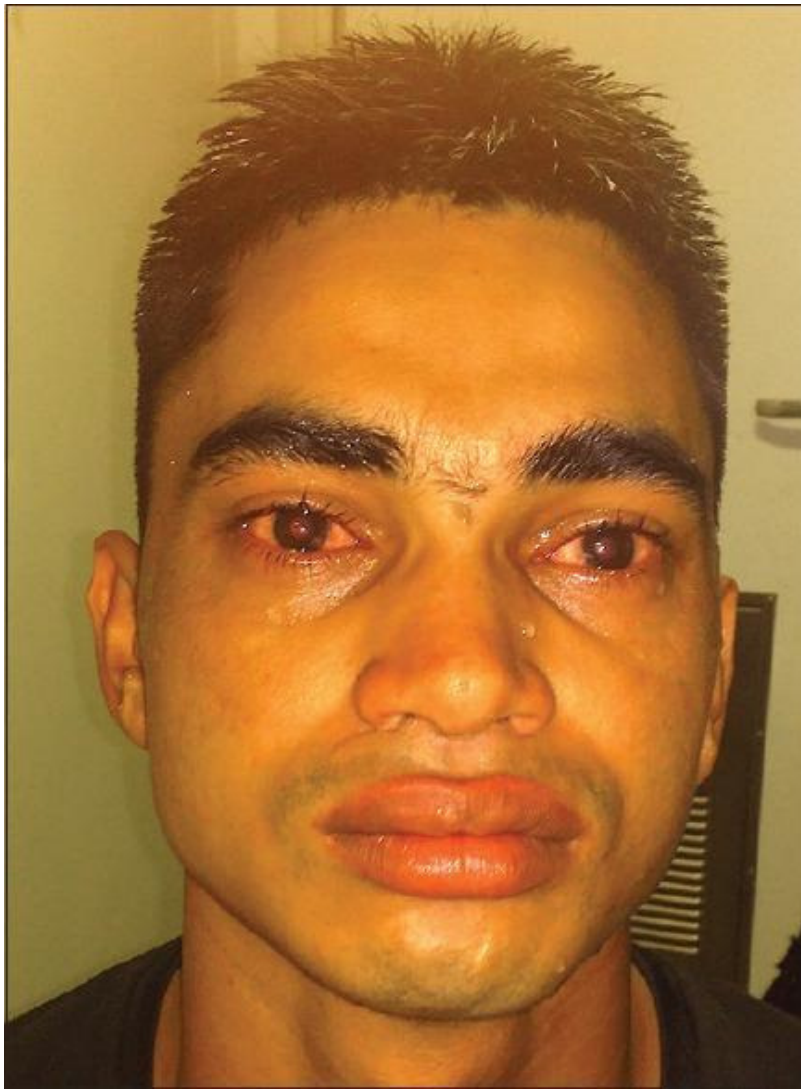
Management: Antihistamines effectively treat cold urticaria. Protective clothing is ideal when exposed to cold environments. Secondary causes for cold urticaria need to be borne in mind.

### Purpura gogglorum and mask squeeze

Cause: Purpura gogglorum is a periocular purpura induced by goggles.[34] Proposed etiologies of this disorder include:

- Direct collision forces or goggles snapping back into the eye[35]
- Suction trauma from frequent pulling away of goggles from the face under negative pressure[36] and
- Progressive pressure, most often seen in children who regularly tighten the strap of their poorly-fitting goggles to compensate for a leaking seal.[37]

Clinical features: Swimmers may present with periocular purpura or congestion of mucosal surfaces [Figure 4].



[Figure 4](#)

Mask squeeze

**Management:** Lesions heal spontaneously. In case of extensive tenderness, swelling, or vision changes, patients need to be evaluated for the possibility of fracture of orbital bones.

### Swimmer's shoulder

**Cause:** During freestyle swimming, an unshaven chin may rub against the shoulder while a swimmer turns the head to breathe, resulting in an irritant dermatitis known as “swimmer's shoulder.”[\[38\]](#)

**Clinical features:** There may be erythematous, abraded plaques on the anterior aspect of the shoulder which may be noted shortly after swimming.[\[38\]](#)

**Management:** Lesions generally heal without treatment. Application of an emollient may alleviate soreness.

### Swimmer's xerosis

Cause: With repeated immersion, sebum is lost; water's tendency to evaporate from the outer skin layers also contributes to swimmer's xerosis. Taking prolonged, hot showers after swimming further exacerbates this dryness.[5]

Clinical features: Swimmer's xerosis manifests with dryness, scaling, and itching of skin, most notably during the winter months.[5]

Management: Application of petrolatum before and after entering the water is recommended. Long showers after swimming need to be avoided. Topical steroid preparations relieve any dry eczematous changes that might develop.

### Suit squeeze

Barotrauma or "suit squeeze" occurs when folds of skin become trapped in creases of a dry suit during compression, giving rise to a typical dark, linear, or reticulate pattern of skin marking.[5]

## Sailing and Rowing

---

### Sailor's marks

Cause: Sailor's marks denote multiple areas of lichenification of the skin of the hands of sailors/fishermen due to repetitive contact and friction between the rope and hands.[39]

Clinical features: Band-shaped calluses manifest bilaterally on the dorsolateral and palmar regions of the first metacarpophalangeal (MCP) joint and the medial surface of the palmar aspect of the fifth MCP joint.[39]

Management: Wearing of protective gloves while sailing is recommended.

### Rowing blisters

Cause: Rowing blisters result from friction between rower's hands and the oar handles.[40]

Clinical presentation: Individuals present with painful blisters that typically manifest on the anterior surfaces of the fingers and palms.[36]

Management: Treatment consists of supportive care of the blisters by draining the lesions without disruption of the roof of the blister up to three times in the 1<sup>st</sup> day and application of petroleum jelly and occlusive dressing.[40]

### Freshwater dermatoses

Hot tub folliculitis (Syn: *Pseudomonas* folliculitis, splash rash) Cause: Hot tub folliculitis is a community-acquired skin infection that results from exposure to contained, skin contaminated water (e.g., of bathtubs, swimming pools, whirlpools, saunas, water slides or swimming pool inflatables). It is caused by *P. aeruginosa* O:11[41] that survives well in warm water, high pH (>7.8), and low chlorine level (<0.5 parts per million). Prolonged water exposure, excessive numbers of bathers, and inadequate pool or hot tub care are the predisposing factors. The condition has also been described to occur following the use of contaminated bathing objects such as loofah sponges.[42]

Clinical features: Follicular erythematous macules appear that progress to papulopustules over 8–48 h after exposure to contaminated water/fomites.[5] Lesions are most prevalent in intertriginous areas or under bathing suits. Lesions also involve exposed skin, but they usually spare the face, neck, soles, and palms. The follicular erythematous macules demonstrate a pale, green fluorescence under Wood's light. [5] Patients may also experience fever, malaise, nausea, diarrhea, otalgia, sore throat, and lymphadenopathy. The rash usually clears spontaneously in 2–10 days, and heals without scarring, but



it may cause desquamation or leave hyperpigmented macules. Rare complications which typically occur in immunosuppressed individuals include abscess formation, ecthyma gangrenosum, subcutaneous nodules, and cellulitis.[43]

Management: In immunocompetent patients, the infection resolves spontaneously within 2 weeks; hence, no treatment is necessary. No evidence exists that the course of the skin condition is altered with treatment. Treating hot tub folliculitis can even result in recurrence. Acetic acid 5% compresses for 20 min twice to four times daily may provide symptomatic relief. Only in severe cases and in immunosuppressed patients, should the use of antibiotics be considered. A course of ciprofloxacin is advised.[5]

### Pseudomonas hot foot syndrome

Cause: *P. aeruginosa* O:11 also causes the *Pseudomonas* hot foot syndrome. The condition has been linked to wading in pools whose floor is coated with abrasive grit. Community outbreaks similar to hot tub folliculitis have been described.[41]

Clinical features: The condition is characterized by exquisitely tender plantar nodules of acute onset in children and a benign, self-limited course. Lesions typically develop within 48 h of exposure to contaminated water.[5] Palmoplantar eccrine hidradenitis is a differential diagnosis; here, sterile lesions occur on the soles of athletes using cold, damp footwear.[44]

Management: As with hot tub folliculitis, patients require only symptomatic treatment. Superchlorination of the pool water, reducing the abrasiveness of pool floors, and scrubbing of pool surfaces and water inlets with quaternary ammonium compounds are the recommended preventive measures.[41]

### Contact dermatitis to pool water

Cause: Pool dermatitis is an irritant contact dermatitis to chlorine and bromine added to the water in pools while “pool water dermatitis” represents an allergic contact dermatitis to the same agents.[45] Contact dermatitis to potassium peroxydisulfate, a pool and hot tub sanitation chemical involved in the elimination of organic contaminants, may also occur.[5] Swimmers may also present with the “bleached swimmer syndrome,” a blonding reaction of body hair, following exposure to the above chemicals.

Clinical features: There may be urticarial or eczematous plaques over the uncovered areas. There may also be loss of body hair, a lightening of dark hair, and a change in the color of swimsuits from dark to white.[5]

Management: Avoidance of pool water and topical corticosteroids is sufficient to treat the contact dermatitis. Swimmers with bleached hair need to be reassured while notifying the pool authorities about the possible high concentration of pool chemicals.

### Platform purpura

Cause: During a missed dive, impact of the diver entering the water may transmit to the skin on the thighs, causing purpura.[5]

Clinical features: There may be symmetrical, variably painful, erythematous plaques on the thighs.

Management: Warm compresses for 5–10 min two or three times daily to relieve the pain, and nonsteroidal anti-inflammatory drugs are beneficial.[5] Lesions resolve over several days.

### Pool palms

Cause: Repetitive rubbing of skin surfaces against rough surfaces in the pool causes a frictional dermatitis called pool palms.[46]

Clinical features: Erythematous plaques are seen over the convexities of palmar hands and fingers.

Management: The condition resolves spontaneously.

### Contact urticaria

Cause: Contact with chlorinated swimming pool water may cause urticaria.[5]

Clinical features: Athletes present with urticarial plaques overlying submerged surfaces 1–5 h after exposure.

Management: Antihistamines usually provide relief.

### Waterslide alopecia

Cause: Alopecia may occur at sites of friction with waterslides of amusement parks.[47]

Clinical features: Symmetric alopecia may be noted over the posterior calves.

Management: Reassurance that the hair will regrow to its normal length in 1–2 months would suffice.

### Protothecosis

Cause: *Prototheca wickerhamii* and *Prototheca zopfii* are achlorophyllic mutants of the green alga chlorella that inhabit both streams and lakes.[48] They also dwell in sewage, slime flux, and animal waste. Cutaneous and extracutaneous infection may result from primary inoculation through a wound acquired in an aquatic environment. In immunocompetent patients, the infection is usually mild, while more commonly, it affects immunosuppressed patients more aggressively.

Clinical features: Patients present with nontender, isolated plaque, or nodule with or without pustules or large eczematous, herpetiform, verrucous, plaques, or ulcers on exposed sites.[49] Olecranon bursitis as well as disseminated or systemic manifestations may occur. Meningeal involvement in immunodeficient patients has also been reported. Diagnosis may be confirmed by skin biopsy revealing the typical “morula-”shaped spores, but the organisms can also be grown on Sabouraud's glucose agar.

Management: Localized disease may be treated with ketoconazole, itraconazole, or voriconazole,[50] and surgical excision. Adjunctive thermal therapy to isolated lesions may be effective. For disseminated disease, intravenous amphotericin B is recommended.[48]

## Miscellaneous Freshwater Dermatoses

---

### *Aeromonas hydrophila* infection

Cause: *Aeromonas hydrophila*, a facultative, anaerobic motile Gram-negative rod, inhabits freshwater lakes and streams and may cause severe soft-tissue infections.[51,52] *A. hydrophila* folliculitis may also occur and could mimic hot tub folliculitis caused by *P. aeruginosa*.

Clinical presentation: The infection presents as rapid onset of cellulitis or an abscess after water contamination of a wound. Within the first 24 h, there is erythema, swelling, and a foul odor likened to that of dead fish.[51]

Management: Severe infections require rapid surgical intervention and antibiotic therapy with oral aminoglycosides or third-generation cephalosporins.[52] Gentamicin cream is efficacious for folliculitis.

## Saltwater Dermatoses

---

### Organism-related dermatoses

**Vibrio vulnificus** infections Cause: First identified as a human pathogen in 1979, *Vibrio vulnificus* causes wound infections, gastrointestinal disease, and infections that occur through traumatic injury in the marine environment or ingestion of raw or undercooked shellfish.[53]

Clinical features: Two distinct syndromes have been described in swimmers: (a) A primary septicemia that results from consumption of undercooked seafood, especially raw oysters. Patients experience fever, diarrhea, nausea, vomiting, and even septic shock soon after consumption. Typically, within 24 h of the onset of symptoms, patients experience the characteristic skin lesions, which consist of severe cellulitis with ecchymoses and bullae.[54] (b) The second syndrome, a necrotizing wound infection secondary to direct inoculation, causes swimmers and divers to develop a painful, rapidly progressive cellulitis along with systemic symptoms and a mortality rate >50%, particularly in immunocompromised hosts, in patients with liver disease or diabetes mellitus. The infection also affects males more frequently than females as a result of the female hormone estrogen, which provides protection against the *V. vulnificus* endotoxin through an unknown mechanism.[54] The diagnosis of *V. vulnificus* infection involves a thorough history, noting marine-related trauma, and ingestion of seafood within 24 h of presentation. Communicating a clinical suspicion of *V. vulnificus* infection allows the microbiologist to use enhanced growth media for wound, stool, and blood cultures to isolate the organism.

Management: Treatment requires the use of doxycycline with a third-generation cephalosporin. In children, trimethoprim-sulfamethoxazole plus an aminoglycoside is used. Necrotic wounds may require debridement or even amputation.[52]

### Erysipeloid

Cause: Erysipeloid is caused by *Erysipelothrix rhusiopathiae*, a Gram-positive, nonsporulating rod. In fish, the organism can persist for long periods in the exterior slime without causing cutaneous infections.[55] In humans, *E. rhusiopathiae* infection usually occurs following skin injury while handling or preparing colonized fish with an incubation period of 1–2 days.

Clinical features: Most human infections are of two cutaneous forms, localized cutaneous (erysipeloid) and generalized cutaneous; both of which are characterized by painful, throbbing erythematous, and intensely pruritic lesions. Unlike cutaneous infections, invasive *E. rhusiopathiae* infections are unusual and are characterized by septicemia and subacute bacterial endocarditis, which can be easily misidentified as *Streptococcus viridians* endocarditis.[55]

Management: The organism is sensitive to penicillins, first-generation cephalosporins, and carbapenems but resistant to vancomycin and aminoglycosides.[53]

## Invertebrate Stings and Envenomations

---

The invertebrates constitute the largest group of organisms known to cause marine envenomations or cutaneous harm in humans. This group consists of six phyla: *Cnidaria*, *Porifera*, *Echinodermata*, *Mollusca*, *Annelida*, and *Platyhelminthes*. Among these phyla are organisms that inject venom into their prey (i.e., cnidarians), those that secrete toxic substances known as crinotoxins (i.e., sponges), those with a biting apparatus for transfer of venom (i.e., octopus), and those with chitinous bristles (i.e., polychaete worms), which cause extreme irritation on contact with the skin. *Platyhelminthes* (flat worms) that are responsible for cercarial dermatitis (swimmer's itch) are also included in this group.

### Cnidarial dermatoses

Cause: The phylum *Cnidaria*, formerly known as coelenterates, comprises four classes: *Hydrozoa*, *Scyphozoa*, *Cubozoa*, and *Anthozoa* [Table 3]. They account for the majority of dermatoses that occur in the Indian marine setting.

Table 3

Four classes of phylum *Cnidaria*

---

*Cnidaria*

*Hydrozoa* - Portuguese man-of-war, fire corals

*Scyphozoa* - True jellyfishes

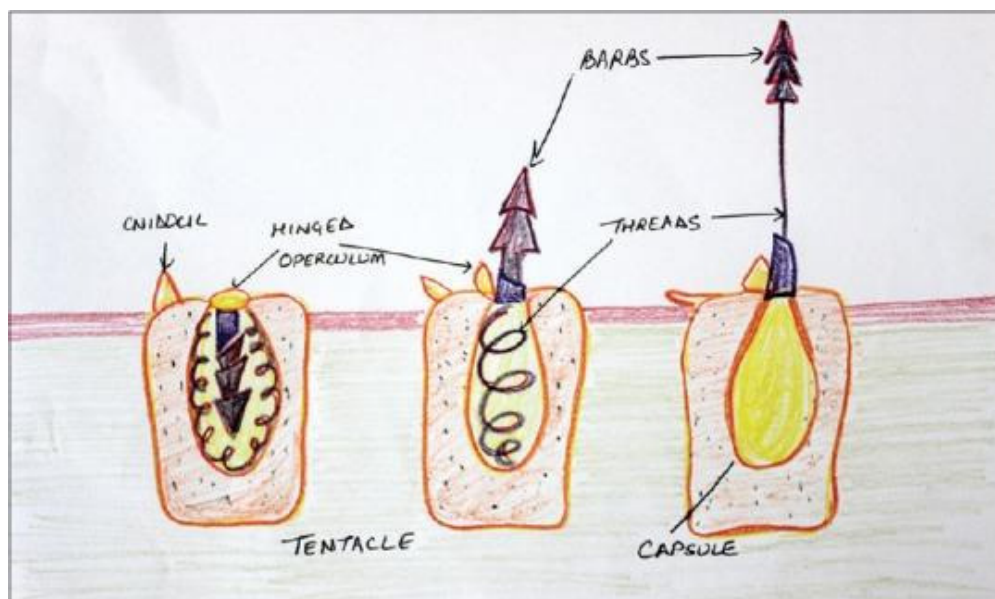
*Anthozoa* - Sea anemones, true corals

*Cubozoa* - Box jellyfishes, *Chironex fleckeri*, *Carukia barnesi*

---

All cnidarians possess highly coiled hollow harpoon-like microtubules called nematocysts on their tentacles that inject a toxin into the skin upon contact. The stings from cnidarians constitute the most frequent envenomations encountered by humans in the marine environment. Both physical and chemical interactions with prey cause the nematocyst to fire, ejecting the harpoon-like structure. Some Cnidarians possess a cnidocil or firing mechanism while others possess chemoreceptors that interact with both the environment and prey to cause firing of the nematocyst [Figure 5]. Two classes of chemoreceptors are involved in prey envenomations: (a) Those specific for N-acetylated sugars and (b) those specific for low-molecular-weight amino acids.[6] Once in contact with prey (or humans), the tube-like organelle is ejected through the capsule into the victim in milliseconds.[49] In humans, microtubules penetrate into small dermal capillaries, ejecting venom, and exerting their toxic effect. Interestingly, nematocysts do exhibit species variation, and this may help in the identification of the offending organism. The complete set of nematocysts identifying a specific organism is known as a cnidome.

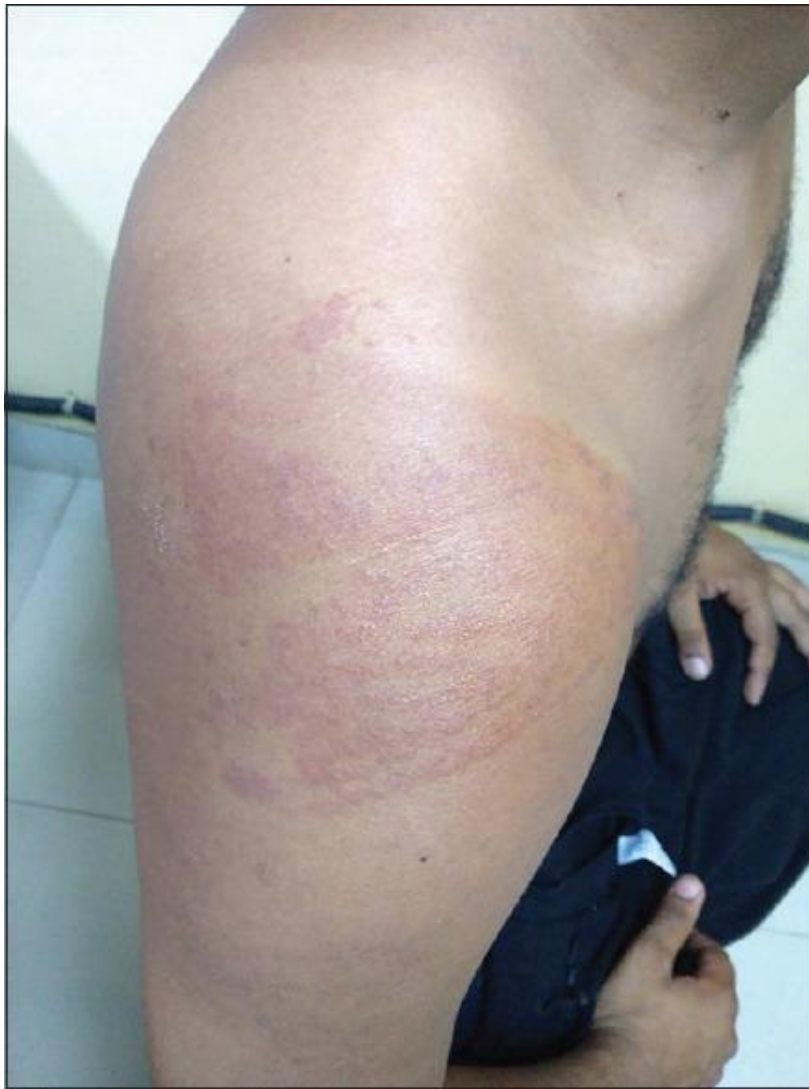



[Figure 5](#)

Structure of the nematocyst

Clinical features: Presentations in humans following cnidarian envenomations may range from local reactions – a whip-like sting pattern, bulla formation, urticaria, allergic contact dermatitis, erythema nodosum, and granuloma annulare[49] – to life-threatening anaphylaxis, hemolysis, cardiac arrhythmias, and renal failure, especially with stings of the Portuguese man-of-war (*Physalia physalis*) and box jellyfish (*Chironex fleckeri*). Irukandji syndrome results from contact with another variety of box jellyfish *Carukia barnesi* and possibly, other species. It is characterized by the presence of discrete lesions, severe pain at the sting site, headache, backache, joint pains, nausea, and vomiting. Pulmonary edema and heart failure may ensue.[56] The linear plaques caused by box jellyfishes and Portuguese man-of-war are longer than those of the true jellyfishes [Figure 6]. This is an important clinical sign to separate the two groups of lesions. The importance of this fact is that the first group provokes severe injuries, with systemic manifestations, but the true jellyfishes rarely do.[49]



[Figure 6](#)

Jellyfish sting

Management: In general, affected swimmers should immediately apply vinegar and cold packs to the wound [Table 4].[6] Some authors believe that applying sand to the area may help in removing unfired nematocysts. Clinicians must also consider pain management and tetanus prophylaxis. Warm compresses, antihistamines, and topical steroids may assuage symptoms. Swimmers with circulatory or respiratory collapse require epinephrine. It is important to note that swimmers should not immerse themselves in freshwater after being stung by saltwater *Cnidaria* because this may activate nematocysts.[49]

Table 4

Treatment of some common marine dermatoses

Organism	Treatment
Portuguese man-of-war	Controversial. Vinegar, hot saline immersion, removal of nematocyst
Common jellyfish	Vinegar, removal of nematocysts, cold seawater rinse
Box jellyfish	Removal of nematocysts, cold seawater rinse, antivenom if indicated
Fire coral	Cold seawater rinsing, removal of nematocysts, vinegar
True coral	Removal of organism, irrigate wound with antibacterial cleanser, explore wound, antibiotics
Sea urchin	Same as the true coral, possible radiographic examination
Swimmer's itch	Brisk towel drying, cool compresses, antihistamines, topical steroids
Bony fish injury	Check wound for retained spines, hot water immersion, analgesics, antibiotics
Sponge	Vinegar compresses, topical steroids, spicule removal

### Seabather's eruption

Cause: Seabather's eruption is dermatitis that affects seabathers, swimmers, and divers after contact with larvae of the adult sea anemone *Edwardsiella lineata* and the thimble jellyfish *Linuche unguiculata*. The larvae become trapped in the bathing suits of swimmers, and pressure caused by the bathing suit or wetsuit results in toxin release.[57]

Clinical features: Stinging sensation and pruritus followed by vesicles, papules, and pustules with or without urticaria occur in areas beneath the swimming suit[49] which may begin after exiting the water but may evolve over hours. The rash typically occurs under the confines of the bathing suit where the larvae become trapped, but uncovered areas may also be affected. Lesions may be follicular with the potential for pustular and vesicular variants. Systemic manifestations including fever, headache, nausea, abdominal pain, and diarrhea have been reported.[57] The differential diagnosis of seabather's eruption includes seaweed dermatitis (*Lyngbya majuscula*), which may appear identical clinically, and swimmer's itch, caused by a cercarial larva affecting uncovered body sites.

Management: The lesions are very difficult to prevent; treatment of seabather's eruption includes the use of topical and systemic antihistamines and potent topical steroids. Importantly, the swimsuit must be washed with detergent to remove any residual larvae before reuse.

### Coral cuts

Cause: Corals, members of the class *Anthozoa*, are classified as either hard or soft corals. Hard corals consist of a calcium carbonate exoskeleton and are the main constituents of reefs.[8] Lacerations from the calcium carbonate exoskeleton of hard corals introduce debris, bacteria, and nematocysts into the wound. Soft corals lack a calcified exoskeleton but contain stinging nematocysts. Although soft corals do not cause lacerations, some members of the order do harbor a potent neurotoxin known as palytoxin. Palytoxin may be ingested by other larger predator organisms (mackerel, triggerfish, crabs) and then consumed by humans, causing palytoxin poisoning.

Clinical features: Coral cuts harbor a potential for infection, foreign body granulomas, and delayed wound healing. Palytoxin ingestion acts upon  $\text{Na}^+/\text{K}^+$  ATP-ase and causes rhabdomyolysis, severe muscle excitability, and respiratory distress.[8]

Management: It is imperative that coral cut wounds are well irrigated with povidone iodine, explored to remove debris, and followed by tetanus toxoid and prophylactic antibiotics. Coral lacerations may take weeks to heal. Treatment of palytoxin poisoning is supportive with close monitoring of renal and pulmonary function.

### Sponges dermatitis

Cause: Sponges belong to the phylum *Porifera* and are found in both marine and freshwater environments. Sponges have silicious spicules in their exoskeleton and some secrete crinotoxins both of which cause harmful effects upon contact with the skin.[8]

Clinical features: Spicules of freshwater sponges *Drulia uruguayensis* and *Drulia ctenosclera* may cause ocular lesions, while those of marine sponges *Neofibularia nolitangere* (“touch me not” sponge) and *Tedania ignis* (fire sponge) may cause fiberglass dermatitis-like irritant skin lesions. *Microciona prolifera* (red moss sponge) may cause immediate stinging, burning, and erythema due to the effect of the crinotoxin.

Management: The use of adhesive tape is recommended for spicule removal, while acetic acid compresses followed by topical steroids aid in treating the effects of the crinotoxins.[8]

### Echinoderm dermatoses

Cause: Echinoderm dermatoses result from contact with marine invertebrates from the phylum *Echinodermata*. Organisms that may cause injury include sea stars, sea urchins, and sea cucumbers. Sea urchins typically creep along the sea bottom and have surface spines with blunt or sharp tips that may contain venom glands.[8] Sea cucumbers are bottom-dwelling, sausage-shaped echinoderms that produce holothurin, a potent cardiac glycoside, on their surface.

Clinical features: Painful wounds with surrounding erythema may occur on the hands or on the soles after a diver handles a sea urchin or walks on the sea bottom. Systemic reactions including nausea, syncope, and respiratory distress may occur. The toxin holothurin on the surface of sponges may cause acute irritant dermatitis, painful chemical conjunctivitis, or blindness. Ingestion of sea cucumbers may result in death.[8]

Management: Divers ought to wear gloves while handling sea urchins and sea cucumbers. Symptomatic treatment following contact with sea urchins includes warm compresses, topical corticosteroids, and antihistamines. Swimmers affected by sea cucumbers should immediately irrigate the wound with warm water, soap, vinegar, or isopropyl alcohol to rinse off the holothurin toxin. Ocular injury needs treatment with topical anesthesia followed by copious irrigation and an ophthalmologic consultation.[8]

### Seaweed dermatitis



Cause: *L. majuscula*, a common blue-green alga found throughout the Pacific, Indian, and Caribbean oceans, causes seaweed dermatitis. It produces active irritants that result in acute dermatitis.[49]

Clinical features: The condition presents with blisters and deep desquamation in areas covered by bathing suits.[50] Swimmers generally experience a stinging, burning, or itching sensation within 24 h of contact.[49] Shortly thereafter, erythematous dermatitis appears, most commonly surrounding the perineal and perianal areas that lasts for approximately 1 week. Patients may also experience respiratory irritation and burning of the upper gastrointestinal tract on ingestion.

Management: Treatment consists of symptomatic relief with cool compresses, topical steroids, antihistamines, and analgesics.

#### General management of marine injuries

- Even minor abrasions and lacerations should be considered potentially contaminated with common marine *Vibrio* species[52]
- All wounds should be irrigated initially with normal saline
- Crushed or devitalized tissues should be excised under local anesthesia or peripheral nerve blocks. Foreign bodies should be removed
- Diagnostic imaging is often indicated, especially in puncture wounds, to exclude retained foreign bodies
- Potential constriction bands, such as bracelets, rings, and watches, should be removed from the injured extremity. Baseline extremity circumference measurements must be taken in the event of swelling from necrotizing fasciitis and compartment syndromes
- Sequential surgical debridement will be indicated in all cases of necrotizing fasciitis; fasciotomies may be needed for compartment syndromes
- Most wounds should be left open or packed open to heal by secondary intention. Delayed primary closures may be indicated for potentially disfiguring facial wounds
- Tetanus prophylaxis is indicated for all marine wounds.

## Miscellaneous Dermatoses

---

### Diver's hand

Cause: Saturation divers may develop extensive peeling of the upper skin layers of the palms and occasionally the soles, a condition known as “diver's hand.”[58]

Clinical features: Scaling and fissuring usually begin at the distal fingers and progress proximally.[58] Most experience peeling of large, 3–6 cm areas. The condition usually resolves spontaneously within 2–4 weeks if patients refrain from further saturation diving.

Management: Medium-potency steroids provide symptomatic relief.

### Cutaneous aspects of decompression sickness

Cause: The condition is seen among deep sea divers. Due to a reduction in the environmental pressure during dive ascent (decompression), gases from the scuba set that had dissolved in the blood and tissues escape as bubbles. These bubbles may affect the neurological system, musculoskeletal system,

inner ear, skin, and lymphatics, causing symptoms of decompression sickness (DCS). Cutaneous symptoms are seen in 3% of cases of DCS.[59] It likely occurs due to bubble emboli passing through an “overloaded” lung filter or due to autochthonous bubble formation.[60]

Clinical features: Skin manifestations range from being local and innocuous, to generalized and ominous. Pruritus, followed by a scarletiform rash, may occur due to piloerection and tissue histamine release caused by dissolved gases in the cutaneous blood vessels. Coughing will accentuate the skin lesions (Mellinghoff sign), confirming systemic DCS. If the condition progresses, dissolved gases interfere with venous drainage resulting in cutis marmorata and subcutaneous emphysema, both signs of serious, systemic DCS. Impaired drainage of cutaneous lymphatics over the trunk may cause a lymphoedematous peau d’orange to occur. Bubble formation in the myelin sheath of peripheral nerves can result in transient paresthesias, numbness, and weakness.[60]

## Conclusion

---

India has a long coastline with varied marine flora and fauna. In addition to having a blue-water Navy, the India's coastline has been witnessing a surge in fishing, recreational diving, beach tourism, and aquatic sport, exposing the population to an assortment of aquatic-related dermatoses. The approach to patients with such dermatoses consists of appropriate history-taking to recognize the type of aquatic activity, saltwater versus freshwater exposure, duration of the water exposure, and any contact with aquatic organisms or aquatic-related equipment. Specific treatment and preventive measures must be prescribed accordingly. Epidemiological studies will further improve the understanding of these dermatoses.

## Declaration of patient consent

The authors certify that they have obtained all appropriate patient consent forms. In the form the patient(s) has/have given his/her/their consent for his/her/their images and other clinical information to be reported in the journal. The patients understand that their names and initials will not be published and due efforts will be made to conceal their identity, but anonymity cannot be guaranteed.

## Financial support and sponsorship

Nil.

## Conflicts of interest

There are no conflicts of interest.

### What is new?

- Surge in fishing, recreational diving, beach tourism, and aquatic sport in India
- Medical practitioners increasingly encounter aquatic-related dermatoses
- Timely recognition and management is of essence.

## References

---

1. Sanil Kumar V, Pathak KC, Pednekar P, Raju NS, Gowthaman R. Coastal processes along the Indian coastline. *Curr Sci*. 2006;91:530–6. [[Google Scholar](#)]

2. Venkatraman K, Wafar M. Coastal and marine biodiversity of India. *Indian J Mar Sci.* 2005;34:57–75. [[Google Scholar](#)]
3. Horák P, Mikeš L, Lichtenbergová L, Skála V, Soldánová M, Brant SV. Avian schistosomes and outbreaks of cercarial dermatitis. *Clin Microbiol Rev.* 2015;28:165–90. [[PMC free article](#)] [[PubMed](#)] [[Google Scholar](#)]
4. Jauhari RK, Nongthombam PD. Occurrence of a snail borne disease, cercarial dermatitis (swimmer itch) in Doon Valley (Uttarakhand), India. *Iran J Public Health.* 2014;43:162–7. [[PMC free article](#)] [[PubMed](#)] [[Google Scholar](#)]
5. Tlougan BE, Podjasek JO, Adams BB. Aquatic sports dermatoses: Part 1. In the water: Freshwater dermatoses. *Int J Dermatol.* 2010;49:874–85. [[PubMed](#)] [[Google Scholar](#)]
6. Ottuso P. Aquatic dermatology: Encounters with the denizens of the deep (and not so deep) a review. Part I: The invertebrates. *Int J Dermatol.* 2013;52:136–52. [[PubMed](#)] [[Google Scholar](#)]
7. Gluckman SJ. *Mycobacterium marinum*. *Clin Dermatol.* 1995;13:273–6. [[PubMed](#)] [[Google Scholar](#)]
8. Gonzalez-Santiago TM, Drage LA. Nontuberculous mycobacteria: Skin and soft tissue infections. *Dermatol Clin.* 2015;33:563–77. [[PubMed](#)] [[Google Scholar](#)]
9. Etuaful S, Carbonnelle B, Grosset J, Lucas S, Horsfield C, Phillips R, et al. Efficacy of the combination rifampin-streptomycin in preventing growth of *Mycobacterium ulcerans* in early lesions of buruli ulcer in humans. *Antimicrob Agents Chemother.* 2005;49:3182–6. [[PMC free article](#)] [[PubMed](#)] [[Google Scholar](#)]
10. Rapid resolution of *Mycobacterium marinum* chronic skin infection during lenalidomide therapy for chronic lymphocytic leukemia. *Clin Infect Dis.* 2008;46:69–71. [[PubMed](#)] [[Google Scholar](#)]
11. Kujundzic M, Braut T, Manestar D, Cattunar A, Malvic G, Vukelic J, et al. Water related otitis externa. *Coll Antropol.* 2012;36:893–7. [[PubMed](#)] [[Google Scholar](#)]
12. Ahlén C, Mandal LH, Iversen OJ. Identification of infectious *Pseudomonas aeruginosa* strains in an occupational saturation diving environment. *Occup Environ Med.* 1998;55:480–4. [[PMC free article](#)] [[PubMed](#)] [[Google Scholar](#)]
13. Saltzer KR, Schutzer PJ, Weinberg JM, Tangoren IA, Spiers EM. Diving suit dermatitis: A manifestation of *Pseudomonas folliculitis*. *Cutis.* 1997;59:245–6. [[PubMed](#)] [[Google Scholar](#)]
14. Basler RS, Basler DL, Basler GC, Garcia MA. Cutaneous injuries in women athletes. *Dermatol Nurs.* 1998;10:9–18. [[PubMed](#)] [[Google Scholar](#)]
15. de Almeida HL, Jr, Siqueira RN, Meireles Rda S, Rampon G, de Castro LA, Silva RM. Pitted keratolysis. *An Bras Dermatol.* 2016;91:106–8. [[PMC free article](#)] [[PubMed](#)] [[Google Scholar](#)]
16. Zichichi L, Asta G, Noto G. *Pseudomonas aeruginosa* folliculitis after shower/bath exposure. *Int J Dermatol.* 2000;39:270–3. [[PubMed](#)] [[Google Scholar](#)]
17. Nenoff P, Krüger C, Ginter-Hanselmayer G, Tietz HJ. Mycology – An update. Part 1: Dermatofungal diseases: Causative agents, epidemiology and pathogenesis. *J Dtsch Dermatol Ges.* 2014;12:188–209. [[PubMed](#)] [[Google Scholar](#)]
18. Gupta AK, Cooper EA. Update in antifungal therapy of dermatophytosis. *Mycopathologia.* 2008;166:353–67. [[PubMed](#)] [[Google Scholar](#)]

19. Prohic A, Jovovic Sadikovic T, Krupalija-Fazlic M, Kuskunovic-Vlahovljak S. *Malassezia* species in healthy skin and in dermatological conditions. *Int J Dermatol*. 2016;55:494–504. [[PubMed](#)] [[Google Scholar](#)]
20. Haiduk J, Treudler R, Ziemer M. Atrophying tinea versicolor with epidermal atrophy. *J Dtsch Dermatol Ges*. 2016;14:740–3. [[PubMed](#)] [[Google Scholar](#)]
21. Rosen T. Mycological considerations in the topical treatment of superficial fungal infections. *J Drugs Dermatol*. 2016;15(2 Suppl):s49–55. [[PubMed](#)] [[Google Scholar](#)]
22. Penso-Assathiany D, Flahault A, Roujeau JC. Warts, swimming pools and atopy: A case control study conducted in a private dermatology practice. *Ann Dermatol Venereol*. 1999;126:696–8. [[PubMed](#)] [[Google Scholar](#)]
23. Johnson LW. Communal showers and the risk of plantar warts. *J Fam Pract*. 1995;40:136–8. [[PubMed](#)] [[Google Scholar](#)]
24. Sterling J. Treatment of warts and molluscum: What does the evidence show? *Curr Opin Pediatr*. 2016;28:490–9. [[PubMed](#)] [[Google Scholar](#)]
25. Gottlieb SL, Myskowski PL. Molluscum contagiosum. *Int J Dermatol*. 1994;33:453–61. [[PubMed](#)] [[Google Scholar](#)]
26. Niizeki K, Kano O, Kondo Y. An epidemic study of molluscum contagiosum. Relationship to swimming. *Dermatologica*. 1984;169:197–8. [[PubMed](#)] [[Google Scholar](#)]
27. Bergendorff O, Hansson C. Contact dermatitis to a rubber allergen with both dithiocarbamate and benzothiazole structure. *Contact Dermatitis*. 2007;56:278–80. [[PubMed](#)] [[Google Scholar](#)]
28. Martellotta D, Di Costanzo L, Cafiero M, La Bella S, Balato A. Contact allergy to p-tert-butylphenol formaldehyde resin and zinc diethyldithiocarbamate in a wet suit. *Dermatitis*. 2008;19:E3–4. [[PubMed](#)] [[Google Scholar](#)]
29. Azurdia RM, King CM. Allergic contact dermatitis due to phenol-formaldehyde resin and benzoyl peroxide in swimming goggles. *Contact Dermatitis*. 1998;38:234–5. [[PubMed](#)] [[Google Scholar](#)]
30. Cao T, Yong AA, Tan KB, Tey HL. Idiopathic aquagenic pruritus: Pathogenesis and effective treatment with atenolol. *Dermatol Ther*. 2015;28:118–21. [[PubMed](#)] [[Google Scholar](#)]
31. Xifra A, Carrascosa JM, Ferrándiz C. Narrow-band ultraviolet B in aquagenic pruritus. *Br J Dermatol*. 2005;153:1233–4. [[PubMed](#)] [[Google Scholar](#)]
32. Casale TB, Olsen JA, DelasAlas HC. Aquagenic urticaria. *J Allergy Clin Immunol Pract*. 2013;1:295–6. [[PubMed](#)] [[Google Scholar](#)]
33. Singleton R, Halverstam CP. Diagnosis and management of cold urticaria. *Cutis*. 2016;97:59–62. [[PubMed](#)] [[Google Scholar](#)]
34. Jowett NI, Jowett SG. Ocular purpura in a swimmer. *Postgrad Med J*. 1997;73:819–20. [[PMC free article](#)] [[PubMed](#)] [[Google Scholar](#)]
35. Jonasson F. Swimming goggles causing severe eye injuries. *Br Med J*. 1997;1:881–3. [[PMC free article](#)] [[PubMed](#)] [[Google Scholar](#)]
36. Metzker A, Merlob P. Suction purpura. *Arch Dermatol*. 1992;128:822–4. [[PubMed](#)] [[Google Scholar](#)]
37. Basler GC. Skin problems in swimmers. *Rx Sports Dermatol*. 1999;1:2–5. [[Google Scholar](#)]



38. Koehn GG. Skin injuries in sports medicine. *J Am Acad Dermatol.* 1991;24:152. [[PubMed](#)] [[Google Scholar](#)]
39. Unal VS, Sevin A, Dayican A. Palmar callus formation as a result of mechanical trauma during sailing. *Plast Reconstr Surg.* 2005;115:2161–2. [[PubMed](#)] [[Google Scholar](#)]
40. Rumball JS, Lebrun CM, Di Ciacca SR, Orlando K. Rowing injuries. *Sports Med.* 2005;35:537–55. [[PubMed](#)] [[Google Scholar](#)]
41. Yu Y, Cheng AS, Wang L, Dunne WM, Bayliss SJ. Hot tub folliculitis or hot hand-foot syndrome caused by *Pseudomonas aeruginosa*. *J Am Acad Dermatol.* 2007;57:596–600. [[PubMed](#)] [[Google Scholar](#)]
42. Bottone EJ, Perez AA, 2nd, Oeser JL. Loofah sponges as reservoirs and vehicles in the transmission of potentially pathogenic bacterial species to human skin. *J Clin Microbiol.* 1994;32:469–72. [[PMC free article](#)] [[PubMed](#)] [[Google Scholar](#)]
43. El Baze P, Thyss A, Caldani C, Juhlin L, Schneider M, Ortonne JP. *Pseudomonas aeruginosa* O-11 folliculitis. Development into ecthyma gangrenosum in immunosuppressed patients. *Arch Dermatol.* 1985;121:873–6. [[PubMed](#)] [[Google Scholar](#)]
44. Tlougan BE, Podjasek JO, Dickman PS, Hansen RC. Painful plantar papules and nodules in a child. Palmoplantar eccrine hidradenitis (PEH) *Pediatr Ann.* 2008;37:83–4. 87. [[PubMed](#)] [[Google Scholar](#)]
45. Van Onselen J. Swimming pools and eczema. *J Fam Health.* 2015;25((4)(Suppl1)):8–9. [[Google Scholar](#)]
46. Blauvelt A, Duarte AM, Schachner LA. Pool palms. *J Am Acad Dermatol.* 1992;27:111. [[PubMed](#)] [[Google Scholar](#)]
47. Adams BB. Water-slide alopecia. *Cutis.* 2001;67:399–400. [[PubMed](#)] [[Google Scholar](#)]
48. Mayorga J, Barba-Gómez JF, Verduzco-Martínez AP, Muñoz-Estrada VF, Welsh O. Protothecosis. *Clin Dermatol.* 2012;30:432–6. [[PubMed](#)] [[Google Scholar](#)]
49. Tlougan BE, Podjasek JO, Adams BB. Aquatic sports dermatoses. Part 2 – In the water: Saltwater dermatoses. *Int J Dermatol.* 2010;49:994–1002. [[PubMed](#)] [[Google Scholar](#)]
50. Yun CH, Jeong JH, Ryu HR, Kim JH, Baek JO, Lee JR, et al. Cutaneous protothecosis responds rapidly to voriconazole. *Int J Dermatol.* 2016;55:1373–7. [[PubMed](#)] [[Google Scholar](#)]
51. Tlougan BE, Podjasek JO, Adams BB. Aquatic sports dermatoses: Part 3. On the water. *Int J Dermatol.* 2010;49:1111–20. [[PubMed](#)] [[Google Scholar](#)]
52. Diaz JH. Skin and soft tissue infections following marine injuries and exposures in travelers. *J Travel Med.* 2014;21:207–13. [[PubMed](#)] [[Google Scholar](#)]
53. Haddad V, Jr, Lupi O, Lonza JP, Tyring SK. Tropical dermatology: Marine and aquatic dermatology. *J Am Acad Dermatol.* 2009;61:733–50. [[PubMed](#)] [[Google Scholar](#)]
54. Bross MH, Soch K, Morales R, Mitchell RB. *Vibrio vulnificus* infection: Diagnosis and treatment. *Am Fam Physician.* 2007;76:539–44. [[PubMed](#)] [[Google Scholar](#)]
55. Romney M, Cheung S, Montessori V. Erysipelothrix rhusiopathiae endocarditis and presumed osteomyelitis. *Can J Infect Dis.* 2001;12:254–6. [[PMC free article](#)] [[PubMed](#)] [[Google Scholar](#)]
56. Little M, Mulcahy RF. A year's experience of Irukandji envenomation in far North Queensland. *Med J Aust.* 1998;169:638–41. [[PubMed](#)] [[Google Scholar](#)]

57. Rossetto AL, Da Silveira FL, Morandini AC, Haddad V, Resgalla C. Seabather's eruption: Report of fourteen cases. *An Acad Bras Cienc.* 2015;87:431–6. [[PubMed](#)] [[Google Scholar](#)]
58. Ahlén C, Iversen OJ, Risberg J, Volden G, Aarset H. Diver's hand: A skin disorder common in occupational saturation diving. *Occup Environ Med.* 1998;55:141–3. [[PMC free article](#)] [[PubMed](#)] [[Google Scholar](#)]
59. Brubakk AO, Neuman TS. Decompression. In: Bennett PB, Elliott DH, editors. *Bennett and Elliott's Physiology and Medicine of Diving.* 5th ed. Edinburgh: Saunders; 2003. [[Google Scholar](#)]
60. Wilmshurst PT, Pearson MJ, Walsh KP, Morrison WL, Bryson P. Relationship between right-to-left shunts and cutaneous decompression illness. *Clin Sci (Lond)* 2001;100:539–42. [[PubMed](#)] [[Google Scholar](#)]

---

Articles from Indian Journal of Dermatology are provided here courtesy of **Wolters Kluwer -- Medknow Publications**