

# Rapid ping-pong eye deviation following a recovery from carbon dioxide narcosis

Shuichiro Neshige <sup>1,2</sup>, Ohno Narumi,<sup>1</sup> Shiro Aoki,<sup>1</sup> Hirofumi Maruyama<sup>1,2</sup>

<sup>1</sup>Department of Clinical Neuroscience and Therapeutics, Hiroshima University Graduate School of Biomedical and Health Sciences, Hiroshima, Japan  
<sup>2</sup>Epilepsy Center, Hiroshima University Hospital, Hiroshima, Japan

## Correspondence to

Dr Shuichiro Neshige;  
s-neshige@hiroshima-u.ac.jp

Accepted 9 March 2021

## DESCRIPTION

A 70-year-old woman with a history of panic disorder was admitted to the emergency room for loss of consciousness from carbon dioxide (CO<sub>2</sub>) narcosis due to atelectasis following lobectomy for lung cancer. After mechanical ventilation, the carbon dioxide partial pressure (PCO<sub>2</sub>) and consciousness levels improved, but she was immobile, showing reduced responsiveness to the environment. While neurological tests for motor function yielded normal results, she did not attempt to move voluntarily. Although her language comprehension was preserved, she did not speak spontaneously. Even though she could breathe, she remained ventilator-dependent. Spontaneous breathing trials induced severe tachypnoea; thus, tracheostomy was performed. Multiple clinical examinations, including blood and cerebrospinal fluid testing and brain imaging, were normal. Electroencephalography showed background slowing. The PCO<sub>2</sub> level remained within normal values during these conditions. Therefore, the cause of her ventilator dependence was unclear. The only neurological abnormality was rapid 'ping-pong' eye deviations: an oculomotor disturbance characterised by involuntary, rapid, alternating gaze between right and left (video 1). These movements were pronounced under psychological stress, such as during neurological examination, but they completely disappeared when she was relaxed, for example, when watching television or spending time alone. Based on these findings, she was diagnosed with catatonia and functional saccadic oculomotor disturbance.<sup>1</sup> This manifestation gradually disappeared after 2-month liaison psychiatry therapy with antianxiety drugs. Acute catatonia should be suspected when a patient fails to withdraw from mechanical ventilation without evidence of a respiratory deficit. The

## Learning points

- ▶ Catatonia reduces a patient's responsiveness to the environment, leading to an immobile condition.
- ▶ Spontaneous breathing trials can fail because of severe catatonia.
- ▶ Functional saccadic oculomotor disturbance is a neurological sign of catatonic stupor.

absence of a neurological abnormality other than an oculomotor disturbance may assist in confirming the diagnosis, especially in patients with a history of psychiatric disorders.<sup>2</sup>

**Contributors** SN: conceptualised study; interpreted of the data; drafted the manuscript for intellectual content. ON: interpreted of the data; revised the manuscript for intellectual content. SA: interpreted of the data; revised the manuscript for intellectual content. HM: revised the manuscript for intellectual content.

**Funding** The authors have not declared a specific grant for this research from any funding agency in the public, commercial or not-for-profit sectors.

**Competing interests** None declared.

**Patient consent for publication** Obtained.

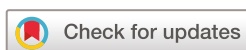**Provenance and peer review** Not commissioned; externally peer reviewed.

## ORCID iD

Shuichiro Neshige <http://orcid.org/0000-0002-5879-155X>

## REFERENCES

- 1 Feil K, Schöberl F, Klemm M, et al. Teaching Video NeurolImages: functional saccadic oculomotor disturbances. *Neurology* 2017;88:e30–1.
- 2 Kaski D, Bronstein AM, Edwards MJ, et al. Cranial functional (psychogenic) movement disorders. *Lancet Neurol* 2015;14:1196–205.



© BMJ Publishing Group Limited 2021. No commercial re-use. See rights and permissions. Published by BMJ.

**To cite:** Neshige S, Narumi O, Aoki S, et al. *BMJ Case Rep* 2021;14:e241740. doi:10.1136/bcr-2021-241740

Copyright 2021 BMJ Publishing Group. All rights reserved. For permission to reuse any of this content visit <https://www.bmj.com/company/products-services/rights-and-licensing/permissions/>  
BMJ Case Report Fellows may re-use this article for personal use and teaching without any further permission.

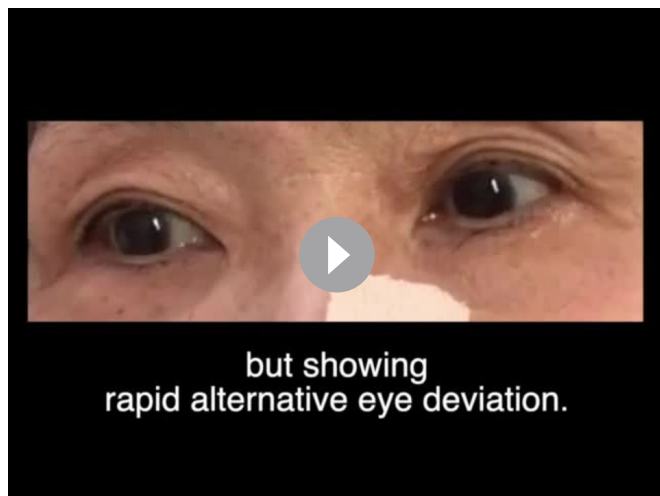
Become a Fellow of BMJ Case Reports today and you can:

- ▶ Submit as many cases as you like
- ▶ Enjoy fast sympathetic peer review and rapid publication of accepted articles
- ▶ Access all the published articles
- ▶ Re-use any of the published material for personal use and teaching without further permission

## Customer Service

If you have any further queries about your subscription, please contact our customer services team on +44 (0) 207111 1105 or via email at [support@bmj.com](mailto:support@bmj.com).

Visit [casereports.bmj.com](http://casereports.bmj.com) for more articles like this and to become a Fellow



**Video 1** Rapid alternative eye deviation: functional oculomotor disturbances are visible only during neurological examination in a patient with severe catatonia during postoperative stupor