

Ocular fundus lesions in sports divers using safe diving practices

R. Holden FRCS, C. D. G. Morsman FRCS(Ed) and C. M. Lane FRCS

Department of Ophthalmology, University Hospital of Wales, Cardiff, UK

Ocular fundus fluorescein angiography was performed on 26 divers, who had used safe diving practices for at least 10 years, and on seven controls. There was no significant difference in the incidence of macular abnormalities between these groups and those of a previous study. Adherence to safe diving practice confers some protection against the macular abnormalities known to occur in divers with a history of decompression sickness.

Keywords: Fluorescein angiography, macular abnormalities, safe diving practice

Subaqua diving is becoming an increasingly popular sport, with over 30 000 active divers in the UK alone. One previous study¹ has shown that asymptomatic retinal abnormalities are relatively common in divers. These were associated with a history of decompression sickness (DCS) and also with length of diving history. Concern was expressed that these lesions may predispose to sight-threatening macular disease and, also, reflect similar pathology occurring systemically. However, those studied were a heterogeneous group with a varied background of diving at both amateur and professional level. There was a relatively high incidence of previous DCS, which is still rare amongst amateur divers². We report a study on a group of wholly amateur divers who have practised safe diving over a period of 10 years or more.

Subjects and methods

Following an article in the British Sub Aqua Club (BSAC) magazine, divers of at least 10 years' experience were recruited from all over the UK. A group of divers with only 1 year's experience was recruited locally to act as controls. All those with any history of DCS or who had ever dived beyond the limits set by standard decompression tables were excluded. Decompression tables are used to calculate the duration of a dive appropriate for the depth, thus avoiding supersaturation of nitrogen in the blood on

ascent. Those with a history of ocular or systemic disease likely to cause fundal pathology were excluded.

Best corrected visual acuity and colour vision were recorded. Anterior and posterior segment examinations were performed. Following informed consent, all the subjects underwent fundus fluorescein angiography on one randomly selected eye. The angiograms were analysed by two masked observers, using projection, who examined the macular area for retinal pigment epithelial (RPE) defects and abnormalities of the parafoveal vasculature.

Twenty-six experienced divers and 12 controls were recruited. The 26 experienced divers represented approximately half of the initial respondents. The main reasons for exclusion were a previous digression from decompression tables or use of the increasingly popular but less stringent decompression computers. A detailed dive-by-dive history from log books was available from 17 of the 26 experienced divers. Owing to a camera fault five of the control angiograms were of unacceptable quality. It was felt unethical to repeat potentially hazardous procedures in these subjects thus reducing the control group to seven.

Results

All subjects had a corrected visual acuity of 6/6 or better and normal colour vision, except one of the controls who was a known deuteranope. None of the subjects had any clinical abnormalities of the anterior or posterior segment. Characteristics of each group are shown in *Table 1*. Discrete RPE defects in the

Table 1. Group characteristics

	Divers (n = 26)	Controls (n = 7)
Mean(s.d.) age (years)	39.3(9.6)	30(3.7)
M:F ratio	23:3	4:3
Mean(s.d.) diving history (years)	14(3.3)	1.1(2.2)
Mean(s.d.) number of deep dives* (n = 17)	77(92)	-

* Any depth below 30 m

Address for correspondence: Roger Holden, Research Registrar, Nuffield Laboratory of Ophthalmology, Oxford OX2 6AN, UK

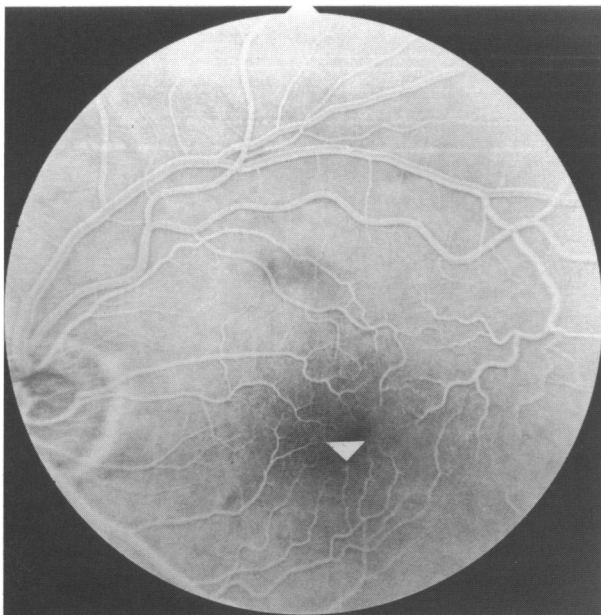
© 1992 Butterworth-Heinemann Ltd
0306-3674/92/020090-03

macular area and parafoveal vascular abnormalities were present in the angiograms of both groups, there being no significant difference between the two groups (Table 2). Typical examples of each are shown in Figure 1.

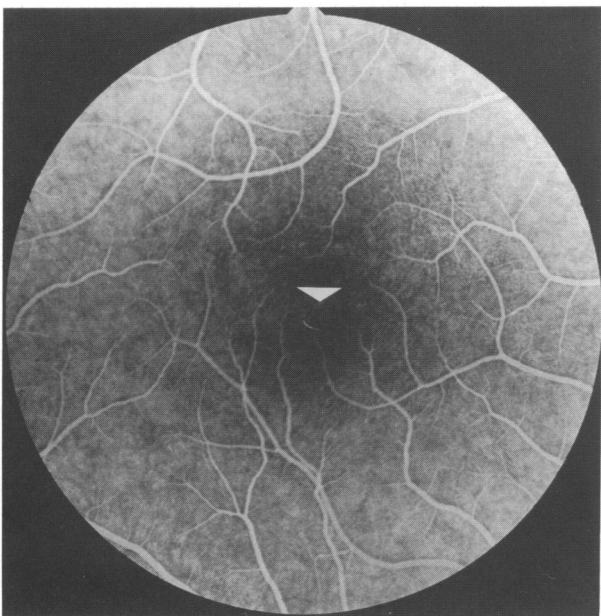
Table 2. Macular abnormalities

	Divers (n = 26)	Controls (n = 7)	P*	CI (%)
RPE defects	9	2	0.27	-32 to 44
Vascular abnormalities	12	1	0.12	0 to 64

CI, 95% confidence interval for population difference in proportions; RPE, retinal pigment epithelium; *Fisher exact probability test



a



b

Figure 1. Angiograms of macular area showing a abnormal capillary pattern (arrows) in a diver, and b retinal pigment epithelial defects in a control

Discussion

These findings suggest that with adherence to recognized safe diving practices, amateur divers are not prone to macular abnormalities. Comparing the incidence of RPE abnormalities in the experienced divers in this study and the controls in the one previous study¹ again shows no significant difference. Other studies^{3,4} have shown RPE defects to be a physiological variation in the normal angiogram. Polkinghorne *et al.*¹ found a higher incidence of specific retinal abnormalities in divers, and a decreased capillary density related to diving history. Estimation of macular capillary density was not performed in this study as there are few published data on normal variations in the retinal angiogram to compare with, especially in different age groups^{5,6}. Our results show a trend towards more vascular abnormalities in divers though this did not reach statistical significance. The wide confidence intervals reflect the small control group.

Macular abnormalities are more common in divers with a history of DCS¹. It may be that the underlying mechanisms of DCS cause these changes. These include vascular obstruction of the choroid and retina either by intravascular microbubbles of nitrogen activating the complement and coagulation systems or by the bubbles themselves⁷⁻¹¹. Alternatively, divers who expose themselves to the risks of DCS also have greater exposure to other hyperbaric phenomena. Hypercoagulability of blood under hyperbaric conditions is known to occur¹² and narrowing of the retinal vessels under such conditions has been observed¹³. Formation of toxic oxygen free radicals has also been proposed as a mechanism¹⁴.

Only divers who had maintained exemplary diving practices for over 10 years were included in this study. Our experience suggests that many divers do not use ideal decompression procedures. In 1988 the BSAC modified their standard decompression tables, originally designed for use by military personnel, introducing more stringent tables with the aim of further reducing the risks of DCS in amateur divers. More recently the BSAC limited the depths to which the majority of its members can dive¹⁵. Other major diving organizations have yet to follow this example. Safe diving practices appear to confer some protection against macular pathology in hyperbaric conditions. Further longitudinal studies are required to confirm this, especially with regard to retinal vascular changes. In the meantime, until the underlying causes of the macular and systemic lesions associated with DCS are elucidated, all attempts to improve safe diving practice are to be encouraged.

References

- 1 Polkinghorne PJ, Sehmi K, Cross M *et al.* Ocular fundus lesions in divers. *Lancet* 1988; ii: 1381-3.
- 2 *Diving Incidence Report*. London: British Sub Aqua Club, 1988.
- 3 Nielson NV. The normal retinal fluorescein angiogram I. *Acta Ophthalmol* 1982; 60: 657-70.
- 4 Nielson NV. The normal fundus fluorescein angiogram III. *Acta Ophthalmol* 1985; 63: 305-10.

Diver angiograms: R. Holden et al.

- 5 Cogan DG. Development and senescence of the human retinal vasculature. *Trans Ophthalmol Soc UK* 1963; **83**: 465–89.
- 6 Schwartz B, Kern J. Age, increased ocular and blood pressures and retinal and disc fluorescein angiograms. *Arch Ophthalmol* 1980; **98**: 1980–6.
- 7 Ward CA, Koheil A, McCulloch D *et al.* Activation of complement at the plasma–air or serum–air interface of rabbits. *J Appl Physiol* 1986; **60**: 1651–8.
- 8 Ogston D, Bennett B. Surface mediated reactions in the formation of thrombin, plasmin and kallikrein. *Br Med Bull* 1978; **34**: 107–12.
- 9 Philp RB, Schacham P, Gowdey CW. Involvement of platelets and microthrombi in experimental decompression sickness: similarities with disseminated intravascular coagulation. *Aerospace Med* 1971; **42**: 494–502.
- 10 Bayne CG, Hunt WS, Johanson DC *et al.* Doppler bubble detection and decompression sickness: a prospective clinical trial. *Undersea Biomed Res* 1985; **12**: 327–32.
- 11 Gardette B. Correlation between decompression sickness and circulating bubbles in 232 divers. *Undersea Biomed Res* 1979; **6**: 99–107.
- 12 Anderson JC, Bennett PC. Haematologic change caused by deep trimix diving. The Atlantis II experience. *Undersea Biomed Res (Suppl)* 1981; **8**: 43.
- 13 Polkinghorne PJ, Bird AC, Cross MR. Retinal vessel constriction under hyperbaric conditions. *Lancet* 1989; **i**: 1099 (Letter).
- 14 Pooley J, Walder DN. Changes in cell volume following hyperbaric exposure: a manifestation of oxygen toxicity. In: Bachrach AJ, Matzen MM, eds. *Underwater Physiology*, Vol. VII. Bethesda, Maryland: Undersea Medical Society, 1980, 45–53.
- 15 Parish T. Training: a new look for the 90's. *Diver* 1991; August: 27–8.

Announcement

We learn with deep regret of the death of our most distinguished Editor Emeritus, Dr Henry Evans Robson. Tributes will appear in the next Journal.