

DECOMPRESSION SICKNESS FOLLOWING REPEATED
BREATH-HOLD DIVES

P. Paulev, M.D.
Institute of Physiology
University of Aarhus
Aarhus, Denmark

In Submarine Medicine Practice page 259(1), it is stated that: "Decompression sickness is virtually impossible for the skin diver because he can not submerge deep enough or remain long enough to take up a troublesome amount of nitrogen — unless he has access to a supply of air at depth." In the following, the reliability of this statement is questioned by a report of a case of decompression sickness after repeated skin dives to great depths. The case reported concerns a Danish medical officer, an educated diver in the Danish Navy. The author has an intimate knowledge of the event, because the medical officer happened to be himself.

Method

The diving took place in a "free escape" tank, adjacent to the Diving School of the Norwegian Naval Base in Haakonsvaern at Bergen. The tank has a depth of 66 feet (20 m). The equipment and circumstances were the best possible for exercise in "free escape" and skin diving. (By skin diving is meant diving without any breathing apparatus.)

The applied technique for the skin dives was that of a so-called "bottom drop" ("feet-first surface dive"). Provided with a nose clip and a mask, the diver at the surface takes a deep breath, shoves off with his arms from the border of the tank and descends with head up - feet down, without making any movements of his extremities. After the first six to ten feet (two to three M), he will "drop to the bottom" with increasing speed.

On the day of the accident all my dives were skin dives, and no supply of air at depth was used. No oxygen-breathing took place between the dives. Before entering the water I had been in a recompression chamber for about eight minutes to 66 feet (20 M), as attendant during a pressure test. Immediately after that I went to the tank and performed the "bottom drop" technique, in connection with my duties as medical supervisor for Danish submarine crews. The following diving pattern was used in nearly all the dives. It took about 20 to 25 seconds to reach the bottom, where I was sitting or walking slowly about, until the urge to breathe became imperative, usually after about two minutes, which is my maximum breath-holding time during a "quiet dive" to that depth. By making a few powerful pulls on a rope attached above the tank, it was possible to ascend very fast (10 to 15 seconds). The "surface intervals" varied between a few seconds and one to two minutes. The total number of dives were about 60.

Result

The total time in the water was about five hours. During the last two hours I had progressive symptoms of nausea, dizziness and eructations but nothing else. Within one-half an hour after the end of the diving I got pains in the left hip joint, but only very slight at the beginning. They were not accentuated by movements. Later the pain became more intense and also affected the right knee joint. Besides dizziness, nausea and eructation, the right leg felt tired and my right arm was so weak that it was of little use. Two hours after the end of the diving, severe chest pains began. They were not influenced by expiration or change of position, and were accompanied by a feeling of inspiratory distress and a sense of imminent collapse. The paresthesia developed in the right hand together with blurring of vision.

Three hours after the diving a colleague found me markedly pale and exhausted as in impending shock. He made a short examination and substantiated visual disturbances and a partial paresis of the right arm. As the symptoms were in progress, accompanied by abdominal pains and anesthesia of the ulnar region of the right hand, I was placed in the recompression chamber. At six atmospheres absolute (at. abs.) pressure I felt an immediate relief with respect to the dizziness and nausea. In a few minutes the bends and the partial paresis had disappeared. After 25 minutes at 6 at. abs. the paresthesia and anesthesia disappeared, and only a slight prickly sensation in the right hand remained. The medical officer of the Diving School, after a careful examination, treated me after "Table 3" of the treatment table⁽²⁾. The treatment was successful with immediate relief of all symptoms and signs.

Discussion

The neurologic signs and the response to recompression make it certain that bubbles were in the vascular bed. Air embolism after lung rupture can not be ruled out just by the fact that no "free escape" or respiration in compressed air occurred in the water. A common case of acute lung rupture is, of course, excluded. Another possibility is a bronchial constriction or obstruction with a valve effect causing air to be trapped in a lung segment. Ruptures in the lung tissues and vascular walls might then cause air to enter the circulation and the peribronchial and mediastinal tissues, even though no bleeding occurred. A normal chest x-ray and no respiratory symptoms and signs during frequent and extensive diving in a year before and after the event can not totally rule out this explanation.

Let us consider the possibility of accumulation of nitrogen. During a breath-hold dive to 18.5 meters of depth we have in agreement with others determined the mean N_2 content of the alveolar air to about 87-93 per cent⁽⁸⁾ at the bottom dependent upon the time of exposure. Provided that the time function table is applicable in this connection it is possible from this percentage to calculate the PN_2 's in tissues with different half-times, after repeated breath-hold dives of the type here described (Figs. 1 and 2). In five minute tissues a PN_2 of 1565 mm of mercury is reached after 13 skin dives to 61 feet and a PN_2 of 2134 mm after the same number of dives to 100 feet. The curves show three interesting

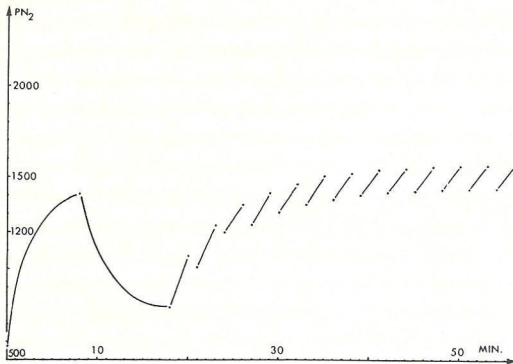


Figure 1. Nitrogen Tensions in Five-Minute Tissues During Repeated Dives. After eight minutes in a pressure chamber at 3 at. abs. followed by a ten minute surface interval which is then followed by 13 breath-hold dives to 61 feet. Each dive lasted two minutes with one minute surface time between each dive.

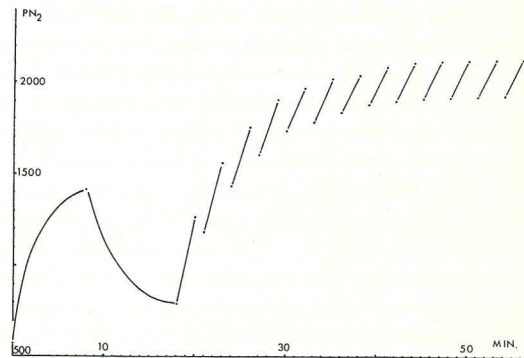


Figure 2. Nitrogen Tensions in Five-Minute Tissues by Repeated Diving. The same diving pattern as in Figure 1, except for the depth of breath-hold dives, which is here 100 feet.

phenomena: (1) the tissue nitrogen tensions increases to a considerable magnitude by repeated breath-hold dives; (2) after a number of dives a certain equilibrium level is reached and then the tissue PN_2 seems to be constant by a continuation of the diving pattern; and (3) this equilibrium level is below the maximum allowable tissue tensions by conventional diving.

In tissues with half-times of 10 to 120 minutes preliminary calculations have shown PN_2 's of about the same level as that of Figures 1 and 2, but after a greater number of dives. This needs further examination. Calculations by the most appreciated help of a computer are in accordance with the conclusions made here(9). Since the rate of ascent was very fast (1.5 to 1.8 meters per sec.) and involved exercise as compared to the passive, conventional ascent (.3 meters per sec), item 3 above, is perhaps not relevant for this type of diving. The rapid rate of ascent would also involve that blood nitrogenated in the lungs at the bottom would still be circulating peripherally when the surface was reached. Some bubble formation on this basis alone could be expected even in the first such dive, although it is not likely that such bubbles would become consequential except in reaching tissues already having a PN_2 sufficiently high to cause nascent bubbles to grow. The final PN_2 's in Figures 1 and 2 are perhaps high enough for this mechanism in the slower half-time tissues.

The N_2 accumulation in combination with the CO_2 retention is perhaps the detail explanation of the bubble formation. A carbon dioxide influence on bubble formation is possible and experimental evidence of CO_2 retention in addition to the N_2 accumulation is present(8). According to our determinations during real breath-hold dives in Norway of the differences in the gas content of the lungs before

and after a bottom drop of 40-60 seconds duration, the CO₂ retention is identical with the CO₂ production during a dive minus about 50 ccs. From Lanphier's and Rahn's data the same amount during a simulated breath-hold dive can be calculated. The amount of N₂ disappearing into the tissues during a seven dive series was on the order of 500 to 800 ccs in our three subjects. Now to the question of the speed with which this enormous amount of CO₂ in N₂ is eliminated after the ascent. With regard to the N₂ this is difficult to evaluate. With regard to the CO₂, Schaefer's findings⁽⁷⁾ and ours⁽⁸⁾ are in accordance. The absorbed CO₂ is not released in great amounts within the first two minutes of the surface intervals. This makes it likely that a gradual accumulation of N₂ and CO₂ will occur during repetitive breath-hold dives to great depths.

The character of the neurological symptoms and signs, their progressive development after the diving, the above theoretical considerations as well as the prompt relief upon recompression makes it reasonable to assume that the case here reported was decompression sickness, as was concluded in a report to the Norwegian Naval Authorities⁽³⁾.

It thus appears that even during relatively short breath-hold dives here described it is possible to produce decompression sickness, which so far has been described only in relation to conventional diving of longer duration.

Three cases of decompression sickness in Norwegian tank instructors were treated by O. Haavelsrud⁽⁴⁾, within one year before the case here reported. All have now totally recovered and are participating in diving experiments. One was a very tall diver with an enormous lung capacity for breath-hold diving. He experienced two episodes of severe decompression sickness. The dives took place in the same "free escape" tank and the same diving pattern was used as described above. These instructors performed a variable number of "bottom drops" before the sickness developed and in each case there was immediate relief by recompression. It is of interest to note that the three Norwegian tank instructors and the case here reported all had a certain degree of N₂ loading by breathing compressed air at 20 meters of depth, before the repeated breath-hold dives took place, and all were cases with severe neurological symptoms and signs. None of these cases displayed any signs of lung rupture.

Cross⁽⁵⁾, has reported a syndrome called "Taravana," of the skin diving pearl divers of the Tuamotu Archipelago in the South Pacific. These divers make 40 to 60 dives per day to depths of 100 feet (30 m) or more, spend an average of two minutes per dive under water, and three to four minutes at the surface. Mild cases of "Taravana" show no more than extreme dizziness or visual disturbances. In severe cases he observed unconsciousness, partial or complete paralysis of one or more extremities (permanent or temporary), and occasionally death. Cross explained his observations in terms of anoxia, and this, of course, is a very likely possibility in cases where only unconsciousness or death is registered. However, the diving pattern (repeated dives to great depths, with long "bottom times" and short "surface intervals") and the neurological character of the injuries reported, is similar to the diving pattern and signs in the case here described. Therefore it is reasonable to assume that "Taravana" is identical with decompression sickness.

On one of the islands, Mangareva, this "skin diving disease" ("Taravana") is not known. The only difference in the diving pattern is that the Mangareva-divers, obeying an old tradition, use "surface intervals" of at least ten minutes, during which time they practice mild hyperventilation. This coincidence of longer "surface intervals" and absence of "Taravana" is in accordance with the explanation of "Taravana" as decompression sickness. Longer "surface intervals" will not only permit a better nitrogen elimination, but also tend to reduce the number of dives per day.

In general, skin diving is performed as "exercise dives"⁽⁶⁾ ("head-first surface dives") in which the demand for oxygen limits the depth, the "bottom times" as well as the number of repeated dives and thereby the nitrogenation. This may explain why decompression sickness is so seldom met in skin diving. However, it should be borne in mind that under certain circumstances repeated skin dives can result in decompression sickness, in which case immediate recompression must be the adequate treatment.

Summary

A report is given of a case of decompression sickness after repeated skin dives to 50 to 66 feet (15 to 20 m). Three similar cases in Norwegian tank instructors are mentioned. All four cases were relieved promptly upon recompression.

A parallel is drawn between the Scandinavian cases of "skin diving disease" and the "pearl diver disease" (Taravana), found on the Tuamotu Archipelago in the South Pacific.

All observed symptoms and signs in these cases of "skin diving disease" may be explained as decompression sickness.

It is emphasized that in such cases immediate recompression is the treatment of choice.

REFERENCES

1. SUBMARINE MEDICINE PRACTICE. U.S. Government Printing Office. Washington, D.C., 1956.
2. U.S. NAVY DIVING MANUAL. Navy Department. Washington, D.C., 1958.
3. Haavelsrud, O. Report to the Norwegian Naval Authorities. Sjøforsvaret, Undervannsbaat-inspeksjonen, Bergen, Norge., 6 March 1964.
4. Haavelsrud, O. Reports to the Norwegian Naval Authorities. Sjøforsvaret, Undervannsbaat-inspeksjonen, Bergen, Norge., November 1963 and January 1964.
5. Cross, E. R. Advanced Skin and SCUBA Diving. p 33, 1961.
6. Olsen, C. R., D. D. Fanestil and P. F. Scholander. J. Appl. Physiol. 17(3): 461, 1962.
7. Schaefer, K. E. Proceedings of the Underwater Physiology Symposium. Nat'l Acad. Sci. - Nat'l Res. Council, Washington, D.C., Publ. 377, pp 131-139, Jan 1955.
8. Paulev, P. and N. Naeraa. Changes of Respiratory Gases in Repeated Breath-Hold Dives (unpublished).
9. Paulev, P. Nitrogen Tissue Tensions Following Repeated Breath-Hold Dives (unpublished).