

Five consecutive cases of sensorineural hearing loss associated with inner ear barotrauma due to diving, successfully treated with hyperbaric oxygen

David Smart¹

¹ Department of Diving and Hyperbaric Medicine, Royal Hobart Hospital, Hobart, Tasmania, Australia

Corresponding author: Clinical Professor David Smart, Department of Diving and Hyperbaric Medicine, Royal Hobart Hospital, Liverpool St, Hobart, Tasmania 7000, Australia

ORCID: [0000-0001-6769-2791](https://orcid.org/0000-0001-6769-2791)

dsmart@inet.net.au

Keywords

Barotrauma; Case reports; Cochlea; Hearing loss, sudden; Hyperbaric oxygen treatment; Inner ear

Abstract

(Smart D. Five consecutive cases of sensorineural hearing loss associated with inner ear barotrauma due to diving, successfully treated with hyperbaric oxygen. *Diving and Hyperbaric Medicine*. 2024 20 December;54(4):360–367. doi: [10.28920/dhm54.4.360-367](https://doi.org/10.28920/dhm54.4.360-367). PMID: [39675746](https://pubmed.ncbi.nlm.nih.gov/39675746/).)

Introduction: This report describes the outcomes of sensorineural hearing loss (SNHL) due to cochlear inner ear barotrauma (IEBt) in five divers treated with hyperbaric oxygen (HBOT).

Methods: The case histories of five consecutive divers presenting with SNHL from IEBt due to diving, were reviewed. All divers provided written consent for their data to be included in the study. All had reference pre-injury audiograms. All noted ear problems during or post-dive. Independent audiologists confirmed SNHL in all divers prior to HBOT, then assessed outcomes after HBOT.

Results: Three divers breathed compressed air on low risk dives, and two were breath-hold. None had symptoms or signs other than hearing loss, and none had vestibular symptoms. All could equalise their middle ears. Inner ear decompression sickness was considered unlikely for all cases. All were treated with HBOT 24 hours to 12 days after diving. Two divers received no steroid treatment, one was treated with HBOT after an unsuccessful 10-day course of steroids, and two divers received steroids two days after commencing HBOT. All divers responded positively to HBOT with substantial improvements in hearing across multiple frequencies and PTA4 measurements. Median improvement across all frequencies (for all divers) was 28 dB, and for PTA4 it was 38 dB.

Conclusions: This is the first case series describing use of HBOT for IEBt-induced SNHL. The variable treatment latency and use/timing of steroids affects data quality, but also reflects pragmatic reality, where steroids have minimal evidence of benefit for IEBt. HBOT may benefit diving related SNHL from IEBt with no evidence of perilymph fistula, and provided the divers can clear their ears effectively. A plausible mechanism is via correction of ischaemia within the cochlear apparatus. More study is required including data collection via national or international datasets, due to the rarity of IEBt.

Introduction

Inner ear barotrauma (IEBt) affecting divers is rare, but can result in significant morbidity, potentially ending the diver's career.¹ The exact incidence is unknown, but even in specialised centres it can take years to accrue large numbers of cases.^{2,3} The pathophysiology in divers is believed to be either explosive or implosive, or internal to the cochlea.⁴

For explosive injury, pressure during descent is transmitted to the tympanic membrane. In cadaveric studies, the tympanic membrane has been demonstrated to rupture at 97.7 kPa (nearly 1 atmosphere absolute [atm abs]) additional pressure.⁵ If the tympanic membrane doesn't rupture, the pressure is transmitted through the auditory ossicles to the oval window, which transmits a hydraulic pressure wave via perilymph to the round window, which may rupture.⁶

Explosive injury will be exacerbated (or precipitated) by forceful Valsalva against a locked Eustacian tube which raises perilymph fluid pressure, concurrently with negative pressure in the middle ear. For implosive injury, the mechanism is believed to be a sudden increase in middle ear pressure when a forceful Valsalva is successful in opening the Eustacian tube, and the tympanic membrane bulges outwards, distracting the auditory ossicles with it, leading to rapid lowering of perilymph pressure in association with a middle ear under positive pressure. This causes inward force on the round window breaching its integrity.

Despite emphasis in the literature about the round window as the injury point, the oval window can also be injured in a contra-coup way during pressure forces, however the ossicles may offer some protection. In addition, high energy pressure from blasts could cause injury to multiple structures in the

auditory chain. The round window has been observed to rupture in anaesthetised cats at mean pressures of 3.2 kPa (23.4 mmHg) above atmospheric, and in Norwegian cattle cadavers at greater than 202 kPa (2 atm).^{7,8} It is difficult to quantify the pressure leading to injury in humans, but these animal studies produced values which are consistent with the range of pressures encountered in diving. In addition to implosive and explosive forces, barotrauma can lead to injury within the sensitive cochlear apparatus. One study reported additional pressures of only 4.8 kPa (0.047 atm) were required to rupture Reissner's (basilar) membrane in cattle.⁸ Intracochlear injuries may occur simultaneously with window ruptures.² It is also possible that internal cochlear injuries occur in isolation without window injuries. Cochlear injuries may result from rupture of the basilar membrane (intracochlear membrane tear) which leads to admixture of peri- and endolymph (dissimilar fluids), inner ear haemorrhage within the cochlea or direct disruption of the organ of Corti. Mechanisms causing injury to the inner ear have been previously documented.^{6,9}

Diagnosis of IEBt is challenging, with the main differential diagnoses being inner ear decompression sickness (IEDCS) (especially if vestibular symptoms are present), or middle ear barotrauma (MEBt) if symptoms are restricted to hearing loss and tinnitus.^{6,9,10} Detailed clinical assessment including air conduction and bone conduction audiometry is required to differentiate cochlear IEBt from MEBt, the former demonstrating sensorineural hearing loss. Treatment options and recommendations for IEBt have been previously documented.^{6,9,10} There is limited advice available for how to treat IEBt when hearing loss is the sole injury; steroids are unproven for this condition, and surgical exploration has very limited supporting evidence of benefit for hearing loss.⁹⁻¹¹ The logic for applying HBOT for IEBt originated from accumulating evidence demonstrating benefit from HBOT as a combination treatment for acute idiopathic sudden sensorineural hearing loss.¹²⁻¹⁶ Despite this evidence, there is also a possibility that pressurisation and HBOT may worsen IEBt.

Outcome measurement using pure tone average across four frequencies: 500 Hz, 1,000 Hz, 2,000 Hz and 4,000 Hz (PTA4), was used for consistency in a meta-analysis of HBOT for idiopathic sudden sensorineural hearing loss.¹⁶ Although PTA4 forms only a small component of comprehensive hearing assessment, it does correlate with speech recognition.^{17,18} This report details outcomes for five IEBt cases treated with HBOT.

Methods

All divers provided written consent for their cases to be reported.

Five consecutive divers were assessed at the Department of Diving and Hyperbaric Medicine for hearing loss after diving, from October 2019 to May 2023. All divers had pre-injury audiograms for reference, and post-injury, all satisfied the definition used for idiopathic sudden sensorineural hearing loss which is 30 dB hearing loss across three frequencies.^{16,19} No diver had any other symptoms or signs. All divers had ear, nose and throat specialist consultation prior to referral to the hyperbaric facility. This specialist assessment included full history, clinical examination, and audiometry (with air conduction and bone conduction). The main criteria for exclusion of other possible diagnoses were clinical, taking into account dive type (freedives vs scuba dives), symptom onset relative to dive profile, dive profiles, lack of other risk factors for DCS, ear clearing problems, isolated (cochlear) symptoms, and absence of any other DCS symptoms. These criteria were identified as being useful to separate IEBt from IEDCS in a recent systematic review.²⁰

In addition to confirming sensorineural hearing loss, the process of excluding other diagnoses included neurological examination, and diving medicine specialist visual assessment of middle ear function (to ensure ease of ear clearing). The most likely diagnosis for all divers in this series was intracochlear IEBt ([Appendix 1*](#)).

Before proceeding to HBOT, all divers were provided with a detailed discussion about the experimental nature of using HBOT for their condition. This discussion was conducted with diving medicine specialists who had access to all of the diver's information. In particular, the divers were given the option of immediately aborting pressurisation if there were any ear clearing problems, or if they felt at any stage they did not want to continue with treatment. Divers also understood there was a possibility that HBOT could make their condition worse. The diving medicine specialists personally checked ear clearing capability for each diver (with observable movement of the tympanic membranes, by visual inspection during gentle active Valsalva manoeuvres. All divers provided written consent to receive HBOT.

All divers received courses of HBOT at 243 kPa (2.4 atm abs), after clinical assessment. Outcomes were assessed by comparing pre- and post-treatment audiometry using PTA4. In addition, the average loss across all nine standard audiogram frequencies 250–8,000 Hz compared to the non-injured ear was also assessed, and the number of frequencies with positive or negative change after intervention. Divers were followed up for a minimum of three months after receiving HBOT.

Results

[Appendix 1*](#) provides more detail about each diver's case history. All divers in this series were male: one scientific

* Appendix 1 can be found on the DHM Journal website: <https://www.dhmjournal.com/index.php/journals?id=347>

diver, two aquaculture divers, one hyperbaric professional and one recreational diver. Their ages ranged from 22–62 (median 51) years. All had pre-injury audiograms from either occupational diving medicals (≤ 12 months previously) or an occupational hearing assessment (the recreational diver). All divers had evidence of sensorineural hearing loss (across three or more frequencies) assessed by an independent audiologist prior to referral to the hyperbaric facility. Only one diver had imaging of their brain or internal auditory meati before receiving HBOT. For some divers, fistula tests were performed which were negative (see [Appendix 1*](#)). No diver had vestibular or neurological symptoms or signs, nor other symptoms except for their affected ear. No diver exhibited abnormal neurological signs when examined. All divers were able to clear their middle ears with gentle Valsalva manoeuvres, and were considered low risk of MEBt with chamber pressurisation. All divers successfully cleared their ears during HBOT and none sustained further symptoms or injury. The narratives for each case report are summarised in [Appendix 1*](#), and their audiograms summarised in tabular form in [Appendix 2*](#).

The details of the divers and outcomes of HBO treatment are summarised in Table 1. No diver had evidence of vestibular dysfunction. Audiometry in the last 12 months was normal for all divers with no significant difference between right and left ears except subject 3 in Table 1 who had pre-existing symmetrical significant (50 dB) hearing loss across 3–8 kHz. All divers had improved hearing following courses of HBOT ranging from 5–10 treatments at 243 kPa. Median improvement across all frequencies (for all divers) was 28 dB, and for PTA4 it was 38 dB. Three divers received steroids, two after two HBOT treatments and one for 10 days prior to HBOT (without benefit). Hearing improvements persisted to three months follow-up for all divers. Two divers had normal magnetic resonance imaging scans, one had a normal computed tomography scan of the petrous temporal bones and two had no imaging of the brain or auditory meati.

Discussion

The author has been unable to locate previous reports of the use of HBOT for IEBt with isolated hearing loss and believes that the evidence for IEBt as the most likely diagnosis in all cases is robust, except perhaps subject 4. Subject 4 had sensorineural hearing loss following a single low risk dive, but with no clear history of ear injury. Symptoms were confined to the ear but had onset some hours after diving. This creates a degree of uncertainty when using published diagnostic criteria.²⁰ If case 4 was IEDCS, it may have been isolated cochlear DCS which is very rare.^{20–22} All divers had symptoms localised to one ear including sensorineural hearing loss, confirmed by independent audiologists. Their injuries occurred during or were noted following diving. Divers 1 and 3 were solely shallow free diving, so IEDCS

was not a possibility. Diver 2 had a 5-minute exposure to pressure in two short, controlled bounces, making IEDCS unlikely. Diver 5 reported definite barotrauma injury restricted to one ear with no other symptoms on dives that were relatively low risk.

All diver histories were checked in detail (face to face interview) by the author either at the time they presented or during their HBOT and at follow-up. As far as can be reasonably ascertained by direct questioning, ear clearing difficulties were infrequent. Two divers (2 and 4, both commercial divers) denied they had any ear clearing difficulties. Diver 5 described an actual event of right ear injury (associated with a mild upper respiratory infection). The breath-hold divers 1 and 3 noted ear problems during or after their dives (diver 3 acknowledged an actual injury at 5 m). Diver 1 may not have been snorkelling deep enough (2.4 m) to notice pain, but the fact that he continued an underwater hockey tournament for a week indicates any equalisation problems were minor. It is known that divers may under-report their injuries, but only one diver reported an upper respiratory tract infection, either active or recent, which was unexpected.⁴ No diver in this series demonstrated signs of MEBt (acknowledging that three divers presented more than a week after injury). Absence of MEBt was noted in 38% of cases in one series,⁴ and not found to be a useful discriminator in another,²⁰ mainly due to insufficient reporting in IEDCS series.

A reported series of IEDCS cases showed it is rare for IEDCS to be solely localised to the cochlea (6% of cases), hence isolated hearing loss is more likely to favour IEBt as a diagnosis.²¹ An amalgamated review of four papers confirmed a low incidence of isolated cochlear DCS (5%), and a strong association of IEDCS with air divers from depths greater than 30 metres.²² In another series of IEDCS 28 cases, 10 subjects had hearing loss, all had symptoms of vertigo, postural instability and 9/10 had nystagmus. None had isolated hearing loss.²³

Using Rozycki et al's. HOOYAH criteria, all five cases presented in this report strongly favour cochlear IEBt and not IEDCS.⁶ No diver had vestibular symptoms making it unlikely that any had a perilymph fistula affecting either round or oval windows. No divers went greater than 18 m and two were breath-hold. In addition, their ability to pressurise inside the hyperbaric chamber made perilymph fistula unlikely.

Lindfors et al. recently reported a systematic review to identify criteria which would help differentiate IEBt from IEDCS.²⁰ The most useful variables were dive type (free diving versus scuba diving), dive gas (compressed air vs mixed gas), dive profile (mean depth 13 vs 43 metres of seawater), symptom onset (when descending vs when

* Appendices 1 and 2 can be found on the DHM Journal website: <https://www.dhmjournal.com/index.php/journals?id=347>

Table 1

Diver characteristics and audiometry results post injury and post treatment; * hearing loss was the average loss in dB for all eight or nine measured frequencies compared to the non-injured ear for each diver; HBOT – hyperbaric oxygen treatment; SNHL – sensorineural hearing loss; SSBA – surface supply breathing apparatus

Diver	Diver profile	Ear clearing issues before problem	Initial symptoms	Audiogram post-injury description	Number of frequencies affected	Hearing loss* post-injury (dB)	PTA4 loss post-injury (dB)	HBOT day started, (n HBOT), When steroids started	Hearing loss* post-HBOT (dB)	PTA4 loss post-HBOT (dB)	Improvement PTA4 post-HBOT (dB)	Number of frequencies improved
1	Snorkelling under-water hockey 2.4 m max depth	No	Tinnitus reduced hearing right ear	Down-sloping SNHL	7 out of 9	43	46	Day 8 (9xHBOT) Steroids day 10	8	4	43	9
2	Compressed air SSBA to 18 m for 5 minutes	No	Tinnitus hearing loss left ear	Flat moderate to severe SNHL	8 out of 8	68	75	Day 0 (10xHBOT) Steroids day 2	21	23	53	8
3	Snorkelling < 5 m	Yes	Difficulty clearing and pain in right ear	Flat moderate to severe SNHL	5 out of 9 4 were pre-existing	29	65	Day 14 (10xHBOT) Steroids 10 days prior, no benefit	1	28	3	5
4	Compressed air SSBA to 15 m well inside table limits	No	Reduced hearing	Upsloping SNHL	8 out of 9	31	39	Day 7 (10xHBOT) No Steroids	6	10	29	8
5	Compressed air scuba to maximum 16 m well inside table limits	Yes	Pain right ear reduced hearing, tinnitus 24 h later	Down-sloping mild SNHL	7 out of 9	24	39	Day 12 (5xHBOT) No Steroids	8	25	14	6

ascending or surfacing), distribution of cochleovestibular symptoms (vestibular versus cochlear) and absence or presence of other DCS symptoms. Symptoms of difficult middle ear equalisation or IEBt were not reliable due to insufficient reporting in the IEDCS series.²⁰ Even with useful criteria, differentiation of IEBt vs IEDCS still frequently devolves to a balance of probabilities because there is considerable overlap in the symptom complexes of each condition.

On that basis, a question is raised: what is the pathophysiology of IEBt with sensorineural hearing loss, and how may HBOT have produced therapeutic benefit? It is acknowledged that recovery in all cases may have been spontaneous, and the temporal relationship of HBOT just a coincidence. An understanding of cochlear anatomy is useful to identify potential therapeutic mechanisms.

A basic depiction of ear anatomy is shown in Figure 1.²⁴ Figures 2 and 3 shows more detailed images of cochlea cross-sectional anatomy.^{25,26} Figure 4 shows detail of the vascular supply to the vestibulocochlear apparatus.²⁷ The cochlear arteries and arterioles must travel inside the bone surrounding the cochlea (a relatively closed system). Supply of oxygen to the organ of corti is via the modiolar artery which provides arteriolar supply to the organ itself, the spiral ganglion, but mostly via the stria vascularis, allowing diffusion of oxygen to the organ of corti via the cochlear duct (scala media). There is some variability between species.²⁸ The cochlea is acutely sensitive to ischaemia, which may result from reductions in blood flow. It has been demonstrated in pigs that raised labyrinthine pressures cause reductions in blood flow which were reversed when the round window ruptured.²⁹

It is conceivable that during IEBt, injuries less severe than the threshold for round window rupture could lead to localised swelling and raised perilymph hydrostatic pressures which

in turn reduce the blood flow via the labyrinthine artery to the organ of corti, and induce hearing loss. This mechanism may precede basilar membrane rupture (in severity), and also precede rupture of the round window.

Given that all subjects in this report had demonstrable improvements in hearing after HBOT, it suggests that the IEBt was a reversible, non-structural injury. If any subject had physical injury to the round window, then it may have been minor, without perilymph extrusion or vestibular symptoms – a subclinical injury without fistula development. This has been suggested by Duplessis’s group who investigated otoacoustic emissions testing in IEBt, and demonstrated abnormalities in divers undertaking multiple repetitive dives. Transient emission shifts were demonstrated more frequently with otoacoustic emissions testing than audiometry, suggesting potential for subclinical injury as a potential cause of sensorineural hearing loss.³⁰

It is possible that IEBt actually spans a spectrum ranging from subclinical injury of the cochlear apparatus through to overt round or oval window ruptures. Less severe injury may precipitate local injury and oedema surrounding the window and/or focal intracochlear membrane injury. Isolated basilar membrane tears or intracochlear haemorrhage may cause hearing loss across multiple frequencies that is potentially less reversible.^{9,10} A final unlikely mechanism for IEBt could be a small pneumolabyrinth, from middle ear gas entering the perilymph, rather than outward fluid leakage with a round window rupture.³¹ Air could potentially enter the labyrinth with an implosive injury, rather than fluid extravasating. If this was proven to be the primary mechanism by which IEBt causes sensorineural hearing loss, then use of HBOT for the condition would not be regarded as controversial – it would be to shrink gas bubbles. Of the possible mechanisms causing reversible sensorineural hearing loss from IEBt, it is this author’s belief that the injury/inflammation/oedema/vascular ischaemia pathophysiology is most plausible.

Figure 1

Cross section of ear anatomy including the inner ear and cochlea

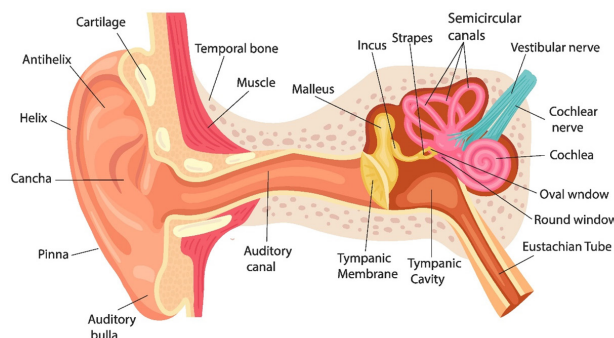


Figure 2

Cross section of one spiral of the cochlea

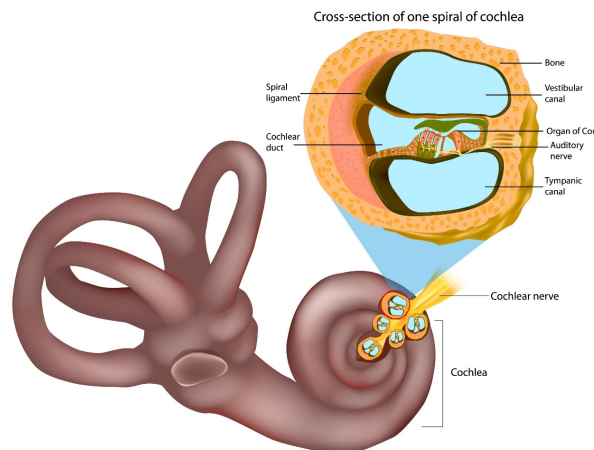


Figure 3

Detailed anatomy of the organ of Corti

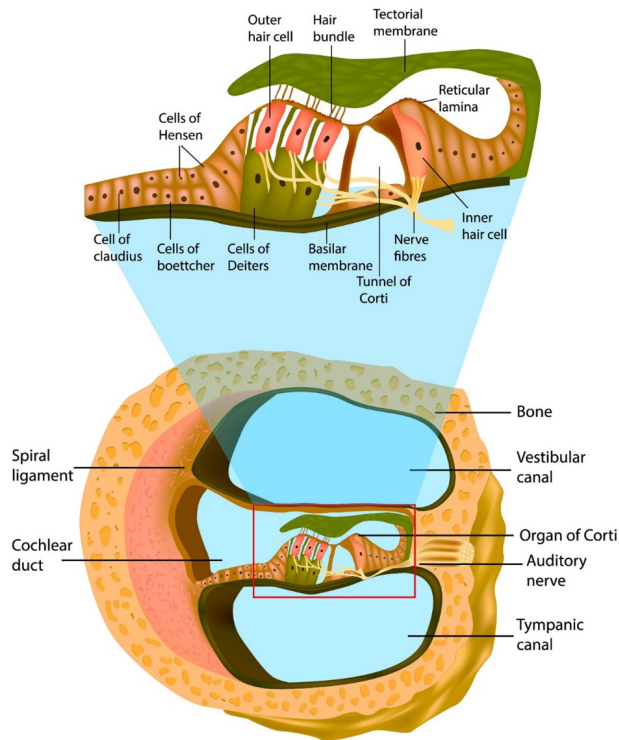
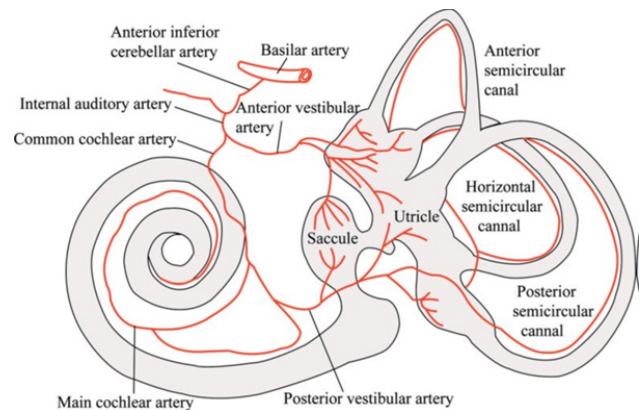
**Figure 4**

Diagram of the blood supply to the inner ear



hearing loss over control treatments.¹⁶ Hyperbaric oxygen is now included as an option in ear nose and throat clinical practice guidelines.³⁶ In a recent retrospective series as a primary treatment, HBOT (without steroids) was effective in improving hearing in patients with idiopathic hearing loss.³⁷ The proposed mechanism of benefit of HBOT is via higher partial pressures of oxygen resulting in greater intracochlear oxygen tensions, in particular within the perilymph and endolymph, and reduction of inflammation and oedema.^{34,35,37} It raises oxygen partial pressures and dissolved oxygen in plasma which correct cellular hypoxia through diffusion into ischaemic regions. In addition, HBOT has been demonstrated to reduce oedema via vasoconstriction and the osmotic effect of dissolved oxygen in plasma. It also reduces reperfusion injury.³⁸ These effects may explain why HBOT is effective for idiopathic sudden sensorineural hearing loss, and why the IEBt cases in this series responded. Reduction of oedema and restoration of oxygenation to an injured cochlear basilar membrane may also have beneficial effects. Further research is required to elucidate the pathophysiology of IEBt.

LIMITATIONS

This series had highly specific entry criteria, which are not frequently encountered: isolated sensorineural hearing loss from IEBt following diving. It is acknowledged that the diagnosis of IEBt (rather than IEDCS) has been made on the balance of probability for the cases, however low risk dives, breath hold dives and absence of any other symptoms makes IEDCS unlikely. It is also acknowledged there are potential confounders to the claim of efficacy of HBOT in these cases. The response to HBOT may have been coincidental, and the divers may have made spontaneous recoveries. The time-periods of unabated hearing loss (for divers 1, 3, 4 and 5), and the direct temporal relationship between HBOT and improved hearing lowers probability of such coincidence. Diver 2's response to HBOT the day after injury was particularly convincing. It is unlikely that steroids were a factor in recovery for these divers. Cases 1 and 2 had improvements in hearing before steroids were

The five divers in this series had flat or down sloping audiograms (highest frequencies worst), consistent with other reports.³² The anatomical proximity of the round window to the cochlear vascular supply and organ of Corti may be a factor in how IEBt affects hearing.²⁷ The base of the cochlea is located close to the round window, where the highest sound frequencies are detected. The arterial supply to both vestibule and cochlea is in close proximity.^{27,33} There is a propensity for IEBt to have greater negative effect on higher frequencies.^{6,32} The proximity of the structures (including venous drainage of the cochlea) provides some plausibility for a proposal of non-rupturing injury to the round window.^{27,33} This could lead to oedema and raised perilymph/endolymph pressure causing ischaemia, as a pathophysiological mechanism of hearing loss.

There may be some potential parallels between idiopathic sudden sensorineural hearing loss and IEBt. There are multiple mechanistic theories for causation of idiopathic sudden sensorineural hearing loss. The vascular hypothesis proposes that ischaemia to the cochlear apparatus, cochlear nerve and other central auditory components is the cause of hearing loss.^{34,35}

The use of HBOT for idiopathic sudden sensorineural hearing loss has been investigated extensively in recent years. A metaanalysis concluded: HBOT as part of a combination treatment (with steroids) was significantly associated with improved hearing outcomes in patients with sensorineural

administered (which followed their second HBOT). Case 3 was referred for HBOT after 10 days of steroid use had no effect on hearing, and cases 4 and 5 received no steroids. Hence steroids may have affected the outcomes in only 2/5 cases. The use of steroids for IEBt remains controversial, and has limited high-level supporting evidence.^{9,11}

Conclusions

Hyperbaric oxygen may benefit sensorineural hearing loss from diving related IEBt which has no evidence of perilymph fistula, and provided the divers can clear their ears effectively for pressurisation. A plausible mechanism is via correction of ischaemia within the cochlear apparatus. More study is required in this field, including data collection via national or international datasets, due to the rarity of IEBt. The selection criteria used with these cases may provide guidance for future research.

References

- Goplen FK, Aasen T, Grønning M, Molvær OI, Nordahl SH. Hearing loss in divers: a 6-year prospective study. *Eur Arch Otorhinolaryngol*. 2011;268:979–85. PMID: 21246211.
- Shupak A, Gil A, Nachum Z, Miller S, Gordon CR, Tal D. Inner ear decompression sickness and inner ear barotrauma in recreational divers: a long-term follow-up. *Laryngoscope*. 2003;113:2141–7. doi: 10.1097/00005537-200312000-00017. PMID: 14660917.
- Edmonds C. Inner ear barotrauma: a retrospective clinical series of 50 cases. *SPUMS Journal*. 2004;34:11–14. [cited 2024 Jul 20]. Available from: https://dhmjournal.com/images/IndividArticles/34March/Edmonds_dhm.34.1.11-14.pdf.
- Simmons FB. The double-membrane break syndrome in sudden hearing loss. *Laryngoscope*. 1979;89:59–66. doi: 10.1288/00005537-197901000-00006. PMID: 423653.
- Talas DÜ, Beger O, Çömelekoglu Ü, Çakir S, Taghipour P, Vayisoglu Y. An insight to tympanic membrane perforation pressure through morphometry: a cadaver study. *Diving Hyperb Med*. 2021;51:10–7. doi: 10.28920/dhm51.1.10-17. PMID: 33761536. PMID: 33761536. PMID: 33761536.
- Rozycki SW, Brown MJ, Camacho M. Inner ear barotrauma in divers: an evidence-based tool for evaluation and treatment. *Diving Hyperb Med*. 2018;48:186–93. doi: 10.28920/dhm48.3.186-193. PMID: 30199891. PMID: 30199891. PMID: 30199891.
- Miriszlai E, Sándor P. Investigations on the critical perilymphatic pressure value causing round window membrane rupture in anesthetized cats. *Acta Otolaryngol*. 1980;89(3-4):323–9. doi: 10.3109/00016488009127144. PMID: 7395501.
- Kringlebotn M. Rupture pressures of membranes in the ear. *Ann Otol Rhinol Laryngol*. 2000;109(10 Pt 1):940–4. doi: 10.1177/000348940010901007. PMID: 11051434.
- Elliott EJ, Smart DR. The assessment and management of inner ear barotrauma in divers and recommendations for returning to diving. *Diving Hyperb Med*. 2014;44(4):208–22. PMID: 25596834.
- Livingstone DM, Smith KA, Lange B. Scuba diving and otology: a systematic review with recommendations on diagnosis, treatment and post-operative care. *Diving Hyperb Med*. 2017;47:97–109. doi: 10.28920/dhm47.2.97-109. PMID: 28641322. PMID: 28641322. PMID: 28641322.
- Wei BP, Stathopoulos D, O’Leary S. Steroids for idiopathic sudden sensorineural hearing loss. *Cochrane Database Syst Rev*. 2013;2013(7):CD003998. doi: 10.1002/14651858.CD003998.pub3. PMID: 23818120. PMID: 23818120. PMID: 23818120.
- Khater A, El-Anwar MW, Nofal AA, Elbahrawy AT. Sudden sensorineural hearing loss: comparative study of different treatment modalities. *Int Arch Otorhinolaryngol*. 2018;22:245–9. doi: 10.1055/s-0037-1605376. PMID: 29983762. PMID: 29983762. PMID: 29983762.
- Cho I, Lee HM, Choi SW, Kong SK, Lee IW, Goh EK, et al. Comparison of two different treatment protocols using systemic and intratympanic steroids with and without hyperbaric oxygen therapy in patients with severe to profound idiopathic sudden sensorineural hearing loss: a randomized controlled trial. *Audiol Neurootol*. 2018;23:199–207. doi: 10.1159/000493558. PMID: 30380530.
- Krajcovicova Z, Melus V, Zigo R, Matisáková I, Vecera J, Kaslíková K. Efficacy of hyperbaric oxygen therapy as a supplementary therapy of sudden sensorineural hearing loss in the Slovak Republic. *Undersea Hyperb Med*. 2018;45:363–70. PMID: 30028922.
- Rhee TM, Hwang D, Lee JS, Park J, Lee JM. Addition of hyperbaric oxygen therapy vs medical therapy alone for idiopathic sudden sensorineural hearing loss: a systematic review and meta-analysis. *JAMA Otolaryngol Head Neck Surg*. 2018;144:1153–61. doi: 10.1001/jamaoto.2018.2133. PMID: 30267033. PMID: 30267033. PMID: 30267033.
- Joshua TG, Ayub A, Wijesinghe P, Nunez DA. Hyperbaric oxygen therapy for patients with sudden sensorineural hearing loss: a systematic review and meta-analysis. *JAMA Otolaryngol Head Neck Surg*. 2022;148:5–11. doi: 10.1001/jamaoto.2021.2685. PMID: 34709348. PMID: 34709348. PMID: 34709348.
- Hill-Feltham PR, Johansson ML, Hodgetts WE, Ostevik AV, McKinnon BJ, Monksfield P, et al. Hearing outcome measures for conductive and mixed hearing loss treatment in adults: a scoping review. *Int J Audiol*. 2021;60:239–45. doi: 10.1080/14992027.2020.1820087. PMID: 32985284.
- Ristovska L, Jachova Z, Kovacevic J, Radovanovic V, Hasanbegovic H. Correlation between pure tone thresholds and speech thresholds. *Journal Human Research in Rehabilitation*. 2021;11:120–5. doi: 10.21554/hrr.092108.
- Murphy-Lavoie H, Piper S, Moon RE, Legros T. Hyperbaric oxygen therapy for idiopathic sudden sensorineural hearing loss. *Undersea Hyperb Med*. 2012;39:777–92. PMID: 22670557.
- Lindfors OH, Räisänen-Sokolowski AK, Hirvonen TP, Sinkkonen ST. Inner ear barotrauma and inner ear decompression sickness: a systematic review on differential diagnostics. *Diving Hyperb Med*. 2021;51:328–37. doi: 10.28920/dhm51.4.328-337. PMID: 34897597. PMID: 34897597. PMID: 34897597.
- Gemppe E, Louge P. Inner ear decompression sickness in scuba divers: a review of 115 cases. *Eur Arch Otorhinolaryngol*. 2013;270:1831–7. doi: 10.1007/s00405-012-2233-y. PMID: 23100085.
- Mitchell SJ, Doolette DJ. Pathophysiology of inner ear decompression sickness: potential role of the persistent foramen ovale. *Diving Hyperb Med*. 2015;45:105–10. PMID: 26165533. [cited 2024 Jul 20]. Available from: https://dhmjournal.com/images/IndividArticles/45June/Mitchell_dhm.45.2.105-110.pdf.
- Smerz R. A descriptive epidemiological analysis of isolated inner ear decompression illness in recreational divers in

