

Barotrauma of the ear and paranasal sinuses

Barotrauma uha i paranazalnih šupljina

Dražen Shejbal, Tajana Gudlin Šbull, Davor Vagić*

Summary

With the increasing popularity of amateur scuba diving and the availability of commercial airplane flights, otorhinolaryngologists will increasingly encounter patients suffering from the effects of barotrauma. Barotrauma occurs according to the principles of Boyle's law, more precisely, due to the inability to equalize pressures within the body cavities. The pathophysiology of barotrauma of the ear and paranasal cavities is reviewed, as well as therapeutic options for prevention and treatment.

Key words: barotrauma, ear, paranasal sinuses

Sažetak

Porastom popularnosti amaterskog ronjenja i dostupnošću komercijalnih avionskih letova, otorinolaringolozi će se sve više susretati s bolesnicima koji boluju od posljedica barotraume. Barotrauma nastaje po principima Boyleovog zakona, preciznije, zbog nemogućnosti izjednačavanja tlakova unutar tjelesnih šupljina.

Prikazana je patofiziologija barotraume uha i paranazalnih šupljina, te terapijske opcije prevencije i liječenja.

Ključne riječi: barotrauma, uho, paranazalni sinusi

Med Jad 2023;53(4):257-262

Introduction

Barotrauma is any tissue damage caused by the pressure difference between the environment and the body cavities.

Pathology of barotrauma in otorhinolaryngology used to be related to the narrow field of military and occupational medicine. The widespread popularity of amateur scuba diving, the commercial accessibility of airplane flights, and the increasing amount of indications for hyperbaric chamber treatment, have increased the incidence of paranasal sinuses and ear injuries. Modern otorhinolaryngology is not only focused on the treatment and prevention of

barotrauma, but also tries to make amateur scuba diving and commercial flying accessible to individuals with, until recently, absolute contraindications for these activities.

Pathophysiology

The occurrence of barotrauma takes place according to the principles of Boyle's law; the volume of gas changes depending on the pressure if temperature is held constant. The air pressure at sea level is 101.3 kPa, and is altered by diving or take-off. If a balloon with a volume of 1 liter is brought to the surface from a depth of 10 meters, its volume will

*Poliklinika Sveti Nikola, Varaždin (Tajana Gudlin Šbull, dr.med.); KBC Sestre milosrdnice, Klinika za otorinolaringologiju i kirurgiju glave i vrata (prof.dr.sc. Davor Vagić, dr.med.); Opća bolnica Varaždin, Odjel za otorinolaringologiju (prim.dr.sc. Dražen Shejbal, dr.med.)

Corresponding address/Adresa za dopisivanje: Dražen Shejbal, Opća bolnica Varaždin, Odjel za otorinolaringologiju, Ivana Meštrovića 1, 42 000 Varaždin E-mail: dr.azen@vip.hr

Received/Primljeno 2023-04-11; Revised/Ispravljeno 2023-11-18; Accepted/Prihvaćeno 2023-11-20

increase to 2 liters, and in order to increase its volume by another liter, it would have to be raised to a height of approximately 5,500 meters. From the example above it is clear that barotrauma occurs more easily when diving, or precisely, each dive is accompanied by a smaller or larger barotrauma.¹

Barotrauma of the outer ear

The outer ear is normally exposed to the outside atmosphere and pressure. Damage occurs if there is an obstruction of the external auditory canal, in this case the equalization of external pressure and pressure behind the obstruction is not possible. The cause of the obstruction may be cerumen, stenosis, atresia, exostoses, foreign bodies, inserts, cotton wool and the like. When diving, a pressure difference of 150 mmHg is critical.^{2,3}

Clinical features

The leading symptoms are pain and pressure in the ear. When atresia is unilateral, dizziness can occur due to caloric stimulation, especially if the lateral semicircular canal is placed in a vertical plane. Various degrees of damage to the eardrum, petechial hemorrhages, bulla, and edema of the auditory canal are seen with the otoscope.³

Treatment

Cleaning of the external auditory canal and treatment of the eardrum injury.

Prevention

Prohibition of diving and flying for individuals with the obstruction of the external auditory canal, inserts for the auditory canal, unless they have a special one-way valvula, must be removed.^{2,3}

Barotrauma of the middle ear

The Eustachian tube is an anatomical structure and when it is open it keeps the pressure in the middle ear constant. During diving out or taking-off, its task is to equalize the increased pressure in the middle ear with the smaller atmospheric pressure.

The pressure gradient is from the ear to the pharynx, and the pressure equalization is generally carried out successfully because the tube is physiologically more adapted to this task (Figure 1).

On landing or immersion, when the pressure in the nasopharynx is higher than the pressure in the middle ear, the mouth of the tube protrudes like a beak into

the nasopharynx and becomes strangled by the increased nasopharynx pressure, which can result in middle ear barotrauma (Figure 2).

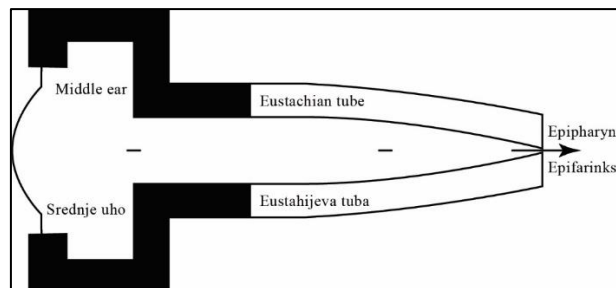


Figure 1 Drawing of the pressure gradient through Eustachian tube during take-off (modified according to Šercer)

Slika 1. Prikaz gradijenta tlaka Eustahijeve tube prilikom uzlijetanja (modificirano prema Šerceru)

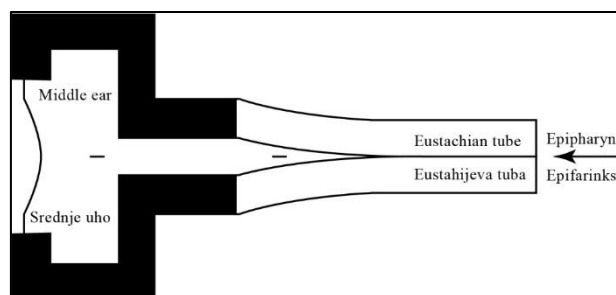


Figure 2 Drawing of the pressure gradient through Eustachian tube during landing (modified according to Šercer)

Slika 2. Prikaz Eustahijeve tube prilikom slijetanja (modificirano prema Šerceru)

In this case barotrauma occurs due to the *ex vacuo* phenomenon in the middle ear, more precisely, the pressure in the middle ear is lower than the pressure in the surrounding structures, and the walls of the middle ear tend to get closer in order to reduce the volume of the middle ear. Negative pressure in the middle ear draws fluid from the middle ear, and the damage to the structures can go as far as the rupture of the blood vessels and mucous membrane of the middle ear.⁴ Factors that potentiate the closure of the tube may be congenital, anatomical, or acquired such as inflammatory edema, vegetation, or tumors.⁵

The next important factor in the flow of air and pressure through the middle ear is the mastoid. The volume of the middle ear is about 2 cm³, and the size of the mastoid is on average 12 cm², with variations from 3 to 25 cm². In commercial flights, despite the design efforts to keep the pressure inside the aircraft cabin constant, the pressure changes by 20% in the half hour of the aircraft landing. The normal air flow through the middle ear during this time at sea level

would be 10 mL. For the ear with a small mastoid it increases to 200 mL during landing, and for the ear with a medium mastoid to 2000 mL, which is an increase of 20 to 200 times. Loads when diving at depths over 10 meters are even greater. From the above follows that the barotrauma from the anatomical point of view is potentiated by the dysfunction of the Eustachian tube and the size of the mastoid because the mastoid "produces volume" that the Eustachian tube must transport.⁶

Interestingly, provided studies on mastoid volume have opened discussions about established otological dogma: frequent ear infections lead to chronic ear infection, thereby reducing mastoid volume. However, recent research has shown that a congenitally small mastoid during life creates chronic ear infection and related conditions (secretory otitis media syndrome, atelectasis, retraction pocket, cholesteatoma). Simply put, the middle ear, like its "big brother", that is, the lungs, has a system of baroreceptors and stretch receptors that hold the air flow in the mastoid within physiological limits. A small mastoid also means underdeveloped physiological mechanisms, leading to the simple conclusion: a well-pneumatized mastoid will never be associated with a chronically ill ear. On the other hand, a chronically ill ear will have a small mastoid and thus will not be burdened with volume traffic, so in a chronically ill ear (secretory otitis media syndrome, atelectasis, retraction pocket, cholesteatoma) there is no contraindication for airplane flight.^{6,7}

In children up to puberty, barotrauma is extremely rare, especially on commercial flights. The reasons are not quite clear, but the three most plausible explanations are: first, by the onset of discomfort in the ear, children become restless and cry, thereby probably equalizing the pressure in the middle ear (by opening the tube)⁷, second, they have a relatively smaller mastoid, which makes the load on the ear due to pressure changes lesser⁶, and third, the Ostmann's pad of fatty tissue, located along the pharyngeal mouth of the tube, develops with aging, and its relative deficiency in children makes the epipharyngeal mouth larger.⁸

Negative pressure, that is, an *ex vacuo* phenomenon, can damage any structure of the middle ear. Most often it occurs when landing an aircraft or during immersion. The eardrum retracts medially which can result in hemorrhage or rupture. By transudation from the mucous membrane, the ear can fill with the fluid, the end result being bursting of blood vessels and hematotympanum. Due to compaction forces auditory ossicles can dislocate, the dislocation of the stapes is particularly dangerous,

and the very transfer of force to the labyrinth can damage the structures of the inner ear, which will be discussed later.^{2,3}

Clinical features

A pressure difference of 90 mm Hg will strangled the pharyngeal mouth of the tube, and this is the limit when an increased risk of the serious damage to the eardrum occurs, especially in the ear with impaired ventilation mechanisms. It should be emphasized that such a pressure difference occurs when diving at a depth of 1.40 m of water!

Symptoms are pain, discomfort, crackling in the ear, sometimes accompanied by dizziness, murmuring, disturbances or hearing loss.

The damage to the eardrum is divided into 6 degrees. 0 - any symptom with a normal eardrum, 1 - injected eardrum, 2 - injected eardrum with areas of hemorrhage, 3 - hemorrhagic eardrum, 4 - hematotympanum, 5 - ruptured eardrum.²

Treatment

Treatment is symptomatic, including cleansing of the external auditory canal. Antibiotics are not given routinely, but only if the incident happened in contaminated water.

Return to diving or flying needs to be individually evaluated based on the appearance of the eardrum, pneumatic otoscopy and audiometry.⁹

Prevention

Individuals with a cold should take nasal decongestants before flight or postpone the flight. If the risk of barotrauma is high due to a positive medical history or an acute respiratory infection, especially with a large mastoid, a preventive myringotomy or insertion of ventilation tubes should be performed.¹⁰ There are silicone inserts with a ceramic valvula which, when placed in the external auditory canal, equalize the pressure in people with an insufficient Eustachian tube function and thus protect the eardrum from damage.

When diving, pressure equalization can be performed by several techniques, with an important note: Valsalva maneuver can cause serious damage to the inner ear. Other methods are Frenzel maneuver, Toynbee maneuver, Lowry technique and Edmonds technique. The most successful but most difficult technique to train is Voluntary Tubal Opening (Beance Tubaire Volontaire, BTV). About 50 percent of divers can successfully master this technique. For divers with poorly ventilated ear, a slow immersion is

required, using one of the recommended maneuvers for each breathing cycle, up to a depth of about 6 meters, and then diving head-first towards the bottom. Similar to the aforementioned commercial flight aid, an insert for the external auditory canal of divers was developed.

Patients with perforation of the eardrum, inserted ventilation tubes, a condition behind the mastoidectomy, are forbidden to dive without specially designed diving masks that leave the ear dry; otherwise the risk of caloric stimulation and infection is unacceptable.

It is important to emphasize that the ear inserts in the external auditory canal prevent the barotrauma of the middle ear, but not of the outer ear, therefore they are acceptable for shallow water immersions.^{5,9}

Individuals who had undergone stapedectomy or ossicular reconstructions do not have an increased risk of damage to the inner ear when diving, to the extent it has been understood so far, but they dive at their own risk. It is necessary to assess whether sudden changes in body position represent a risk for newly established architectonics of ossicles and implants, and the risk of a liquor fistula in the stapes area is extremely difficult to assess. If diving, immersion to the greater depths is not recommended.^{10,11}

One historical interesting thing: during the Second World War, Luftwaffe pilots were periodically subjected to a preventive myringotomy, and shortly after the war, nasopharynx of the Allied pilots was irradiated so that post-radiation scarring would make the tube constantly open.¹²

Barotrauma of the inner ear

The ossicular chain transfers energy generated by the pressure changes in the middle ear to the inner ear. Hemorrhage, labyrinthine membrane rupture, ischemic damage by restriction in blood supply to a spiralis modioli, and perilymphatic fistulas by a round or oval window rupture may occur. The mechanism of fistula formation has been proven on an animal model, and can be explosive and implosive. The explosive mechanism ruptures the round window membrane if a diver performs a Valsalva maneuver, without successful opening of the Eustachian tube at the same time. Increased pressure of the cerebrospinal fluid is transmitted to the cochlea via the cochlear aqueduct and the internal auditory canal, and it ruptures, by explosion toward the middle ear, through the Scarpa's membrane (Figure 3).^{13,14}

The implosion also occurs during the Valsalva maneuver, if the Eustachian tube abruptly opens. The pressure in the middle ear is then increased by

approximately 250 mmHg and it moves the stapes plate, which until then was imprinted by an ex vacuo mechanism toward the inner ear, in its normal position. This produces an implosion wave that can dislocate the stapes or rupture the Scarpa's membrane by implosion, or more simplified, toward the inner ear (Figure 4).^{15,16}

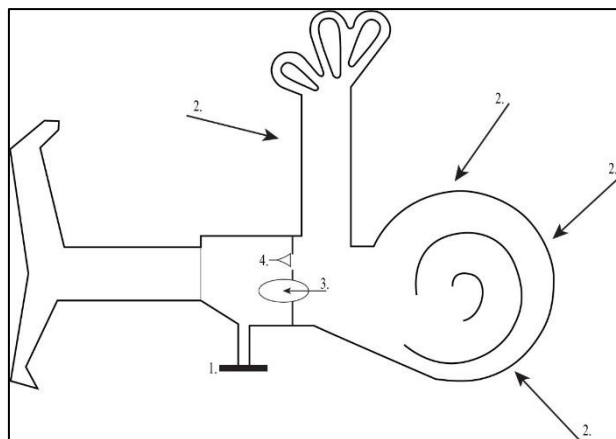


Figure 3 Explosive mechanism of the inner ear injury. 1. Eustachian tube is blocked, shown with thick line. 2. thick arrows show an increased pressure of a cerebrospinal fluid. 3. the encircled thin arrow shows an explosive rupture of the Scarpa's membrane. 4. stapes
 Slika 3. Eksplozivni mehanizam ozljede uha. 1. debela crta prikazuje blokiranu Eustahijevu tubu. 2. debele strelice prikazuju povećani tlak cerebrospinalne tekućine. 3. zaokružena tanka strelica prikazuje eksplozivnu rupturu membrane Scarpe. 4. stapes.

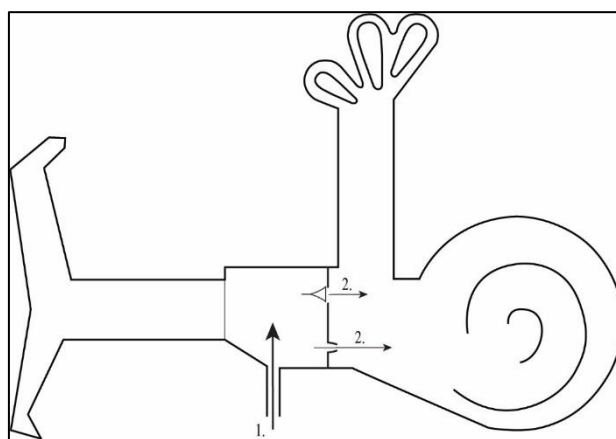


Figure 4 Implosive mechanism of inner ear damage caused by abrupt opening of the tube. 1. vertical arrow: tube opening. 2. horizontal arrows show pressure forces between middle and inner ear mediated by Scarpa's and stapes.

Slika 4. Implozivni mehanizam ozljede unutarnjeg uha uzrokovan iznenadnim otvaranjem Eustahijeve tube. 1. uspravna strelica prikazuje otvorenu tubu 2. vodoravne

strellice prikazuju sile tlaka između srednjeg uha i unutrašnjeg uha, preko membrane Scarpe i stapesa.

Clinical features

Hearing loss, tinnitus and dizziness are the leading symptoms. Hearing loss is sensorineural, and if the eardrum or middle ear structures are also damaged, the hearing impairment is mixed. Nystagmus may also occur.

If a window rupture occurs, the labyrinthine fistula test is positive in about 30% of cases, a Hennebert's sign may occur, and a reasonable suspicion is raised if hearing fluctuates, with a sudden onset of dizziness, nausea or vomiting.^{14,16}

Treatment

Damages to the ear without a window rupture are treated in hospital with bed rest and corticosteroids. Corticosteroids should not be given for more than two weeks, with a gradual decrease in dosage when most mild and moderate hearing impairments are satisfactorily recovering. Severe damages take 6 to 7 weeks to recover, while complete recovery occurs in 50% of patients.^{17,18} If labyrinthine fistula is suspected, patients must be hospitalized, with strict bed rest and with the head inclined by 30 to 40 degrees, 7 to 10 days, with sedation if necessary. Heavy physical activity is not recommended for 4 weeks after release from hospital. Nose blowing is forbidden, and the patient must sneeze through open mouth. To minimize the Valsalva effect and the pressure increase of the cerebrospinal fluid, the use of laxatives is recommended as well. If the signs of liquor fistula persist, the ear must be surgically explored.^{14,19}

Paparella proved on an animal model that complete healing of the Scarpa's membrane occurs in 90% of cases for a maximum of 9 days.¹⁶ Surgical exploration performed too early risks the surgeon's entry into the non-transparent operative field caused by exudate, edema, and bleeding due to barotrauma. After identification of the round window, the patient should be placed in Trendelenburg position, an anesthesiologist insufflates the lungs for 30 seconds, and the surgeon inspects the eventual appearance of cerebrospinal fluid. The area around the stapes is also inspected. The fistula closes with a fibroadipose autologous tissue piece after careful cleaning of the surrounding from adhesions and mucosa.^{14,19}

Barotrauma of the paranasal sinuses

Barotrauma of the paranasal sinuses occurs if their mouths are impenetrable. They are most commonly

injured when diving, or landing, when negative pressure is maintained inside the sinus. Obstruction occurs due to anatomical anomalies, polyps, inflammatory edema of the mucosa, or a deformed nasal septum.^{2,3}

Clinical features

The most common symptom is pain in the frontal sinuses, then in the ethmoid, and maxillary sinuses. The next symptom by frequency is epistaxis, which is generally neither serious nor long lasting. Cases of blindness, pneumocephalus, trigeminal nerve injury, and meningitis have been sporadically reported as a consequence of barotrauma of the sinuses.¹

The diagnosis is made on the basis of clinical features and a radiograph. Sinus mucosal edema mimics cystic formation. The aeroliquid level can also be seen. Interestingly, although pain in the frontal sinuses is most common, radiological changes are most commonly seen in the maxillary sinuses.^{2,3}

Treatment

Decongestants are sufficient (enough), the routine use of antibiotics is not recommended. It is necessary to diagnose predisposing factors by diagnostic, computerized tomography or endoscopy and to eliminate ostium obstruction by surgical methods.^{20,21}

After barotrauma, it is advisable to make an initial RTG imaging of the sinuses, as diving is allowed after 6 weeks if the radiological pathological finding has regressed.²

Prevention

If there is a pain in the sinuses, a dive up to 6 m deep must be slowed down. Unless the pain regresses, diving must not be continued. Diagnostic processing and treatment are required, then repeat the dive, preferably in a swimming pool under controlled conditions.^{20,22}

Conclusion

A modern man is increasingly diving, flying, professionally and even more for recreation (diving is the fastest growing recreational sport in the USA). Barotrauma of the ears and sinuses is becoming a more frequent diagnosis in the pathology of tourism medicine. Therefore, the incidence of such injuries is expected to increase in Croatia as well.

References

1. Becker GD, Parell GJ. Barotrauma of the ears and sinuses after scuba diving. *Eur Arch Otorhinolaryngol* 2001;258: 159-163
2. Mallen JR, Roberts DS. SCUBA Medicine for otolaryngologists: Part I. Diving into SCUBA physiology and injury prevention. *Laryngoscope* 2020;130: 52-58.
3. Neblett ML. Otolaryngology and sport scuba diving. *Ann Otol Rhinol Laryngol* 1985; 94 (suppl 115):1-12.
4. Rišavi A. Avijacijska i astronautska otorinolaringologija. U: Šercer A. Otorinolaringologija II, Zagreb: Jugoslavenski leksikografski zavod, 1965;713-715.
5. Stieler O, Loba W, Gawęcki W. et al. The impact of regular diving on the condition of the middle ear. *Int J Occup Med Environ Health* 2021;34:779-788.
6. Sade J, Amos A, Fuchs C. Barotrauma vis-a-vis the «Chronic otitis media syndrome»: two condition with middle ear gas deficiency. *Ann Otol Rhinol Laryngol* 2003;112:230-235.
7. Weiss MH, Frost OJ. May children with otitis media with effusion safely fly? *Clin Pediatr (Phila)* 1987;26:567-568.
8. Orita Y, Sando I, Hasebe S, Miura M. Postnatal change on the location of Ostmann's fatty tissue in the region lateral to Eustachian tube. *Int J Pediatr Otorhinolaryngol* 2003;67:1105-1112.
9. Klingmann C, Praetorius M, Baumann I, Plinkert PK. Otorhinolaryngologic disorders and diving accidents: an analysis of 306 divers. *Eur Arch Otorhinolaryngol* 2007;264:1243-1251.
10. Lasak JM, Van Ess M, Kryzer TC, Cummings RJ. Middle ear injury through the external auditory canal: a review of 44 cases. *Ear Nose Throat J* 2006;85:722,724-8.
11. Hüttenbrink KB. Biomechanics of stapesplasty: a review. *Otol Neurotol* 2003;24:548-557.
12. Pelousa EO. The history of otolaryngology in the Canadian military: from first to last. *J Otolaryngol* 1997;26:345-350.
13. Thompson JN, Kohut KI. Perilymph fistulae: variability of symptoms and results of surgery. *Otolaryngol Head Neck Surg* 1979;87:898-903.
14. Scarpa A, Ralli M, De Luca P. et al. Inner Ear Disorders in SCUBA Divers: A Review. *J Int Adv Otol* 2021;17:260-264
15. Antonelli PJ, Parell GJ, Becker GD, Paparella MM. Temporal bone pathology in scuba diving deaths. *Otolaryngol Head Neck Surg* 1993;109:514-521.
16. Paparella MM, Schachern PA, Choo YB. The round window membrane: otological observations. *Ann Otol Rhinol Laryngol* 1983;92:629-634.
17. Singleton GT, Post KN, Karlan MS, Bock DG. Perilymph fistulas. Diagnostic criteria and therapy. *Ann Otol Rhinol Laryngol* 1978;87:797-803.
18. Parell GJ, Becker GD. Conservative management of inner ear barotrauma resulting from scuba diving. *Otolaryngol Head Neck Surg* 1985;93:393-397.
19. Pullen FW 2nd. Perilymphatic fistula induced by barotrauma. *Am J Otol* 1992;13:270-272.
20. Lynch JH, Deaton TG. Barotrauma with extreme pressures in sport: from scuba to skydiving. *Curr Sports Med Rep* 2014;13:107-112
21. Murrison AW, Smith DJ, Francis TJ, Counter RT. Maxillary sinus barotrauma with fifth cranial nerve involvement. *J Laryngol Otol* 1991;105:217-219.
22. Parell GJ, Becker GD. Neurological consequences of scuba diving with chronic sinusitis. *Laryngoscope* 2000;110:1358-1360.