

# Case report

## Electric shock leading to acute lung injury in a scuba diver

Kelly Johnson-Arbor

*Department of Plastic and Reconstructive Surgery, MedStar Georgetown University Hospital, Washington DC, USA*

**Corresponding author:** Dr Kelly Johnson-Arbor, Department of Plastic and Reconstructive Surgery, MedStar Georgetown University Hospital, 3800 Reservoir Road NW, Washington DC, 20007, USA

[kkja@me.com](mailto:kkja@me.com)

### Keywords

Burns; Diving; Electric injuries; Salt water aspiration

### Abstract

(Johnson-Arbor K. Electric shock leading to acute lung injury in a scuba diver. *Diving and Hyperbaric Medicine*. 2022 December 20;52(4):286–288. doi: 10.28920/dhm52.4.286-288. PMID: 36525687.)

**Introduction:** Electrical injuries are a rarely reported complication of scuba diving.

**Case report:** A 33-year-old woman wore a 12-volt heated shirt designed for motorcycling, powered by a canister light battery, while scuba diving. A leak in her drysuit allowed water to make contact with an electrified connector from the heated shirt, and she experienced painful electrical shocks. She was able to disconnect the power source and finish the dive, but she developed progressive fevers and dyspnoea several hours later. She was diagnosed with acute lung injury and treated with bronchodilators. Her symptoms resolved over subsequent weeks.

**Discussion:** Acute lung injury is rarely reported after low voltage electrical injury. In this case, the use of a heated shirt that was not intended for underwater activities heightened the patient's risk for electric shock that likely resulted in aspiration of sea water and subsequent acute lung injury. To reduce risk of injury, divers should use equipment that is designed for underwater submersion. Medical professionals who treat the diving population should be aware that divers may use modified equipment that increases the risk of diving-related complications.

---

### Introduction

Electrical injuries are rare, accounting for approximately 5% of admissions to major burn centres.<sup>1</sup> Although significant exposures to electrical current are rarely encountered during underwater diving, electrical injury can cause significant disease or death if it occurs while submerged underwater. This report describes a case of low voltage electrical shock in a scuba diver that indirectly resulted in acute lung injury. Written permission for case report publication was obtained from the patient.

### Case report

A 33-year-old woman was participating in technical scuba diving using a closed-circuit rebreather apparatus. To prevent cold exposure, she wore a thermal base layer and a 12 volt (V), 2.8 ampere (Amp) heated shirt marketed for motorcyclists, underneath her drysuit. The heated shirt was long-sleeved, with electrical wires throughout the trunk and arms, and was powered by an 18.5 V diving canister light battery attached to the exterior of her drysuit. On occasion, she wore heated motorcycle gloves. These gloves had wires that connected to the heated shirt and were also powered by the battery.

On an excursion to a depth of 45 meters (150 feet) of seawater, she chose to not wear the heated motorcycle gloves due to a need for increased manual dexterity. The distal left wrist connector on the heated shirt, which was normally connected to the left glove wire, remained exposed within the drysuit (Figure 1). A leak in one of her drysuit wrist seals allowed water to enter the suit. When she turned on power to the heated shirt, she immediately felt the sensation of electrical shocks along her left wrist, adjacent to the exposed connector. She experienced pain, muscular contractions of her upper extremities, and blurred vision, but did not lose consciousness. She screamed in pain, but a mouthpiece retaining strap prevented her from expelling her dive surface valve (DSV) from her mouth. She was unable to communicate what had happened to her dive partner, but she was able to manually disconnect power to the heated shirt and stop the electrical shocks. As her dive profile had been otherwise uneventful, she then finished her dive, completed a normal ascent and decompression, and drove home.

Later that evening, she developed a low-grade fever. The following day, her temperature rose to 39.2°C and she experienced chills as well as dyspnoea. She took rapid COVID-19 antigen tests which were negative. Due to worsening dyspnoea, she sought medical care three days later.

**Figure 1**

Wrist connector that was exposed to electrical current and salt water



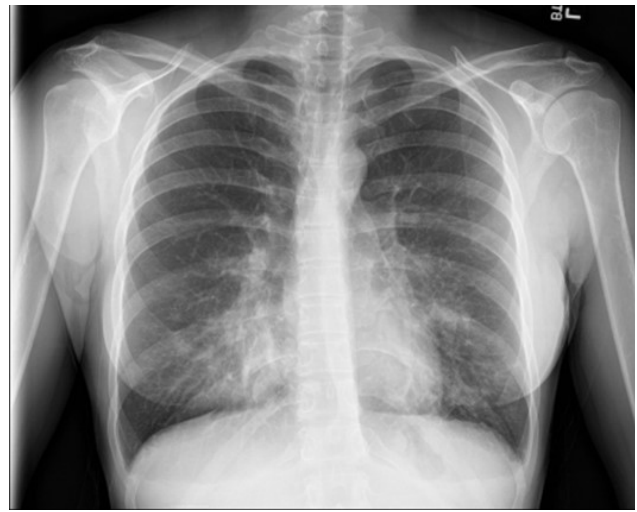
At that time, her vital signs were unremarkable (temperature 36.7°C, respiratory rate 18 per minute, oxygen saturation 99% on room air). Physical examination revealed diminished sounds at both lung bases. An electrocardiogram revealed normal sinus rhythm, normal QRS and QTc intervals, and no acute ischaemic changes. A chest X-ray showed bilateral airspace changes (Figure 2), and computed tomography (CT) of the chest performed two days later revealed bilateral anterior nodular and ground glass opacities involving all five lung lobes (Figure 3). Laboratory evaluation, including renal function, urinalysis, creatinine kinase concentration, and complete blood count, was unremarkable (the white blood cell count was  $7.5 \times 1,000 \cdot \text{uL}^{-1}$  [normal range 3.4–10.8  $1,000 \cdot \text{uL}^{-1}$ ]). A diagnosis of acute lung injury was established, and an albuterol metered-dose inhaler was prescribed. The patient's dyspnoea and fevers improved over the next few days, although she reported experiencing intermittent palpitations with exertion. Six weeks after the dive, she remained asymptomatic. Subsequent evaluations, including pulmonary function testing, cardiac echocardiography, and exercise stress testing were within normal limits. A repeat chest CT scan showed resolution of the previously noted pulmonary abnormalities. The diver was advised that she could safely resume diving, although use of the heated motorcycle shirt while underwater was strongly discouraged.

### Discussion

This diver experienced acute lung injury after sustaining electrical shocks, but the relationship between the electrical injury and her acute lung injury was initially unclear.

**Figure 2**

Bilateral airspace disease involving the right middle lobe and lingula on chest radiograph

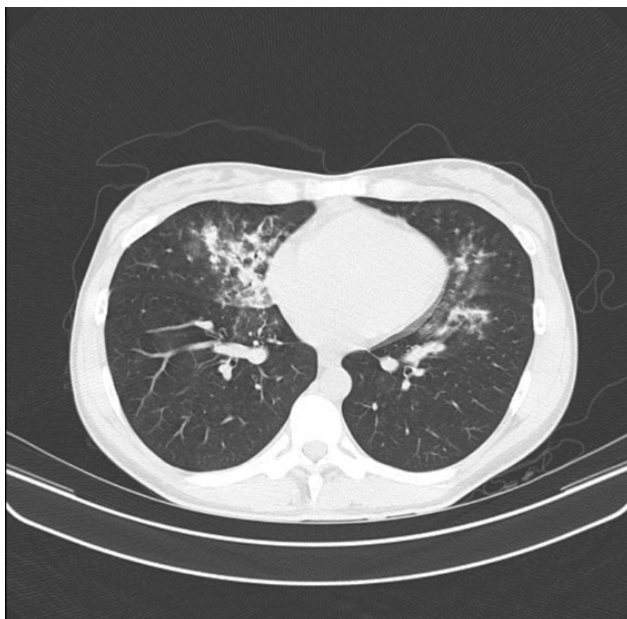


Electrical injuries result from the passage of heat and electrical current through tissues, which causes cellular damage through muscle fibrillation and coagulation necrosis.<sup>2</sup> Electrical injuries are often divided into those resulting from low voltage (< 1,000 V) and high voltage (> 1,000 V) exposures, but the current and duration of shock are also factors that determine the extent of injury. Acute lung injury is rarely described in the context of low voltage electrical injury but has been reported to occur after exposures to 110–380 V, much higher than the 12 V exposure experienced by the patient described above.<sup>3–6</sup> As a 12 V shock is unlikely to directly cause acute lung injury, it is unlikely that the electrical shocks experienced by this diver were a direct cause of her pulmonary injury, and thus alternative causes were explored. Both immersion pulmonary edema and a 'caustic cocktail' exposure were considered as potential diagnoses, but were ultimately dismissed as the timing and characteristics of the signs and symptoms were inconsistent with these diagnoses. Seawater aspiration can cause acute lung injury, and the anterior location of the infiltrates noted on this patient's chest CT imaging were consistent with aspiration occurring in the prone (e.g., diving) position. Although the patient did not recall aspirating oral contents or sea water during the dive, it is possible that this occurred while she screamed after initially receiving electrical shocks, and that this caused her subsequent pulmonary injury.

After seawater aspiration was established as the most likely cause of acute lung injury, the events that contributed to the aspiration event were investigated. As described, the diver wore a heated shirt under her drysuit. A leak in the drysuit allowed water to contact an exposed electrical connector on the shirt, which created an electrical current. Heated undergarments are used by divers for thermal protection and to potentially reduce the risk of decompression sickness.

**Figure 3**

Chest computed tomography scan image with bilateral opacities present



The use of a heated undergarment while diving introduces a risk of electric shock (and possibly thermal burns), as demonstrated in this case report. Divers may also experience unexpected injuries when using batteries with a different voltage than the heated garment (e.g., an 18 V battery on a 12 V heated shirt). While there are heated undergarments that are marketed as being safe for use while diving, some divers use retrofitted shirts intended for motorcycle riding, hunting, or other outdoor activities. These garments may be advertised as being water-resistant, but they are not intended for use underwater. Modification of these garments may result in complications including electrical injury, especially in the event of a leaking drysuit. The diver was fortunate in that she wore a mouthpiece retainer strap that prevented her from expectorating her DSV during the initial electric shock. The location of the battery exterior to her drysuit also made it easier for her to disconnect the power to the heated shirt. Had the battery been secured on the inside of the drysuit, the painful muscular contractions she experienced as a result of the electrical shocks would have complicated her ability to quickly or effectively disconnect the battery from the shirt. Divers who wear drysuits with interior batteries are at increased risk for electrical injury as well as thermal burns and should remain cognizant of these potential complications when purchasing and using these devices. Additionally, to optimise diver safety, drysuit system manufacturers should avoid producing garments with interior batteries.

### Conclusions

Seawater aspiration precipitated by electric shock represents an extremely rare but potentially life-threatening

complication of underwater diving. To reduce the risk of electric shock and acute lung injury related to seawater aspiration, divers should only use equipment that is designed for underwater use. When wearing heated garments underwater, divers must ensure that their drysuits and other equipment are functioning properly, without significant leaks that might allow water to make contact with electrified wires. A mouthpiece retainer strap may be lifesaving in the event of underwater electric shock or any other event that causes distress or loss of consciousness, and use of such a device should be considered by all divers who wear heated equipment. Divers should be aware of the potential for adverse events, including direct electrical injury and/or seawater aspiration, when using battery-powered equipment underwater and should be encouraged to promptly seek medical attention if electrical injury occurs while submerged.

### References

- 1 Shih JG, Shahrokhi S, Jeschke MG. Review of adult electrical burn injury outcomes worldwide: an analysis of low-voltage vs high-voltage electrical injury. *J Burn Care Res.* 2017;38:e293–e298. doi: [10.1097/BCR.0000000000000373](https://doi.org/10.1097/BCR.0000000000000373). PMID: [27359191](https://pubmed.ncbi.nlm.nih.gov/27359191/). PMCID: [PMC5179293](https://pubmed.ncbi.nlm.nih.gov/pmc/PMC5179293/).
- 2 Marques EG, Júnior GA, Neto BF, Freitas RA, Yaegashi LB, Almeida CE, et al. Visceral injury in electrical shock trauma: proposed guideline for the management of abdominal electrocution and literature review. *Int J Burns Trauma.* 2014;4:1–6. PMID: [24624308](https://pubmed.ncbi.nlm.nih.gov/24624308/). PMCID: [PMC3945822](https://pubmed.ncbi.nlm.nih.gov/pmc/PMC3945822/).
- 3 Guimarães F, Camões J, Mesquita A, Gomes E, Araujo R. A case report: low voltage electric injuries culminating in cardiac arrest and direct lung injury. *Cureus.* 2020;12(10):e11261. doi: [10.7759/cureus.11261](https://doi.org/10.7759/cureus.11261). PMID: [33274138](https://pubmed.ncbi.nlm.nih.gov/33274138/). PMCID: [PMC7707888](https://pubmed.ncbi.nlm.nih.gov/pmc/PMC7707888/).
- 4 Chen CW, Lin YK, Yeh YS, Chen CW, Lin TY, Chang SH. Low-voltage electricity-associated burn damage of lung parenchyma: case report and literature review. *J Emerg Med.* 2021;60(2):e33–e37. doi: [10.1016/j.jemermed.2020.09.039](https://doi.org/10.1016/j.jemermed.2020.09.039). PMID: [33097353](https://pubmed.ncbi.nlm.nih.gov/33097353/).
- 5 Truong T, Le TV, Smith DL, Kantrow SP, Tran VN. Low-voltage electricity-induced lung injury. *Respirol Case Rep.* 2017;6(2):e00292. doi: [10.1002/rcr2.292](https://doi.org/10.1002/rcr2.292). PMID: [29321936](https://pubmed.ncbi.nlm.nih.gov/29321936/). PMCID: [PMC5756716](https://pubmed.ncbi.nlm.nih.gov/pmc/PMC5756716/).
- 6 Karamanli H, Akgedik R. Lung damage due to low-voltage electrical injury. *Acta Clin Belg.* 2017;72:349–51. doi: [10.1080/17843286.2016.1252547](https://doi.org/10.1080/17843286.2016.1252547). PMID: [27800714](https://pubmed.ncbi.nlm.nih.gov/27800714/).

**Conflicts of interest and funding:** nil

**Submitted:** 30 July 2022

**Accepted after revision:** 13 November 2022

**Copyright:** This article is the copyright of the authors who grant *Diving and Hyperbaric Medicine* a non-exclusive licence to publish the article in electronic and other forms.