

Hyperbaric oxygen treatment for refractory haemorrhagic cystitis occurring after chemotherapy and haematopoietic stem cell transplantation: retrospective analysis of 25 patients

Handan Ozturk¹, Bengusu Mirasoglu², Samil Aktas²

¹ Ankara Numune Research and Training Hospital, Underwater and Hyperbaric Medicine Department, Ankara, Turkey

² Istanbul University, Istanbul Faculty of Medicine, Underwater and Hyperbaric Medicine Department, Istanbul, Turkey

Corresponding author: Associate Professor Bengusu Mirasoglu, Istanbul Tıp Fakültesi, Sualtı Hekimliği ve Hiperbarik Tıp Anabilim Dalı, 34093 Fatih, Istanbul, Turkey

bengusu.mirasoglu@istanbul.edu.tr

Key words

Cyclophosphamide; Hematopoietic stem cell transplantation; Hemorrhagic cystitis; Hyperbaric research

Abstract

(Ozturk H, Mirosoğlu B, Aktas S. Hyperbaric oxygen treatment for refractory haemorrhagic cystitis occurring after chemotherapy and haematopoietic stem cell transplantation: retrospective analysis of 25 patients. *Diving and Hyperbaric Medicine*. 2022 March 31;52(1):27–34. doi: 10.28920/dhm52.1.27-34. PMID: 35313370.)

Introduction: Intractable haemorrhagic cystitis (HC) is a serious complication of chemotherapy (CT) and haematopoietic stem cell transplantation (HSCT). Hyperbaric oxygen treatment (HBOT) is a promising treatment option based on the similarities in injury pattern and observed histological changes with radiation induced HC, which is an approved indication. We present our experience with HBOT in HC occurring after CT and HSCT.

Methods: Medical files of patients who underwent HBOT between the years 2000–2020 for HC that developed after chemotherapy and/or HSCT were reviewed. Demographic data, primary diagnosis, history of HC and details of HBOT were documented. Treatment outcomes were grouped as complete and partial healing, no response and deterioration.

Results: Twenty-five patients underwent a median of 12 HBOT sessions for HC occurring after CT and HSCT. Complete healing was observed in 11 patients whereas haematuria improved in seven patients. HC grades after HBOT were significantly better than referral grades. A significant correlation was shown with the number of HBOT sessions and change in haematuria. Patients who underwent seven or more HBOT sessions benefitted most.

Conclusions: HBOT appears to be a safe and effective treatment for refractory HC following CT and HSCT. Higher quality evidence would be needed to prove efficacy. However, given the difficulty of conducting randomised controlled trials on such a vulnerable and small group of patients with few treatment options, and given the consistency of current observational evidence, HC occurring after CT and HSCT may be considered as an optional or investigational indication for HBOT.

Introduction

Haemorrhagic cystitis (HC) is a diffuse bladder inflammation that causes haematuria and other urinary tract complaints. Clinical presentation can vary from painless microscopic haematuria to severe occlusive haematuria that causes renal failure. It can be a life-threatening situation requiring challenging treatments with prolonged hospitalisation, multiple transfusions and sometimes aggressive interventions while impairing quality of life. Acute HC is mostly caused by bacterial infections and responds well to treatment.^{1,2} Chronic or intractable HC is related mostly to treatment of malignancy and can be induced by radiotherapy, some chemotherapeutics (particularly cyclophosphamide) and haematopoietic stem cell transplantation (HSCT).³ Interstitial cystitis is another but comparatively rare cause.

Cyclophosphamide is used for preconditioning before HSCT and in the treatment of certain solid tumours and lymphoma, as well as some immune-inflammatory conditions like

systemic lupus erythematosus or Wegener's granulomatosis.⁴ Cyclophosphamide induces HC through its urotoxic metabolite acrolein which impairs the integrity of urothelium when comes in direct contact and causes mucosal and submucosal oedema, ischaemia and cell loss. Consequent bleeding from telangiectatic capillaries develops.⁵ In immunocompromised patients, specifically after HSCT, urotropic viruses like BK Polyoma virus, John Cunningham virus or adenovirus types reactivate and replicate in the already injured mucosa.^{6,7} Finally, it is thought an immune reaction directed towards virus antigens further damages the mucosa leading to haemorrhage.⁸ HC associated with HSCT is regarded as early onset when it starts between 48 hours to one week after preconditioning. Late onset HC, conversely, may occur weeks after the transplant.³ Histologic changes in chemotherapy (CT)- and HSCT-related HC are very similar to those in radiation-induced HC, which is characterised by progressive endarteritis, mucosal and submucosal oedema and inflammation with cellular hypoxia leading to fibrosis and diffuse telangiectasia.^{9,10}

Management of HC occurring after CT and HSCT is primarily based on prevention. Mesna, which binds the urotoxic metabolite acrolein in the urine, and supportive treatments like hyperhydration (forced diuresis) and continuous bladder irrigation are the common methods for prevention.⁶ HC incidence after CT and HSCT has declined significantly with these measures however they are not always successful and HC may still develop.⁴ Supportive treatments are first line options but their efficacy is limited once haemorrhage starts and HC may progress.² Spontaneous remission is also possible in some but it may take a long time with significant morbidity in the interim.^{6,11}

There is no definitive treatment algorithm when prevention fails but a wide range of therapeutic approaches have been investigated. Systemic use of pentosane polysulphate sodium, oestrogens, recombinant factor VII or VIII and some growth factors are conservative options however results are inconsistent. Intravesical instillation of some agents like hyaluronic acid, prostaglandins or alum have been reported but evidence for their use is conflicting. Antivirals, specifically cidofovir (both intravenous and intravesical use) were shown to be beneficial in the presence of virus but efficacy still needs to be validated. Besides, deterioration in renal function is a serious concern. Recently cellular therapies were introduced but scientific support is still scarce. Aggressive surgical interventions ranging from clot evacuation, fibrin glue application to vesicostomy, selective arterial embolization, and even cystectomy may be necessary in unresponsive cases.^{3,6,11}

Hyperbaric oxygen treatment (HBOT) has emerged as a non-invasive modality for HC occurring after CT and HSCT based on the similarity of histological changes to radiation-induced HC (an accepted indication for HBOT), and promising results have been reported.^{3,5} It is proposed as a safe treatment with recommendation levels similar to other options in urological reviews and guidelines.^{3-6,11} However, it is not approved in HC after CT or HSCT by the European Committee for Hyperbaric Medicine (ECHM), Undersea and Hyperbaric Medicine Society (UHMS) or our local authority (the Turkish Ministry of Health) and its use is still limited even though refractory HC caused by radiation cystitis is approved.^{12,13} Taking account of cumulative evidence from observational clinical reports together with some comparative and experimental studies, HC occurring after CT and HSCT may be considered for approval as at least a weak recommendation. We report our 20-year experience of treating HC occurring after CT and HSCT with HBOT to add to the body of observational evidence.

Methods

This single centre retrospective study was approved by Istanbul Faculty of Medicine Clinical Research Ethical Board with approval number 2017/394.

Patients who underwent HBOT in our department between the years 2000–2020 for HC that developed after chemotherapy and/or HSCT were identified. Radiation-induced HC cases were not included. Patient files were reviewed and demographic data, primary diagnosis, history of HC including previous chemotherapy and HSCT data, treatment before referral and details of HBOT were documented. Severity of HC at the time of presentation and at the end of HBOT was graded as proposed elsewhere¹⁴ (Table 1). A classification was developed to assess the response to HBOT and treatment outcomes were grouped as complete healing, partial healing, no-response and deterioration (Table 2). Complete healing and partial healing were defined as complete resolution of symptoms (HC Grade 0), or reduction in severity of symptoms without complete resolution, respectively.

HYPERBARIC OXYGEN TREATMENT

Hyperbaric oxygen was administered at 243 kPa (2.4 atmospheres absolute) in a multiplace chamber (Hipertech Zyron12, Turkey) once daily, five days per week. Treatment involved 15 minutes of compression; three 25-minute oxygen breathing periods separated by five-minute air breaks; and 15 minutes of decompression. Oxygen was administered by a mask. Medical staff attended all sessions.

The number of HBOT sessions was generally determined on a case-by-case basis depending on the patient's response and general condition. Patients were primarily followed by the referring physician by daily physical examination, blood and urine tests. HBOT was stopped when symptoms totally resolved or no further improvement was observed, or if a patient's general condition deteriorated unrelated to HBOT.

STATISTICAL ANALYSIS

Data were analysed using IBM SPSS v21.0 software. Normality of distribution was evaluated by Kolmogorov-Smirnov test. Demographic and descriptive data were expressed as mean and standard deviation or numbers and

Table 1
Haemorrhagic cystitis grading as proposed by Droller et al.¹⁴

Grade	Manifestations
0	No haematuria, no irritative symptoms
I	Non-visible (microscopic) haematuria, dysuria
II	Macroscopic haematuria
III	Macroscopic haematuria with small clots
IV	Gross haematuria with clots causing urinary tract obstruction requiring instrumentation for clot evacuation

Table 2

Treatment outcome groups, number of patients and mean number of sessions applied in each outcome group

Outcome	Definition	Patients <i>n</i> (%)	HBO sessions Mean (SD)
Complete healing	No residual signs or symptoms	11 (44%)	15 (13)
Partial healing	At least one grade improvement in haematuria but complete healing is not present	7 (28%)	14 (5)
No response	No change in haematuria	7 (28%)	3 (1)
Deterioration	Increase in haematuria	0	0

Table 3

Demographic and medical details of the patients; ALL – acute lymphocytic leukaemia; AML – acute myeloblastic leukaemia; CID – combined immunodeficiency; CML – chronic myeloid leukaemia; FA – Fanconi anaemia; HSCT – haematopoietic stem cell transplantation; MDS – myelodysplastic syndrome; RMS – rhabdomyosarcoma

Patient characteristics	
Female / Male, <i>n</i> (%)	9/16 (36% / 64%)
Age, mean (SD)	18.3 (9.8)
Medical details, <i>n</i> (%)	
Chemotherapy	25 (100%)
HSCT	22 (88%)
AML	6 (24%)
ALL	10 (40%)
CML	2 (8%)
MDS	4 (16%)
Other (RMS, FA, CID)	3 (12%)

percentages where appropriate. HC grades before and after HBOT were compared by Wilcoxon test for non-parametric paired samples. The Kruskal-Wallis test was used to compare number of HBOT sessions applied in all treatment outcome groups and the Mann-Whitney U test was used to compare pairs of outcome groups. Correlation between number of HBOT sessions and treatment outcomes was investigated with Spearman's rho test. The HBOT efficacy limit was determined using receiver operating characteristic (ROC) analysis. Significance was accepted at $P < 0.05$.

Results

Twenty seven patients were treated with HBOT for HC occurring after CT or HSCT. Two patients were excluded; one had an incomplete record and one ceased treatment due to a new diagnosed bladder malignancy.

Demographic data and details of previous medical records for the 25 patients analysed are given in Table 3. Female patients (mean [SD] age = 23.7 [13.3] years) were significantly older than males (15.3 [5.6]) ($P = 0.033$). Urotropic virus presence was confirmed in 13 patients. Either no virus was detected or presence was not reported in the remaining 12 patients.

Patients had received conventional treatments after HC occurred. The combination of hyperhydration and continuous bladder irrigation was applied to all patients. Twenty-two patients had received antibiotic therapy. Thirteen patients in whom virus detection was reported had received antivirals. Patients were referred for HBOT after they remained unresponsive to their treatments.

Haemorrhagic cystitis grades at the time of referral and at the end of HBOT are given in Table 4. Grades after HBOT were significantly lower than referral grades. ($P < 0.001$) None of the patients had Grade I at the time of referral. Change in number of patients in each HC grade with HBOT is given in Figure 1. Of the 25 patients included, 11 (44%) healed completely whereas clinical condition improved in seven (28%) and did not change in seven (28%) patients. Haematuria did not worsen in any patient.

Of the seven patients who did not respond to HBOT, two refused to continue after two sessions, one quit after the sixth session due to scheduled chemotherapy and in three others HBOT was interrupted by their primary physicians after the third session due to deterioration in general condition unrelated to HBOT. Similarly, in the partial healing group, four patients' treatments were terminated by their primary physicians as soon as an improvement was observed despite our advice to continue. Complete resolution was reported in three of these patients at eight, 10 and 20 days after HBOT. Nevertheless, these patients were still classified as being in the partial healing group.

The patients underwent a mean of 12 (SD 10) HBOT sessions. The mean number of sessions patients underwent in each outcome group is given in Table 2. The number of sessions applied differed significantly between treatment outcomes ($\chi^2 = 13.13$; $P = 0.001$). There was no statistically significant difference between the number of sessions applied in the total healing and the partial healing group but the number of sessions in the no response group was significantly less than both the complete and partial healing groups ($P = 0.002$ and 0.008 respectively). A significant correlation was shown with the number of sessions applied and change in HC grades with HBOT ($\rho = 0.601$, $P = 0.001$).

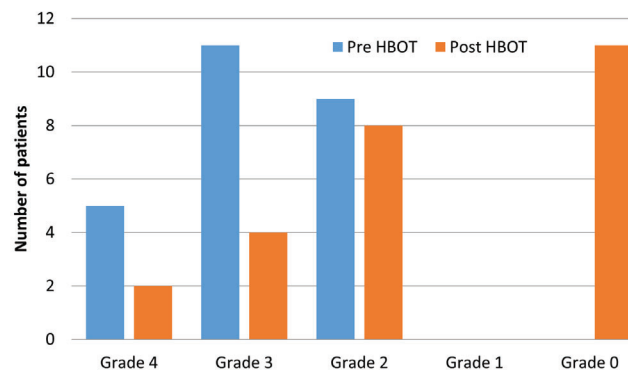
Table 4

Number of patients in each haemorrhagic cystitis grade group before and after HBOT; * no response; † partial healing; ‡ complete healing

Haemorrhagic cystitis grade before HBOT	Haemorrhagic cystitis grade after HBOT (n)				
	Grade IV (n = 2)	Grade III (n = 4)	Grade II (n = 8)	Grade I (n = 0)	No haematuria (n = 11)
Grade IV (n = 5)	2*	2†	0	0	1‡
Grade III (n = 11)		2*	5†	0	4‡
Grade II (n = 9)			3*	0	6‡
Grade I (n = 0)				0	0

Figure 1

Change in the number of patients in each haemorrhagic cystitis grade group before and after HBOT



ROC analysis revealed that patients who underwent seven (sensitivity = 0.889; specificity = 1.000) or more HBOT sessions benefitted from the treatment more (area under curve = 0.964; %95 GA: 0.803–0.999; $P < 0.0001$).

Discussion

The first reports of HBOT use in cyclophosphamide-induced HC dates back to the beginning of the 1990s.^{15,16} Since then a number of studies have been published. All these studies have a few points in common. (1) Almost all of them are either case reports or series. (2) HBOT was applied as a last resort after all available treatments of the time had been tried. (3) Generally severe cases were referred. (4) Almost all studies report successful results with complete cessation of haemorrhage. (5) An exact mechanism of action was not proposed either in these clinical studies or in the few experimental studies conducted later. (6) Similar to many other applications of HBOT, treatment protocol (pressure, time, frequency, total number of sessions) varied among studies. (7) Haematuria generally did not recur during the follow up time indicated.

There are no controlled trials of HBOT in HC occurring after CT and HSCT but there are several case reports all with successful results.^{17–32} It is possible that only cases responding well to HBOT were reported in single case reports so case series may provide a more objective evaluation of the efficacy of HBOT. Complete healing was reported in all referred patients in two of the five case series available and few patients remained unresponsive in the other three.^{9,33–36} The only patient who did not show complete healing in one report was reported to have Fanconi anaemia and received only five HBOT sessions due to “pressure intolerance”.³³ In another study, the recovery rate with HBOT was 78%; significantly higher than achieved with prostaglandin treatment.³⁴ Likewise, seven of ten paediatric patients healed completely and haematuria resolved in two of the three non-recovered patients shortly after ceasing HBOT.³⁵ No recurrence was reported in any of the case reports or series so far.

There are few relevant experimental studies however they all show beneficial effects of HBOT on damaged bladder. The first study of acrolein-induced HC in rats, showed that HBOT applied prior to and after acrolein installation increased the amount of intact bladder epithelium.³⁷ Later, consecutive animal studies investigating HBOT’s role in cyclophosphamide induced HC were conducted.^{38–41} Initially the authors compared protective effects of HBOT and Mesna by evaluating changes in bladder weight, ratio of bladder weight to body weight and haematuria grades. It was found that when HBOT was added to Mesna, urothelial damage was minimal and evaluated parameters were comparable to the control group.^{38,39} Their subsequent study investigating nitric oxide involvement in CT induced HC and its relation to HBOT, showed that HBOT decreased the necrotic area in the bladder and concluded that HBOT was more therapeutic than prophylactic. They confirmed this result in their next study that showed accelerated urothelial regeneration with HBOT.^{40,41} Recently, HBOT was shown to decrease inflammation, oedema, fibrosis and tissue damage of bladder mucosa in a hydrogen peroxide-induced chronic cystitis model.⁴² Results observed in experimental studies are in line with clinical reports in general. Yet, well designed

experimental studies looking into possible mechanism of HBOT in HC would fill a gap.

The present retrospective analysis of 25 patients showed HBOT can be useful for HC occurring after CT and HSCT. Apart from being the largest series presented to date, this study differs from the previous ones by evaluating the response to HBOT in terms of change in haematuria severity instead of cure rate alone. This provides a clearer view on the effects of HBOT. In our study group, haematuria ceased in eleven patients and improved in seven, while no change was observed in the rest of the patients. Complete healing in our study was less than healing rates reported before. However, premature interruption of HBOT was common in our patient group whereas only a few patients were reported to withdraw prematurely in previous series. It can be speculated that outcomes could be better if these patients had received more sessions. Indeed, our findings revealed that number of HBOT sessions had an impact on treatment outcomes. Additionally, the minimum number of sessions for HBOT to be effective was found to be seven. Yet, all seven patients in the no response group underwent less than seven sessions due to problems unrelated to HBOT. Again, the possibility of a better outcome with additional sessions cannot be ignored.

Naturally, in a group where spontaneous remission is possible and other treatment methods are also applied it is hard to attribute healing solely to HBOT. However, in our study group all patients had received treatments that were accepted standard of care at the time they had been treated and had remained unresponsive. As was the case in most of the previous reports, improvement was observed only after they started HBOT. In a recent study that compared HBOT with conventional therapies for HC occurring after HSCT, HBOT was found to have higher complete resolution rates and shorter treatment times.⁴³ A similar result was revealed in a study in which HBOT was compared to prostaglandin instillations.³⁴

HBOT increases tissue oxygenation and vascular endothelial growth factor, initiates stem cell mobilisation, capillary angiogenesis and fibroblast proliferation, decreases oedema and fibrosis, improves granulation and epithelialization, all leading to healing in damaged and ischaemic tissue. Moreover, by modulating leukocyte function, it reduces pathological inflammation and enhances immune responses to pathogens.^{9,44} Both in cyclophosphamide- and virus-induced HC pathological findings show inflammation and ulceration in bladder mucosa. The underlying mechanism is thought to be ischaemia which leads to mucosal breakdown.^{7,10} HBOT elevates tissue oxygen tension in hypoxic urothelium, normalising tissue healing and so helping the repair of damaged bladder mucosa. Provision of permanent healing is attributed to this mucosal repair.^{18,19,23}

There is no definitive HBOT protocol for HC occurring after CT and HSCT and data about number of sessions required

for efficacy and treatment schedules are inconsistent. The minimum number of sessions at which a response to treatment was observed is three. In a few other cases, haematuria or tamponade were reported to resolve with a maximum of five sessions.^{20,27,28} However, various numbers of sessions are reported and an objective analysis about minimum effective sessions is not available. Our findings may contribute to treatment planning in this regard.

The total number of sessions applied also varies in the existing literature but is generally less than 40. Four patients were reported to undergo higher number of sessions (56, 58, 60 and 84 sessions) until complete healing was achieved.^{22,24,33,34} In the present study, the majority of patients received less than 20 sessions. Two patients who eventually healed completely underwent 39 and 42 sessions. It is clear that a maximum number of sessions can't be proposed with the limited data available. Nevertheless, when the similarity of pathophysiology is considered, common practice for radiation induced HC may be adapted.

A similar uncertainty is present about the timing of HBOT. In most of the reported cases, HBOT has been used after all other treatments fail. However, HBOT is expected to be more beneficial in the earlier period when its possible mechanisms of action are considered.¹⁹ Besides, HBOT does not interfere with other treatment options so can be applied as an adjuvant. In fact, one study showed that haematuria resolved significantly faster in the patients who started HBOT early in the clinical course.³³ Several authors suggest early referral for HBOT instead of using it as a last resort.^{18,23}

HBOT is a relatively safe modality. The most common side effect is middle ear barotrauma which is reversible and serious side effects are very rare. No side effects were recorded in our patients. The most unusual event reported in previous articles is a capillary leak syndrome in a patient with Fanconi anaemia.⁴⁵ This patient developed generalised oedema, hallucinations and confusion after the ninth HBOT session and all symptoms disappeared when HBOT was ceased. The authors speculatively related this condition to toxic effects of oxygen and recommended avoiding HBOT in HC patients with Fanconi anaemia. Interestingly the only patient who remained unresponsive to HBOT in another study also had Fanconi anaemia which the author presented as a relative contraindication. Apparently, the patient withdrew from treatment after five sessions not due to a recognized side effect but a condition defined as "*pressure intolerance*".³³ Our Fanconi anaemia patient discontinued after 11 sessions due to deterioration in general condition. His haematuria had improved at the time of cessation and later resolved completely. He was included in the partial healing group as mentioned earlier. We cannot exclude the possibility of an adverse effect since the primary physician did not provide details about the patient's condition.

A more prominent threat to these patients would be cross infection during their visits to hyperbaric chamber. They

are generally immunosuppressed and prone to infection, but in daily practice many patients, specifically wound care patients, with resistant nosocomial infections are also treated in hyperbaric chambers. Therefore, management of HC patients at hyperbaric unit and in the chamber would require particular care.¹⁰ Such a complication has not been reported before however all our patients underwent exclusive HBOT sessions scheduled as the first session of the day and the chamber was disinfected before each session. Moreover, patients who require continuous irrigation may have difficulties especially in monoplace chambers. In one report, an in-chamber continuous irrigation scheme initially used was abandoned due to a bladder rupture that developed during a session.^{46,47}

Although remarkable healing has been reported with HBOT, its use in HC occurring after CT and HSCT is relatively uncommon. This is probably due to the scarcity of robust evidence for its use. On the other hand, almost all other current and commonly adapted methods also have similar or weaker evidence.^{3,11,48} In the 6th European Conference of Infections in Leukaemia (ECIL) treatment guidelines, HBOT has similar levels of evidence and recommendation to intravenous cidofovir and fibrin glue for the treatment of HC after HSCT whereas other approaches are not recommended at all.¹¹ In a recent systematic review of BK virus-related HC, HBOT was considered to be “*effective and safe*” for treatment and stated to have level 4 evidence with a grade C recommendation. A higher level of evidence (Level 3) was defined only for intravenous cidofovir in this review.⁶ Also, in the Canadian Urological Association’s best practice report for paediatric HC, HBOT is again presented as “*safe, effective and relatively low risk*” and stated to have Level 3 evidence with a grade B recommendation. Similar or weaker evidence was identified for all other therapeutic modalities and even preventive measures like hydration or Mesna.³

In hyperbaric medicine guidelines, however, HC occurring after CT and HSCT is not included while other common intractable HC states are. Radiation-induced HC is an approved indication by both the ECHM and UHMS. Until very recently there was only one randomised trial which actually compared efficacy of hyaluronic acid and HBOT in radiation cystitis and other support came from retrospective observational studies. It was only in 2019 that a randomised clinical trial demonstrating effectiveness of HBOT for radiation cystitis was published.⁴⁹ Interstitial cystitis is also an ECHM-approved indication although with a weak recommendation (type 3; reasonable to use).¹² The level of evidence is stated to be low and similarities in the mucosal injury with radiation-induced HC forms the basis for approval. HC occurring after CT and HSCT also exhibits a similar injury pattern and histological change.^{9,10,19} Although there are not any high-level evidence studies like RCTs on HBOT use in HC occurring after CT and HSCT, numerous observational clinical studies and some comparative studies

have consistently reported successful results. Experimental studies also show reparative effect of HBOT on damaged bladder mucosa. When evaluated collectively, there is support for evaluation of HC occurring after CT and HSCT as an indication for HBOT.

LIMITATIONS

This is the largest series of CT and HSCT-related HC treated with HBOT to date but it has some limitations due to the retrospective nature of the study. First, long term follow-up information is absent. Yet, in previous reports, only one recurrence which later recovered was reported during follow ups extending to 136 months.^{9,50} Indeed, HBOT is considered to provide “*permanent healing*” and was even proposed to be “*disease modifying*” by some authors.^{17,25}

Also, analysis about viral loads and how they were modified with HBOT as well as correlations between treatment outcome and onset of HC could not be performed since there were missing data in patient files. In the studies in which viraemia and viruria during HBOT was followed, significant decreases in virus counts were observed.^{4,6,51} HBOT does not have a known antiviral effect. Therefore, this decrease is probably due to recovery of the hypoxic and inflamed bladder mucosa, which may be a convenient environment for the opportunistic viruses in these immunocompromised patients.

Another important drawback of the study is absence of specific treatment guidelines for the patient group who were treated. Decisions on the referral for HBOT and the course of treatments were made on a case-by-case basis. The heterogeneity of the collected data made evaluation harder. In addition, neither the referring physicians nor the HBOT specialists were blinded to the treatments. Therefore, possibility of bias in interpreting the clinical course cannot be excluded. There is a need for prospective randomised controlled trials with clear treatment guidelines and outcome reporting.

Conclusions

Haemorrhagic cystitis patients have primary diseases which are life threatening and have been generally treated with hard, sophisticated and expensive therapies. However, HC itself can be more serious than the primary disease due to the suffering and morbidity it causes. Our study and others have shown HBOT is safe and can benefit these patients. It is evident that studies investigating the mechanism of action of HBOT specifically in HC and prospective controlled clinical studies are required. Given the difficulty of conducting randomised trials on such a vulnerable and small group of patients with few treatment options, and given the consistency of current observational evidence, HC occurring after CT and HSCT may be considered as an optional or investigational indication for HBOT.

References

- 1 Manikandan R, Kumar S, Dorairajan LN. Hemorrhagic cystitis: a challenge to the urologist. *Indian J Urol.* 2010;26:159–66. doi: [10.4103/0970-1591.65380](https://doi.org/10.4103/0970-1591.65380). PMID: [20877590](https://pubmed.ncbi.nlm.nih.gov/20877590/). PMCID: [PMC2938536](https://pubmed.ncbi.nlm.nih.gov/pmc/PMC2938536/).
- 2 Haldar S, Dru C, Bhowmick NA. Mechanisms of hemorrhagic cystitis. *Am J Clin Exp Urol.* 2014;2:199–208. PMID: [25374922](https://pubmed.ncbi.nlm.nih.gov/25374922/). PMCID: [PMC4219308](https://pubmed.ncbi.nlm.nih.gov/pmc/PMC4219308/).
- 3 Hannick JH, Koyle MA. Canadian Urological Association best practice report: pediatric hemorrhagic cystitis. *Can Urol Assoc J.* 2019;13:E325–E334. doi: [10.5489/cuaj.5993](https://doi.org/10.5489/cuaj.5993). PMID: [31763977](https://pubmed.ncbi.nlm.nih.gov/31763977/). PMCID: [PMC6877374](https://pubmed.ncbi.nlm.nih.gov/pmc/PMC6877374/).
- 4 Payne H, Adamson A, Bahl A, Borwell J, Dodds D, Heath C, et al. Chemical- and radiation-induced haemorrhagic cystitis: current treatments and challenges. *BJU Int.* 2013;112:885–97. doi: [10.1111/bju.12291](https://doi.org/10.1111/bju.12291). PMID: [24000900](https://pubmed.ncbi.nlm.nih.gov/24000900/). PMCID: [PMC4155867](https://pubmed.ncbi.nlm.nih.gov/pmc/PMC4155867/).
- 5 Matz EL, Hsieh MH. Review of advances in uroprotective agents for cyclophosphamide- and ifosfamide-induced hemorrhagic cystitis. *Urology.* 2017;100:16–9. doi: [10.1016/j.urology.2016.07.030](https://doi.org/10.1016/j.urology.2016.07.030). PMID: [27566144](https://pubmed.ncbi.nlm.nih.gov/27566144/).
- 6 Aldiwani M, Tharakan T, Al-Hassani A, Gibbons N, Pavlu J, Hrouda D. BK virus associated haemorrhagic cystitis. a systematic review of current prevention and treatment strategies. *Int J Surg.* 2019;63:34–42. doi: [10.1016/j.ijssu.2019.01.019](https://doi.org/10.1016/j.ijssu.2019.01.019). PMID: [30711618](https://pubmed.ncbi.nlm.nih.gov/30711618/).
- 7 Jandial A, Mishra K, Sandal R, Kant Sahu K. Management of BK virus-associated haemorrhagic cystitis in allogeneic stem cell transplant recipients. *Ther Adv Infect Dis.* 2021;8:2049936121991377. doi: [10.1177/2049936121991377](https://doi.org/10.1177/2049936121991377). PMID: [33614030](https://pubmed.ncbi.nlm.nih.gov/33614030/). PMCID: [PMC7871057](https://pubmed.ncbi.nlm.nih.gov/pmc/PMC7871057/).
- 8 Leung AY, Yuen KY, Kwong YL. Polyoma BK virus and haemorrhagic cystitis in haematopoietic stem cell transplantation: a changing paradigm. *Bone Marrow Transplant.* 2005;36:929–37. doi: [10.1038/sj.bmt.1705139](https://doi.org/10.1038/sj.bmt.1705139). PMID: [16184185](https://pubmed.ncbi.nlm.nih.gov/16184185/).
- 9 Davis M, MacDonald H, Sames C, Nand K. Severe cyclophosphamide-induced haemorrhagic cystitis treated with hyperbaric oxygen. *NZ Med J.* 2011;124(1340):48–54. PMID: [21952384](https://pubmed.ncbi.nlm.nih.gov/21952384/).
- 10 Botta LM, Botta GP. Hemorrhagic cystitis: treatment with hyperbaric oxygen therapy in patients with acute lymphoblastic leukemia. *Clin J Oncol Nurs.* 2018;22:E146–E151. doi: [10.1188/18.CJON.E146-E151](https://doi.org/10.1188/18.CJON.E146-E151). PMID: [30451996](https://pubmed.ncbi.nlm.nih.gov/30451996/).
- 11 Cesaro S, Dalianis T, Hanssen Rinaldo C, Koskenvuo M, Pegoraro A, et al. ECIL-6 Group. ECIL guidelines for the prevention, diagnosis and treatment of BK polyomavirus-associated haemorrhagic cystitis in haematopoietic stem cell transplant recipients. *J Antimicrob Chemother.* 2018;73:12–21. doi: [10.1093/jac/dkx324](https://doi.org/10.1093/jac/dkx324). PMID: [29190347](https://pubmed.ncbi.nlm.nih.gov/29190347/).
- 12 Mathieu D, Marroni A, Kot J. Tenth European Consensus Conference on Hyperbaric Medicine: recommendations for accepted and non-accepted clinical indications and practice of hyperbaric oxygen treatment. *Diving Hyperb Med.* 2017;47:24–32. doi: [10.28920/dhm47.1.24-32](https://doi.org/10.28920/dhm47.1.24-32). PMID: [28357821](https://pubmed.ncbi.nlm.nih.gov/28357821/). PMCID: [PMC6147240](https://pubmed.ncbi.nlm.nih.gov/pmc/PMC6147240/).
- 13 Moon R, editor. Undersea and Hyperbaric Medical Society hyperbaric oxygen therapy indications, 14th ed. North Palm Beach (FL): Best Publishing Company; 2019.
- 14 Droller MJ, Saral R, Santos G. Prevention of cyclophosphamide-induced hemorrhagic cystitis. *Urology.* 1982;20:256–8. doi: [10.1016/0090-4295\(82\)90633-1](https://doi.org/10.1016/0090-4295(82)90633-1). PMID: [7123717](https://pubmed.ncbi.nlm.nih.gov/7123717/).
- 15 Shameem IA, Shimabukuro T, Shirataki S, Yamamoto N, Maekawa T, Naito K. Hyperbaric oxygen therapy for control of intractable cyclophosphamide-induced hemorrhagic cystitis. *Eur Urol.* 1992;22:263–4. doi: [10.1159/000474767](https://doi.org/10.1159/000474767). PMID: [1468485](https://pubmed.ncbi.nlm.nih.gov/1468485/).
- 16 Yazawa H, Nakada T, Sasagawa I, Miura M, Kubota Y. Hyperbaric oxygenation therapy for cyclophosphamide-induced haemorrhagic cystitis. *Int Urol Nephrol.* 1995;27:381–5. doi: [10.1007/BF02550072](https://doi.org/10.1007/BF02550072). PMID: [8586509](https://pubmed.ncbi.nlm.nih.gov/8586509/).
- 17 Hughes AJ, Schwarzer AP, Millar IL. Hyperbaric oxygen in the treatment of refractory haemorrhagic cystitis. *Bone Marrow Transplant.* 1998;22:585–6. doi: [10.1038/sj.bmt.1701376](https://doi.org/10.1038/sj.bmt.1701376). PMID: [9758348](https://pubmed.ncbi.nlm.nih.gov/9758348/).
- 18 Furness PD 3rd, Palmer LS, Palmer JS, Capelli-Schellpfeffer M, Cheng EY. Hyperbaric oxygen therapy for pediatric hemorrhagic cystitis. *J Urol.* 1999;161:1596–7. PMID: [10210424](https://pubmed.ncbi.nlm.nih.gov/10210424/).
- 19 Hattori K, Yabe M, Matsumoto M, Kudo Y, Yasuda Y, Inoue H, et al. Successful hyperbaric oxygen treatment of life-threatening hemorrhagic cystitis after allogeneic bone marrow transplantation. *Bone Marrow Transplant.* 2001;27:1315–7. doi: [10.1038/sj.bmt.1703077](https://doi.org/10.1038/sj.bmt.1703077). PMID: [11548852](https://pubmed.ncbi.nlm.nih.gov/11548852/).
- 20 Kuroda I, Kuwata Y, Kakehi Y. Hyperbaric oxygen therapy for Wegener's granulomatosis with cyclophosphamide-induced hemorrhagic cystitis. *Int J Urol.* 2002;9:470–2. doi: [10.1046/j.1442-2042.2002.00497.x](https://doi.org/10.1046/j.1442-2042.2002.00497.x). PMID: [12225346](https://pubmed.ncbi.nlm.nih.gov/12225346/).
- 21 Kalayoglu-Beşişik, S, Abdul-Rahman IS, Erer B, Yenerel MN, Oguz FS, Tunc M, et al. Outcome after hyperbaric oxygen treatment for cyclophosphamide-induced refractory hemorrhagic cystitis. *J Urol.* 2003;170:922. doi: [10.1097/01.ju.0000080563.58561.c8](https://doi.org/10.1097/01.ju.0000080563.58561.c8). PMID: [12913734](https://pubmed.ncbi.nlm.nih.gov/12913734/).
- 22 Saito S, Kaiho Y, Namina T, Konda R, Satoh M, Ishidoya S, et al. A case of severe hemorrhagic cystitis following bone marrow transplantation. *Int Urol Nephrol.* 2004;36:349–52. doi: [10.1007/s11255-004-0748-x](https://doi.org/10.1007/s11255-004-0748-x). PMID: [15783104](https://pubmed.ncbi.nlm.nih.gov/15783104/).
- 23 Bratsas KS, Stephanides AA, Spyropoulos E, Zachariades BP, Androulakakis PA. Hyperbaric oxygen therapy for cyclophosphamide induced refractory hemorrhagic cystitis in a child. *J Urol.* 2004;172:679. doi: [10.1097/01.ju.0000129267.31060.9d](https://doi.org/10.1097/01.ju.0000129267.31060.9d). PMID: [15247759](https://pubmed.ncbi.nlm.nih.gov/15247759/).
- 24 Jou YC, Lien FC, Cheng MC, Shen CH, Lin CT, Chen PC. Hyperbaric oxygen therapy for cyclophosphamide-induced intractable refractory hemorrhagic cystitis in a systemic lupus erythematosus patient. *J Chin Med Assoc.* 2008;71:218–20. doi: [10.1016/S1726-4901\(08\)70108-4](https://doi.org/10.1016/S1726-4901(08)70108-4). PMID: [18436507](https://pubmed.ncbi.nlm.nih.gov/18436507/).
- 25 Focosi D, Maggi F, Pistolesi D, Benedetti E, Papineschi F, Galimberti S, et al. Hyperbaric oxygen therapy in BKV-associated hemorrhagic cystitis refractory to intravenous and intravesical cidofovir: case report and review of literature. *Leuk Res.* 2009;33:556–60. doi: [10.1016/j.leukres.2008.06.018](https://doi.org/10.1016/j.leukres.2008.06.018). PMID: [18656258](https://pubmed.ncbi.nlm.nih.gov/18656258/).
- 26 Kumar SA, Prasanth P, Tripathi K, Ghosh P. Hyperbaric oxygen – A new horizon in treating cyclophosphamide-induced hemorrhagic cystitis. *Indian J Urol.* 2011;27:272–3. doi: [10.4103/0970-1591.82849](https://doi.org/10.4103/0970-1591.82849). PMID: [21814321](https://pubmed.ncbi.nlm.nih.gov/21814321/). PMCID: [PMC3142841](https://pubmed.ncbi.nlm.nih.gov/pmc/PMC3142841/).
- 27 Gökçe M, Akçay A, Tuğcu D, Erdemir M, Mirasoğlu B. Hyperbaric oxygen therapy for hemorrhagic cystitis. *Exp Clin Transplant.* 2014;12:279–80. PMID: [24907729](https://pubmed.ncbi.nlm.nih.gov/24907729/).
- 28 Hosokawa K, Yamazaki H, Nakamura T, Yoroidaka T, Imi T, Shima Y, et al. Successful hyperbaric oxygen therapy for refractory BK virus-associated hemorrhagic cystitis after cord blood transplantation. *Transpl Infect Dis.* 2014;16:843–6. doi: [10.1111/tid.12266](https://doi.org/10.1111/tid.12266). PMID: [25040402](https://pubmed.ncbi.nlm.nih.gov/25040402/).
- 29 Kaur D, Khan SP, Rodriguez V, Arndt C, Claus P. Hyperbaric

- oxygen as a treatment modality in cyclophosphamide-induced hemorrhagic cystitis. *Pediatr Transplant*. 2018;22(4):e13171. doi: [10.1111/petr.13171](https://doi.org/10.1111/petr.13171). PMID: [29569791](https://pubmed.ncbi.nlm.nih.gov/29569791/).
- 30 Tanaka T, Nakashima Y, Sasaki H, Masaki M, Mogi A, Tamura K, et al. Severe hemorrhagic cystitis caused by cyclophosphamide and capecitabine therapy in breast cancer patients: two case reports and literature review. *Case Rep Oncol*. 2019;12:69–75. doi: [10.1159/000496331](https://doi.org/10.1159/000496331). PMID: [31043944](https://pubmed.ncbi.nlm.nih.gov/31043944/). PMCID: [PMC6477505](https://pubmed.ncbi.nlm.nih.gov/PMC6477505/).
- 31 López D, Alismail A, Tan LD. Hyperbaric oxygen therapy of an adolescent stem cell transplantation recipient with hemorrhagic cystitis and BK virus. *Case Rep Pulmonol*. 2020;2020:3465412. doi: [10.1155/2020/3465412](https://doi.org/10.1155/2020/3465412). PMID: [32455043](https://pubmed.ncbi.nlm.nih.gov/32455043/). PMCID: [PMC7243008](https://pubmed.ncbi.nlm.nih.gov/PMC7243008/).
- 32 Maken K, Bland DK. Hyperbaric oxygen for refractory hemorrhagic cystitis after stem cell transplantation: case report. *Undersea Hyperb Med*. 2020;47:125–9. PMID: [32176953](https://pubmed.ncbi.nlm.nih.gov/32176953/).
- 33 Savva-Bordalo J, Pinho Vaz C, Sousa M, Branca R, Campilho F, Resende R, et al. Clinical effectiveness of hyperbaric oxygen therapy for BK-virus-associated hemorrhagic cystitis after allogeneic bone marrow transplantation. *Bone Marrow Transplant*. 2012;47:1095–8. doi: [10.1038/bmt.2011.228](https://doi.org/10.1038/bmt.2011.228). PMID: [22080970](https://pubmed.ncbi.nlm.nih.gov/22080970/).
- 34 Cesaro S, Brugiolo A, Faraci M, Uderzo C, Rondelli R, Favre C, et al. Incidence and treatment of hemorrhagic cystitis in children given hematopoietic stem cell transplantation: a survey from the Italian association of pediatric hematology oncology-bone marrow transplantation group. *Bone Marrow Transplant*. 2003;32:925–31. doi: [10.1038/sj.bmt.1704252](https://doi.org/10.1038/sj.bmt.1704252). PMID: [14561994](https://pubmed.ncbi.nlm.nih.gov/14561994/).
- 35 Zama D, Masetti R, Vendemini F, Di Donato F, Morelli A, Prete A, et al. Clinical effectiveness of early treatment with hyperbaric oxygen therapy for severe late-onset hemorrhagic cystitis after hematopoietic stem cell transplantation in pediatric patients. *Pediatr Transplant*. 2013;17:86–91. doi: [10.1111/petr.12031](https://doi.org/10.1111/petr.12031). PMID: [23230825](https://pubmed.ncbi.nlm.nih.gov/23230825/).
- 36 Urbaniak-Kujda D, Kapelko-Słowik K, Biernat M, Dybko J, Laszkowska M, Kuliczowski K. The use of hyperbaric oxygen therapy in the treatment of hemorrhagic cystitis after allogeneic stem cell transplantation from an unrelated donor. *Int J Hematol*. 2015;102:364–7. doi: [10.1007/s12185-015-1832-y](https://doi.org/10.1007/s12185-015-1832-y). PMID: [26121955](https://pubmed.ncbi.nlm.nih.gov/26121955/).
- 37 Hader JE, Marzella L, Myers RA, Jacobs SC, Naslund MJ. Hyperbaric oxygen treatment for experimental cyclophosphamide-induced hemorrhagic cystitis. *J Urol*. 1993;149:1617–21. doi: [10.1016/s0022-5347\(17\)36462-5](https://doi.org/10.1016/s0022-5347(17)36462-5). PMID: [8501819](https://pubmed.ncbi.nlm.nih.gov/8501819/).
- 38 Etlik O, Tomur A, Deveci S, Pişkin I, Pekcan M. Comparison of the uroprotective efficacy of mesna and HBO treatments in cyclophosphamide-induced hemorrhagic cystitis. *J Urol*. 1997;158:2296–9. doi: [10.1016/s0022-5347\(01\)68238-7](https://doi.org/10.1016/s0022-5347(01)68238-7). PMID: [9366379](https://pubmed.ncbi.nlm.nih.gov/9366379/).
- 39 Korkmaz A, Oter S, Deveci S, Goksoy C, Bilgic H. Prevention of further cyclophosphamide induced hemorrhagic cystitis by hyperbaric oxygen and mesna in guinea pigs. *J Urol*. 2001;166:1119–23. PMID: [11490309](https://pubmed.ncbi.nlm.nih.gov/11490309/).
- 40 Korkmaz A, Oter S, Deveci S, Ozgurtas T, Topal T, Sadir S, et al. Involvement of nitric oxide and hyperbaric oxygen in the pathogenesis of cyclophosphamide induced hemorrhagic cystitis in rats. *J Urol*. 2003;170:2498–502. doi: [10.1097/01.ju.0000085593.31396.d8](https://doi.org/10.1097/01.ju.0000085593.31396.d8). PMID: [14634459](https://pubmed.ncbi.nlm.nih.gov/14634459/).
- 41 Oztas E, Korkmaz A, Oter S, Topal T. Hyperbaric oxygen treatment time for cyclophosphamide induced cystitis in rats. *Undersea Hyperb Med*. 2004;31:211–6. PMID: [15485083](https://pubmed.ncbi.nlm.nih.gov/15485083/).
- 42 Minami A, Tanaka T, Otoshi T, Kuratsukuri K, Nakatani T. Hyperbaric oxygen significantly improves frequent urination, hyperalgesia, and tissue damage in a mouse long-lasting cystitis model induced by an intravesical instillation of hydrogen peroxide. *Neurourol Urodyn*. 2019;38:97–106. doi: [10.1002/nau.23822](https://doi.org/10.1002/nau.23822). PMID: [30411813](https://pubmed.ncbi.nlm.nih.gov/30411813/).
- 43 Hosokawa K, Aoki G, Ohata K, Takamatsu H, Nakagawa N, Imi T, et al. Effectiveness of hyperbaric oxygen therapy for virus-associated hemorrhagic cystitis after allogeneic hematopoietic stem cell transplantation. *Int J Hematol*. 2021;114:109–15. doi: [10.1007/s12185-021-03120-y](https://doi.org/10.1007/s12185-021-03120-y). PMID: [33728556](https://pubmed.ncbi.nlm.nih.gov/33728556/). PMCID: [PMC7962929](https://pubmed.ncbi.nlm.nih.gov/PMC7962929/).
- 44 Milovanova TN, Bhopale VM, Sorokina EM, Moore JS, Hunt TK, Hauer-Jensen M, et al. Hyperbaric oxygen stimulates vasculogenic stem cell growth and differentiation in vivo. *J Appl Physiol* (1985). 2009;106:711–28. doi: [10.1152/japplphysiol.91054.2008](https://doi.org/10.1152/japplphysiol.91054.2008). PMID: [19023021](https://pubmed.ncbi.nlm.nih.gov/19023021/). PMCID: [PMC2644249](https://pubmed.ncbi.nlm.nih.gov/PMC2644249/).
- 45 Al-Seraihi A, Ayas M. Hyperbaric oxygen should not be used in the management of hemorrhagic cystitis in patients with Fanconi anemia. *Pediatr Blood Cancer*. 2007;49:854–6. doi: [10.1002/pbc.20692](https://doi.org/10.1002/pbc.20692). PMID: [16317730](https://pubmed.ncbi.nlm.nih.gov/16317730/).
- 46 Cooper JS, Allinson P, Winn D, Keim L, Sippel J, Shalberg P, et al. Continuous bladder irrigation in the monoplace hyperbaric chamber: two case reports. *Undersea Hyperb Med*. 2015;42:419–23. PMID: [26591981](https://pubmed.ncbi.nlm.nih.gov/26591981/).
- 47 Cooper JS, Lagrange CA. Risk of continuous bladder irrigation in the monoplace hyperbaric chamber: a cautionary tale. *Undersea Hyperb Med*. 2018;45:683–4. PMID: [31158936](https://pubmed.ncbi.nlm.nih.gov/31158936/).
- 48 Harkensee C, Vasdev N, Gennery AR, Willetts IE, Taylor C. Prevention and management of BK-virus associated haemorrhagic cystitis in children following haematopoietic stem cell transplantation – a systematic review and evidence-based guidance for clinical management. *Br J Haematol*. 2008;142:717–31. doi: [10.1111/j.1365-2141.2008.07254.x](https://doi.org/10.1111/j.1365-2141.2008.07254.x). PMID: [18540939](https://pubmed.ncbi.nlm.nih.gov/18540939/).
- 49 Oscarsson N, Müller B, Rosén A, Lodding P, Mölne J, Giglio D, et al. Radiation-induced cystitis treated with hyperbaric oxygen therapy (RICH-ART): a randomised, controlled, phase 2–3 trial. *Lancet Oncol*. 2019;20:1602–14. doi: [10.1016/S1470-2045\(19\)30494-2](https://doi.org/10.1016/S1470-2045(19)30494-2). PMID: [31537473](https://pubmed.ncbi.nlm.nih.gov/31537473/).
- 50 Degener S, Pohle A, Strelow H, Mathers MJ, Zumbé J, Roth S, et al. Long-term experience of hyperbaric oxygen therapy for refractory radio- or chemotherapy-induced haemorrhagic cystitis. *BMC Urol*. 2015;15:38. doi: [10.1186/s12894-015-0035-4](https://doi.org/10.1186/s12894-015-0035-4). PMID: [25953493](https://pubmed.ncbi.nlm.nih.gov/25953493/). PMCID: [PMC4423090](https://pubmed.ncbi.nlm.nih.gov/PMC4423090/).
- 51 Gilis L, Morisset S, Billaud G, Ducastelle-Leprêtre S, Labussière-Wallet H, Nicolini FE, et al. High burden of BK virus-associated hemorrhagic cystitis in patients undergoing allogeneic hematopoietic stem cell transplantation. *Bone Marrow Transplant*. 2014;49:664–70. doi: [10.1038/bmt.2013.235](https://doi.org/10.1038/bmt.2013.235). PMID: [24488049](https://pubmed.ncbi.nlm.nih.gov/24488049/).

Conflicts of interest and funding: nil

Submitted: 09 March 2021

Accepted after revision: 20 December 2021

Copyright: This article is the copyright of the authors who grant *Diving and Hyperbaric Medicine* a non-exclusive licence to publish the article in electronic and other forms.