

# A diving physician's experience of dental barotrauma during hyperbaric chamber exposure: case report

Busra Dilara Altun<sup>1</sup>, Selin Gamze Sümen<sup>2</sup>, Asim Dumlu<sup>1</sup>

<sup>1</sup> Marmara University, Faculty of Dentistry, Department of Oral and Maxillofacial Radiology, Istanbul, Turkey

<sup>2</sup> Underwater and Hyperbaric Medicine at the University of Health Sciences, Hamidiye Medical Faculty, Istanbul, Turkey

**Corresponding author:** Dr Busra Dilara Altun, Marmara Üniversitesi Başbüyük Sağlık Yerleşkesi, Diş Hekimliği Fakültesi, Başbüyük Yolu 9/3 34854 Başbüyük, Maltepe, İstanbul, Turkey  
[busradkaraca@hotmail.com](mailto:busradkaraca@hotmail.com)

## Key words

Barodontalgia; Case reports; Hyperbaric oxygen treatment; Pain

## Abstract

(Altun BD, Sümen SG, Dumlu A. A diving physician's experience of dental barotrauma during hyperbaric chamber exposure: case report. *Diving and Hyperbaric Medicine*. 2022 March 31;52(1):63–65. doi: 10.28920/dhm52.1.63-65. PMID: 35313376.) Previous cases of dental barotrauma have been reported in pilots and divers. We report a case of dental barotrauma and barodontalgia in a diving physician accompanying patients during hyperbaric oxygen treatment, and due to pressure changes in the hyperbaric chamber. The physician developed sharp pain localised to the right maxillary molars but radiating to the face, ear and head during decompression from 243 kPa (2.4 atmospheres absolute). The pain intensified following completion of decompression and was consistent with irreversible pulpitis. Clinical examination and panoramic radiography suggested fracture of a heavily restored tooth due to barotrauma. This was managed by tooth extraction. The physician subsequently discontinued accompanying the patients during their hyperbaric oxygen treatment sessions. Dentists and maxillofacial surgery specialists suggest waiting for a minimum of four weeks or until the tooth socket and/or oral tissue has healed sufficiently to minimise the risk of infection or further trauma before exposure to further pressure change. Although seemingly rare, and despite the comparatively slow pressure changes, dental barotrauma can occur in hyperbaric chamber occupants.

## Introduction

Hyperbaric oxygen treatment (HBOT) is defined as inhalation of 100% oxygen at an elevated pressure (most commonly at or above 203 kPa or two atmospheres absolute). It is commonly used for the treatment of decompression sickness, air embolism, carbon monoxide poisoning, problematic wounds such as diabetic foot, ulcers and late effects of radiotherapy.<sup>1–3</sup> HBOT is regarded as a safe treatment modality in which serious side effects (such as pulmonary barotrauma) are rare, and more common side effects (such as hyperoxic myopia or middle ear barotrauma) are usually mild and reversible.<sup>4–6</sup>

Barotrauma may occur due to the changes in volume of gas-containing spaces inside the body, in response to changing atmospheric pressure. If pressure changes happen quickly and pressure equalisation between anatomic gas spaces and changing ambient pressure is not achieved, tissue such as the eardrum may be damaged.<sup>7,8</sup> Head and face barotrauma is especially seen in rigid cavities that cannot expand or contract such as sinuses, middle ear and teeth.<sup>9–11</sup>

Barodontalgia is intraoral pain evoked by a change in barometric pressure.<sup>11</sup> Indirect barodontalgia may occur due to middle ear or sinus barotrauma, with referral of pain to the

teeth.<sup>12</sup> Direct barodontalgia is generally assumed to arise from changes in volume of gas pockets trapped or evolved in defective restorations causing fracture of the restoration and/or the tooth itself (odontocrexis), although there is one report of a tooth fracture occurring on an apparently sound tooth in a fighter pilot during flight.<sup>13</sup> Pain is considered a result of the involvement of the innervated dental pulp. Irreversible pulpitis may occur, which is characterised by persistent pain, even if the cause is eliminated and may be exacerbated at night.<sup>14,15</sup>

Barotrauma, barodontalgia and odontocrexis (tooth fracture) are known risks for divers and pilots who are frequently exposed to pressure changes. To prevent these complications, maintaining good clinical oral health practices such as having biannual dental checkups and daily brushing and flossing teeth are recommended.<sup>16,17</sup>

The risk is less well defined for occupants of recompression chambers. A search of Ovid/Medline, PubMed, ScienceDirect and Web of Science databases up to October 2021 using the terms "hyperbaric oxygen therapy", "dental barotrauma", and "barodontalgia" found 45 cases all experienced during diving and aviation,<sup>13–16,18–23</sup> with none during hyperbaric chamber exposure.

## Case report

The patient consented to the publication of her case history and radiography.

A 49-year-old Turkish woman presented with pain in the right posterior maxillary region. She introduced herself as a hyperbaric physician and stated that she had her right maxillary premolars and molars (tooth numbers: 15, 16, 17 and 18) filled a year previously with no known complications. The pain on the treatment side started when she was accompanying her patients as an inside attendant in the hyperbaric chamber during decompression from 243 kPa. It was described as sharp and radiated to the face, ear and head. It intensified through the subsequent evening in a pattern consistent with irreversible pulpitis. The pain was only partially responsive to strong oral analgesia.

Clinical and radiological examination revealed that there was a fracture in the maxillary right third molar and its restoration (Figure 1). In view of the low probability of successful secondary restoration and the possibility of supraeruption of the tooth over time due to an impacted and ectopic mandibular third molar (Figure 2), an extraction was considered the best treatment. After the extraction she ceased accompanying the patients during their hyperbaric oxygen therapy session in accordance with standard advice to wait for a minimum of four to six weeks or until the tooth socket and/or oral tissue has healed sufficiently to minimise the risk of infection or further trauma before subjecting the wound to pressure change.<sup>17,24,25</sup> Although this recommendation pertains to diving, it was adhered to due to the similarity of the mechanism. During follow-up clinical examination on 15th day post-extraction, the patient reported no complaints.

## Discussion

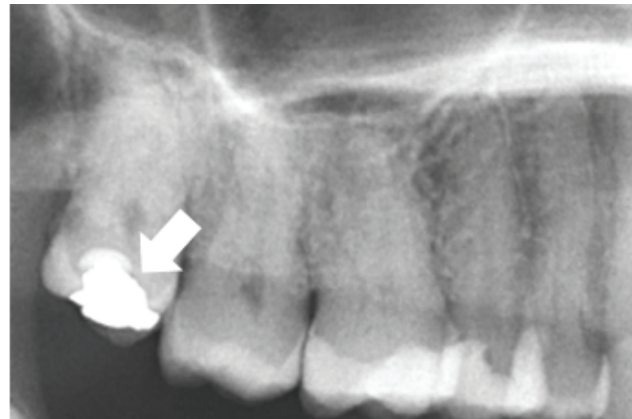Aviators and divers who encounter substantial atmospheric pressure changes may suffer from barodontalgia and dental barotrauma.<sup>13-16,18-23</sup> The present case represents a seemingly rare example of barodontalgia occurring during pressure change in a hyperbaric chamber, and identifies it as a risk for patients and an occupational risk for hyperbaric chamber attendants.

The mechanism of barodontalgia and odontocrexia during pressure changes is still unclear. Trapped air under the restoration or endodontically treated tooth is one explanation. When pressure decreases, trapped air expands and this may result in the fracture of the tooth or dislodgement of restorations. Moreover, expanding air may trigger pain by compressing dentine tubules and pulp.<sup>26,27</sup> The present case is consistent with this theory. Fracture of the restoration appears to have occurred during a decompression which allowed air trapped in her tooth to expand. The patient had no symptoms prior to this decompression.

In relation to prevention, it has been suggested that diving be avoided for at least one week following oral surgery to prevent air from entering healing tissues, and that the dentist must confirm healing.<sup>11</sup> Some publications recommend a four to six week break after tooth extraction.<sup>17,24,25</sup> It follows that we advised our patient that she should not act as a hyperbaric attendant for four weeks after extraction of her third molar. Although she did not have any complaints 15 days after the extraction, this time was necessary for full wound healing.

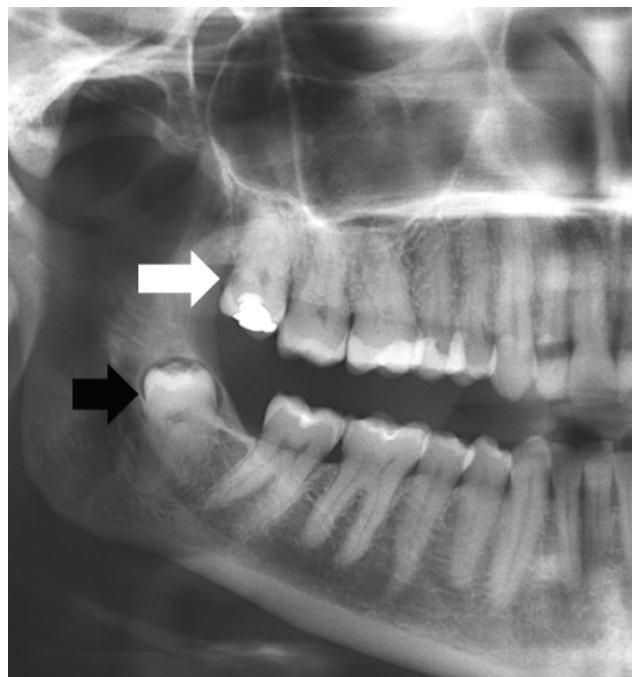
**Figure 1**

Panoramic radiography showing a fracture in the third maxillary molar (white arrow)



**Figure 2**

Panoramic radiography showing unopposed maxillary third molar (white arrow) and impacted mandibular third molar (black arrow)



## Conclusions

In addition to diving and aviation, this case demonstrates that dental barotrauma and barodontalgia can also be encountered during HBOT. Hyperbaric physicians may consider adding dental barotrauma to lists of potential complications in consent processes, especially in patients with poor dentition. Dentists should also be aware of the possibility of dental barotrauma among divers, pilots, hyperbaric physicians and nurses.

## References

- Heyboer M 3rd, Sharma D, Santiago W, McCulloch N. Hyperbaric oxygen therapy: side effects defined and quantified. *Adv Wound Care (New Rochelle)*. 2017;6:210–24. doi: [10.1089/wound.2016.0718](https://doi.org/10.1089/wound.2016.0718). PMID: [28616361](https://pubmed.ncbi.nlm.nih.gov/28616361/). PMCID: [PMC5467109](https://pubmed.ncbi.nlm.nih.gov/pmc/PMC5467109/).
- Chouinard AF, Giasson L, Fortin M. Hyperbaric oxygen therapy for head and neck irradiated patients with special attention to oral and maxillofacial treatments. *J Can Dent Assoc*. 2016;82:g24. PMID: [28240582](https://pubmed.ncbi.nlm.nih.gov/28240582/).
- Devaraj D, Srisakthi D. Hyperbaric oxygen therapy – can it be the new era in dentistry? *J Clin Diagn Res*. 2014;8:263–5. doi: [10.7860/JCDR/2014/7262.4077](https://doi.org/10.7860/JCDR/2014/7262.4077). PMID: [24701552](https://pubmed.ncbi.nlm.nih.gov/24701552/). PMCID: [PMC3972582](https://pubmed.ncbi.nlm.nih.gov/pmc/PMC3972582/).
- Heyboer M 3rd, Wojcik SM, Grant WD, Chambers P, Jennings S, Adcock P. Middle ear barotrauma in hyperbaric oxygen therapy. *Undersea Hyperb Med*. 2014;41:393–7. PMID: [25558548](https://pubmed.ncbi.nlm.nih.gov/25558548/).
- Camporesi EM. Side effects of hyperbaric oxygen therapy. *Undersea Hyperb Med*. 2014;41:253–7. PMID: [24984321](https://pubmed.ncbi.nlm.nih.gov/24984321/).
- Plafki C, Peters P, Almeling M, Welslau W, Busch R. Complications and side effects of hyperbaric oxygen therapy. *Aviat Space Environ Med*. 2000;71:119–24. PMID: [10685584](https://pubmed.ncbi.nlm.nih.gov/10685584/).
- DeGorordo A, Vallejo-Manzur F, Chanin K, Varon J. Diving emergencies. Resuscitation. 2003;59:171–80. doi: [10.1016/s0300-9572\(03\)00236-3](https://doi.org/10.1016/s0300-9572(03)00236-3). PMID: [14625107](https://pubmed.ncbi.nlm.nih.gov/14625107/).
- Robichaud R, McNally ME. Barodontalgia as a differential diagnosis: symptoms and findings. *J Can Dent Assoc*. 2005;71:39–42. PMID: [15649340](https://pubmed.ncbi.nlm.nih.gov/15649340/).
- Zadik Y. Aviation dentistry: current concepts and practice. *Br Dent J*. 2009;206:11–6. doi: [10.1038/sj.bdj.2008.1121](https://doi.org/10.1038/sj.bdj.2008.1121). PMID: [19132029](https://pubmed.ncbi.nlm.nih.gov/19132029/).
- Zadik Y. Barodontalgia. *J Endod*. 2009;35:481–5. doi: [10.1016/j.joen.2008.12.004](https://doi.org/10.1016/j.joen.2008.12.004). PMID: [19345791](https://pubmed.ncbi.nlm.nih.gov/19345791/).
- Zadik Y, Drucker S. Diving dentistry: a review of the dental implications of scuba diving. *Aust Dent J*. 2011;56:265–71. doi: [10.1111/j.1834-7819.2011.01340.x](https://doi.org/10.1111/j.1834-7819.2011.01340.x). PMID: [21884141](https://pubmed.ncbi.nlm.nih.gov/21884141/).
- Kieser J, Holborow D. The prevention and management of oral barotrauma. *N Z Dent J*. 1997;93(414):114–6. PMID: [9470443](https://pubmed.ncbi.nlm.nih.gov/9470443/).
- Gunepin M, Derache F, Audoual T. Fracture of a sound tooth in a pilot under hypobaric conditions. *Aviat Space Environ Med*. 2010;81:691–3. doi: [10.3357/ASEM.2754.2010](https://doi.org/10.3357/ASEM.2754.2010). PMID: [20597251](https://pubmed.ncbi.nlm.nih.gov/20597251/).
- Zadik Y, Einy S, Pokroy R, Bar Dayan Y, Goldstein L. Dental fractures on acute exposure to high altitude. *Aviat Space Environ Med*. 2006;77:654–7. PMID: [16780246](https://pubmed.ncbi.nlm.nih.gov/16780246/).
- Peker I, Erten H, Kayaoglu G. Dental restoration dislodgment and fracture during scuba diving: a case of barotrauma. *J Am Dent Assoc*. 2009;140:1118–21. doi: [10.14219/jada.archive.2009.0338](https://doi.org/10.14219/jada.archive.2009.0338). PMID: [19723944](https://pubmed.ncbi.nlm.nih.gov/19723944/).
- Divers Alert Network. Diver loses five fillings on one dive. 2008. [cited 2021 Nov 17]. Available from: <https://dan.org/safety-prevention/diver-safety/case-summaries/diver-loses-five-fillings-on-one-dive/>.
- Edmonds C, Lowry C, Pennfather J, Walker R, editors. *Diving and Subaquatic Medicine*. 4th ed. New York: Arnold; 2002. p. 233–41.
- Stoetzer M, Kuehlhorn C, Ruecker M, Ziebolz D, Gellrich NC, von See C. Pathophysiology of barodontalgia: a case report and review of the literature. *Case Rep Dent*. 2012;2012:453415. doi: [10.1155/2012/453415](https://doi.org/10.1155/2012/453415). PMID: [23243520](https://pubmed.ncbi.nlm.nih.gov/23243520/). PMCID: [PMC3518957](https://pubmed.ncbi.nlm.nih.gov/pmc/PMC3518957/).
- Gulve MN, Gulve ND. Provisional crown dislodgement during scuba diving: a case of barotrauma. *Case Rep Dent*. 2013;2013:749142. doi: [10.1155/2013/749142](https://doi.org/10.1155/2013/749142). PMID: [23984113](https://pubmed.ncbi.nlm.nih.gov/23984113/). PMCID: [PMC3745870](https://pubmed.ncbi.nlm.nih.gov/pmc/PMC3745870/).
- Holowatyj RE. Barodontalgia among flyers: a review of seven cases. *J Can Dent Assoc*. 1996;62:578–84. PMID: [8764677](https://pubmed.ncbi.nlm.nih.gov/8764677/).
- Zadik Y, Chapnik L, Goldstein L. In-flight barodontalgia: analysis of 29 cases in military aircrew. *Aviat Space Environ Med*. 2007;78:593–6. PMID: [17571660](https://pubmed.ncbi.nlm.nih.gov/17571660/).
- Woodmansey K. Class II barodontalgia: review and report of a case. *Gen Dent*. 2008;56:e39–42. PMID: [21444271](https://pubmed.ncbi.nlm.nih.gov/21444271/).
- Senia ES, Cunningham KW, Marx RE. The diagnostic dilemma of barodontalgia. Report of two cases. *Oral Surg Oral Med Oral Pathol*. 1985;60:212–7. doi: [10.1016/0030-4220\(85\)90296-8](https://doi.org/10.1016/0030-4220(85)90296-8). PMID: [2863800](https://pubmed.ncbi.nlm.nih.gov/2863800/).
- Divers Alert Network. Wisdom tooth extraction and diving. [cited 2021 Nov 17]. Available from: <https://dan.org/health-medicine/health-resources/diseases-conditions/wisdom-tooth-extraction-and-diving/>.
- Edmonds C. *Diving medicine for scuba divers*. 4th edition. 2012. [cited 2021 Nov 17]. Available from: <http://www.deepdivingacademy.it/corsisubtorino/download/Carl-Edmond.pdf>.
- Jagger RG, Jackson SJ, Jagger DC. In at the deep end – an insight into scuba diving and related dental problems for the GDP. *Br Dent J*. 1997;183:380–2. doi: [10.1038/sj.bdj.4809515](https://doi.org/10.1038/sj.bdj.4809515). PMID: [9419946](https://pubmed.ncbi.nlm.nih.gov/9419946/).
- Brandt MT. Oral and maxillofacial aspects of diving medicine. *Mil Med*. 2004;169:137–41. doi: [10.7205/milmed.169.2.137](https://doi.org/10.7205/milmed.169.2.137). PMID: [15040636](https://pubmed.ncbi.nlm.nih.gov/15040636/).

**Conflicts of interest and funding:** nil

**Submitted:** 1 August 2021

**Accepted after revision:** 17 January 2022

**Copyright:** This article is the copyright of the authors who grant *Diving and Hyperbaric Medicine* a non-exclusive licence to publish the article in electronic and other forms.