

Hyperbaric oxygen treatment of central retinal vein occlusion with cilioretinal artery occlusion secondary to hormonal treatment: Case report and review

Asma Khallouli¹, Khaled Khelifi¹, Rahma Saidane¹, Racem Choura¹, Afef Maalej¹, Raja Ben Sassi²

¹ Department of Ophthalmology, Military Hospital of Tunis, Tunisia

² Department of Hyperbaric Oxygen Therapy, Military Hospital of Tunis, Tunisia

Corresponding author: Dr Racem Choura, Department of Ophthalmology, Military Hospital of Tunis, Mont Fleury- 1008, Tunisia

choura.racem@gmail.com

Key words

Cilioretinal artery occlusion; Retinal vein occlusion; Fertility agents; Female

Abstract

(Khallouli A, Khelifi K, Saidane R, Choura R, Maalej A, Ben Sassi R. Hyperbaric oxygen treatment of central retinal vein occlusion with cilioretinal artery occlusion secondary to hormonal treatment: Case report and review. *Diving and Hyperbaric Medicine*. 2020 December 20;50(4):431–436. doi: 10.28920/dhm50.4.431-436. PMID: 33325028.)

Introduction: This report describes a case of central retinal vein occlusion (CRVO) and cilioretinal artery occlusion (CLRAO) after hormonal treatment for induction of ovulation that was successfully treated with hyperbaric oxygen.

Case report: A 48 year-old woman was admitted to our department for sudden blurred vision in her left eye. The patient had a history of 3-months hormonal treatment for induction of ovulation. The best corrected visual acuity was 7/10 (20/32) in the left eye and 10/10 (20/20) in the right eye. Fundus examination of the left eye revealed flame-shaped haemorrhages, whitening of the retina along the distribution of cilioretinal artery and tortuous retinal veins. Fluorescein angiography confirmed the combination of a non-ischaemic CRVO with CLRAO. The patient was treated with a 2 h session of hyperbaric oxygen at 253 kPa (2.5 atmospheres absolute) once daily for a total of 30 sessions. Best corrected visual acuity improved to 10/10 (20/20) in the left eye.

Conclusions: CRVO and CLRAO are both occlusive disorders. HBOT is a safe low-cost treatment modality that can be beneficial in some ocular pathologies. It can maintain oxygenation of the retina through the choroidal blood supply, decrease oedema and preserve compromised tissue adjacent to the ischaemic area.

Introduction

Veno-occlusive retinal disorders are the most common vascular visual impairing condition after diabetic retinopathy. Central retinal vein occlusion (CRVO) is the most common primary veno-occlusive disorders of the retina. Older age, male gender, arterial hypertension, glaucoma and hyperviscosity syndromes are the major risk factors. However, CRVO may occur in young adults with no systemic or ocular disorders. Characteristic fundus findings consist of retinal vascular tortuosity, retinal hemorrhages in the four quadrants, cotton wool spots, optic disc swelling and macular oedema.¹ Thrombosis within a retinal vein leads to a partial obstruction of blood flow. The subsequent increased intraluminal pressure causes transudation of blood products into the retina according to Starling's law which increases the amount of interstitial fluid and protein. This results in an increase in interstitial oncotic pressure, and thus perpetuates tissue oedema.² Macular oedema in retinal vein occlusion is responsible for the visual loss. Unlike ischaemic CRVO with neovascular glaucoma, the non-ischaemic form has typically a more benign course and a better visual outcome. Yet, the

conversion to ischaemic CRVO is not rare.

The retina is supplied by the ophthalmic artery, the first intracranial branch of the internal carotid artery, via the central retinal and the ciliary arteries. The central retinal artery supplies the retina as it branches into smaller segments upon leaving the optic disc. The ciliary arteries supply the choroid and the anterior portion of the globe via the rectus muscles. The cilioretinal artery (CLRA), an anatomic variant seen in about 32% of eyes, arises from the short posterior ciliary arteries. In approximately 19% of eyes it contributes to the macular blood supply.³ The coexistence of CRVO and cilioretinal artery occlusion (CLRAO) is a rare disorder that can be easily overlooked. It was first described in 1968.⁴ Several hypotheses have been advanced to explain the simultaneous development of CLRAO and CRVO. It has been postulated that partial obstruction of the posterior ciliary arteries may be the cause of CLRAO.⁵ The authors hypothesised a spectrum of ocular vascular lesions intermediate between acute CRVO and acute ischaemic optic neuropathy.⁵ The pathogenesis of this condition remains unclear and the possibility of primary occlusion of

the cilioretinal artery must be considered in these eyes.⁶ It has also been supposed that optic disk oedema caused by CRVO may result in CLRAO.⁷ The pathogenesis of CLRAO in patients with CRVO is not precisely known. However, it is most likely the result of elevated intraluminal pressure in the retinal capillaries due to CRVO that exceeds the pressure in the CLRA.⁸

Therapeutic interventions for ischaemic CRVO can be classified into two major categories. The first is aimed at the obstruction to venous outflow, the causal condition. This category includes antithrombotic agents, thrombolytics, optic nerve sheath decompression, and radial optic neurotomy. These treatments do not appear to offer any benefit. The second category is aimed at the consequences of venous occlusion and includes panretinal laser photocoagulation (PRP) and intravitreal anti-vascular endothelial growth factor/corticosteroid agents. These latter are the most commonly used and appear to be effective.⁹

There is no therapy proven to be effective for CLRAO associated with CRVO.¹ Both CRVO and CLRAO are ultimately hypoxic phenomena. Few authors have reported their experience with HBOT in the treatment for this rare combination.⁸ We report a case of apparent success with HBOT in a 48 year-old woman who presented with CRVO and CLRAO after a 3-month history of hormonal treatment for ovulation induction.

Case report

A healthy 48 year-old Caucasian woman was referred to our department for sudden blurred vision in her left eye with onset two days prior. The patient had a history of a 3-month hormonal treatment for induction of ovulation. She reported no previous visual disturbances. Furthermore, she had no cardiovascular risk factors.

At baseline, the best corrected visual acuity was 7/10 (20/32) in the left eye and 10/10 (20/20) in the right eye (Snellen chart). Anterior segment examination and intra ocular pressure were normal. Fundus examination of the left eye revealed whitening of the retina along the distribution of the cilioretinal artery, sparing the fovea, flame-shaped haemorrhages and minimally dilated and tortuous retinal veins (Figure 1).

Fluorescein angiography showed hypofluorescence in the territory of the cilioretinal artery, prolonged arteriovenous filling time and delayed central vein filling, confirming the combination of a non-ischaemic CRVO with CLRAO (Figure 2).

Visual fields were not evaluated. Macular spectral domain optical coherence tomography showed inner layer oedema in the occluded CLRA territory with hyper-reflectivity of the macular retinal inner layer, demonstrating ischaemic damage (Figure 3).

Figure 1

Color and red free fundus photographs demonstrating haemorrhages and venous dilatation consistent with central retinal vein occlusion, and white oedema located in the territory of the cilioretinal artery corresponding to its occlusion

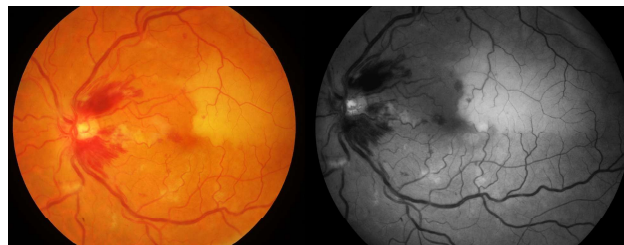

Figure 2

Fluorescein angiography showing marked delay in arteriovenous transit time (longer than 20 seconds), parapapillary retinal haemorrhages and late vessel wall staining associated with non-perfusion of the cilioretinal artery: Combination of a non-ischaemic CRVO and CLRAO

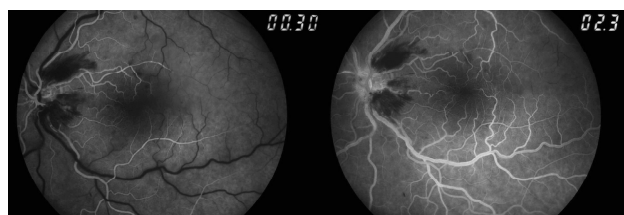
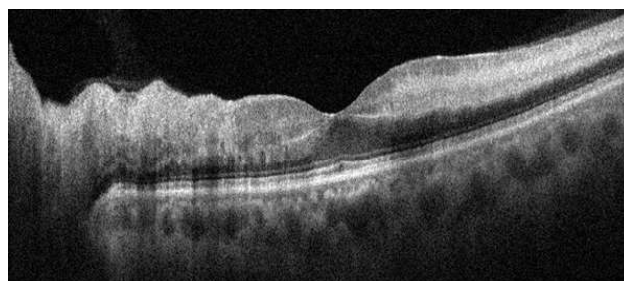


Figure 3

Macular spectral domain optical coherence tomography (SD-OCT) showing inner layer oedema in the territory of the occluded cilioretinal artery with high hyper-reflectivity of the macular retinal inner layer demonstrating ischaemic damages



Optical coherence tomography angiography 6 mm x 6 mm demonstrated an attenuation of both the superficial and deep capillary plexuses, thus defining ischaemic damage in the macular retinal inner layer (Figure 4).

Systemic physical examination revealed no abnormality. Laboratory work up (haematocrit, haemoglobin, white blood cell counts, platelets and erythrocyte sedimentation rate, C-reactive protein, fasting blood lipids and glucose) was unremarkable. Cryoglobulin, lupus anticoagulant, and anti-cardiolipin antibodies were all negative. Antithrombin III, protein C, and protein S activities were normal. Carotid ultrasonography and echocardiography demonstrated no abnormality.

Figure 4

Optical coherence tomography-angiography 6 mm x 6 mm demonstrated an attenuation of both superficial and deep capillary plexus, which correlated precisely with ischaemic damages in the macular retinal inner layer

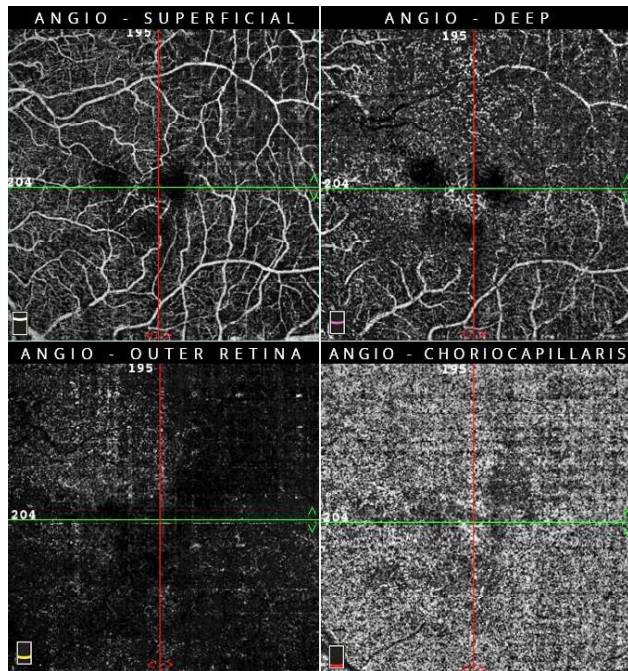


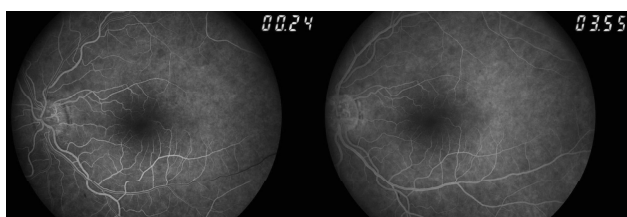
Figure 5

Color and red free fundus photographs at the end of treatment: The haemorrhages were absorbed. The dilation-tortuosity of retinal vessels and the whitening along the course of the cilioretinal artery were completely resolved

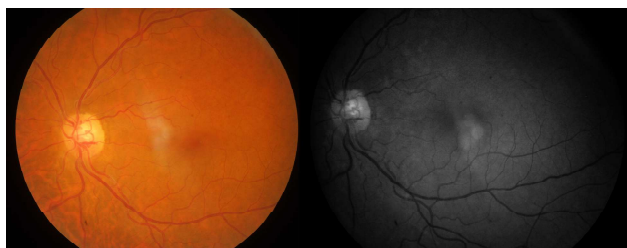

Figure 6

Follow-up fluorescein angiography showing a normal dye arteriovenous transit time and no abnormal fluorescence



The patient was treated with 2-hour daily session of HBOT at 253 kPa (2.5 atmospheres absolute [atm abs]) for a total of 30 sessions. Upon follow-up, best corrected visual acuity had increased to 10/10 (20/20) in the left eye. The haemorrhages were absorbed. The retinal vessel dilation and tortuosity as well as the whitening along the course of the cilioretinal artery had completely resolved (Figure 5). Fluorescein angiography showed a normal arteriovenous dye transit time (Figure 6). Spectral domain optical coherence tomography demonstrated diffuse thinning of the inner nuclear layer, corresponding to the zone of the CLRAO (Figure 7).

Optical coherence tomography angiography of the affected eye showed a wedge-shaped area of capillary non-perfusion in both superficial and deep retinal capillary plexuses in the area supplied by the CLRA. The choriocapillaris was not affected and the central avascular zone was preserved (Figures 8 and 9).

The scheduled treatment was completed successfully without any complication or coincident medical event.

Discussion

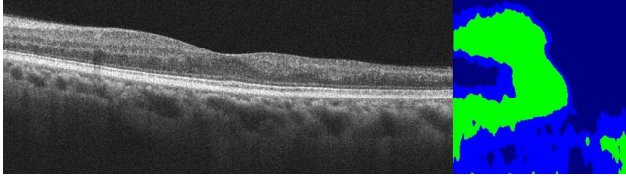
CLRAO has been reported in association with embolism, CRVO and a variety of medical conditions as well as with pregnancy.³ Combined CRVO and CLRAO subsequently reported to account for 40% of all CLRA obstructions.^{5,10} There are three forms of CLRAO: isolated non-arteritic; associated with giant cell arteritis; and associated with CRVO.¹¹

CLRAO associated with CRVO is a clinical entity thought to be due to transient haemodynamic obstruction of the CLRA. It may be caused by sudden increase in retinal capillary pressure to a level higher than normally present in the CLRA. Thus, retinal capillary pressure due to CRVO may exceed CLRA perfusion pressure, causing CLRAO.¹²⁻¹⁴ Alternatively, a primary reduction in the perfusion pressure in the cilioretinal and retinal arteries may cause a decrease in retinal circulation and venous stasis and thrombosis.^{6,15} In eyes with a cilioretinal supply, the probability that cilioretinal infarction will complicate retinal vein occlusion is thought to increase with the severity of venous obstruction and as the origin of CLRA increases distally from the posterior ciliary artery tree.¹⁶

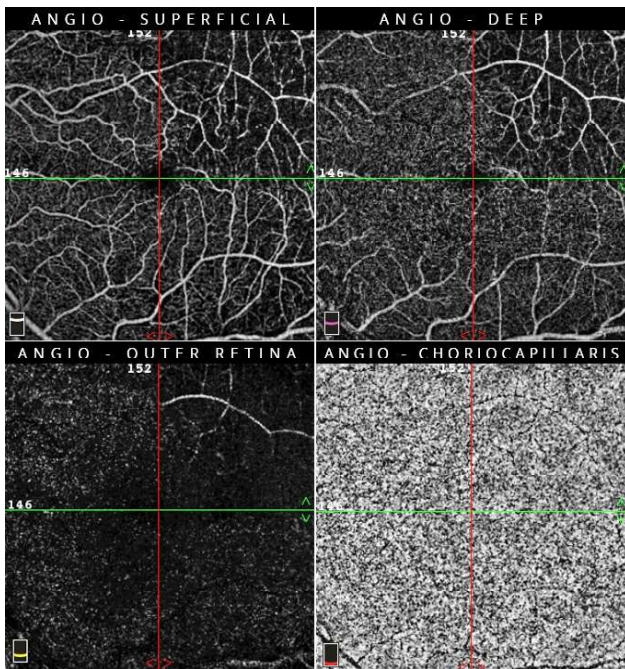
Experimental studies have also shown that arterial constriction following venous obstruction is attributable to a decrease in local levels of nitric oxide, which might contribute to a reduction in CLRA perfusion.¹⁷ The central retinal artery has sufficient autoregulatory capacity to maintain perfusion, in contrast to the CLRA arising from the choroidal vascular bed.¹⁶ Furthermore, perfusion pressure in the choroidal vascular bed is lower than that in the central retinal artery.¹⁸

Figure 7

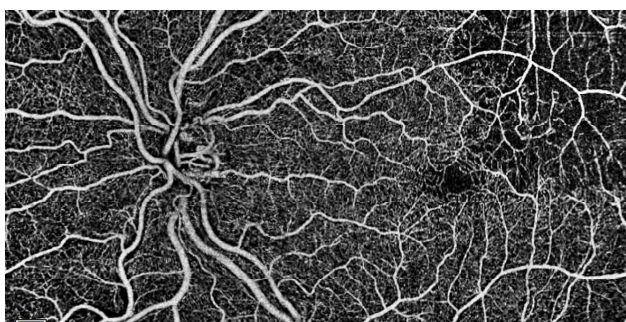
Macular SD-OCT at the end of treatment demonstrating diffuse thinning of the inner nuclear layer, corresponding to the territory of the cilioretinal artery occlusion

**Figure 8**

Optical coherence tomography-angiography 6 mm x 6 mm at the end of treatment revealing a wedge-shaped area of capillary non-perfusion in both the superficial and deep retinal capillary plexus in areas supplied by the cilioretinal artery. The choriocapillaris was not affected

**Figure 9**

Optical coherence tomography-angiography montage of two 8-mm scans passing through the center part of the macula: It allowed clear visualisation of the ischaemic areas and anomalies related to the disappearance of capillary networks in the territory of the occluded cilioretinal artery. Note that the central avascular zone is preserved



The assessment of cilioretinal infarction through the indicators of the degree of venous obstruction includes: a dye transit time > 30 seconds in the central circulation; venous tortuosity; perivenous cotton wool sentinels; and macular perivenular whitening.¹⁶

There is no treatment proven to be effective for CLRAO associated with CRVO.³ Non-ischæmic CRVO often has a favourable course without specific medication. However, ischaemic CRVO usually has a poor visual outcome no matter what treatment is used, and the goals of treatment may be to prevent the development and sequelae of ocular neovascular disease.¹⁹ In regards to the natural history of visual outcome in CLRAO, one study reported that visual acuity was $\geq 20/40$ in 73% of cases on initial examination and 100% of cases on final follow-up.¹¹ Therefore, the effectiveness of treatment modalities for visual outcome needs to be evaluated against this background. With respect to arterial occlusions, the American Academy of Ophthalmology Preferred Practice Guidelines states: *“In general, there are no proven therapies or treatments for symptomatic artery occlusions. There are case reports, small case series, and uncontrolled studies that suggest that several potential interventions may be helpful. However, there are no level I data to support any single specific therapy. Initial treatment of an acute central retinal artery obstruction may include digital massage, anterior chamber paracentesis, vasodilation, breathing into a paper bag, carbogen therapy, topical pressure-lowering therapies, or hyperbaric chambers”*.²⁰

In fact, HBOT is very effective in the large majority of cases if administered early after the onset of vision loss. It is no longer effective in the stage of irreversible ischaemic retinal damage.^{1,21,22} The challenge is to administer supplemental oxygen soon enough to prevent irreversible retinal damage. Most oxygen in blood is bound to haemoglobin, which is 97% saturated at atmospheric pressure. Some oxygen is however carried in solution, and this portion is increased at pressure due to Henry’s law, which may improve tissue oxygenation.²³ When breathing normobaric air, arterial oxygen tension is approximately 13 kPa (100 mmHg) and tissue oxygen tension is about 7 kPa (55 mmHg). However, 100% oxygen at 304 kPa (3 atm abs) can increase arterial oxygen tensions to ~266 kPa (2000 mmHg), allowing the delivery of 60 ml oxygen per litre of blood (compared to 3 ml·L⁻¹ when breathing air at atmospheric pressure). In theory, this would be sufficient to meet the needs of most tissues without any requirement for delivery of oxygen from haemoglobin. The high driving partial pressures allows this dissolved oxygen to diffuse further through poorly perfused tissue and can also enable tissue oxygenation even with impaired haemoglobin oxygen carriage.^{24–26}

Both CRVO and CLRAO are ultimately hypoxic phenomena. During HBOT at 203 kPa the inspired partial pressure of oxygen, which determines the arterial oxygen pressure, is almost ten times greater than when breathing air at normal atmosphere pressure. Oxygen at higher pressure

diffuses from the choroidal circulation or other patent retinal vessels to reach the ischaemic retina. This restores cellular metabolism and keeps the retina alive, giving time for emboli to break-up or redistribute. This may explain the phenomenon of visual improvement reported during the first HBOT session with reduction of retinal oedema resulting in better acuity.²⁷

HBOT has long been used in treating specific ocular conditions such as rhinoorbital mucormycosis and scleral necrosis.²⁸ Recent publications reported that HBOT can likewise be a promising treatment modality for certain ophthalmic vascular diseases. HBOT can be used in selected cases of ischaemic optic neuropathy, central retinal artery occlusion, branch retinal artery occlusion with central vision loss, ischaemic central retinal vein occlusion, ischaemic branch retinal vein occlusion, cystoid macular oedema associated with retinal venous occlusion, diabetic retinopathy, Purtscher's retinopathy, radiation retinopathy and sickle cell retinopathy though the level of supportive evidence is not high for some of these indications.^{1,28-31} Emergency HBOT was first indicated as treatment for acute central retinal artery obstruction (CRAO) in the 2009 committee report of the Undersea and Hyperbaric Medical Society (UHMS) in the USA, and has subsequently been supported by the European Committee for Hyperbaric Medicine.²⁷ Recent studies have suggested that HBOT is a safe, easily administered, low-cost and effective treatment in patients with non-arteritic retinal artery occlusion.³²

A positive response to HBOT should prompt a customised follow-up treatment with supplemental oxygen, in order to maintain retinal viability until the obstructed retinal artery is re-canalized, which typically occurs within 72 hours.²¹ HBOT was also reported as a safe and effective treatment for a case of cystoid macular oedema secondary to retinal vein occlusion.³³ HBOT may not only increase oxygenation and perfusion pressure, but also reduces intraocular and episcleral venous pressure which promotes thrombus migration to a more distal site.^{3,34} In addition, change in luminal sizes of the retinal veins with distending pressure has been described as an effect of HBOT.³⁴ These changes lead to blood flow acceleration in the eye. Favourable response to the first HBOT session should prompt a follow-up HBOT regimen. Admission to a stroke centre and hourly monitored visual status following a successful first HBOT session for CRAO has been recommended.²¹ Vision loss during follow-up requires aggressive use of intermittent 100% normobaric and hyperbaric oxygen, in order to preserve retinal function until central retinal artery recanalisation occurs.²¹ Nonetheless, an evidence-based management plan has not yet been established.

There is no clear recommendation regarding the number or frequency of HBOT sessions in this clinical situation, though guidelines are available for acute CRAO.³⁵ One group used a daily 2-h HBOT at 253 kPa (2.5 atm abs) for 14 consecutive days to treat a 43 year-old patient with a

combination of CRVO and CLRAO.⁸ Another reported the use of a daily 90 min HBOT at 243 kPa (2.4 atm abs) in a patient with ischaemic CRVO. The treatment was continued for 30 days, then decreased to two to three sessions per week for a total of 60 sessions. Visual acuity improved from 20/200 to 20/20.³⁴ In our case, the patient was treated with 2-hour daily session of HBOT at 253 kPa (2.5 atm abs) for a total of 30 sessions. The major parameters for visual prognosis are the time between the onset of symptoms and the starting of HBOT, and the time till retinal reperfusion.³⁶

Conclusions

The combination of CRVO and CLRAO is a discreet clinical entity. Although there are several hypotheses to explain this condition, it is most likely that the elevated intraluminal pressure in the retinal capillaries due to CRVO exceeds the pressure in the CLRA. Both disorders are hypoxic phenomena. Although there is no treatment proven to be effective for this entity, HBOT was suggested to be a potential treatment modality. A multicentre, randomised controlled trial to study the results of using HBOT to treat CRVO (with and without CLRAO) would be ideal, but such a study has not yet been done and would be challenging to accomplish. In the interim, evidence from case series and retrospective cohort studies should be published and carefully reviewed in order to make evidence-based, best practice decisions.

References

- Butler FK Jr, Hagan C, Murphy-Lavoie H. Hyperbaric oxygen therapy and the eye. *Undersea Hyperb Med*. 2008;35:333-87. PMID: 19024664.
- Karia N. Retinal vein occlusion: Pathophysiology and treatment options. *Clin Ophthalmol*. 2010;4:809-16. doi: 10.2147/ophth.s7631. PMID: 20689798. PMCID: PMC2915868.
- Hayreh SS. Acute retinal arterial occlusive disorders. *Prog Retin Eye Res*. 2011;30:359-94. doi: 10.1016/j.preteyeres.2011.05.001. PMID: 21620994. PMCID: PMC3137709.
- Oosterhuis JA. Fluorescein fundus photography in retinal vein occlusion. In: Henkes HE, editor. *Perspectives in ophthalmology*. Amsterdam: Excerpta Medica; 1968.
- McLeod D, Ring CP. Cilio-retinal infarction after retinal vein occlusion. *Br J Ophthalmol*. 1976;60:419-27. doi: 10.1136/bjo.60.6.419. PMID: 25233547. PMCID: PMC1017521.
- Glacet-Bernard A, Gaudric A, Touboul C, Coscas G. Occlusion de la veine centrale de la rétine avec occlusion d'une artère cilio-rétinienne: à propos de 7 cas [Occlusion of the central retinal vein with occlusion of a cilioretinal artery: a propos of 7 cases]. *J Fr Ophtalmol*. 1987;10:269-77. PMID: 3624794. French.
- Schatz H, Fong AC, McDonald HR, Johnson RN, Joffe L, Wilkinson CP, et al. Cilioretinal artery occlusion in young adults with central retinal vein occlusion. *Ophthalmology*. 1991;98:594-601. doi: 10.1016/s0161-6420(91)32245-0. PMID: 2062490.
- Celebi AR, Kilavuzoglu AE, Altiparmak UE, Cosar CB, Ozkiris A. Hyperbaric oxygen for the treatment of the rare

- combination of central retinal vein occlusion and cilioretinal artery occlusion. *Diving Hyperb Med.* 2016;46:50–3. PMID: [27044464](#).
- 9 McAllister IL. Central retinal vein occlusion: A review. *Clin Exp Ophthalmol.* 2012;40:48–58. doi: [10.1111/j.1442-9071.2011.02713.x](#). PMID: [22003973](#).
 - 10 Brown GC, Moffat K, Cruess A, Magargal LE, Goldberg RE. Cilioretinal artery obstruction. *Retina.* 1983;3:182–7. doi: [10.1097/00006982-198300330-00007](#). PMID: [6635353](#).
 - 11 Hayreh SS, Podhajsky PA, Zimmerman MB. Branch retinal artery occlusion. *Ophthalmology.* 2009;116:1188–94. e1–4. doi: [10.1016/j.ophtha.2009.01.015](#). PMID: [19376586](#). PMID: [PMC2759688](#).
 - 12 Keyser BJ, Duker JS, Brown GC, Sergott RC, Bosley TM. Combined central retinal vein occlusion and cilioretinal artery occlusion associated with prolonged retinal arterial filling. *Am J Ophthalmol.* 1994;117:308–13. doi: [10.1016/s0002-9394\(14\)73137-x](#). PMID: [8129002](#).
 - 13 Bottós JM, Aggio FB, Dib E, Farah ME. Impending central retinal vein occlusion associated with cilioretinal artery obstruction. *Clin Ophthalmol.* 2008;2:665–8. doi: [10.2147/oph.s2694](#). PMID: [19668772](#). PMID: [PMC2694011](#).
 - 14 Theoulakis PE, Livieratou A, Petropoulos IK, Lepidas J, Brinkmann CK, Katsimpris JM. Cilioretinal artery occlusion combined with central retinal vein occlusion - a report of two cases and review of the literature. *Klin Monbl Augenheilkd.* 2010;227:302–5. doi: [10.1055/s-0029-1245291](#). PMID: [20408080](#).
 - 15 Hayreh SS, Fraterrigo L, Jonas J. Central retinal vein occlusion associated with cilioretinal artery occlusion. *Retina.* 2008;28:581–94. doi: [10.1097/IAE.0b013e31815ec29b](#). PMID: [18398361](#).
 - 16 McLeod D. Central retinal vein occlusion with cilioretinal infarction from branch flow exclusion and choroidal arterial steal. *Retina.* 2009;29:1381–95. doi: [10.1097/IAE.0b013e3181b85f41](#). PMID: [19898176](#).
 - 17 Donati G, Pournaras CJ, Pizzolato GP, Tsacopoulos M. Decreased nitric oxide production accounts for secondary arteriolar constriction after retinal branch vein occlusion. *Invest Ophthalmol Vis Sci.* 1997;38:1450–7. PMID: [9191609](#).
 - 18 Hayreh SS. Pathogenesis of visual field defects. Role of the ciliary circulation. *Br J Ophthalmol.* 1970;54:289–311. doi: [10.1136/bjo.54.5.289](#). PMID: [4987892](#). PMID: [PMC1207817](#).
 - 19 Flaxel CJ, Adelman RA, Bailey ST, Fawzi A, Lim JJ, Vemulakonda GA, et al. Retinal vein occlusions preferred practice pattern®. *Ophthalmology.* 2020;127:P288–P320. doi: [10.1016/j.ophtha.2019.09.029](#). PMID: [31757503](#).
 - 20 Flaxel CJ, Adelman RA, Bailey ST, Fawzi A, Lim JJ, Vemulakonda GA, et al. Retinal and Ophthalmic Artery Occlusions Preferred Practice Pattern®. *Ophthalmology.* 2020;127:259–87. doi: [10.1016/j.ophtha.2019.09.028](#). PMID: [31757501](#).
 - 21 Butler FK, Hagan C, Van Hoesen K, Murphy-Lavoie H. Management of central retinal artery occlusion following successful hyperbaric oxygen therapy: Case report. *Undersea Hyperb Med.* 2018;45:101–7. PMID: [29571239](#).
 - 22 Murphy-Lavoie H, Butler F, Hagan C. Central retinal artery occlusion treated with oxygen: A literature review and treatment algorithm. *Undersea Hyperb Med.* 2012;39:943–53. PMID: [23045923](#).
 - 23 Pittman RN. Regulation of tissue oxygenation. San Rafael (CA): Morgan & Claypool Life Sciences; 2011. Chapter 4, Oxygen Transport. Available from: <https://www.ncbi.nlm.nih.gov/books/NBK54103/>.
 - 24 Gill AL, Bell CNA. Hyperbaric oxygen: Its uses, mechanisms of action and outcomes. *QJM.* 2004;97:385–95. doi: [10.1093/qjmed/hch074](#). PMID: [15208426](#).
 - 25 Gabb G, Robin ED. Hyperbaric oxygen. A therapy in search of diseases. *Chest.* 1987;92:1074–82. doi: [10.1378/chest.92.6.1074](#). PMID: [3315479](#).
 - 26 Leach RM, Rees PJ, Wilmshurst P. Hyperbaric oxygen therapy. *BMJ.* 1998;317(7166):1140–3. doi: [10.1136/bmj.317.7166.1140](#). PMID: [9784458](#). PMID: [PMC1114115](#).
 - 27 Elder MJ, Rawstron JA, Davis M. Hyperbaric oxygen in the treatment of acute retinal artery occlusion. *Diving Hyperb Med.* 2017;47:233–8. doi: [10.28920/dhm47.4.233-238](#). PMID: [29241233](#). PMID: [PMC6706338](#).
 - 28 Lin LJ, Chen TX, Wald KJ, Tooley AA, Lisman RD, Chiu ES. Hyperbaric oxygen therapy in ophthalmic practice: an expert opinion. *Expert Rev Ophthalmol.* 2020;15:119–26. doi: [10.1080/17469899.2020.1739523](#).
 - 29 Maalej A, Khallouli A, Choura R, Ben Sassi R, Rannen R, Gharsallah H. The effects of hyperbaric oxygen therapy on diabetic retinopathy: A preliminary study. *J Fr Ophthalmol.* 2020;43:133–8. doi: [10.1016/j.jfo.2019.07.005](#). PMID: [31831276](#).
 - 30 Abdalla Elsayed MEA, Mura M, Al Dhibi H, Schellini S, Malik R, Kozak I, et al. Sick cell retinopathy. A focused review. *Graefes Arch Clin Exp Ophthalmol.* 2019;257:1353–64. doi: [10.1007/s00417-019-04294-2](#). PMID: [30895451](#).
 - 31 Lin YC, Yang CM, Lin CL. Hyperbaric oxygen treatment in Purtscher's retinopathy induced by chest injury. *J Chin Med Assoc.* 2006;69:444–8. doi: [10.1016/S1726-4901\(09\)70289-8](#). PMID: [17051757](#).
 - 32 Weiss JN. Hyperbaric oxygen treatment of nonacute central retinal artery occlusion. *Undersea Hyperb Med.* 2009;36:401–5. PMID: [20112531](#).
 - 33 Gokce G, Metin S, Erdem U, Sobaci G, Durukan AH, Cagatay HH, et al. Late hyperbaric oxygen treatment of cilioretinal artery occlusion with nonischemic central retinal vein occlusion secondary to high altitude. *High Alt Med Biol.* 2014;15:84–8. doi: [10.1089/ham.2013.1086](#). PMID: [24673536](#).
 - 34 Wright JK, Franklin B, Zant E. Clinical case report: treatment of a central retinal vein occlusion with hyperbaric oxygen. *Undersea Hyperb Med.* 2007;34:315–9. PMID: [18019081](#).
 - 35 Menzel-Severing J, Siekmann U, Weinberger A, Roessler G, Walter P, Mazinani B. Early hyperbaric oxygen treatment for nonarteritic central retinal artery obstruction. *Am J Ophthalmol.* 2012;153:454–9.e2. doi: [10.1016/j.ajo.2011.08.009](#). PMID: [21996308](#).
 - 36 Celebi ARC, Kadayifcilar S, Eldem B. Hyperbaric oxygen therapy in branch retinal artery occlusion in a 15-year-old boy with methylenetetrahydrofolate reductase mutation. *Case Rep Ophthalmol Med.* 2015;2015:640247. doi: [10.1155/2015/640247](#). PMID: [25722905](#). PMID: [PMC4334424](#).

Conflicts of interest and funding: nil

Submitted: 25 March 2020

Accepted after revision: 16 June 2020

Copyright: This article is the copyright of the authors who grant *Diving and Hyperbaric Medicine* a non-exclusive licence to publish the article in electronic and other forms.