

# Hyperbaric oxygen treatment for infants: retrospective analysis of 54 patients treated in two tertiary care centres

Kubra Ozgok Kangal<sup>1</sup>, Bengusu Mirasoglu<sup>2</sup>

<sup>1</sup> Department of Underwater and Hyperbaric Medicine, University of Health Sciences, Gulhane Faculty of Medicine, Gulhane Research and Training Hospital, Ankara, Turkey

<sup>2</sup> Department of Underwater and Hyperbaric Medicine, Istanbul University, Istanbul Faculty of Medicine, Istanbul, Turkey

**Corresponding author:** Associate Professor Kubra Ozgok Kangal, Gen. Dr. Tevfik Saglam Cad. SBÜ-Gülhane Eğitim ve Araştırma Hastanesi, Sualtı Hekimliği ve Hiperbarik Tıp Kliniği, Etlik/Ankara, Turkey

[kubra\\_ozgok@hotmail.com](mailto:kubra_ozgok@hotmail.com)

## Keywords

Hyperbaric medicine; Neonate; Newborn; Premature

## Abstract

(Ozgok Kangal K, Mirasoglu B. Hyperbaric oxygen treatment for infants: retrospective analysis of 54 patients treated in two tertiary care centres. Diving and Hyperbaric Medicine. 2024 31 March;54(1):9–15. doi: 10.28920/dhm54.1.9-15. PMID:38507905.)

**Introduction:** We aimed to analyse the outcomes of hyperbaric oxygen treatment (HBOT) and describe difficulties encountered in infants, a rare patient population in this therapeutic intervention, with limited scientific reports.

**Methods:** This was a retrospective analysis of patients 12 months old or younger who underwent HBOT in two different institutions. Demographic data, clinical presentation, HBOT indication, chamber type, oxygen delivery method, total number of treatments, outcome and complications were extracted from clinical records.

**Results:** There were 54 infants in our study. The patients' median age was 3.5 (range 0–12) months. The major HBOT indication was acute carbon monoxide intoxication ( $n = 32$ ). A total of 275 HBOT treatments were administered, mostly performed in multiplace chambers ( $n = 196$ , 71%). Only one patient (2%) required mechanical ventilation. Acute signs were fully resolved in the most patients ( $n = 40$ , 74%). No complications related to HBOT were reported.

**Conclusions:** This study suggests that HBOT may be a safe and effective treatment for infants. Paediatricians should consider HBOT when indicated in infants even for the preterm age group.

## Introduction

Hyperbaric oxygen treatment (HBOT) has been widely used for several conditions such as acute carbon monoxide (CO) intoxication, arterial gas emboli, impaired wound healing, and peripheral/traumatic ischaemic conditions.<sup>1</sup> Some of these conditions are also common in the paediatric age group and referral of these patients for HBOT has been increasing in recent decades.<sup>2–6</sup> A retrospective study reported favourable outcomes in 93% of the 139 children who underwent HBOT, mostly for acute CO intoxication.<sup>5</sup> Two consecutive Australian studies in which outcomes were not analysed, described safe administration of HBOT in paediatric patients treated mainly for acute ischaemic conditions and severe infections.<sup>3,4</sup> Although some paediatric series may involve patients under one year of age, data on this group are lacking.<sup>3–5</sup> Use of HBOT in neonates and infants remains very limited, and reports regarding its use in this patient population are scarce except for a few encouraging case reports and case series. Remarkably, HBOT is used only to treat acute indications like peripheral ischaemic conditions and acute CO intoxication in all these reports.<sup>7–15</sup> It is recognised that treating neonates involves difficulties such as the need for an accompanying caregiver, technical issues about administration of treatment

or providing appropriate environmental conditions in the hyperbaric chambers.<sup>16</sup>

Scarcity of evidence about the efficacy and safety of HBOT in this age group together with challenges of managing a neonate in a hyperbaric chamber perhaps cause hesitation and reluctance in HBOT referrals. In view of the potential benefits of HBOT in this age group, the need for related studies arises. In this regard, we aimed to share our experience in treating neonates, particularly in respect of HBOT outcomes and any difficulties encountered. To our knowledge, this is the first study specifically evaluating HBOT use in patients younger than one year of age.

## Methods

This study was approved both by the Ethical Committees of University of Health Sciences – Gulhane Faculty of Medicine (approval number and date: 2020/06; April 19th, 2020) and Istanbul University Istanbul Faculty of Medicine (approval number and date: 508161; September 30th, 2021).

The present study is a retrospective analysis of neonates and infants who underwent HBOT in two university hospitals. Both institutions serve as referral HBOT centres in two different Turkish metropolises, Ankara and Istanbul.

Patients who were 12 months old or younger and treated between January 1st, 2013 and October 31st, 2019 in Gulhane Research and Training Hospital (Gulhane RTH) and between January 1990 and March 2021 at Istanbul Faculty of Medicine (Istanbul FM) were included in the study.

Demographic data, medical history, clinical presentation, HBOT indication, chamber type, oxygen delivery method, total number of HBOT sessions, HBOT outcome, complications related to HBOT and other treatment modalities during HBOT were documented from patient medical files. For acute CO intoxication cases, carboxyhaemoglobin (COHb) levels at referral and delay in HBOT initiation (from onset of intoxication signs) were also recorded.

The age groups were identified as 'neonates' (<28 days) and 'infants' (28 days – 12 months). The patients were classified into two major groups with regard to the conditions they were treated for: 'acute CO intoxication patients' and 'patients with complicated wound-related problems'.

The acute CO intoxication patients were further grouped as 'mild', 'moderate-severe' and 'severe' based on the clinical severity at the time of referral. 'Mild' refers to discomfort, vomiting, difficulty in breastfeeding whereas patients with a minimum one end-organ injury including cardiological, neurological, respiratory or metabolic were recorded as 'moderate-severe'. The patients who required treatment with inotropic drugs, mechanical ventilation, or having multiorgan failure were defined as the 'severe'

group. HBOT was continued until the resolution of all signs in a maximum of five sessions. At the end of the HBOT course, all parents were routinely informed about delayed neurological sequelae (DNS) after CO intoxication. They were also warned to present to the Department of Paediatrics or Department of Underwater and Hyperbaric Medicine as soon as possible if they had any suspicion about DNS development in their infant, and to inform their physicians about the acute CO intoxication history.

The complicated wound related problems group comprised of non-healing wounds, compromised flaps/grafts and acute peripheral ischaemia related problems.

Treatment outcomes were reported as 'full-clinical resolution', 'partial-recovery', and 'no-recovery' for all conditions treated. The definition of each treatment outcome group with regard to the condition treated is presented in Table 1. Treatment outcomes were evaluated with clinical status, related laboratory parameters and wound photos regularly recorded. No long-term follow-ups were included in this study; the patients' clinical status was evaluated at the end of the HBOT course for outcome classification.

One monoplace (Hipertech, MON-08, 2014) (Hipertech, Başakşehir/İstanbul Turkey) and one multiplace HBOT chamber (Hipertech ZYRON 12, 2008) were available in Gulhane RTH whereas in Istanbul FM the treatments were performed in two different multiplace chambers (a Patterson Kelly 1944 chamber between 1990 and 1997,

**Table 1**

The definitions of treatment outcome classifications according to medical condition groups; \*amputation below the ankle joint level is defined as a 'minor amputation', while an amputation above the ankle is defined as a 'major amputation'. HBOT – hyperbaric oxygen treatment

HBOT indication	Full clinical resolution	Partial recovery	No-recovery
Acute carbon monoxide intoxication	Resolution of all signs and symptoms in maximum five sessions	Residual symptoms after fifth HBOT session	No relief of the signs or symptoms after the fifth HBOT session, or death
Non-healing wounds	Complete wound closure	50% or more reduction of wound size and relief of infection signs (redness, swelling, pus, pain)	No change in wound size or an increase in wound size, or death
Peripheral ischaemia related problems	Complete resolution of cyanosis/tissue ischaemia	Partial resolution of cyanosis/tissue ischemia with minimal necrosis or minor amputation* with recovered cyanotic/ ischaemic tissues	Complete necrosis of the cyanotic/ischemic tissues or major amputation,* or death
Grafts/Flaps	Complete survival of the graft/flap	Survival of at least 50% of the graft/flap	Survival of less than 50% of the graft/flap

**Figure 1**  
The infant face mask



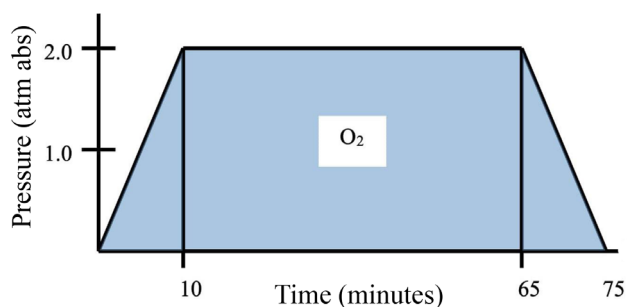
**Figure 2**

The baby incubator used for neonates inside the multiplace hyperbaric chamber



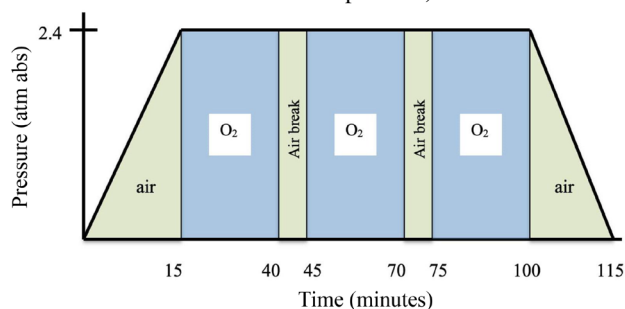
**Figure 3**

The treatment protocol for monoplace chambers which involved breathing 100% oxygen at 203 kPa (2.0 atmospheres absolute [atm abs]) for 75 minutes (10 minutes compression, 55 minutes at 2.0 atm abs, 10 minutes decompression)



**Figure 4**

The treatment protocol for multiplace chambers in which 100% oxygen was administered at 243 kPa (2.4 atmospheres absolute [atm abs]) for 115 minutes (15 minutes compression; three 25-minute oxygen periods separated by five-minute air breaks; 15 minutes decompression)



and a Hipertech ZYRON 12 after 2008). Infants were not treated between 1997 and 2008 in Istanbul FM due to unavailability of chambers. In Gulhane RTH, patients who had emergency conditions and did not require continuous monitoring were preferably treated in the monoplace chamber with an accompanying parent. The monoplace chamber was pressurised with 100% oxygen, so patients breathed ambient oxygen. In multiplace chambers, oxygen was administered via an infant face mask (Figure 1) or hood unless the patient was intubated. A special baby incubator was used for neonates after 2019 in Istanbul FM (Figure 2). An inside attendant was present during all treatments. Treatment protocols are depicted in Figures 3 and 4.

Thermoregulation was provided by covering the baby with multilayer cotton sheets. In Istanbul FM, heated Mediflex® bags were also placed under the sheets in the special baby incubator. Special care was given to avoid direct contact between mediflex bags and the patient. Feeding was continued inside the chamber during the air breaks if

necessary. Pacifier use was encouraged during compression and decompression for enabling middle ear equalisation. Patients who showed signs of discomfort during compression or decompression were examined for middle ear barotrauma by a paediatric specialist after the session.

All patients were evaluated by at least one hyperbaric medicine specialist in both centres in terms of HBOT need. The European Committee for Hyperbaric Medicine (ECHM) and the Undersea and Hyperbaric Medicine Society (UHMS) recommendations were followed.<sup>1,17</sup> The daily and total numbers of HBOT treatments were determined on a case by case basis. For acute CO intoxications, HBOT treatments were continued until no further clinical improvement was observed (maximum five treatments). The patients with complicated wound related problems were recommended to continue HBOT until achieving complete wound closure or complete granulation of the wound bed (ready for graft/flap). HBOT was discontinued if no change was observed for two weeks or amputation was required. For acute peripheral ischaemic tissues, HBOT was continued until

**Table 2**

Demographic data of infants, chamber type, oxygen delivery methods and treatment outcomes; \*chamber is pressurised with 100% oxygen (only in monoplace chambers)

Parameter	Overall data <i>n</i> (%)	Acute carbon monoxide intoxication <i>n</i> (%)	Complicated wound related problems <i>n</i> (%)
<b>Age classification (<i>n</i> = 53)</b>			
Neonates (< 28 days)	15 (28.3%)	6 (18.8%)	9 (42.9%)
Infants (28 days – 12 months)	38 (71.7%)	26 (81.3%)	12 (57.1%)
<b>Sex (<i>n</i> = 51)</b>			
Male	30 (58.8%)	17 (56.7%)	13 (61.9%)
Female	21 (41.2%)	13 (43.3%)	8 (38.1%)
<b>Chamber (<i>n</i> = 54)</b>			
Monoplace	25 (46.3%)	20 (62.5%)	5 (22.7%)
Multiplace	29 (53.7%)	12 (37.5%)	17 (77.3%)
<b>Oxygen delivery (<i>n</i> = 50)</b>			
Ambient oxygen*	25 (50%)	20 (62.5%)	5 (27.8%)
Hood	12 (24%)	10 (31.3%)	2 (11.1%)
Specialised baby incubator	6 (12%)	0	6 (33.3%)
Face mask (infant size)	6 (12%)	1 (3.1%)	5 (27.8%)
Endotracheal tube	1 (2%)	1 (3.1%)	0
<b>Outcomes (<i>n</i> = 53)</b>			
Full clinical resolution	40 (75.5%)	31 (96.9%)	9 (42.9%)
Partial-recovery	8 (15.1%)	0	8 (38.1%)
No-recovery	5 (9.4%)	1 (3.1%)	4 (19.0%)

the demarcation line became evident if total healing was not observed.

Data analysis was performed using SPSS Statistics Version 21 (IBM Corp., Armonk NY, USA). Demographic and descriptive data were reported as *n* (%) and mean (standard deviation) where appropriate. Non-normally distributed data were reported as median (range). The Kolmogorov Smirnov test was performed to determine the normal distribution of continuous variables with data greater than 50, or the Shapiro-Wilk test was preferred for continuous variables with data less than 50.

## Results

There were 54 infants in our study. The patients' median age was 3.5 months (range 2 days to 12 months), two neonates being premature. The demographic data are presented in Table 2. Thirty-one patients (57%) were treated at Gulhane RTH and 23 (43%) were treated at Istanbul FM. The major HBOT indication was acute CO intoxication (*n* = 32). A total of 275 treatments were administered in two institutions. The majority of HBOT treatments (*n* = 196, 71%) were

performed in multiplace chambers. The hyperbaric chamber type and oxygen delivery methods are presented in Table 2. The median HBOT treatment number per patient was one (range one to 48). Most patients (*n* = 40, 74%) fully recovered. No complications were reported during HBOT treatments in both institutions.

## PATIENTS WITH ACUTE CO INTOXICATION

The median age of 32 patients treated for acute CO intoxication was 5 months (range 3 days to 12 months). The median number of treatments was one (range one to five). The mean COHb level at presentation was 22.6% (SD 9.3%), and the mean delay time for HBOT was 4.6 (SD 1.9) hours. The majority (56%) of the patients had moderate-severe clinical severity at referral. Twenty-five patients (79%) had an electrocardiogram (ECG) recorded all of which were reported to be normal. Fourteen patients (44%) had elevated cardiac enzymes at the emergency department admission. Only one patient needed mechanical ventilation and was unconscious during the HBOT initiation. His condition did not change at the end of the HBOT course.



**Table 3**

The detailed classification of medical conditions grouped as 'complicated wound related problems'

Medical conditions	n (%)
Post-operative non-healing wound	3 (13.6%)
Compromised flaps/grafts	2 (9.1%)
Epidermolysis bullosa	1 (4.5%)
Acute peripheral ischaemia	15 (68.2%)
Soft tissue infection	1 (4.5%)

#### PATIENTS WITH COMPLICATED WOUND RELATED PROBLEMS

Twenty-two infants were treated for complicated wound related problems (Table 3). Their median age was 1 month (range 2 days to 12 months), two neonates being premature.. The mean delay time for HBOT was 5.6 (SD 4.5) days. The median number of treatments was 11 (range two to 48).

The medical history was unremarkable only for six patients (27%). All other infants had diagnosed comorbidities including meningomyelocele, hydrocephalus, anti-phospholipid syndrome, undefined vasculitis, Wiskott-Aldrich Syndrome, Fallot tetralogy, ventricular septal defect, intrauterine sepsis and hypoxia, purpura fulminans, flexor tenosynovitis and post-coronavirus disease complications. The wound/ischaemia localisations of the infants were recorded as lower extremity ( $n = 9$ ), upper extremity ( $n = 5$ ), back ( $n = 4$ ), penis ( $n = 2$ ), sternum ( $n = 1$ ) and whole body ( $n = 1$ ).

Two patients had surgical debridement during the course of their HBOT; one patient underwent a graft operation, three patients underwent minor amputations (toe amputation in two, and finger amputation in one) and two others underwent major amputation (one below-knee amputation, and one above-knee amputation). One patient did not complete the recommended HBOT schedule. The treatment outcomes of the patients ( $n = 21$ ) are presented in Table 2.

#### Discussion

Infant patients arguably present the most unique challenges for HBOT physicians. Referrals are few in number and consequently there is little experience reported in the literature. In this study, the characteristics and treatment outcomes of infant patients who underwent HBOT were analysed. A total of 275 HBOT treatments were administered either in monoplace ( $n = 79$ ) and multiplace chambers ( $n = 196$ ) to 54 infants in two tertiary care institutions. Most of the patients ( $n = 40$ , 74.1%) completely recovered and no complications were reported during HBOT treatments.

Although many of the accepted HBOT indications are also relevant to the infant age group, common conditions

for which infants receive HBOT may vary from adults. Delayed radiation injury and complicated wounds have been reported as the most common HBOT indications for adults.<sup>18</sup> However, emergency conditions come to forefront in paediatric series. Acute CO intoxication and acute peripheral ischaemia also involving purpura fulminans, limb ischaemia, critical ischaemia of the glans penis after circumcision are reported to be the most common indications in the paediatric population.<sup>4,5,7-10,15</sup> In our study, the most common HBOT indications were acute CO intoxication ( $n = 32$ ) and acute peripheral ischaemia ( $n = 15$ ) similar to other published infant case series.<sup>7-15</sup> There are promising clinical studies on neonatal hypoxic ischaemic encephalopathy and case reports on necrotising enterocolitis of the neonate but no patients with these conditions were referred for HBOT in this study.<sup>14,19,20</sup> Since these patients mostly need advanced life support and the evidence of efficacy is scarce, paediatricians may be unwilling to suggest HBOT for this critically ill patient group.<sup>14</sup> In contrast, our cohort included two compromised flap cases and an epidermolysis bullosa case which were not reported to be treated with HBOT in this age group before.

Although available published data on infant patients receiving HBOT is limited, their outcomes seem favorable. One study reported full clinical resolution of 13 acute CO poisoning patients among 14 infant patients treated with HBOT.<sup>11</sup> Similarly, two other case reports recorded complete clinical resolution with HBOT in acute CO intoxication.<sup>12,13</sup> In our study, the majority of the acute CO poisoning patients (96.9%) had full clinical resolution, however, the complete clinical recovery rate in the complicated wound related problem group was 40.6%. Most of the complicated wound related problem patients (68.2%) were treated for acute peripheral ischaemia which is an emergent HBOT indication. A promptly initiated frequent HBOT schedule may provide better outcomes in this group.<sup>7</sup> One publication reported a full term neonate with pale bluish discoloration starting at the upper thigh due to severe arterial thromboemboli in the lower extremity, who was referred for HBOT at the 7th day following onset and the outcome was below knee amputation.<sup>15</sup> In contrast, our own group reported complete recovery in an infant who was born with total brachial artery occlusion and severe limb ischaemia. In that case, HBOT was started much earlier (at the 48th postnatal hour) and continued with an intense schedule.<sup>7</sup> Similarly, another group reported different outcomes seemingly related to delay in initiating HBOT in two cases of glans penis ischaemia following circumcision.<sup>10</sup> Collectively, these reports suggest that delay in HBOT may significantly affect the outcome in acute ischaemic conditions. In the present study, the complicated wound-related problem group had relatively long delay times for HBOT which might have contributed to the low clinical resolution rates in this patient group. Lack of awareness, and doubts about safety and effectiveness of HBOT among paediatricians may be leading to delayed HBOT referrals of infants.

The major controversy for infants is the possibility of adverse events during HBOT. Central nervous system oxygen toxicity, pulmonary oxygen toxicity and retinopathy of the premature (ROP) are the most feared complications related to HBOT in infancy. However, no adverse events related to HBOT were reported in infants either in our study or in the available literature.<sup>7,9,10,21</sup> The lack of information about oxygen toxicity in infants may have hindered the application of HBOT in these patients. The literature on ROP and HBOT is scarce and limited to animal studies. Most of them do not present any evidence regarding the relationship between ROP and HBOT.<sup>14,22–24</sup> Only in one experimental study (using rats) was retinal vascular density significantly increased in the HBOT-exposed group. Nevertheless, their HBOT treatment table, in which rats were exposed to 506 kPa (5 atm abs) oxygen, involved a much higher oxygen dose compared to currently utilised clinical HBOT protocols.<sup>25</sup> Therefore, no convincing association between HBOT and ROP in human premature neonates or neonates has been proven. Likewise, a 25-day old neonate, who was born in the 32nd week of gestational age, defined as moderate preterm, underwent 16 HBOT treatments without evidence of ROP in our study. The patient was examined by an ophthalmologist before the first HBOT session, at the end of the HBOT schedule and two weeks after HBOT was ended. Still, infants with ROP risk should be examined before and after HBOT and continued to be regularly followed up by an ophthalmologist.<sup>6</sup>

Thermoregulation and thermoprotection may become significant challenges for infants during HBOT.<sup>6</sup> Newborns, particularly preterm and low-birth-weight neonates, have limited capacity for thermoregulation. Environmental temperature fluctuations can lead to considerable thermal stress in infants and both hypothermia and hyperthermia can lead to significant morbidity and mortality.<sup>26</sup> As temperature fluctuations may be inevitable inside an HBOT chamber, maintaining a stabilised thermoneutral environment can be challenging during HBOT treatments. Therefore, additional protective measures may need to be considered. No complications related to thermal stress were reported in either of our institutions where simple actions like covering the baby with additional sheets were utilised. Also, specialised devices like the hyperbaric chamber compatible baby incubator that was successfully used in Istanbul FM may be developed with the increased need.

Transportation related risks should also be carefully considered for patients who require long distance transfer for each HBOT session. Indeed, extubation and periods of hypotension periods have been reported during transport for HBOT in paediatric patients.<sup>2,3</sup> Another important drawback related to transport may be an increased risk of intraventricular haemorrhage for preterms due to immature fragile vessels.<sup>27</sup> We did not encounter any complication during transportation.

The major limitation was the absence of long-term follow-up, which is particularly significant for acute CO intoxication cases in which there is a recognised risk of delayed neurological sequelae. Due to the study's retrospective nature, data on long-term follow-up were not available. Thus, this study aimed to evaluate acute responses to HBOT as all infant cases with many HBOT indications have been included and evaluated together. The long-term outcomes of HBOT for acute CO intoxication in infants are beyond the aim of this study.

To our knowledge, this is the largest study presenting 54 infants treated with HBOT. We report experience from two HBOT facilities with both multiplace and monoplace chambers, thus providing a broad clinical perspective. The scientific data on HBOT use in this age group is limited. More HBOT research is required in the paediatric population. However, conducting prospective controlled studies is challenging for ethical reasons.

## Conclusions

This study suggests that HBOT is a safe and effective treatment modality for infants. Paediatricians should consider HBOT in centres with appropriate clinical experience in the delivery of HBOT to infants. Paediatricians would be correct to hesitate to refer in centres not appropriately equipped/trained for the delivery of HBOT to infants. Close collaboration between paediatric and the hyperbaric medical teams and improving technical availabilities of HBOT facilities for infant patients would result in improved outcomes. This study may guide hyperbaric physicians in their clinical care of infant patients as well as future scientific studies.

## References

- 1 Moon RE, editor. Hyperbaric oxygen therapy indications. 14th ed. North Palm Beach (FL): Best Publishing Company; 2019.
- 2 Keenan HT, Bratton SL, Norkool DM, Brogan TV, Hampson NB. Delivery of hyperbaric oxygen therapy to critically ill, mechanically ventilated children. *J Crit Care*. 1998;13:7–12. doi: [10.1016/s0883-9441\(98\)90023-5](https://doi.org/10.1016/s0883-9441(98)90023-5). PMID: [9556121](https://pubmed.ncbi.nlm.nih.gov/9556121/).
- 3 Frawley GP, Fock A. Pediatric hyperbaric oxygen therapy in Victoria, 1998–2010. *Pediatr Crit Care Med*. 2012;13(4):e240–4. doi: [10.1097/PCC.0b013e318238b3f3](https://doi.org/10.1097/PCC.0b013e318238b3f3). PMID: [22643574](https://pubmed.ncbi.nlm.nih.gov/22643574/).
- 4 Frawley G, Bennett M, Thistlethwaite K, Banham N. Australian paediatric hyperbaric oxygen therapy 1998–2011. *Anaesth Intensive Care*. 2013;41:74–81. doi: [10.1177/0310057X1304100113](https://doi.org/10.1177/0310057X1304100113). PMID: [23362893](https://pubmed.ncbi.nlm.nih.gov/23362893/).
- 5 Waisman D, Shupak A, Weisz G, Melamed Y. Hyperbaric oxygen therapy in the pediatric patient: the experience of the Israel Naval Medical Institute. *Pediatrics*. 1998;102(5):E53. doi: [10.1542/peds.102.5.e53](https://doi.org/10.1542/peds.102.5.e53). PMID: [9794983](https://pubmed.ncbi.nlm.nih.gov/9794983/).
- 6 Liebert EL. Hyperbaric oxygen therapy in childhood carbon monoxide poisoning. *Curr Opin Pediatr*. 1999;11:259–64. doi: [10.1097/00008480-199906000-00017](https://doi.org/10.1097/00008480-199906000-00017). PMID: [10349107](https://pubmed.ncbi.nlm.nih.gov/10349107/).
- 7 Mirasoglu B, Cetin H, Ozdemir Akgun S, Aktas S. Hyperbaric

- oxygen treatment for intrauterine limb ischaemia: a newborn in the chamber. *Diving Hyperb Med.* 2021;51:220–3. doi: [10.28920/dhm51.2.220-223](https://doi.org/10.28920/dhm51.2.220-223). PMID: [34157740](https://pubmed.ncbi.nlm.nih.gov/34157740/). PMCID: [PMC8426121](https://pubmed.ncbi.nlm.nih.gov/PMC8426121/).
- 8 Siraneci R, Hatipoğlu N, Hatipoğlu H, Dünder K, Baygın L, Yıldız C, et al. Acute arterial thrombotic purpura complicating varicella and the role of hyperbaric oxygen as an adjunctive therapy. *Turk J Pediatr.* 2004;46:256–8. PMID: [15503480](https://pubmed.ncbi.nlm.nih.gov/15503480/).
  - 9 Yılmaz A, Kaya N, Meriç R, Bayramlı Z, Öroğlu B, Celkan TT, et al. Use of hyperbaric oxygen therapy of purpura fulminans in an extremely low birth weight preterm: A case report. *J Neonatal Perinatal Med.* 2023;16:339–42. doi: [10.3233/NPM-200428](https://doi.org/10.3233/NPM-200428). PMID: [32741781](https://pubmed.ncbi.nlm.nih.gov/32741781/).
  - 10 Polak N, Fischelev G, Lang E, Wang Z, Neheman A, Haim YB, et al. Hyperbaric oxygen as salvage therapy for neonates suffering from critical ischemia of the glans penis after circumcision. *Urology.* 2021;149:e48–e51. doi: [10.1016/j.urology.2020.09.006](https://doi.org/10.1016/j.urology.2020.09.006). PMID: [32956687](https://pubmed.ncbi.nlm.nih.gov/32956687/).
  - 11 Rudge FW. Carbon monoxide poisoning in infants: treatment with hyperbaric oxygen. *South Med J.* 1993;86:334–7. doi: [10.1097/00007611-199303000-00017](https://doi.org/10.1097/00007611-199303000-00017). PMID: [8451675](https://pubmed.ncbi.nlm.nih.gov/8451675/).
  - 12 Kreshak AA, Lawrence SM, Ontiveros ST, Castellano T, VanHoesen KB. Perinatal carbon monoxide poisoning: treatment of a 2-hour-old neonate with hyperbaric oxygen. *AJP Rep.* 2022;12(1):e113–e116. doi: [10.1055/s-0042-1744216](https://doi.org/10.1055/s-0042-1744216). PMID: [35280718](https://pubmed.ncbi.nlm.nih.gov/35280718/). PMCID: [PMC8906995](https://pubmed.ncbi.nlm.nih.gov/PMC8906995/).
  - 13 Turan C, Yurtseven A, Baki Beyter M, Saz EU. A 7-day-old male infant with carbon monoxide poisoning treated with hyperbaric oxygen. *Pediatr Emerg Care.* 2020;36(6):e360–e361. doi: [10.1097/PEC.0000000000001612](https://doi.org/10.1097/PEC.0000000000001612). PMID: [30335685](https://pubmed.ncbi.nlm.nih.gov/30335685/).
  - 14 Sánchez EC. Use of hyperbaric oxygenation in neonatal patients: a pilot study of 8 patients. *Crit Care Nurs Q.* 2013;36:280–9. doi: [10.1097/CNQ.0b013e318294e95b](https://doi.org/10.1097/CNQ.0b013e318294e95b). PMID: [23736667](https://pubmed.ncbi.nlm.nih.gov/23736667/).
  - 15 Wiebers J, Purdy I, Lieber M, Milisavljevic V. Hyperbaric oxygen in treatment of neonatal arterial thromboembolism of lower extremities. *J Perinatol.* 2006;26:777–9. doi: [10.1038/sj.jp.7211606](https://doi.org/10.1038/sj.jp.7211606). PMID: [17122788](https://pubmed.ncbi.nlm.nih.gov/17122788/).
  - 16 Waisman D, Baenzinger O, Gall N. Hyperbaric oxygen therapy in newborn infants and pediatric patients. In: Neuman TS, Thom SR, editors. *Physiology and medicine of hyperbaric oxygen therapy*. 1st ed. Philadelphia: Saunders; 2008. p. 95–116.
  - 17 Mathieu D, Marroni A, Kot J. Tenth European consensus conference on hyperbaric medicine: recommendations for accepted and non-accepted clinical indications and practice of hyperbaric oxygen treatment. *Diving Hyperb Med.* 2017;47:24–32. doi: [10.28920/dhm47.1.24-32](https://doi.org/10.28920/dhm47.1.24-32). PMID: [28357821](https://pubmed.ncbi.nlm.nih.gov/28357821/). PMCID: [PMC6147240](https://pubmed.ncbi.nlm.nih.gov/PMC6147240/).
  - 18 Harlan NP, Ptak JA, Rees JR, Cowan DR, Fellows AM, Moses RA, et al. International multicenter registry for hyperbaric oxygen therapy: results through June 2021. *Undersea Hyperb Med.* 2022;49:275–87. PMID: [36001560](https://pubmed.ncbi.nlm.nih.gov/36001560/).
  - 19 Wei L, Wang J, Cao Y, Ren Q, Zhao L, Li X, et al. Hyperbaric oxygenation promotes neural stem cell proliferation and protects the learning and memory ability in neonatal hypoxic-ischemic brain damage. *Int J Clin Exp Pathol.* 2015;8(2):1752–9. PMID: [25973064](https://pubmed.ncbi.nlm.nih.gov/25973064/). PMCID: [PMC4396307](https://pubmed.ncbi.nlm.nih.gov/PMC4396307/).
  - 20 Gong XB, Feng RH, Dong HM, Liu WH, Gu YH, Jiang XY, et al. Efficacy and prognosis of hyperbaric oxygen as adjuvant therapy for neonatal hypoxic-ischemic encephalopathy: a meta-analysis study. *Front Pediatr.* 2022;10:707136. doi: [10.3389/fped.2022.707136](https://doi.org/10.3389/fped.2022.707136). PMID: [35529335](https://pubmed.ncbi.nlm.nih.gov/35529335/). PMCID: [PMC9069061](https://pubmed.ncbi.nlm.nih.gov/PMC9069061/).
  - 21 Jain KK. Hyperbaric oxygenation in obstetrics and gynecology. In: Jain KK, editor. *Textbook of hyperbaric medicine*. Springer; 2017. p. 485–9.
  - 22 Ricci B, Calogero G. Oxygen-induced retinopathy in newborn rats: effects of prolonged normobaric and hyperbaric oxygen supplementation. *Pediatrics.* 1988;82:193–8. PMID: [3399291](https://pubmed.ncbi.nlm.nih.gov/3399291/).
  - 23 Ricci B, Calogero G, Lepore D. Variations in the severity of retinopathy seen in newborn rats supplemented with oxygen under different conditions of hyperbarism. *Exp Eye Res.* 1989;49:789–97. doi: [10.1016/s0014-4835\(89\)80039-9](https://doi.org/10.1016/s0014-4835(89)80039-9). PMID: [2591495](https://pubmed.ncbi.nlm.nih.gov/2591495/).
  - 24 Calvert JW, Zhou C, Zhang JH. Transient exposure of rat pups to hyperoxia at normobaric and hyperbaric pressures does not cause retinopathy of prematurity. *Exp Neurol.* 2004;189:150–61. doi: [10.1016/j.expneurol.2004.05.030](https://doi.org/10.1016/j.expneurol.2004.05.030). PMID: [15296845](https://pubmed.ncbi.nlm.nih.gov/15296845/).
  - 25 Torbati D, Peyman GA, Wafapoor H, Shaibani SB, Khoobehi B. Experimental retinopathy by hyperbaric oxygenation. *Undersea Hyperb Med.* 1995;22:31–9. PMID: [7742708](https://pubmed.ncbi.nlm.nih.gov/7742708/).
  - 26 Sherman TI, Greenspan JS, St Clair N, Touch SM, Shaffer TH. Optimizing the neonatal thermal environment. *Neonatal Netw.* 2006;25:251–60. doi: [10.1891/0730-0832.25.4.251](https://doi.org/10.1891/0730-0832.25.4.251). PMID: [16913236](https://pubmed.ncbi.nlm.nih.gov/16913236/).
  - 27 Özek E, Gülcan Kersin S. Intraventricular hemorrhage in preterm babies. *Turk Pediatr Ars.* 2020;55:215–21. doi: [10.14744/turkpediatrics.2020.66742](https://doi.org/10.14744/turkpediatrics.2020.66742). PMID: [33061747](https://pubmed.ncbi.nlm.nih.gov/33061747/). PMCID: [PMC7536465](https://pubmed.ncbi.nlm.nih.gov/PMC7536465/).

**Conflicts of interest and funding:** nil

**Submitted:** 14 June 2023

**Accepted after revision:** 21 November 2023

**Copyright:** This article is the copyright of the authors who grant *Diving and Hyperbaric Medicine* a non-exclusive licence to publish the article in electronic and other forms.